

Early dysfunction of an implanted pacemaker in a patient with complete atrioventricular block

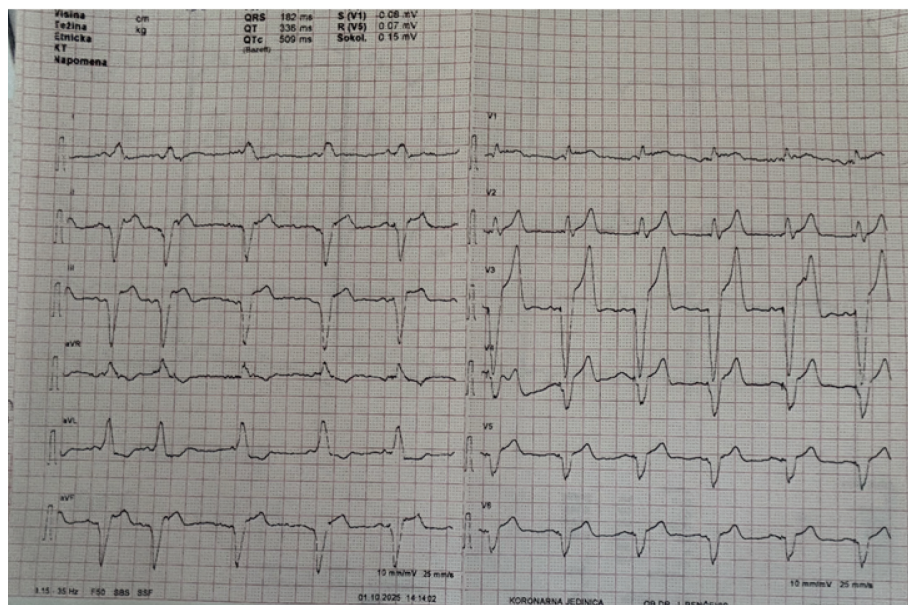


FIGURE 2. 12-lead electrocardiogram after pacemaker implantation.

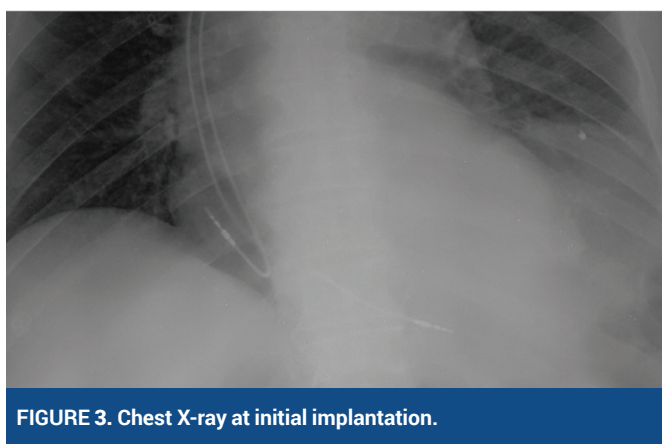


FIGURE 3. Chest X-ray at initial implantation.

imaging revealed no displacement of the electrode, with identical positioning and normal electrode impedance. The ventricular electrode failed to transmit impulses even when connected to the programmer. Therefore, a new ventricular electrode was implanted via the left subclavian vein (Figure 4).

Conclusion: Dysfunction of the ventricular electrode may have been due to a microfracture of the electrode, which was not visible radiographically, or a microtear into fibrotic tissue².

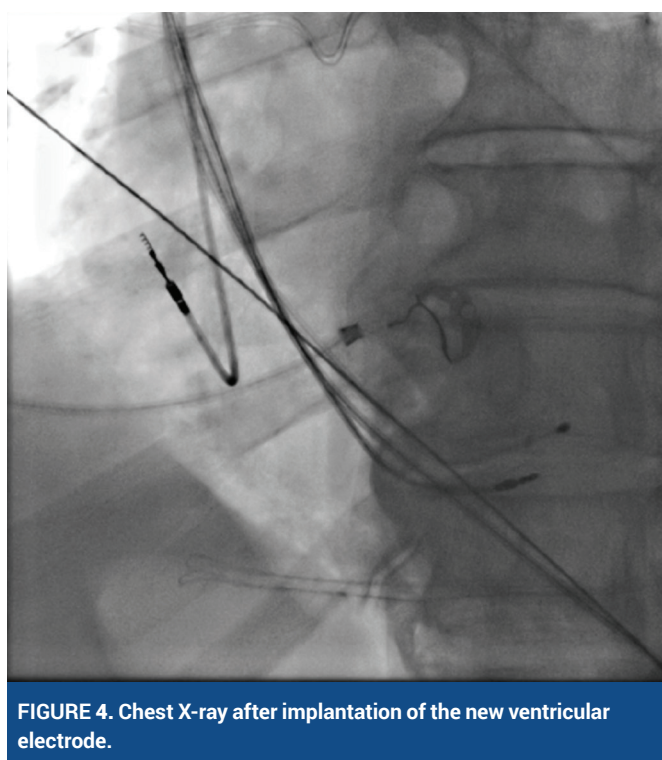


FIGURE 4. Chest X-ray after implantation of the new ventricular electrode.

LITERATURE

1. Ahmed I, Goyal A, Chhabra L. Atrioventricular Block. [Updated 2024 Feb 12]. In: StatPearls [Internet]. Treasure Island (FL): StatPearls Publishing; 2025 Jan-. Available from: <https://www.ncbi.nlm.nih.gov/books/NBK459147/>
2. Yolay İF, İşler Y, Kaya H, Yüksel M, Ay MO, Ocak U. Factors Influencing Mortality in Patients with Pacemaker/ICD Dysfunction Presenting to Emergency Departments. Eurasian J Emerg Med. 2024 Dec 18;23(4):270-277. <https://doi.org/10.4274/eajem.galenos.2024.47113>