

Ablation-induced myocardial infarction: a case report

Josip Ereiz^{1,*},
Ante Lisičić²,
Ana Jordan²,
Katica Cvitkušić-Lukenda^{1,3}

¹General Hospital "Dr. Josip Benčević", Slavonski Brod, Croatia

²Dubrava University Hospital, Zagreb, Croatia

³Josip Juraj Strossmayer University of Osijek, Faculty of Dental Medicine and Health Osijek, Osijek, Croatia

KEYWORDS: radiofrequency ablation, myocardial infarction, posterolateral branch, coronary sinus.

CITATION: *Cardiol Croat.* 2026;21(1-2):26-7. | <https://doi.org/10.15836/ccar2026.26>

***ADDRESS FOR CORRESPONDENCE:** Josip Ereiz, Opća bolnica "Dr Josip Benčević", Andrije Štampara 42, HR-35000 Slavonski Brod, Croatia. / Phone +385-99-534-4456 / E-mail: ereiz12345@gmail.com

ORCID: Josip Ereiz, <https://orcid.org/0009-0002-2139-016X> • Ante Lisičić, <https://orcid.org/0000-0002-4365-9652>
 Ana Jordan, <https://orcid.org/0000-0001-5610-6259> • Katica Cvitkušić-Lukenda, <https://orcid.org/0000-0001-6188-0708>

Introduction: Coronary artery (CA) injury is a rare complication following radiofrequency ablation (RFA) with the overall incidence of less than 0.1%. The risk of injury can be even higher (50%) if applying radiofrequency energy within 2mm of the CA.¹⁻³

Case report: The patient, a 36-year-old Caucasian female was referred for an electrophysiology (EP) study (April 2022) after narrow complex tachycardia had been diagnosed in the Emergency Department. The patient is a healthy adult with highly symptomatic episodes of palpitations which occurred daily. The EP study was conducted, confirming the diagnosis of typical atrioventricular nodal re-entrant tachycardia (AVNRT). After the radiofrequency energy was applied on the slow pathway, solely the atypical AVNRT was re-induced. The site of the earliest activation was located on the posteroseptal part of the right atrium, next to the ostium of the coronary sinus (CS). An additional ablation was performed and the tachycardia was terminated. After the procedure, a single episode of ventricular fibrillation was observed, necessitating prompt defibrillation (**Figure 1**). Once the return of the spontaneous circulation has been re-established, electrocardiogram demonstrated changes indicative of an acute myocardial infarction of the posterior region (**Figure 2**). The next step involved an urgent invasive coronary angiography, which confirmed acute occlusion of the posterolateral (PL) branch situated next

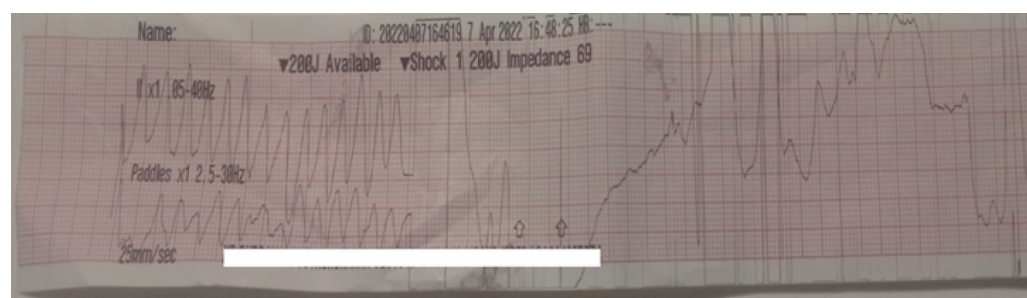


FIGURE 1. Ventricular fibrillation after radiofrequency ablation.

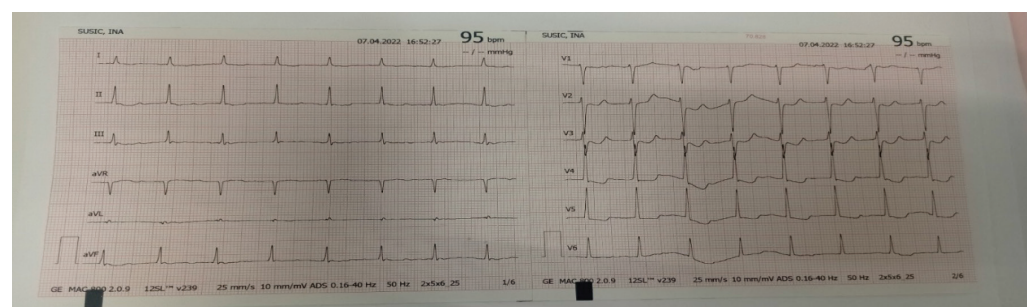


FIGURE 2. Acute posterior myocardial infarction after radiofrequency ablation.

RECEIVED:
 October 19, 2025

ACCEPTED:
 November 14, 2025



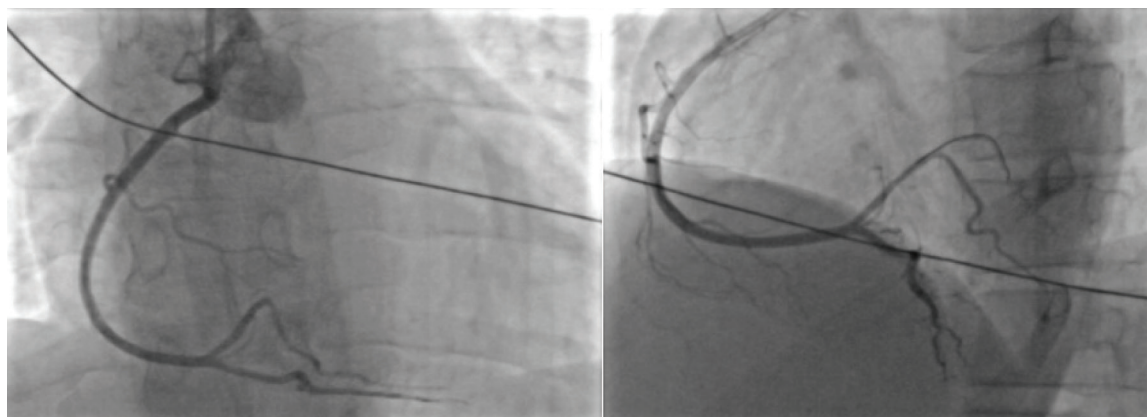


FIGURE 3. Coronary angiography, occluded posterolateral branch.

to the ostium of the CS (**Figure 3**). Percutaneous transluminal coronary angioplasty was performed and re-established the blood flow through the PL branch, but on the follow-up angiogram, a localised contrast extravasation was observed. After a prolonged balloon inflation, normal flow through the PL was restored. Over the course of the remaining hospitalization, the patient was hemodynamically stable, without residual chest pain and without segmental wall motion abnormalities or pericardial effusion on echocardiogram. New arrhythmias were not detected.

Conclusion: Even though the RFA is highly effective, caution is necessary when applying energy within the CS due to its close anatomical correlation with PL branch. Performing coronary angiography prior to the energy delivery may aid in the prevention of CA injury.

LITERATURE

1. Stavrakis S, Jackman WM, Nakagawa H, Sun Y, Xu Q, Beckman KJ, et al. Risk of coronary artery injury with radiofrequency ablation and cryoablation of epicardial posteroseptal accessory pathways within the coronary venous system. *Circ Arrhythm Electrophysiol*. 2014 Feb;7(1):113-9. <https://doi.org/10.1161/CIRCEP.113.000986>
2. Mao J, Moriarty JM, Mandapati R, Boyle NG, Shivkumar K, Vaseghi M. Catheter ablation of accessory pathways near the coronary sinus: value of defining coronary arterial anatomy. *Heart Rhythm*. 2015 Mar;12(3):508-514. <https://doi.org/10.1016/j.hrthm.2014.11.035>
3. Bhaskaran A, Chik W, Thomas S, Kovoov P, Thiagalingam A. A review of the safety aspects of radio frequency ablation. *Int J Cardiol Heart Vasc*. 2015 Jun 9;8:147-153. <https://doi.org/10.1016/j.ijcha.2015.04.011>