



A SYSTEMATIC REVIEW OF CEREBRAL ATROPHY IN ISCHEMIC STROKE

Fahad Soma^{1*}, Azka Khan², Anna Podlasek^{3,4} and Faraz Ahmed Bokhari⁵

¹King Abdulaziz University, Occupational Therapy Department, Faculty of Medical Rehabilitation Sciences, Jeddah, Saudi Arabia

²Riphah International University, Faculty of Rehabilitation and Allied Health Sciences Islamabad, Pakistan

³NIHR Nottingham BRC, University of Nottingham, Nottingham, UK

⁴Clinical Radiology, Queens Medical Centre - Nottingham University Hospitals NHS Trust, Nottingham, UK

⁵Department of Physiology, Shaikh Zayed Federal FPGMI, Lahore, Pakistan.

SUMMARY – Background: Stroke, a neurological condition, ranks as the second leading cause of death and disability worldwide, resulting in sensory, motor and cognitive impairments. Post-stroke cerebral atrophic changes in various brain regions, both ipsilesional and contralesional, carry significant clinical implications. This systematic review and meta-analysis aims to explore structural (volume and cortical thickness) and functional deficits induced by post-ischemic stroke cerebral atrophy.

Methods: The review encompassed studies conducted from January 2010 to October 2021, resulting in the inclusion of 33 articles sourced from PubMed/Medline, Cochrane/EMBASE and PEDro databases. Keywords such as 'stroke', 'cortical atrophy', 'cerebral atrophy', 'motor', 'sensory' and 'cognitive disability' were utilized in the search process.

Results: Notably, the temporal lobe emerged as the most commonly affected site for atrophic volume changes, followed by the thalamic areas, hippocampus, cerebellum and sensory cortex. Cortical thinning was observed in frontotemporal, inferior parietal, primary motor cortex (M1) and superior frontal gyrus regions of the stroke hemisphere. Regarding functional outcomes, gray matter volume (GMV) was found to correlate with motor function, with severe GMV atrophy hindering clinical recovery, while increased GMV was linked to better outcomes. Additionally, GMV was associated with cognitive functions. Notably, changes in total and regional brain tissue volume were observed early post-stroke and continued at an accelerated rate compared to normal age-related atrophic changes.

Conclusion: This underscores the potential of brain atrophy as a prognostic marker for identifying regions of structural plasticity and as a therapeutic target.

Keywords: Stroke; Cortical atrophy; Cerebral atrophy; Motor, sensory and cognitive impairment

Correspondence to: *Fahad Soma*

King Abdulaziz University, Occupational Therapy Department,
Faculty of Medical Rehabilitation Sciences, Jeddah, Saudi Arabia
Email: fsomaa49@gmail.com

Received March 18, 2024, accepted May 27, 2024

Introduction

Stroke is the second most common cause of disability and death worldwide, accounting for 5.5 million deaths and a 50% rate of disability among stroke survivors¹. Depending on the underlying pathogenic mechanisms that cause it, stroke is categorised as either ischemic or hemorrhagic. Ischemic stroke is more common. It is characterized by an initial occluded vessel leading to irreversible brain damage and secondary distal changes such as cerebral atrophy. Subsequently, it leads to long-term disabilities depending on the injured brain area².

The abnormal processes that underline cerebral atrophy vary according to the location and pattern of the atrophy, though generally atrophy involves a reduction in the size or volume of the brain's cortex (involving the extra pyramidal, pyramidal, cerebellar and autonomic systems), a widening of the cortical sulci, gradual enlargement of the ventricles and pronounced cortical thinning³. Cerebral atrophy includes atrophy of the cortical (gray matter (GM) of the cerebral cortex) and subcortical areas (subcortical white and gray matter, such as basal ganglia or fibres in the deep white matter (WM)). Cortical atrophy is associated with Alzheimer's disease and drug/alcohol toxicity⁴, and subcortical atrophy to age-related cerebral small vessel disease⁵ and other issues like inflammatory demyelination (i.e., multiple sclerosis)⁶. Many clinical presentations present with both cortical and subcortical atrophy patterns, which may reflect the fact that multiple pathologies, including Alzheimer's disease and cerebrovascular disease, work concurrently⁷. Both cortical and/or subcortical atrophy has been linked with risk factors for arteriosclerosis, including diabetes, hypertension and cigarette smoking⁸, indicating that the dominant underlying pathology is vascular in nature – arteriosclerosis⁹.

Interestingly, correlations between ischemic stroke and cerebral atrophy have also been described in the literature. Ermine *et al.* induced human ischemia-like changes in an animal model and found that it led to the formation of a chronically progressive cortical atrophy which was widespread, distant from the infarct site and progressively extending all over the infarcted hemisphere¹⁰. Also, recent imaging studies confirm diffuse and progressive atrophy beyond the ischemic area as an important pathophysiological feature of

stroke, including structural changes ranging from progressive atrophy of the whole brain to reduction in contralateral thalamic volume¹¹⁻¹⁴.

This systematic review and meta-analysis aims to summarise the current literature on post-stroke secondary cerebral atrophy and its clinical impact. It includes a detailed description of the spatial patterns of post-stroke atrophy including their location, extent and volume. From the clinical standpoint, this article also examines the impact of these changes on functional deficits in patients.

Materials and Methods

The present review was conducted and reported according to the Preferred Reporting Items for Systematic Reviews and Meta-Analyses (PRISMA) guidelines for systematic reviews and meta-analyses¹⁵.

Search strategy

Articles published between January 2010 and April 2021 on the PubMed/Medline, Cochrane/EMBASE and PEDro databases were examined. The search was performed using the Boolean operations "OR" and "AND," with the following keywords: stroke, cortical atrophy, cerebral atrophy, motor, sensory and cognitive disability, which were employed in combination or separately. First, duplicates were removed from the titles and abstracts. The remaining titles/abstracts were reviewed by two independent assessors (A.K., A.P.). The full texts were then retrieved and independently evaluated for eligibility. Additional relevant research was found by hand-searching the reference list of the included papers. Conflicts were resolved by a third independent assessor (F.S.).

Study selection

The inclusion criteria for the studies were as follows: studies that included patients with cerebral atrophy confirmed through structural magnetic resonance imaging (MRI), studies conducted on human participants affected by an ischemic stroke. Articles of any design were eligible for inclusion (including randomized controlled trials, cohort studies, observational studies, systematic reviews, meta-analyses and conference proceedings).

The studies' exclusion criteria included the following: studies published in any language other than English, studies for which the full text was not available and technical papers.

Data collection

Data extracted from the included studies and the results generated in this systematic review provided an exhaustive summary of the present literature regarding cortical atrophy and several other impairments following cerebrovascular accidents. Moreover, our study highlighted a possible complication that could

be found due to cortical atrophy in a particular group of patients containing a specific set of characteristics, like age or sex, and which is absent in other groups of patients. This information acted as a framework for further medical research in this domain.

Statistical analysis

Standard descriptive measurements were utilized to describe baseline information. However, due to the degree of between-study reporting heterogeneity, statistical/meta-analysis was not performed.

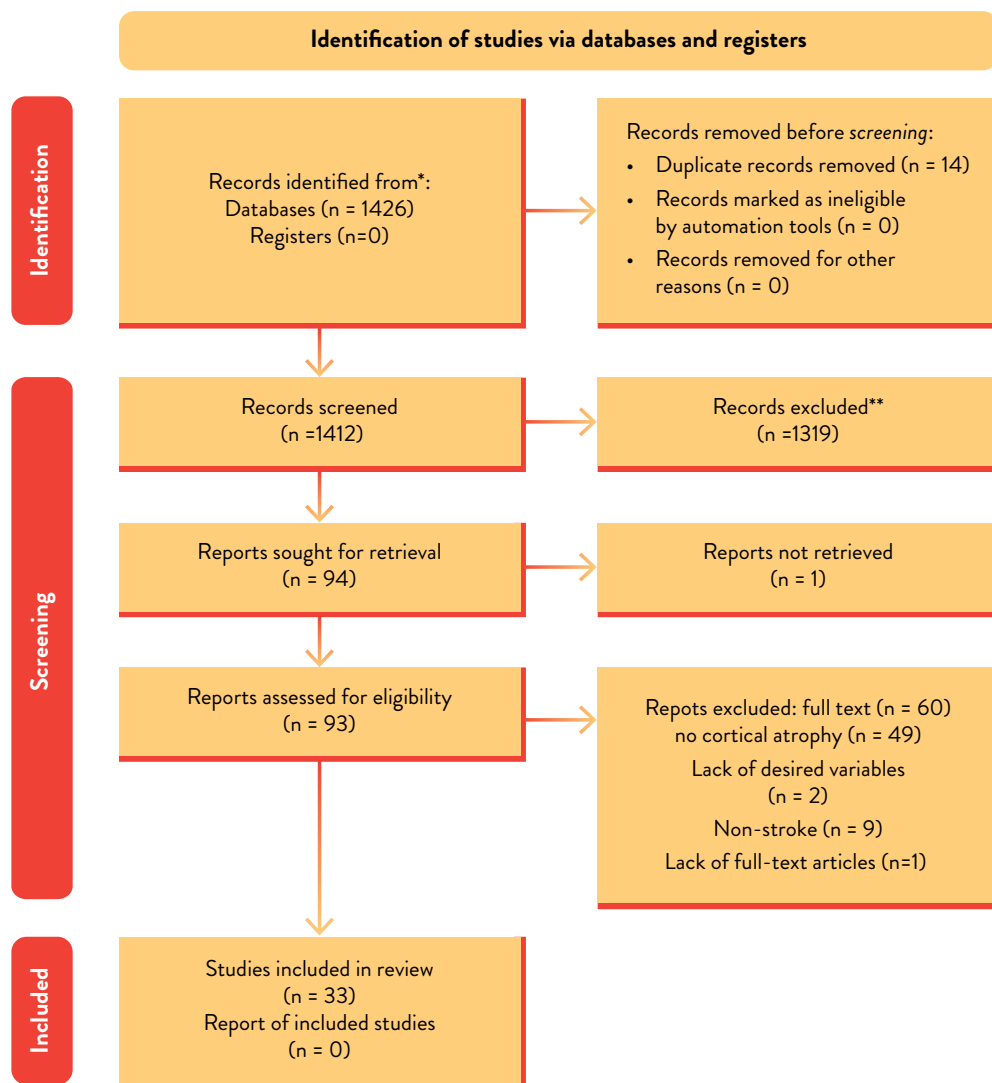


Figure 1. PRISMA Flowchart

Study quality assessment

The included studies were assessed for the risk of bias. ROBINS-I tool (ROB-1) was used for the evaluation of non-randomised studies¹⁶. Moreover, it was visualized by the robvis tool.

Results

For this systematic review, 1,426 titles and abstracts were retrieved through different database searches. After the removal of duplicates, the remaining 1,412 titles and abstracts were screened. A total of 93 full-text articles were extracted from these 1,412 studies for further evaluation and a total of 33 articles were included in this systematic review. A PRISMA flow diagram of database research was generated (Figure 1).

Time since onset of stroke: The included studies reported cerebral changes in the brains of stroke survivors. Several studies included participants during the acute stage (a few days to a few weeks post-stroke)¹⁷⁻²⁴, while other studies included participants three months post-stroke^{11 12 25-30}.

Few studies included participants six or more months post-stroke^{13 31-35}. Brodtman³⁶ included participants between 3 and 12 months after their stroke event. The remaining studies considered patients with more than 18 months of history after stroke³⁷⁻³⁹.

Assessment Scale for Motor, Sensory and Cognitive Changes: Different assessment scales were used to assess sensory, motor and cognitive changes. National Institutes of Health Stroke Scale (NIHSS), the Motricity Index (MI), the Barthel Index (BI), the Modified Rankin Scale (MRS) and the Fugl-Meyer Assessment (FMAS) were used for the assessment of motor-related changes. NIHSS, the Mattis Dementia Rating scale (MDRS), the Montreal Cognitive Assessment (MoCA) and the Mini-Mental State Exam (MMSE) were used for sensory assessment. Cognitive impairment was assessed with MoCA, Rey's Auditory Verbal Learning Test (RAVLT), MMSE, the Geriatric Depression Scale (GDS), MDRS, the Hospital Anxiety and Depression Scale (HADS) and other study-specific cognitive measures reported in the included studies (Table 1).

Structural/Volume Change (Table 2)

Changes in the volumes of various parts of the brain were found in various studies (Table 1). The most frequently quoted changes in volume were in the temporal lobe, thalamic areas, hippocampi, front cortex, cerebellum and somatosensory area (S1, S2). Also, white matter hyperintensities (WMHs) were noted to be associated with cognitive decline.

Cortical thickness (CT) (Table 2)

A high number of WMHs was associated with a thinner cortex, especially across frontotemporal and inferior parietal cortical regions. Ipsilesional changes in CT were noted even after short periods following the stroke, while contralesional areas exhibited increased CT. Other studies noted a significant decrease in CT in areas linked with ischemic stroke three months post-stroke and the same has been documented one year post-stroke. Significant linkage was found between focal cortical thinning and the probability of connectivity with the infarcted region. Another finding was microstructural damage in WM tracts connecting acute strokes with distant cortical locations, which significantly correlated with CT changes in those connected cortical areas. A focal decrease in CT was noted in the connected and affected M1 compared to the non-affected M1 (only in the deepest layers). Significant cortical thinning was noted in the superior frontal gyrus of the stroke hemisphere.

Functional outcomes (Table 2)

GMV was found to be related to motor centers and functional outcomes. Also, it correlated with MI in cognitive-related areas (after adjusting for time intervals). Moreover, severe GMV atrophy in the ipsilesional precentral gyrus (PreCG) led to deficient clinical recovery. Elsewhere, the GMV of the ventromedial prefrontal cortex was found to be inversely related to pain intensity. Better clinical outcomes were found to be related to an increase in GMV in the contralesional orbitofrontal gyrus (OFG) and middle frontal gyrus (MFG). Bilateral GMV changes in posterior cerebellar

Table 1. Demographic, Stroke-related Summary Statistics and Cerebral Atrophy Characteristics

	Age in years ± SD	Sex M/F	Stroke related	Structural/ Volume changes	Cortical thickness	Functional changes/ outcomes	Comorbidities
Aoi, 2012 ³¹	63.41.4 (Cases) 65.3 ± 0.8 (Controls)	19/14 61/48	Stroke sidedness: R/L: 11/8 (males) 7/7 (females) 38/23 (males), 25/23 (females)	Frontal, temporal and parietal lobe volumes were significantly smaller in stroke cases (ipsilateral to stroke)		Better cerebral blood flow regulation is linked with lesser atrophy and better long-term functional outcomes in older adults with chronic ischemic infarctions	Hypertension in 23/33 cases and smoking.
Auriel, 2016 ³⁷	62.6 ± 7.8 (CCI>60 mL/min, n=259) 74.9 ± 8.3 (CCI<60 mL/min, n=172)	185/74 78/96		Ischemic strokes, WMHs/ abnormal microstructural integrity; Intracranial volume and hippocampal volume lesser in CCI <60 group than >60 group		Mild cognitive impairment, dementia, depression	Diabetes mellitus, Dyslipidemia, Hypertension, Ischemic heart disease and smoking.
Baker, 2019 ¹⁷	59.3 ± 12.2 (No cerebral atrophy, n=589) 68.6 ± 12 (Subcortical atrophy n=144) 67.8 ± 11 (Cortical atrophy n=203)	358/231 122/81 100/44	Strokes with atrophy (cortical/subcortical/both) were likely to have ischemic cardioembolic cause in addition to WMLs.	Patients with isolated subcortical atrophy or with both atrophy subtypes were significantly more likely to have retinopathy lesions or enhanced arteriolar light reflex.			Hypertension, diabetes and smoking.
Bournoville, 2018 ⁵²	62.6 (median)	33/23	Site: middle cerebral artery (superficial and deep). Pre-stroke WMLs.		No difference was found in CT between cognitively impaired and healthy groups	Functional change was not associated with GM atrophy in patients with CI compared to those without it	
Brodtmann, 2020 ³⁶	67.9 ± 12.3	63/22 (at baseline) 84/39 (at 3 months post-stroke) 77/34 (at 12 months post-stroke)	The majority were right-sided at all three time points The majority were subcortical at all three time points Most strokes were partial anterior (Oxfordshire scale)	Rates of atrophy in stroke were not significantly different from those in controls. Ipsilesional hemispheric, hippocampal and thalamic atrophy rates were 2 to 4 times greater in the first 3 months after stroke. Hippocampal, thalamic, total brain and hemispheric brain volumes were greater in stroke patients.	Contralateral CT in stroke were not significantly different from those in controls.		High vascular risk profile for stroke patients at all 3 time points.

Table 1. [Continued]

	Age in years ±SD	Sex M/F	Stroke related	Structural/Volume changes	Cortical thickness	Functional changes/ outcomes	Comorbidities
Brodman, 2012 ¹¹	65.1 (Cases) 67.2 (Controls)	9/3 (Cases) 5/5 (Controls)	Site: Cortical: 10; Sub- cortical: 2	Significant reductions in thalamic volume noted.	Post-stroke changes in re- gional CT are evident even over shorter time periods. Increased contralateral CT was noted (probably compensatory mechanism).	Severe GMV atrophy in the ipsilesional PreCG was related to poor clinical recovery, while greater GMV increases in the contralateral OFG and MFG were related to bet- ter clinical recovery.	
Cai, 2016 ¹⁸	48.9	All males	Site: Single is- chemic stroke le- sion involving basal ganglia regions.	Compared with the acute stage, significant decreases in GMV were observed in the ipsilesional PreCG, ParaCG and contralateral cerebellar lobule VII in the chronic stage. Additionally, signifi- cant increases in GMV were found in the contralateral OFC, MFG and IFG.			
Chen, 2013 ⁴⁰	Females: 73.3±7.2 Males: 72.1±6.9	30/30	Site: Frontal, pari- etal, temporal and occipital lobes, and subcortical WM, thalamus, basal ganglia and in- fratentorial regions.	Female patients had sig- nificantly larger volumes of right OFC and right anterior cingulate cortex.		In female patients, at 3 and 15 months post-stroke, left dorsolateral prefrontal cortex volume significantly correlated with Verbal Fluency Test score.	Hypertension and diabetes mellitus.
Chen, 2019 ³³	60±6	21/10	Stroke sided- ness: R/L: 16/15	T1 patients showed signifi- cantly higher functional con- nectivity with non-atrophic area of S1. Patients showed reduction in cortical volume in the ipsile- sional top part of the top S1 region and ipsilesional lateral bottom S1.			
Cheng, 2015 ¹²	68	7/5	Stroke sided- ness: R/L: 5/7 Site: basal ganglia; internal capsule; corona radiata		Three months post-stroke, a significant drop in CT was detected in areas linked with ischemic le- sions, while CT in uncon- nected cortical areas was largely unchanged. An area of significant cor- tical thinning was noted in the superior frontal gyrus of the stroke hemisphere.	No significant correlations found between the degree of motor recovery and change in CT.	

Table 1. [Continued]

	Age in years ± SD	Sex M/F	Stroke related	Structural/ Volume changes	Cortical thickness	Functional changes/ outcomes	Comorbidities
Cheng, 2020 ¹⁹	68	13/5	Stroke lesions were located in the left hemisphere in 11 patients (61%)		One year after stroke, a significant decrease in CT was noted in areas connected to ischemic lesions as well as homologous contralateral brain regions.	No significant associations with clinical recovery.	
Dickie, 2020 ⁴¹	65.5±12.3	161/83			Higher WMHs were associated with a thinner cortex. Statistically significant negative associations between CT and WMHs across frontotemporal and inferior parietal cortical regions were noted.		Hypertension, hypercholesterolemia, atrial fibrillation and diabetes.
Duering, 2012 ³⁸	50.4	2/7	Stroke sidedness: R/L: 3/5 (one midline). Site: corpus callosum, internal capsule and centrum semiovale.		A strong correlation was found between mean focal cortical thinning and the probability of connectivity with the infarcted region.		
Duering, 2015 ¹³	70.9	23/9			Focal CT specifically in areas connected to acute strokes (CT was more prominent in regions showing a high probability of connectivity to infarct areas). Also noted was microstructural damage in WM tracts connecting acute strokes with distant cortex significantly correlated with CT changes in that region.		Hypertension, hypercholesterolemia, diabetes and smoking

Table 1. [Continued]

	Age in years ± SD	Sex M/F	Stroke related	Structural/Volume changes	Cortical thickness	Functional changes/ outcomes	Comorbidities
Fan, 2013 ²⁰	48.7	9/1	Left hemisphere subcortical infarctions involving motor pathways. All patients were first-onset stroke patients who showed motor deficits in both the upper and lower extremities.	Post-stroke, GMV decreased bilaterally in brain areas directly/indirectly linked with lesions.		GMVs of these brain areas did not correlate with MI. GMV was increased in several brain areas associated with motor/cognitive functions post-stroke, however after adjusting for time intervals, only GMVs in cognitive-related brain areas remained positively correlated with MI.	Hypertension and diabetes.
Ferris, 2018 ³⁴	67±8.9	19/5	Chronic stroke (> 6 months post-stroke) with and without diabetes (diabetic and non-diabetic). Stroke sidedness: R/L: 12/12 Site: internal capsule, corona radiata, internal capsule and striatum, MCA thalamus, putamen		Compared to stroke alone, individuals with stroke and diabetes had lower CT bilaterally in the primary somatosensory cortex, and primary and secondary motor cortices.	Contralateral primary and secondary motor cortex thicknesses were negatively related to sensorimotor outcomes in the paretic upper limb in the stroke and diabetes group, such that those with thinner primary and secondary motor cortices had better motor function.	
Gran-Olivares, 2010 ³⁹	71.7±12 (MCI-V) 65.1±11.3 (NCL-V)	7/8 (MCI-V) 11/4 (NCL-V)	Lacunar strokes in the internal capsule, thalamus, basal ganglia, corona radiata, pons or centrum ovale.	MCI-V patients showed regional GMV losses between the first and second evaluation in cortical (frontal and temporal) and subcortical (pons, cerebellum and caudate) areas.		Frontal lobe dysfunction and regional cortical/subcortical GM atrophy best differentiates the clinical course of lacunar stroke in patients with/without CI.	

Table 1. [Continued]

	Age in years ± SD	Sex M/F	Stroke related	Structural/ Volume changes	Cortical thickness	Functional changes/ outcomes	Comorbidities
Krause, 2016 ²¹	65.3±10.2 (CPSP) 63.45± 9.11 (non-pain stroke) 63.8±13 (healthy controls)	13/10 (CPSP) 13/9 (non-CP-SP)	Chronic subcortical sensory stroke with and without central post-stroke pain (CPSP)	CPSP patients exhibited decreased GMV in secondary somatosensory cortex (S2), anterior and posterior insular cortex, ventrolateral prefrontal and orbitofrontal cortex, temporal cortex and nucleus accumbens compared to healthy controls. Comparing CPSP to non-pain patients revealed a similar (yet restricted) pattern of atrophy in the S2, ventrolateral prefrontal and temporal cortex.		GMV of the ventromedial prefrontal cortex correlated negatively with pain intensity ratings.	
Kuceyeski, 2014 ²²	74.6±14.1	9/17		ChaCo scores were generally higher in areas near stroke lesions. ChaCo scores were found to be highest in: postcentral/precentral gyri, insula, middle cingulate, thalami, putamen, caudate nuclei and pallidum.		ChaCo scores identified the most affected regions to be those related with sensorimotor, perception, learning and memory functions.	
Lotan, 2019 ²⁶	61	15/5		Loss of microstructural integrity of the affected corticospinal tract noted with increased mean diffusivity and decreased fractional anisotropy compared to the contralateral nonaffected tract.	Focal decrease in CT was noted in the connected, affected M1 cortex compared to the nonaffected M1 (only in its deepest laminar class).	Clinical scores were correlated with microstructural damage of corticospinal tracts and with CT (only to its deepest laminar class).	Hypertension, hypercholesterolemia, diabetes mellitus and smoking.
Mihalov, 2016 ³⁵	67-72± 11.64	30/17		Frontal cortical atrophy.			Frontal cortical atrophy and depression symptoms strongly correlated with symptoms of post-stroke apathy.

Table 1. [Continued]

	Age in years ± SD	Sex M/F	Stroke related	Structural/Volume changes	Cortical thickness	Functional changes/ outcomes	Comorbidities
Pohjas- vaara, 1999 ²⁸	70.2±7.7	169/168	Pre-stroke cog- nitive study	Moderate/severe WM changes and cerebral atrophy were found: Mean Fazekas WM score of pre-stroke patients with cognitive decline was sig- nificantly higher compared to those without pre-stroke cognitive decline. Moderate/severe cor- tical frontal, entorhinal, hippocampal and medial temporal atrophy were more common in patients without pre-stroke cognitive decline. Moderate/severe central temporal, frontal, lateral and occipital atrophy were significantly more common among pre-stroke patients with cognitive decline than patients without it.		3-month outcome was worse in pre-stroke patients with cognitive decline compared to those without (measured by all ADL scales and cognitive scales). The number of patients who developed dementia 3 months after stroke was significantly higher in pre-stroke pa- tients with cognitive de- cline than in those without.	Hypertension, diabetes, cardiac failure, atrial fibrillation, history of my- ocardial infarction, hyper- cholesterolemia, smoking and history of previous CVD (TIA, ischemic and hemorrhagic strokes).
Wei, 2020 ²³	59±9 (pontine stroke [PS] cases); 57±8 (normal con- trols)	4/7 (PS cases); 8/12 (normal controls)	Stroke sided- ness: R/L: 3/8	With the progression of stroke, GMV decreased significantly in the bilateral cerebellar posterior lobe (ipsilateral Crus II and con- tralateral Crus I), initially de- tected in the first month. It continued to decrease during the following 6 months. Further analysis revealed that brain regions in the PS group, mainly areas in the bilateral prefrontal, parietal, temporal lobes and paralim- bic system and cerebellum, were mutually positively and negatively correlated.		Changes of GMV in these regions were correlated with behavioral scores related to motor and cog- nitive functions.	

Table 1. [Continued]

	Age in years ± SD	Sex M/F	Stroke related	Structural/ Volume changes	Cortical thickness	Functional changes/ outcomes	Comorbidities
Xiong, 2014 ⁴²	75.2±7.6	52/48	Site: Frontal lobe, parieto-occipital lobe, temporal lobe, infratentorium, basal ganglia (striatum, globus pallidus, thalamus, internal/external capsule, insula) and thalamus of each hemisphere.	Old age, low triglyceride, periventricular WM changes and presence of thalamic microbleeds were independently predictive of less cortical GMV ratio.			Prior stroke, hypertension, hyperlipidemia, diabetes mellitus, atrial fibrillation and smoking
Yu, 2017 ²⁴	58.8 ± 14.7	7/5	First-ever stroke; single infarct in middle cerebral artery-perfused zone.	Decreased GMV was found in postcentral gyrus, precentral gyrus, precuneus, angular gyrus, insula, thalamus and cerebellum. Raised GMV was found in the hippocampus, orbital gyrus and lingual gyrus at the follow-up examination. Increased cerebral blood flow was found in the subcallosal cingulate gyrus, hippocampus and lingual gyrus at follow-up.		Only decreased GMV in the cerebellar anterior lobe was negatively associated with an improvement of the Barthel index.	Hypertension, hyperlipidemia and diabetes mellitus.
Pundik, 2018 ⁴³	54.8 ± 11.7	Male: 15 Female: 5	Cortical and subcortical only: 8 This was an interventional study in which 20 chronic stroke patients were treated for 12 weeks with rehabilitation measures. Their CT was consequently measured.				Improved sensory perception was found to be associated with increased CT in association sensory cortices.

Abbreviations: R/L=right/left; M/F=male/female; CCI = creatinine clearance; IADL=instrumental activities of daily living; mRS=modified Rankin scale; WMHs = white matter lesions; ADL=activities of daily living; GM = Gray matter; WM = White matter; MCA = Middle Cerebral Artery; CCI = creatinine clearance; WMHs = White matter hyperintensities; GMV = Gray matter volume; PreCG = Precentral gyrus; ParaCG = paracentral gyrus; OFC = orbitofrontal cortex; MFG = middle frontal gyri; IFG = inferior frontal gyri; CT = Cortical thickness; MCI-V = Vascular mild cognitive impairment; CI = Cognitive impairment; CSP = central post-stroke pain; ChaCo score = Change in Connectivity Score; Ct = Computed tomography; MI = Mortricity Index; BI = Barthel Index

	D1	D2	D3	D4	D5	D6	D7	Overall
Aoi, 2012	+	+	+	+	+	+	+	+
Auriel, 2016	+	+	+	+	+	+	+	+
Baker, 2010	+	+	+	+	+	+	+	+
Bournonville, 2018	+	+	+	+	+	+	+	+
Brodtimann, 2012	-	+	+	+	+	+	+	-
Cai, 2016	-	-	+	+	-	-	-	-
Chen, 2013	-	-	-	-	+	+	+	-
Chen, 2019	-	-	-	+	-	+	+	-
Cheng, 2015	-	-	-	+	-	+	+	-
Cheng, 2020	+	+	+	+	+	+	+	+
Dickie, 2020	-	-	-	-	+	+	+	-
Dueling, 2012	-	-	-	+	-	+	+	-
Dueling, 2015	-	+	+	+	+	+	+	-
Fan, 2013	+	+	+	+	+	+	+	+
Ferris, 2014	+	+	+	+	+	+	+	+
Grau-Olivares, 2010	-	+	-	-	+	+	+	-
Jouvent, 2008	+	+	+	+	+	+	+	+
Krause, 2016	-	+	-	+	+	-	+	-
Kuceyeski, 2014	+	+	+	+	+	+	+	+
Liu, 2015	+	+	+	+	+	-	-	-
Lotan, 2019	+	+	+	+	+	+	+	+
Mihalov, 2016	+	+	+	+	+	-	+	-
Ozzoude, 2020	-	+	+	+	+	+	+	-
Pohjasvaara, 1999	-	+	-	+	+	+	+	-
Sagnier, 2019	-	+	+	+	+	+	+	-
Smith, 2012	⊗	⊗	⊗	⊗	⊗	+	+	⊗
Veldsman, 2017	⊗	⊗	⊗	⊗	⊗	+	+	⊗
Wang, 2016	+	+	+	+	+	+	+	+
Wei, 2020	-	+	-	+	+	+	+	-
Xiong, 2014	+	+	+	+	+	+	+	+
Yu, 2017	-	+	+	+	+	+	+	-
Zi, 2014	+	+	+	+	+	+	+	+

Domains: D1 : Bias due to confounding.
 D2: Bias due to selection of participants.
 D3: Bias in classification of interventions.
 D4: Bias due to deviations from intended interventions.
 D5: Bias due to missing data.
 D6: Bias in measurement of outcomes.
 D7: Bias in selection of the reported result.

Judgement:
 ⊗ Serious
 - Moderate
 + Low

Figure 2. Risk of bias domains

Table 2. Regions assessed and Assessment Scale

Regions assessed	Assessment scales
Sensory	NIHSS, MDRS, MOCA and MMSE
Motor	NIHSS, MI, BI, MRS and FMAS.
Cognition	MoCA, RAVLT, MMSE, GDS, MDRS, HADS

Abbreviations: NIHSS = National Institute of Health Stroke Scale; MI = Motricity Index; BI = Barthel Index; MRS = Modified Rankin scale; MDRS = Modified Dementia Rating Scale; MoCA = Montreal Cognitive Assessment scale; MMSE = Mini-Mental State Examination; FMA = Fugl-Meyer Assessment scale; GDS = geriatric depression scale; HADS = Hospital Anxiety and Depression Scale

lobes were found to be linked with behavioural scores related to motor/cognitive functions.

Left dorsolateral prefrontal cortex volume was associated with Verbal Fluency Test scores in elderly post-stroke females (at two time points: 3 months and 15 months). Frontal lobe dysfunction and regional cortical/subcortical GM atrophy best differentiated the clinical course of lacunar stroke in patients with/without cognitive impairment (CI).

Contralesional primary and secondary motor cortex thickness was negatively related to sensorimotor outcomes in the paretic upper limb in the stroke and diabetes group. Interestingly, this meant that patients with thinner primary and secondary motor cortices had better motor function.

Areas closer to the stroke lesion, which have a higher degree of disconnection than regions further away, were found to exhibit greater atrophy. The Change in Connectivity (ChaCo) score identified the most affected regions related to sensorimotor, perception, learning and memory functions. Also, an improved regulation of cerebral blood flow was associated with a lower risk of atrophy and better functional outcomes in the long term.

Risk of bias

The majority of included studies showed a low to moderate risk of bias. Only two studies had a serious risk of bias. Details are shown in Figures 2 and 3.

Discussion

This review examines cerebral cortical changes and functional outcomes in ischemic stroke, highlighting the complexity and variability of cerebral atrophy. The most common atrophy sites are the temporal lobe, thalamic areas, hippocampus, cerebellum and sensory cortex, with cortical thinning in the frontotemporal and motor regions. Atrophy affects both WM and GM, with GMV loss linked to poorer motor outcomes. The temporal lobe, crucial for autonomic functions⁴⁴ shows significant atrophy, impacting stroke recovery⁴⁵⁻⁴⁷.

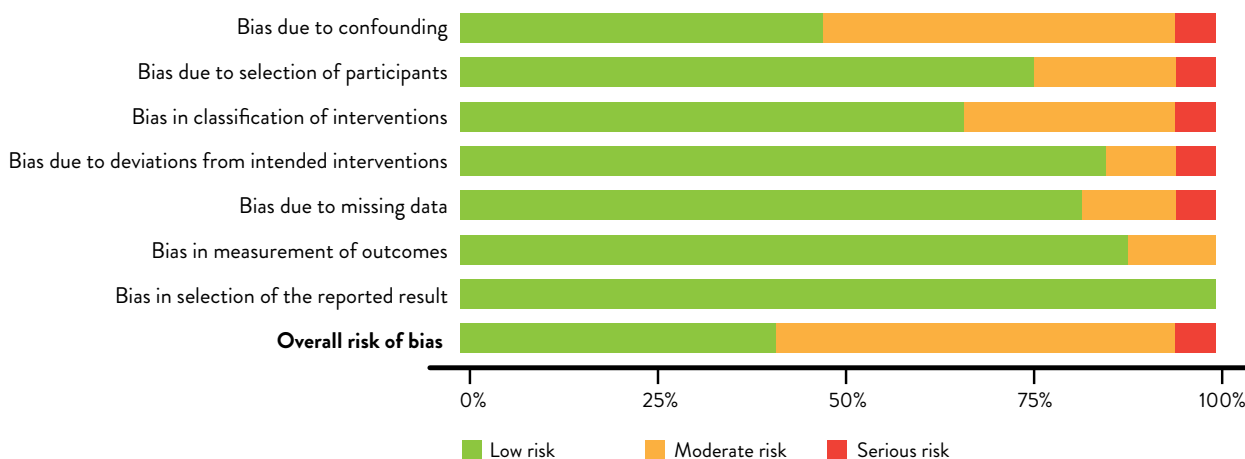


Figure 3. Overall Risk of Bias

There is a key issue concerning the anatomical presentation of cerebral atrophy and how to diagnose it on imaging techniques. While changes in the volume of cortical areas are reasonably easy to locate and measure, they do not elucidate other changes on the cortical tissue surface. An interesting solution for this is to use a voxel-based morphometry (VBM)-based method and scan the whole brain to see post-stroke GMV changes, since GMV reflects cortical thickness and surface area¹⁸. Fan *et al.* reported a post-stroke decrease in GMV bilaterally in brain areas directly or indirectly linked with stroke infarcts, suggesting regional damage in these “healthy” brain tissues of stroke patients. In addition, the GMV of several areas linked to motor and cognitive functions was found to be increased post-stroke²⁰.

It should be noted that generalized cortical thinning occurs with normal ageing. However, it is important to differentiate it from stroke-induced changes, specifically in their location and pattern. One way to differentiate between the two is that stroke-induced cortical thinning occurs because of focal cortical thinning in areas that have anatomical connections with the infarcted brain areas with ischemic changes¹². The process of retrograde degeneration after an axonal injury can explain how stroke in one place may lead to distal atrophy. Cortical infarcts affecting the motor cortex and/or descending pathways have been postulated to trigger Wallerian degeneration of WM tracts, spanning over many weeks⁴⁸.

Furthermore, MRI evidence suggests that the deepest cortical layers of M1 may exhibit most of this atrophy⁴⁹. On a similar note, microstructural damage to WM tracts has also been reported in areas of cortical thinning duly connected to areas of the stroke lesion⁵⁰. One of the reasons for this damage (especially microvascular damage) may be because the brain, being a low-impedance organ, receives high volumes of blood⁵¹, which makes it prone to this type of damage. Lastly, the extent of microstructural damage in the connecting WM tracts has been found to determine the extent of cortical thinning⁵².

Our study on cerebral atrophy and its association with long-term disability revealed several significant findings related to functional outcomes in stroke patients. Specifically, we found that elderly post-stroke females showed an association between prefrontal

cortex volume and verbal fluency. Additionally, lacunar stroke patients, both with and without cognitive impairment, were affected by regional cortical/subcortical GM atrophy, which influenced their clinical course. Moreover, individuals in stroke and diabetes groups exhibited a negative association between contralesional primary and secondary motor cortex thicknesses and sensorimotor outcomes in the paretic upper limb, suggesting that those with thinner motor cortices demonstrated better motor function. Furthermore, our analysis of connectivity scores (ChaCo) indicated that the proximity between infarcted and corresponding secondary atrophic areas played a role in influencing functional outcomes. Lastly, an improved regulation of cerebral blood flow was associated with a reduced risk of atrophy and better long-term functional outcomes.

Pundik *et al.*⁴³ were the first to report changes in bilateral cortical thickness linked to sensory recovery post-rehabilitation in chronic stroke patients. They found significant sensory improvement in the area close to the occipital pole, lateral occipital cortex, intracalcarine cortex, cuneal cortex, precuneus cortex, inferior temporal gyrus, occipital fusiform gyrus, supracalcarine cortex and the temporal occipital fusiform cortex in the ipsilesional hemisphere in response to rehabilitative treatment. Of interest was the increase in CT leading to improved sensory acuity in the contralesional posterior parietal cortex (including supramarginal and angular gyri), reported earlier in animal⁵³ and human stroke settings⁵⁴⁻⁵⁶.

It is known that stroke-induced atrophic changes occur several days or weeks prior to stroke onset. The extended therapeutic time window for these lesions may allow the discovery of treatment modalities targeting this state of secondary neurodegeneration. In addition, the resultant neuroprotection may promote brain plasticity and improve clinical management, leading to better functional outcomes⁵⁷.

The study has several limitations that warrant consideration. Firstly, there is a scarcity of studies reporting dynamic changes in the brain, primarily due to the retrospective or cross-sectional design of most existing studies. Secondly, heterogeneities in lesion location and duration were commonly observed, which posed challenges in drawing general conclusions. Additionally, limited research focused on whole-brain atrophic changes, with even fewer interventional studies

reporting tangible changes in functional outcomes post-stroke. Another limitation is the lack of changes in CT in the contralesional lesion-connected/unconnected cortices in certain studies. These discrepancies may be attributed to factors including shorter follow-up durations, insensitive methods used in the region-of-interest (ROI) analysis and the limitations of CT in capturing other presentations of atrophy, such as cortical surface changes.

Conclusions

In due course, ischemic stroke triggers a cascade of cerebral atrophic changes in the gray and white matter of the brain. Changes in total and regional brain tissue volume start early post-stroke and continue at an accelerated rate, compared to normal age-related atrophic changes. When developed via robust and well-designed research studies, brain atrophy timeline and milestones could prove to be useful parameters for developing prognostic and therapeutic tools. In terms of functional outcomes, with rapidly growing avenues for brain stimulation and brain-machine technologies, identifying potential regions of structural plasticity and, therefore, recovery is likely to prove pivotal in improving stroke rehabilitation protocols.

FUNDING STATEMENT: Nil

COMPETING INTERESTS STATEMENT: None

AUTHORS' CONTRIBUTIONS: F.S., A.K., A.P. were involved in the conceptualization, supervision, investigation, methodology, data curation and writing of the original draft. F.S., A.K., A.P., F.A.B. contributed to the visualization, investigation, methodology, as well as writing review and editing. All authors have read and approved the final manuscript.

References

1. Donkor ES. Stroke in the century: a snapshot of the burden, epidemiology, and quality of life. *Stroke research and treatment* 2018;2018
2. Woitzik J, Back T, Thome C. Flow-dependent versus spreading-like impairment of brain tissue integrity during focal cerebral ischemia and its consequences for neuroprotective strategies. *Front Biosci* 2008;13:1500-06.
3. Whitwell JL, Jack Jr CR, Parisi JE, et al. Rates of cerebral atrophy differ in different degenerative pathologies. *Brain* 2007;130(4):1148-58.
4. Fox NC, Schott JM. Imaging cerebral atrophy: normal ageing to Alzheimer's disease. *The Lancet* 2004;363(9406):392-94.
5. Prins ND, van Dijk EJ, den Heijer T, et al. Cerebral small-vessel disease and decline in information processing speed, executive function and memory. *Brain* 2005;128(9):2034-41.
6. O'Sullivan M, Jouvent E, Saemann PG, et al. Measurement of brain atrophy in subcortical vascular disease: a comparison of different approaches and the impact of ischaemic lesions. *Neuroimage* 2008;43(2):312-20.
7. Mungas D, Jagust W, Reed BR, et al. MRI predictors of cognition in subcortical ischemic vascular disease and Alzheimer's disease. *Neurology* 2001;57(12):2229-35.
8. Longstreth W, Manolio TA, Arnold A, et al. Clinical correlates of white matter findings on cranial magnetic resonance imaging of 3301 elderly people: the Cardiovascular Health Study. *Stroke* 1996;27(8):1274-82.
9. Moody DM, Brown WR, Challa VR, et al. Cerebral Microvascular Alterations in Aging, Leukoaraiosis, and Alzheimer's Disease a. *Annals of the New York Academy of Sciences* 1997;826(1):103-16.
10. Ermine CM, Soma F, Wang T-Y, et al. Long-term motor deficit and diffuse cortical atrophy following focal cortical ischemia in athymic rats. *Frontiers in cellular neuroscience* 2019;13:552.
11. Brodtmann A, Pardoe H, Li Q, et al. Changes in regional brain volume three months after stroke. *J Neurol Sci* 2012;322(1-2):122-8. <https://doi.org/10.1016/j.jns.2012.07.019>
12. Cheng B, Schulz R, Bonstrup M, et al. Structural plasticity of remote cortical brain regions is determined by connectivity to the primary lesion in subcortical stroke. *J Cereb Blood Flow Metab* 2015;35(9):1507-14. <https://doi.org/10.1038/jcbfm.2015.74>
13. Duering M, Righart R, Wollenweber FA, et al. Acute infarcts cause focal thinning in remote cortex via degeneration of connecting fiber tracts. *Neurology* 2015;84(16):1685-92.
14. Yassi N, Malpas CB, Campbell BC, et al. Contralesional thalamic surface atrophy and functional disconnection 3 months after ischemic stroke. *Cerebrovascular diseases* 2015;39(3-4):232-41.
15. Moher D, Liberati A, Tetzlaff J, Altman DG. Preferred reporting items for systematic reviews and meta-analyses: the PRISMA statement. *Int J Surg* 2010;8(5):336-41.

16. Sterne JA, Hernán MA, Reeves BC, et al. ROBINS-I: a tool for assessing risk of bias in non-randomised studies of interventions. *bmj* 2016;355
17. Baker ML, Wang JJ, Liew G, et al. Differential associations of cortical and subcortical cerebral atrophy with retinal vascular signs in patients with acute stroke. *Stroke* 2010;41(10):2143-50. <https://doi.org/10.1161/STROKEAHA.110.594317>
18. Cai J, Ji Q, Xin R, et al. Contralateral cortical structural reorganization contributes to motor recovery after subcortical stroke: a longitudinal voxel-based morphometry study. *Frontiers in human neuroscience* 2016;10:393.
19. Cheng B, Dietzmann P, Schulz R, et al. Cortical atrophy and transcallosal diaschisis following isolated subcortical stroke. *J Cereb Blood Flow Metab* 2020;40(3):611-21. <https://doi.org/10.1177/0271678X19831583>
20. Fan F, Zhu C, Chen H, et al. Dynamic brain structural changes after left hemisphere subcortical stroke. *Hum Brain Mapp* 2013;34(8):1872-81. <https://doi.org/10.1002/hbm.22034>
21. Krause T, Asseyer S, Taskin B, et al. The Cortical Signature of Central Poststroke Pain: Gray Matter Decreases in Somatosensory, Insular, and Prefrontal Cortices. *Cereb Cortex* 2016;26(1):80-88. <https://doi.org/10.1093/cercor/bhu177>
22. Kuceyeski A, Kamel H, Navi BB, et al. Predicting future brain tissue loss from white matter connectivity disruption in ischemic stroke. *Stroke* 2014;45(3):717-22. <https://doi.org/10.1161/STROKEAHA.113.003645>
23. Wei Y, Wang C, Liu J, et al. Progressive Gray Matter Atrophy and Abnormal Structural Covariance Network in Ischemic Pontine Stroke. *Neuroscience* 2020;448:255-65. <https://doi.org/10.1016/j.neuroscience.2020.08.033>
24. Yu X, Yang L, Song R, et al. Changes in structure and perfusion of grey matter tissues during recovery from Ischaemic subcortical stroke: a longitudinal MRI study. *European Journal of Neuroscience* 2017;46(7):2308-14.
25. Li Q, Pardoe H, Lichter R, et al. Cortical thickness estimation in longitudinal stroke studies: A comparison of 3 measurement methods. *NeuroImage: Clinical* 2015;8:526-35. <https://doi.org/10.1016/j.nicl.2014.08.017>
26. Lotan E, Tavor I, Barazany D, et al. Selective atrophy of the connected deepest cortical layers following small subcortical infarct. *Neurology* 2019;92(6):e567-e75. <https://doi.org/10.1212/WNL.0000000000006884>
27. Ozzoude M, Ramirez J, Raamana PR, et al. Cortical Thickness Estimation in Individuals With Cerebral Small Vessel Disease, Focal Atrophy, and Chronic Stroke Lesions. *Front Neurosci* 2020;14:598868. <https://doi.org/10.3389/fnins.2020.598868>
28. Pohjasvaara T, Mäntylä R, Aronen HJ, et al. Clinical and radiological determinants of prestroke cognitive decline in a stroke cohort. *Journal of Neurology, Neurosurgery & Psychiatry* 1999;67(6):742-48.
29. Sagnier S, Okubo G, Catheline G, et al. Chronic Cortical Cerebral Microinfarcts Slow Down Cognitive Recovery After Acute Ischemic Stroke. *Stroke* 2019;50(6):1430-36. <https://doi.org/10.1161/STROKEAHA.118.024672>
30. Wang Z, van Veluw SJ, Wong A, et al. Risk Factors and Cognitive Relevance of Cortical Cerebral Microinfarcts in Patients With Ischemic Stroke or Transient Ischemic Attack. *Stroke* 2016;47(10):2450-5. <https://doi.org/10.1161/STROKEAHA.115.012278>
31. Aoi MC, Hu K, Lo MT, et al. Impaired cerebral autoregulation is associated with brain atrophy and worse functional status in chronic ischemic stroke. *PLoS One* 2012;7(10):e46794. <https://doi.org/10.1371/journal.pone.0046794>
32. Bournonville C, Henon H, Dondaine T, et al. Identification of a specific functional network altered in poststroke cognitive impairment. *Neurology* 2018;90(21):e1879-e88. <https://doi.org/10.1212/WNL.0000000000005553>
33. Chen L, Luo T, Wang K, et al. Effects of thalamic infarction on the structural and functional connectivity of the ipsilesional primary somatosensory cortex. *European radiology* 2019;29(9):4904-13.
34. Ferris JK, Peters S, Brown KE, et al. Type-2 diabetes mellitus reduces cortical thickness and decreases oxidative metabolism in sensorimotor regions after stroke. *J Cereb Blood Flow Metab* 2018;38(5):823-34. <https://doi.org/10.1177/0271678X17703887>
35. Mihalov J, Mikula P, Budis J, Valkovic P. Frontal Cortical Atrophy as a Predictor of Poststroke Apathy. *J Geriatr Psychiatry Neurol* 2016;29(4):171-6. <https://doi.org/10.1177/0891988716641248>
36. Brodtmann A, Khlif MS, Egorova N, et al. Dynamic Regional Brain Atrophy Rates in the First Year After Ischemic Stroke. *Stroke* 2020;51(9):e183-e92. <https://doi.org/10.1161/STROKEAHA.120.030256>
37. Auriel E, Kliper E, Shenhar-Tsarfaty S, et al. Impaired renal function is associated with brain atrophy and poststroke cognitive decline. *Neurology* 2016;86(21):1996-2005.
38. Duering M, Righart R, Csanadi E, et al. Incident subcortical infarcts induce focal thinning in connected cortical regions. *Neurology* 2012;79(20):2025-28.

39. Grau-Olivares M, Arboix A, Junque C, et al. Progressive gray matter atrophy in lacunar patients with vascular mild cognitive impairment. *Cerebrovasc Dis* 2010;30(2):157-66. doi: 10.1159/000316059
40. Chen Y-K, Xiao W-M, Wang D, et al. Atrophy of the left dorsolateral prefrontal cortex is associated with poor performance in verbal fluency in elderly poststroke women. *Neural regeneration research* 2013;8(4):346.
41. Dickie DA, Gardner K, Wagener A, et al. Cortical thickness, white matter hyperintensities, and cognition after stroke. *Int J Stroke* 2020;15(1):46-54. <https://doi.org/10.1177/1747493019851291>
42. Xiong Y, Wong A, Wong K, et al. Predictors for cortical gray matter volume in stroke patients with confluent white matter changes. *J Neurol Sci* 2014;338(1-2):169-73. <https://doi.org/10.1016/j.jns.2013.12.044>
43. Pundik S, Scoco A, Skelly M, et al. Greater cortical thickness is associated with enhanced sensory function after arm rehabilitation in chronic stroke. *Neurorehabilitation and neural repair* 2018;32(6-7):590-601.
44. Central Autonomic Network: Functional Organization and Clinical Correlations. Mayo Clinic Proceedings; 1998. Elsevier Limited.
45. Ogoh S, Brothers RM, Eubank WL, Raven PB. *Autonomic neural control of the cerebral vasculature: acute hypotension Stroke* 2008;39:1979-87.
46. Novak V, Yang AC, Lepicovsky L, et al. Multimodal pressure-flow method to assess dynamics of cerebral autoregulation in stroke and hypertension. *BioMedical Engineering OnLine* 2004;3(1):1-11.
47. Sander D, Winbeck K, Klingelhöfer J, et al. Prognostic relevance of pathological sympathetic activation after acute thromboembolic stroke. *Neurology* 2001;57(5):833-38.
48. Buss A, Pech K, Merkler D, et al. Sequential loss of myelin proteins during Wallerian degeneration in the human spinal cord. *Brain* 2005;128(2):356-64.
49. Lifshits S, Tomer O, Shamir I, et al. Resolution considerations in imaging of the cortical layers. *Neuroimage* 2018;164:112-20.
50. Zhao P, Alsop D, Abduljalil A, et al. Vasoreactivity and peri-infarct hyperintensities in stroke. *Neurology* 2009;72(7):643-49.
51. Lee M, Saver J, Chang K, et al. Ov biagele B. *Low glomerular filtration rate and risk of stroke: meta-analysis BMJ* 2010;341:c4249.
52. Gutiérrez-Ortiz C, Méndez-Guerrero A, Rodrigo-Rey S, et al. Miller Fisher Syndrome and polyneuritis cranialis in COVID-19. *Neurology* 2020;95(5):e601-e05.
53. Takatsuru Y, Fukumoto D, Yoshitomo M, et al. Neuronal circuit remodeling in the contralateral cortical hemisphere during functional recovery from cerebral infarction. *Journal of Neuroscience* 2009;29(32):10081-86.
54. Bannister LC, Crewther SG, Gavrilescu M, Carey LM. Improvement in touch sensation after stroke is associated with resting functional connectivity changes. *Frontiers in neurology* 2015;6:165.
55. Jang SH, Lee MY. Correlation between somatosensory function and cortical activation induced by touch stimulation in patients with intracerebral hemorrhage. *International Journal of Neuroscience* 2013;123(4):248-52.
56. Nelles G, Spiekermann G, Jueptner M, et al. Reorganization of sensory and motor systems in hemiplegic stroke patients: a positron emission tomography study. *Stroke* 1999;30(8):1510-16.
57. Zhang J, Zhang Y, Xing S, et al. Secondary neurodegeneration in remote regions after focal cerebral infarction: a new target for stroke management? *Stroke* 2012;43(6):1700-05.

Sažetak

SUSTAVNI PREGLED CEREBRALNE ATROFIJE KOD ISHEMIJSKOG MOŽDANOG UDARA

Fahad Somaa, Azka Khan, Anna Podlasek i Faraz Ahmed Bokhari

Uvod: Moždani udar, kao neurološko stanje, drugi je vodeći uzrok smrtnosti i onesposobljenosti u svijetu te dovodi do senzornih, motoričkih i kognitivnih oštećenja. Atrofične promjene mozga koje nastaju nakon moždanog udara u različitim regijama, kako ipsilezijskim tako i kontralateralnim, imaju značajne kliničke implikacije. Cilj ovog sustavnog pregleda i meta-analize jest istražiti strukturne (volumen i debljina korteksa) i funkcionalne deficite izazvane cerebralnom atrofijom nakon ishemijskog moždanog udara.

Metode: Pregled je obuhvatio studije provedene od siječnja 2010. do listopada 2021. godine, pri čemu su uključena 33 rada iz baza podataka PubMed/Medline, Cochrane/EMBASE i PEDro. U pretraživanju su korištene ključne riječi poput „stroke“, „cortical atrophy“, „cerebral atrophy“, „motor“, „sensory“ i „cognitive disability“.

Rezultati: Temporalni režanj istaknuo se kao najčešće zahvaćeno područje s atrofičnim promjenama volumena, a slijede područja talamusa, hipokampus, mali mozak i somatosenzorni korteks. Stanjivanje korteksa zabilježeno je u frontotemporalnim regijama, donjem parijetalnom režnju, primarnom motoričkom korteksu (M1) i gornjoj frontalnoj vijugi polutke zahvaćene moždanim udarom. Što se tiče funkcionalnih ishoda, utvrđeno je da je volumen sive tvari (GMV) povezan s motoričkom funkcijom, pri čemu je izražena atrofiya GMV-a otežavala klinički oporavak, dok je povećani GMV bio povezan s boljim ishodima. Nadalje, GMV je bio povezan i s kognitivnim funkcijama. Značajno je da su promjene ukupnog i regionalnog volumena moždanog tkiva uočene rano nakon moždanog udara te su se nastavile ubrzanom tempom u usporedbi s normalnim, dobno uvjetovanim atrofičnim promjenama.

Zaključak: Ovi rezultati naglašavaju potencijal moždane atrofiye kao prognostičkog markera za prepoznavanje regija strukturne plastičnosti te kao terapijske mete.

Ključne riječi: Moždani udar; Kortikalna atrofiya; Cerebralna atrofiya; Motoričko, senzorno i kognitivno oštećenje