

SLUČAJ ANKILOZANTNOG SPONDILITISA NA LOKALITETU ŽUMBERAK – SV. NIKOLA BISKUP

A CASE OF ANKYLOSING SPONDYLITIS AT THE ŽUMBERAK – ST NICHOLAS THE BISHOP SITE

ANITA ADAMIĆ HADŽIĆ

Antropološki centar Hrvatske akademije znanosti i umjetnosti
Anthropological Centre of Croatian Academy of Sciences and Arts
Ante Kovačića 5
HR-10 000 Zagreb
aadamac@hazu.hr

ANAMARIJA UGLEŠIĆ

Antropološki centar Hrvatske akademije znanosti i umjetnosti
Anthropological Centre of Croatian Academy of Sciences and Arts
Ante Kovačića 5
HR-10 000 Zagreb
anamarija.uglesic@hazu.hr

UDK: 902:616.711-002(497.521.3)“654“; 904:726.8(497.521.3)“654“

DOI: 10.15291/archeo.4954

IZVORNI ZNANSTVENI ČLANAK / ORIGINAL SCIENTIFIC PAPER

Primljeno / Received: 2025-7-25

Prihvaćeno / Accepted: 2025-9-15

KLJUČNE RIJEČI:

*ankilozantni spondilitis,
osteološki ostaci, rani
novi vijek, kontinentalna
Hrvatska, Žumberak*

Ankilozantni spondilitis jest progresivna, nezarazna i kronična upalna reumatska bolest kod koje dolazi do kalcifikacije vezivnog tkiva, najčešće na sakroilijačnim zglobovima, zglobovima kralježnice i kostovertebralnim zglobovima. U zadnjim stadijima bolesti kralježnica poprima izgled „bambusova štapa“. Oboljeli se svakodnevno moraju nositi s kroničnom boli, deformacijama i smanjenom pokretljivošću. Kasni stadiji bolesti dovode do respiratorne insuficijencije, gubitka neuroloških funkcija, pa čak i do smrti. Ovo istraživanje bavi se osteološkim ostacima mladog muškarca iz groba 313 s ranonovovjekovno-ga arheološkog lokaliteta Žumberak – sv. Nikola biskup. Na kostima su uočene osteološke promjene konzistentne s promjenama karakterističnima za ankilozantni spondilitis. Prisutnost promjena, kao i stupanj razvijenosti bolesti, upućuju na vrlo brzo i agresivno napredovanje bolesti. Muškarac je imao vrlo izraženu kifozu u predjelu prsne kralježnice te lordozu u vratnoj kralježnici. S obzirom na prisutno sužavanje intervertebralnog prostora između vratnih kralježaka koje dovodi do kompresije leđne moždine, ankilozantni spondilitis najvjerojatniji je uzrok smrti muškarca. Diferencijalnim dijagnozama odbačeno je da je riječ o difuznoj idiopatskoj koštanoj hiperostozi, reaktivnom artritisu, meloreostozi, reumatoidnom artritisu i psorijatičnom artritisu. Ovo je prvi opisani slučaj ankilozantnog spondilitisa iz kontinentalne Hrvatske i iz perioda ranoga novog vijeka.

KEY WORDS:

*ankylosing spondylitis,
osteological remains,
early modern era,
continental Croatia,
Žumberak*

Ankylosing spondylitis is a progressive, non-infectious and chronic inflammatory rheumatic disease characterised by calcification of connective tissue, most commonly in the sacroiliac, vertebral and costovertebral joints. In the late stages of the disease, the spine assumes the so-called bamboo-spine appearance. Sufferers face chronic pain, deformities and reduced mobility on a daily basis. Late stages of the disease lead to respiratory insufficiency, loss of neurological functions and even death. This study deals with the osteological remains of a young man from Grave 313 at the early modern archaeological site of Žumberak – St Nicholas the Bishop. Osteological changes observed on the bones are consistent with those characteristic of ankylosing spondylitis. The presence of these changes and the degree of disease progression indicate a very rapid and aggressive

course. The man had a markedly pronounced kyphosis in the thoracic spine and lordosis in the cervical spine. Given the narrowing of the intervertebral space between the cervical vertebrae, which leads to compression of the spinal cord, ankylosing spondylitis is the most likely cause of death. Differential diagnoses ruled out diffuse idiopathic skeletal hyperostosis, reactive arthritis, melorheostosis, rheumatoid arthritis and psoriatic arthritis. This is the first recorded case of ankylosing spondylitis from continental Croatia during the early modern era.

UVOD

Bolesti su dio ljudske svakodnevice od samih početaka čovječanstva. Neke su odnosile ljudske živote, a neke su znatno otežavale svakodnevno funkcioniranje pojedinca u zajednici. Osobe s težim oblicima bolesti gotovo su u potpunosti ovisile o skrbi i angažiranosti uže i šire zajednice, dok se stav prema oboljelima razlikovao od zajednice do zajednice – ili su smatrani punopravnim članovima zajednice ili su bili izdvajani, što je nakon smrti oboljelog dovodilo i do njegova ukapanja na izdvojenom dijelu groblja.¹

Ankilozantni spondilitis (AS) (bolest Marie-Strumpell ili Bechterewljeva bolest), upravo je takva bolest, koja u svojim završnim stadijima dovodi do teškog invaliditeta i potpune ovisnosti o pomoći zajednice. To je progresivna, nezarazna i kronična upalna reumatska bolest čija je etiologija još uvijek nepoznata,² međutim, smatra se da je posljedica međudjelovanja okolišnih i genskih čimbenika. Prema istraživanjima, čak 90 % rizika za razvoj bolesti genski je uvjetovano.³ Poznato je i da antigeni poput HLA-B60, IL-23R, KIF21B i ERAP1 imaju važnu ulogu kod pojave bolesti, ali nijedan u toj mjeri kao HLA-B27.⁴

Od ankilozantnog spondilitisa znatno više obolijevaju muškarci nego žene. U istraživanjima omjeri između muškaraca i žena kreću se čak od 5 : 1⁵ pa sve do 9 : 1⁶.

Prvi simptomi bolesti javljaju se vrlo rano, u dobi od 20 do 40 godina, međutim, nije ne-

INTRODUCTION

Diseases have been part of everyday life since the very beginnings of humankind, some claiming human lives and others significantly hindering individuals' everyday functioning within the community. Historically, people suffering from more severe forms of disease were almost entirely dependent on the care and involvement of both their immediate and wider community, while attitudes towards the sick varied from one community to another – they were either regarded as full members of the community or set apart, which, after their death, also resulted in their burial in a separate part of the cemetery.¹

Ankylosing spondylitis (AS) (Marie-Strümpell disease or Bechterew's disease) is an illness which, in its final stages, leads to severe disability and complete dependence on the support of the community. It is a progressive, non-infectious and chronic inflammatory rheumatic disease whose aetiology is still unknown²; however, it is considered to result from the interaction of environmental and genetic factors. According to research, as much as 90% of the risk of developing the disease is genetically determined.³ It is also known that antigens such as HLA-B60, IL-23R, KIF21B and ERAP1 play an important role in the onset of the disease, although none to the same extent as HLA-B27.⁴

Significantly more men suffer from ankylosing spondylitis, in comparison to women. Studies report male-to-female ratios ranging from 5:1⁵ to as high as 9:1.⁶

¹ FEDORINA *et al.* 2022: 31; BONCZAROWSKA *et al.* 2025.

² KHUDAVERDYAN *et al.* 2021: 86.

³ ŠLAUS, NOVAK, ČAVKA 2012: 3989; BROWN 2008: 132–137.

⁴ DUYAR 2019: 1100–1101; BETTENCOURT *et al.* 2015: 103–134; VAN DER LINDEN, VAN DER HEIJDE 1998: 663–676; TSAI 2012: 73–84.

⁵ RESNICK, NIWAYAMA 1988.

⁶ ŠLAUS, NOVAK, ČAVKA 2012: 3985–3986; ORTNER, PUTSCHAR 1981; AUFDERHEIDE, RODRÍGUEZ-MARTÍN 1998.

¹ FEDORINA *et al.* 2022: 31; BONCZAROWSKA *et al.* 2025.

² KHUDAVERDYAN *et al.* 2021: 86.

³ ŠLAUS, NOVAK, ČAVKA 2012: 3989; BROWN 2008: 132–137.

⁴ DUYAR 2019: 1100–1101; BETTENCOURT *et al.* 2015: 103–134; VAN DER LINDEN, VAN DER HEIJDE 1998: 663–676; TSAI 2012: 73–84.

⁵ RESNICK, NIWAYAMA 1988.

⁶ ŠLAUS, NOVAK, ČAVKA 2012: 3985–3986; ORTNER, PUTSCHAR 1981; AUFDERHEIDE, RODRÍGUEZ-MARTÍN 1998.

obično ni da se jave još ranije ili pak kasnije.⁷ Istraživanja su pokazala da se početak bolesti u 15 % pacijenata javlja prije 16. godine (u zemljama u razvoju taj je postotak znatno veći pa doseže 40 % i više).⁸ Bolest dovodi do kalcifikacije vezivnog tkiva, najčešće na sakroilijačnom zglobu, zglobovima kralježnice i kostovertebralnim zglobovima.⁹ Iako se brzina i obrazac razvoja ankiloze kralježnice razlikuje od osobe do osobe, tipična deformacija kralježnice razvije se nakon približno deset godina od pojave prvih simptoma.¹⁰ Ako bolest zahvati udove, tada je najčešće vidimo na zglobovima zdjelice i ramena. Također, može zahvatiti temporomandibularne zglobove i zglobove koljena, pri čemu je zahvaćenost često asimetrična.¹¹ Najčešće započinje na sakroilijačnim zglobovima i slabinskim kralješcima, a potom napreduje prema prsnim kralješcima i pripadajućim kostovertebralnim zglobovima. U kasnijim stadijima bolest zahvaća čak i vratnu kralježnicu.¹² U završnoj se fazi tijela kralježaka remodeliraju i gube svoj normalni izgled, tako da zajedno s asociranim sindezmoftima¹³ tvore kontinuiranu glatku površinu koja izgledom podsjeća na bambusov štap (engl. *bamboo spine*)¹⁴.

Klinička slika pacijenata oboljelih od AS-a uključuje kroničnu bol u leđima, umor te ukočenost najčešće u području zdjelice i donjih leđa.¹⁵ Od prvih simptoma javljaju se još i bol u peti i akutni uveitis.¹⁶ Zbog erozija i ankiloza uslijed upale dolazi do ograničene pokretljivosti u području kralježnice. Bolest je često praćena otečenim i bolnim zglobovima koji su

The first symptoms of the disease appear very early, between the ages of 20 and 40 – although it is not unusual for them to occur even earlier or later.⁷ Studies have shown that in 15 % of patients the onset of the disease occurs before the age of 16 (in developing countries this percentage is much higher, reaching 40 % or more).⁸ The disease leads to calcification of connective tissue, most commonly in the sacroiliac joint, the joints of the spine and the costovertebral joints.⁹ Although the speed and pattern of spinal ankylosis development vary from person to person, the typical spinal deformity develops approximately ten years after the appearance of the first symptoms.¹⁰ If the disease affects the limbs, it is most commonly seen in the joints of the pelvis and shoulder. It can also affect the temporomandibular joints and the knee joints, the involvement often being asymmetrical.¹¹ It most commonly begins in the sacroiliac joints and the lumbar vertebrae, and then progresses towards the thoracic vertebrae and the associated costovertebral joints. In later stages, the disease even affects the cervical spine.¹² In the final stage, the vertebral bodies are remodelled and lose their normal appearance, so that together with the associated syndesmophytes¹³ they form a continuous smooth surface resembling a bamboo rod.¹⁴

The clinical presentation of patients with AS includes chronic back pain, fatigue and stiffness, most often in the pelvic region and lower back.¹⁵ Among the earliest symptoms are heel pain and acute uveitis.¹⁶ Due to erosions and ankylosis resulting from inflammation, mobility in the spinal region becomes restricted. The disease is

⁷ KHAN 1998: 1-10; WOLF 2012: 15-26.

⁸ ELYAN, KHAN 2006: 12-14.

⁹ AUFDERHEIDE, RODRÍGUEZ-MARTÍN 1998; ORTNER 2003; ROBERTS, MANCHESTER 2005.

¹⁰ VAN DER LINDEN, VAN DER HEIJDE, BRAUN 2005: 1125-1141; KHAN 2003: 1161-1181.

¹¹ SIEPER *et al.* 2002; OLIVIERI *et al.* 1998: 3-6; BENNET *et al.* 2004: 121-134.

¹² ORTNER 2003.

¹³ Sindezmofti su vertikalne koštane izrasline na rubovima zglobova.

¹⁴ KHAN 1998: 1-10.

¹⁵ SIEPER, PODDUBNYI 2017: 73-84.

¹⁶ ELYAN, KHAN 2006: 12-13; KHAN 2002.

⁷ KHAN 1998: 1-10; WOLF 2012: 15-26.

⁸ ELYAN, KHAN 2006: 12-14.

⁹ AUFDERHEIDE, RODRÍGUEZ-MARTÍN 1998; ORTNER 2003; ROBERTS, MANCHESTER 2005.

¹⁰ VAN DER LINDEN, VAN DER HEIJDE, BRAUN 2005: 1125-1141; KHAN 2003: 1161-1181.

¹¹ SIEPER *et al.* 2002; OLIVIERI *et al.* 1998: 3-6; BENNET *et al.* 2004: 121-134.

¹² ORTNER 2003.

¹³ Syndesmophytes are vertical bony outgrowths along the margins of the joints.

¹⁴ KHAN 1998: 1-10.

¹⁵ SIEPER, PODDUBNYI 2017: 73-84.

¹⁶ ELYAN, KHAN 2006: 12-13; KHAN 2002.

posljedica artritisa i entezitisa¹⁷ te burzitisom i tendinitisom rotatorne manšete¹⁸. U kasnijim stadijima bolesti ponekad se javlja i ankiloza u akromioklavikularnom i glenohumeralnom zglobovima.¹⁹ Kako to često bude s ovakvim sustavnim tipom bolesti, kod oboljelih se često razvijaju i spondiloartritis te crijevne infekcije poput Crohnove bolesti.²⁰ Također, ljudi koji boluju od AS-a imaju povećani rizik od bolesti koronarnih arterija.²¹ Pacijenti se susreću i s osteoporozom kralježnice, koja povećava rizik od kompresijskih fraktura na kralješcima, kao i od pseudoartroza.²²

S napredovanjem bolesti oboljeli se, dakle, mora nositi s kroničnom boli, deformacijama i smanjenom pokretljivošću, što u konačnici dovodi do velikih promjena u svakodnevnom funkcioniranju, gdje se osoba sve više mora oslanjati na druge ljude. U prošlosti, kada nije postojala medicinska skrb kao danas, posljedice za oboljeloga bile su još znatno teže. Nosili su se i s respiratornom insuficijencijom te gubitkom neuroloških funkcija, a smrtni ishod, nažalost, nije bio nepoznanica.²³

Danas nema lijeka za ovu bolest, međutim, pacijentima se daje određena terapija koja usporava tijek bolesti i smanjuje simptome.

Ovo istraživanje prikazat će vjerojatni slučaj ankilozantnog spondilitisa na kosturu muškarca iz groba 313 s kontinentalnoga ranonovovjekovnog lokaliteta Žumberak – sv. Nikola biskup.²⁴

often accompanied by swollen and painful joints caused by arthritis and enthesitis,¹⁷ as well as by bursitis and rotator cuff tendinitis.¹⁸ In later stages of the disease, ankylosis may also occur in the acromioclavicular and glenohumeral joints.¹⁹ As is often the case with systemic conditions of this type, patients frequently develop spondyloarthritis and intestinal disorders such as Crohn's disease.²⁰ People with AS also have an increased risk of coronary artery disease.²¹ Patients additionally experience spinal osteoporosis, which increases the risk of compression fractures in the vertebrae as well as of pseudoarthroses.²²

As the disease progresses, affected individuals must cope with chronic pain, deformities and reduced mobility, which ultimately leads to major changes in everyday functioning, with sufferers becoming increasingly dependent on others. In the past, when medical care was not as available as it is today, the consequences for affected individuals were even more severe. They also faced respiratory insufficiency and loss of neurological functions, and a fatal outcome, unfortunately, was not uncommon.²³

There is no cure for this disease today; however, patients receive certain therapies that slow its progression and reduce symptoms.

This study presents a probable case of ankylosing spondylitis in the skeleton of a man from Grave 313 at the continental early modern site of Žumberak – St Nicholas the Bishop.²⁴

¹⁷ SOKER *et al.* 2014: 99–104; SOKER *et al.* 2016: 419–424.

¹⁸ SOKER *et al.* 2016: 419–424.

¹⁹ *Ibid.*

²⁰ DE KEYSER *et al.* 2002: 525–532; RASHID, WILSON, EBRINGER 2013: 1–4.

²¹ DIVECHA *et al.* 2005: 171–176.

²² KHAN 2002.

²³ WOLF 2012: 15–26; ŠLAUS 2006; DUYAR 2019: 1101–1105.

²⁴ Unatoč tome što je bolest rijetka (1 : 1000), o ankilozantnom spondilitisu u arheološkom kontekstu pisali su brojni autori diljem svijeta: BASS, GREGG, PROVOST 1974; PÁLFI *et al.* 1996; BOURKE 1971; FELDTKELLER, LEMMEL, RUSSEL 2002; ORTNER 2003; KRAMAR 1981; LAZA, HERVELLA, DE-LA-RUA 2016; LEDEN *et al.* 2009; LUNARDINI *et al.* 2008; SARIGU, FLORIS, FLORIS 2012. U Hrvatskoj su o toj temi dosad pisali samo ŠLAUS, NOVAK, ČAVKA 2012, pri čemu su predstavili četiri slučaja iz srednjovjekovne primorske Hrvatske.

¹⁷ SOKER *et al.* 2014: 99–104; SOKER *et al.* 2016: 419–424.

¹⁸ SOKER *et al.* 2016: 419–424.

¹⁹ *Ibid.*

²⁰ DE KEYSER *et al.* 2002: 525–532; RASHID, WILSON, EBRINGER 2013: 1–4.

²¹ DIVECHA *et al.* 2005: 171–176.

²² KHAN 2002.

²³ WOLF 2012: 15–26; ŠLAUS 2006; DUYAR 2019: 1101–1105.

²⁴ Despite the rarity of the disease (1:1000), numerous authors worldwide have written about ankylosing spondylitis in an archaeological context: BASS, GREGG, PROVOST 1974; PÁLFI *et al.* 1996; BOURKE 1971; FELDTKELLER, LEMMEL, RUSSEL 2002; ORTNER 2003; KRAMAR 1981; LAZA, HERVELLA, DE-LA-RUA 2016; LEDEN *et al.* 2009; LUNARDINI *et al.* 2008; SARIGU, FLORIS, FLORIS 2012. In Croatia, the topic has so far been addressed only by ŠLAUS, NOVAK, ČAVKA 2012, who presented four cases from medieval coastal Croatia.

MATERIJALI I METODE

Selo Žumberak nalazi se u sjeverozapadnoj Hrvatskoj, na graničnom području prema Sloveniji. Tijekom srednjeg vijeka područje Žumberka bilo je u vlasništvu različitih crkvenih i svjetovnih gospodara. Znatne promjene u sastavu stanovništva događaju se u vrijeme pojačane osmanske prijetnje, kada se na to područje doseljavaju prebjeci iz osmanskih krajeva, u literaturi poznati kao uskoci (Vlasi), koji od tada čine većinu stanovništva.²⁵

Na nadmorskoj visini od 300 m, u Žumberku, smjestila se srednjovjekovna jednobrodna crkva sv. Nikole biskupa s tragovima gotike i baroknim inventarom.²⁶ Smatra se da je izgrađena u drugoj polovici 13. stoljeća te da je bila župna crkva žumberačkih knezova iz obitelji Spanheim.²⁷ Sredinom 17. stoljeća obnovljena je u baroknom stilu, a današnji izgled dobila je 1894.²⁸

Godine 2004. započela je obnova crkve, a arheološka istraživanja traju od 2006. Istraživanja su obuhvatila unutrašnjost crkve, kriptu, kosturnicu i groblje oko crkve.²⁹

Pretpostavlja se da je groblje oko crkve sv. Nikole bilo u upotrebi od 14. stoljeća, a ukapanje na tom prostoru vjerojatno je trajalo do kraja 18. stoljeća, kada se groblje premješta na novu lokaciju.³⁰ Uočavaju se dva sloja ukopa – kasnosrednjovjekovni i ranonovovjekovni. Grobovi su bili nepravilno orijentirani, prilagođeni konfiguraciji terena. Svi su ukopi kosturni, a pokojnici su pokapani s različitim položajima ruku.³¹

²⁵ SEKULIĆ 2017: 14–16.

²⁶ AZINOVIĆ BEBEK 2007: 184–185; 2009: 463–468; 2011: 293; 2017: 32–34; AZINOVIĆ BEBEK, JANEŠ 2016: 123–127.

²⁷ SEKULIĆ 2017: 16.

²⁸ AZINOVIĆ BEBEK, JANEŠ 2016: 123; AZINOVIĆ BEBEK 2017: 32.

²⁹ AZINOVIĆ BEBEK 2007: 184–185; 2009: 463–468; 2011: 293–294; 2012: 292; 2013: 333–334; 2014: 251–252; 2015: 272–275; 2017: 32–52; AZINOVIĆ BEBEK, JANEŠ 2016: 127–131.

³⁰ AZINOVIĆ BEBEK 2011: 293–294; 2017: 38.

³¹ AZINOVIĆ BEBEK, JANEŠ 2016: 135; AZINOVIĆ BEBEK 2017: 32.

MATERIALS AND METHODS

The village of Žumberak is located in north-western Croatia, on the border with Slovenia. During the Middle Ages, the Žumberak area was owned by various ecclesiastical and secular lords. Significant changes in the population occurred during the period of increased Ottoman threat, when refugees from Ottoman territories settled in the area. In the literature these newcomers are known as Uskoks (Vlachs), and from that point onward they made up the majority of the population.²⁵

At an elevation of 300 m above sea level stands Žumberak's medieval single-nave Church of St Nicholas the Bishop, featuring traces of Gothic style and Baroque furnishings.²⁶ It is believed to have been built in the second half of the 13th century and to have served as the parish church of the Žumberak princes of the Spanheim family.²⁷ In the mid-17th century it was renovated in the Baroque style, and it acquired its present appearance in 1894.²⁸

The restoration of the church began in 2004, while archaeological investigations have been ongoing since 2006. This research has encompassed the church interior, the crypt, the ossuary and the cemetery surrounding the building.²⁹

It is assumed that the cemetery surrounding the Church of St Nicholas was in use from the 14th century, and that burials in this area probably continued until the late 18th century, when a new cemetery was opened nearby.³⁰ Two burial layers have been identified – a late medieval layer and an early modern layer. The graves were irregularly oriented, adapted to the

²⁵ SEKULIĆ 2017: 14–16.

²⁶ AZINOVIĆ BEBEK 2007: 184–185; 2009: 463–468; 2011: 293; 2017: 32–34; AZINOVIĆ BEBEK, JANEŠ 2016: 123–127.

²⁷ SEKULIĆ 2017: 16.

²⁸ AZINOVIĆ BEBEK, JANEŠ 2016: 123; AZINOVIĆ BEBEK 2017: 32.

²⁹ AZINOVIĆ BEBEK 2007: 184–185; 2009: 463–468; 2011: 293–294; 2012: 292; 2013: 333–334; 2014: 251–252; 2015: 272–275; 2017: 32–52; AZINOVIĆ BEBEK, JANEŠ 2016: 127–131.

³⁰ AZINOVIĆ BEBEK 2011: 293–294; 2017: 38.

Pronađeni su keramički i stakleni nalazi,³² okovi vezica i pojasa, potkove cipela, gumbi, pređice, pojasne kopče, lokot, ključ, kao i različiti nabožni predmeti – medaljice, križevi i krunice.³³

Makroskopska antropološka analiza osteoloških ostataka s groblja oko crkve sv. Nikole biskupa u Žumberku provedena je u laboratoriju Antropološkog centra Hrvatske akademije znanosti i umjetnosti. Tijekom obrade posebno se istaknuo kostur iz groba 313, koji će zbog svoje specifičnosti biti detaljnije predstavljen u nastavku rada. Nalazio se sjeverno od zvonika, uz sjeverni i poprečni zid groblja. Pojedinaac je bio položen u lijes bez grobnih nalaza, a njegova orijentacija bila je sjever – jug, s blagim odklonom prema zapadu, što odgovara orijentaciji crkve. Na temelju stratigrafskih odnosa grob najvjerojatnije pripada razdoblju novog vijeka, iako precizna kronološka atribucija nije moguća bez dodatnih analiza.³⁴ Kostur je odlično očuvan i gotovo cjelovit. Gornja i donja čeljust dobro su očuvane, ali prisutan je postmortalni gubitak gornjega desnog i lijevoga prvog sjekutića. Od koštanih elemenata nedostaju samo prvi vratni kralježak, desna goljenična i desna lisna kost, kao i sitne kosti poput nekih falangi, kostiju pešća, zapešća, nožja i donožja. Stidna kost desne zdjelice kosti također nije sačuvana. Zahvaljujući vrlo dobroj očuvanosti osteoloških ostataka, bilo je moguće odrediti biološki spol i dob u trenutku smrti u užem rasponu.

Spol je određen na temelju morfoloških obilježja zdjelice kosti, ponajprije pubične simfize³⁵ i oblika velikoga sjednog ureza,³⁶ a potom i analizom morfologije lubanje.³⁷ Doživljena dob procijenjena je primjenom više metoda:

configuration of the terrain. All burials were skeletal, and the deceased were interred with their arms in various positions.³¹ Finds include ceramic and glass objects,³² lace and belt fittings, shoe hobnails, buttons, belt rings, belt buckles, a padlock, a key, as well as various devotional items – medallions, crosses and rosaries.³³

The macroscopic anthropological analysis of the osteological remains from the cemetery surrounding the Church of St Nicholas the Bishop in Žumberak was carried out in the laboratory of the Anthropological Centre of the Croatian Academy of Sciences and Arts. During the examination, the skeleton from Grave 313 attracted attention due to its specific features, and it will therefore be presented in more detail in the following section. The grave was located north of the bell tower, along the northern and transverse cemetery wall. The individual had been placed in a coffin without grave goods; the orientation was north–south with a slight deviation towards the west, corresponding to that of the church. On the basis of stratigraphic relationships, the grave most likely belongs to the early modern period, although precise chronological attribution is not possible without additional analyses.³⁴ The skeleton is excellently preserved and almost complete. The maxilla and mandible are well preserved, but there is post-mortem loss of the upper right and left first incisors. The only missing skeletal elements are the first cervical vertebra, the right tibia and the right fibula, as well as small bones such as some phalanges, metacarpals, carpals, metatarsals and tarsals. The pubic bone of the right os coxae is also not preserved. Thanks to the very good state of preservation of the osteological remains, it was possible to determine the biological sex and to narrow the age at death.

Sex was determined on the basis of morphological features of the pelvic bone,³⁵ primarily

³² JANEŠ 2017: 52–62.

³³ AZINOVIĆ BEBEK 2017: 44–51.

³⁴ AZINOVIĆ BEBEK, STINGL: usmeni podaci.

³⁵ PHENICE 1969: 297–301.

³⁶ BUIKSTRA, UBELAKER 1994; KLALES *et al.* 2012: 104–114.

³⁷ WALKER 2008: 39–50.

³¹ AZINOVIĆ BEBEK, JANEŠ 2016: 135; AZINOVIĆ BEBEK 2017: 32.

³² JANEŠ 2017: 52–62.

³³ AZINOVIĆ BEBEK 2017: 44–51.

³⁴ AZINOVIĆ BEBEK, STINGL: personal communication.

³⁵ PHENICE 1969: 297–301.

analizom promjena na aurikularnoj ploštini crijevne kosti,³⁸ čašici zdjelice³⁹ i sternalnom kraju ključne kosti⁴⁰ te stupnja degenerativnih promjena na zglobnim ploštinama dugih kostiju i kralježaka,⁴¹ kao i na temelju obliteracije lubanjskih šavova⁴².

REZULTATI

Nakon provedenih analiza utvrđeno je da je riječ o muškarcu u dobi od 25 do 35 godina. Vidljivo je da su svi prisutni kralješci međusobno spojeni koštanom ankilozom – u većini su slučajeva u potpunosti srasli, a kod manjeg je dijela riječ o ankilozu samo stražnjih ligamenata (sl. 1). Prvi vratni kralježak postmortalno je izgubljen, međutim, vidljivo je da je bio spojen s kondilima zatiljne kosti zbog prisutnih elemenata spajanja vidljivih na kondilima. S drugim vratnim kralješkom nije bio spojen. Drugi vratni kralježak ima prisutnu izraženu osifikaciju apikalnog ligamenta na *dens axis*. Ankilozu kralježnice može se podijeliti u tri koštana bloka. Prvi blok čine kralješci od C2 do T1, a intervertebralni prostor između njih sačuvan je između C3 i C4, C5 i C6 te C7 i T1 (riječ je o prostoru širine od 1 do 3 mm). Kralješci T1 i T2 međusobno su spojeni u predjelu stražnjih ligamenata, uz blago sačuvan intervertebralni prostor. Drugi veliki potpuni koštani blok proteže se od T2 do T10. Kralješci T10 i T11 spojeni su u području stražnjih ligamenata, a njihov intervertebralni prostor sačuvan je s prednje strane. Treći potpuni koštani blok čine kralješci od T11 do L2. Stražnji su ligamenti kralježaka od L2 do L5 srasli, uz blago sačuvan prostor između kralježaka s prednje strane. Kralješci L5 i S1 u potpunosti su spojeni koštanom ankilozom, a zbog postmor-

the pubic symphysis and the shape of the greater sciatic notch,³⁶ followed by an analysis of cranial morphology.³⁷ Age at death was estimated using several methods: by examining changes on the auricular surface of the ilium,³⁸ the acetabulum,³⁹ the sternal end of the clavicle,⁴⁰ the degree of degenerative changes on the articular surfaces of the long bones and vertebrae,⁴¹ as well as on the basis of cranial suture obliteration.⁴²

THE RESULTS

After the analyses were completed, it was established that the individual had been a man aged between 25 and 35 years. All preserved vertebrae are visibly fused to one another by bony ankylosis – in most cases they are completely fused, while in a smaller number the ankylosis involves only the posterior ligaments (Fig. 1). The first cervical vertebra was lost post-mortem; however, it is evident that it had been fused to the occipital condyles, as elements of fusion are visible on them. It was not fused to the second cervical vertebra. The second cervical vertebra exhibits marked ossification of the apical ligament on the *dens axis*. The ankylosed spine can be divided into three ankylosed vertebral blocks. The first block consists of the vertebrae from C2 to T1, and the intervertebral space between them is preserved between C3 and C4, C5 and C6, and C7 and T1 (with a width of 1 to 3 mm). The T1 and T2 vertebrae are fused to each other in the region of the posterior ligaments, with a slightly preserved intervertebral space. The second large complete bony block extends from T2 to T10. The T10 and T11 vertebrae are fused in the region of the posterior ligaments, while their intervertebral space is preserved on the anterior

³⁸ LOVEJOY *et al.* 1985: 15–28.

³⁹ SAN-MILLÁN, TURBON, RISSECH 2017.

⁴⁰ FALYS, PRANGLE 2015: 1–12.

⁴¹ PFEIFFER 1991: 167–175.

⁴² MEINDL, LOVEJOY 1985: 57–66.

³⁶ BUIKSTRA, UBELAKER 1994; KLALES *et al.* 2012: 104–114.

³⁷ WALKER 2008: 39–50.

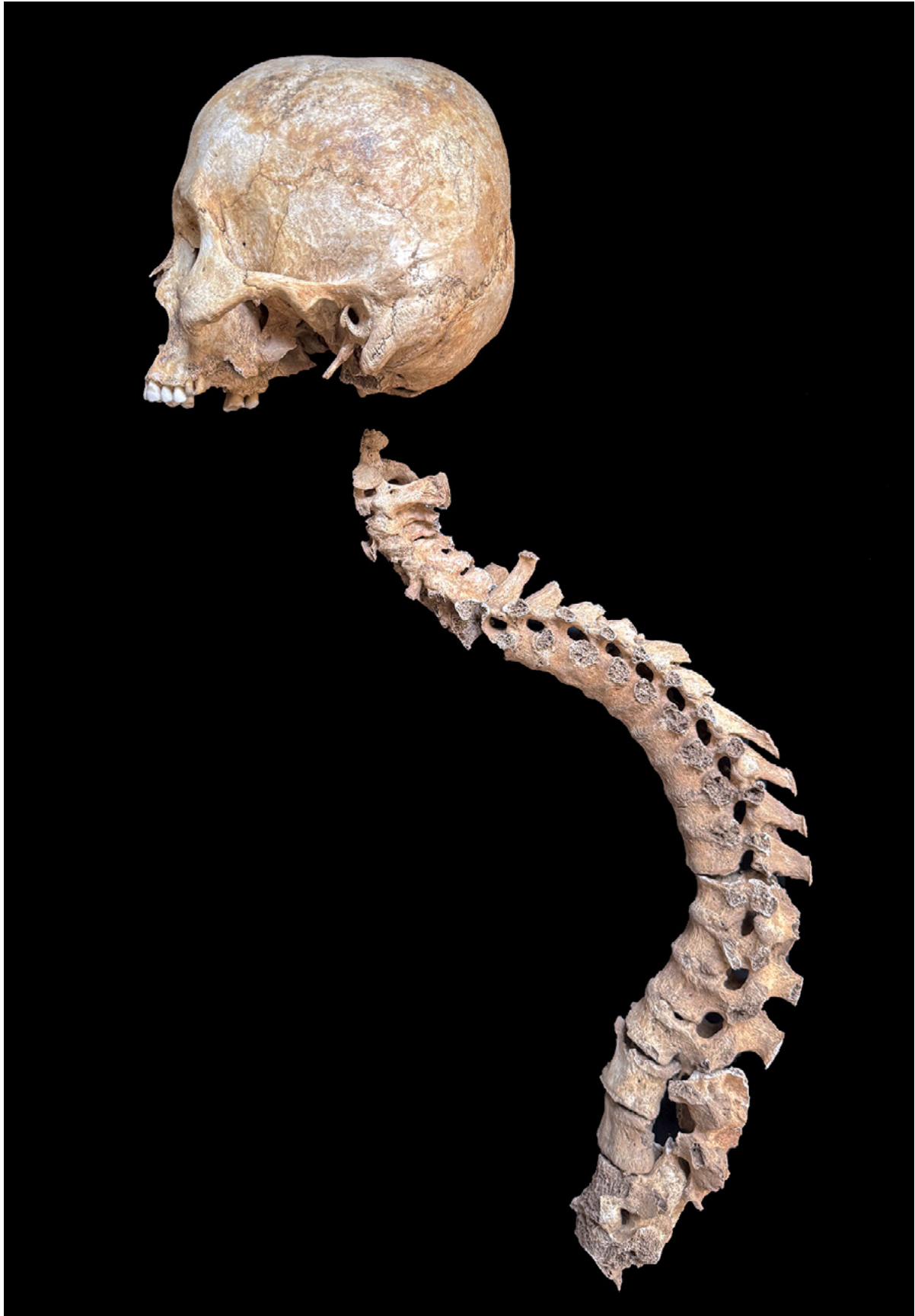³⁸ LOVEJOY *et al.* 1985: 15–28.

³⁹ SAN-MILLÁN, TURBON, RISSECH 2017.

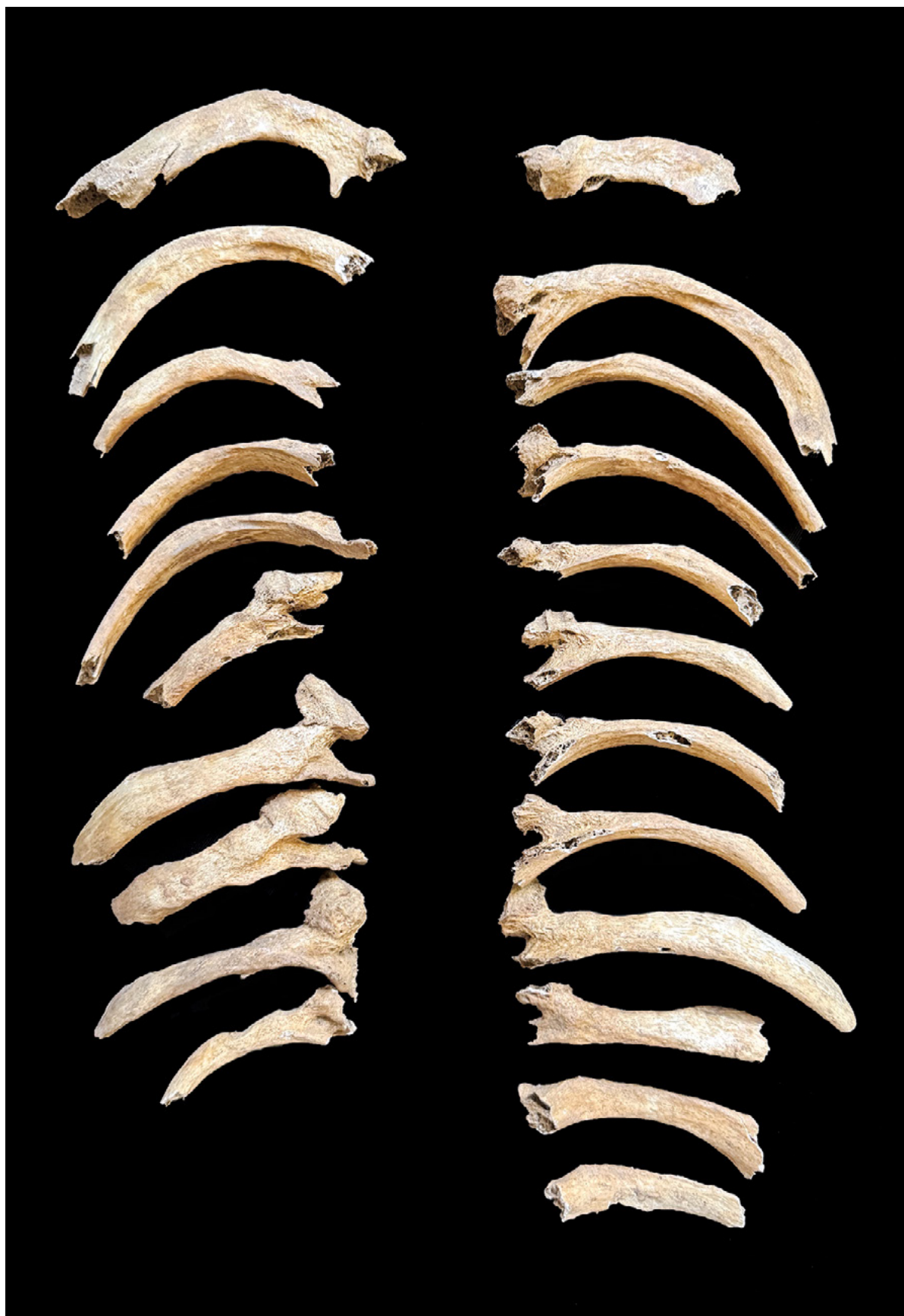⁴⁰ FALYS, PRANGLE 2015: 1–12.

⁴¹ PFEIFFER 1991: 167–175.

⁴² MEINDL, LOVEJOY 1985: 57–66.



SLIKA 1. Ankiroza kralježnice koja upućuje na ankilozantni spondilitis (snimila A. Uglešić)
FIGURE 1 Ankylosed spine demonstrating ankylosing spondylitis (photo by A. Uglešić)



SLIKA 2. *Prisutna rebra na kojima se uočavaju elementi ankiloze s prsnim kralješcima* (snimila A. Uglešić)
FIGURE 2 *Present ribs showing elements of ankylosis with the thoracic vertebrae* (photo by A. Uglešić)

talnog oštećenja s prednje strane vidljiva je i osifikacija intervertebralnog diska. Dakle, većina kralježaka ima razvijene sindezmodite na svojim rubovima koji se protežu vertikalno prema susjednom kralješku i spajaju kralježnicu u tri koštana bloka koja imaju kontinuiranu i glatku površinu. Prednji dio tijela kod nekih kralježaka dobio je četvrtasti oblik, što uz ankiлоzu cijeloy kralježnici daje izgled „bambusova štapa”, karakterističnog za ankiлоzantni spondilitis.⁴³ Sva su rebra prisutna te je unatoč postmortalnim oštećenjima vidljivo da su bilateralno ankiлоzom bila povezana sa svim prsnim kralješcima (sl. 2). Takvo spajanje rebra s kralježnicom na kraju može dovesti i do respiracijske insuficijencije.⁴⁴

Prsnu kralježnicu prati teška kifozna koja je rezultirala savijenošću osobe prema naprijed, a vratna kralježnica pokazuje lordozu koja je nastala kao odgovor na kifozu, kako bi osoba mogla držati glavu u pravilnijem položaju.

Sakroilijačni zglobovi na zdjeličnim kostima također su bili međusobno srasli, ali i ta je ankiлоza postmortalno oštećena (sl. 3). Isto tako, obje ključne kosti bile su spojene s manubrijem prsne kosti (sl. 4). Od ostalih patologija zabilježen je blagi degenerativni osteoarthritis na desnom temporomandibularnom zglobu, ramenima, laktovima, kukovima i koljenima. Na sjednim kostima uočen je burzitis koji je jače izražen na lijevoj strani (sl. 5). Također, na lijevoj goljeničnoj i lisnoj kosti prisutan je umjereni zarasli periostitis. Među ostalim, na nekim prisutnim zubima uočene su karijesne lezije i dentalni apscesi, osobito na kutnjacima, uz nekoliko zaživotnih gubitaka zubi. Također, na prednjim zubima primijećena je hipoplazija zubne cakline. Lubanja ima neobičan izgled koji podsjeća na umjetno deformirane lubanje, međutim, taj fenomen bit će tema nekih budućih istraživanja.

⁴³ ŠLAUS 2006.

⁴⁴ *Ibid.*

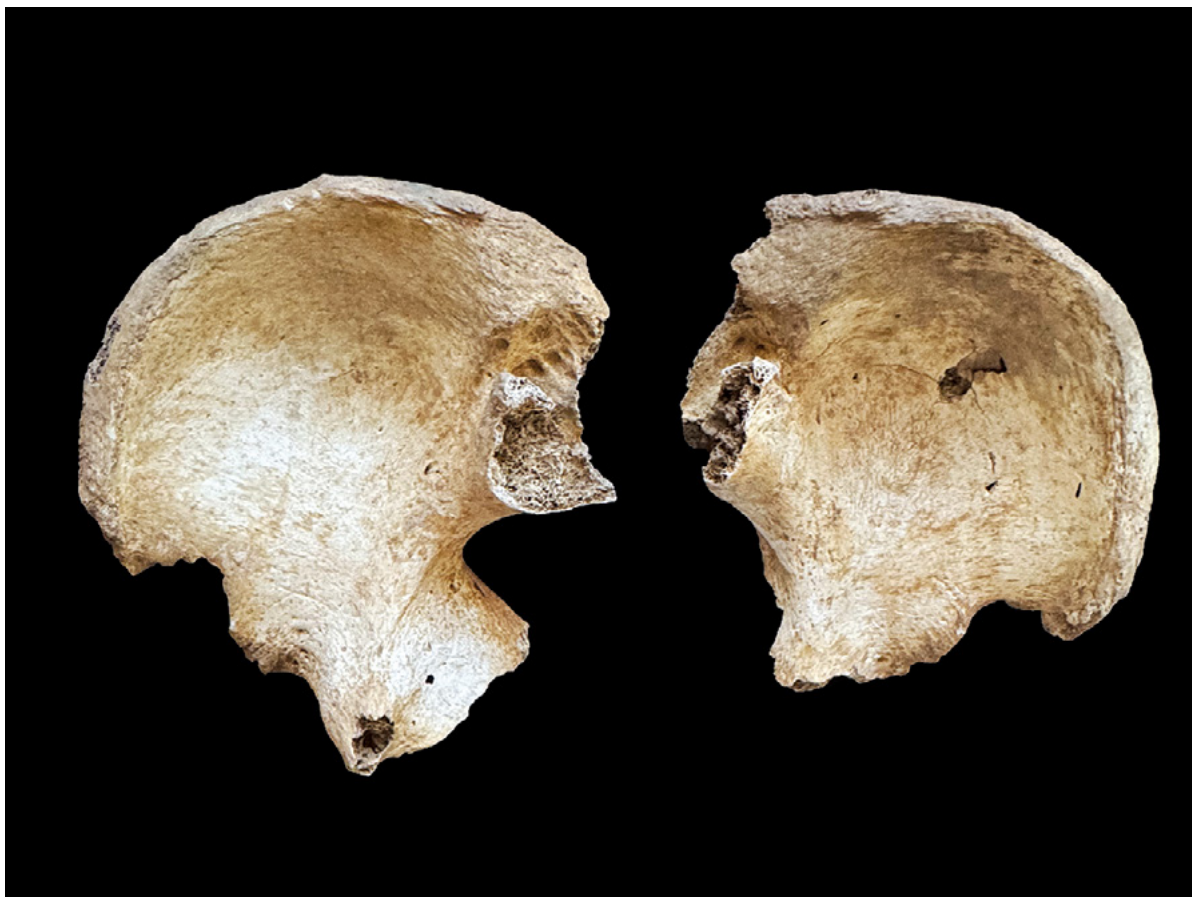
side. The third complete bony block consists of the vertebrae between T11 and L2. The posterior ligaments of the L2 to L5 vertebrae are fused, with a slightly preserved anterior intervertebral space. The L5 and S1 vertebrae are completely fused by bony ankylosis, and due to post-mortem damage on the anterior side, ossification of the intervertebral disc is also visible. Thus, most of the vertebrae have syndesmophytes along their margins, extending vertically towards the adjacent vertebra and fusing the spine into three bony blocks with a continuous, smooth surface. In some segments, the anterior portions of the vertebral bodies have become squared, and this, combined with the extensive ankylosis, results in the characteristic bamboo spine associated with ankylosing spondylitis.⁴³ All ribs are present, and despite post-mortem damage, it is evident that they were bilaterally fused by ankylosis to all thoracic vertebrae (Fig. 2). Such fusion of the ribs with the spine can eventually lead to respiratory insufficiency.⁴⁴

The thoracic spine shows pronounced kyphosis, which would have bent the individual forward, whereas the cervical spine exhibits a compensatory lordosis enabling a more upright head posture.

The sacroiliac joints on the pelvic bones were also fused, although this ankylosis has been damaged post-mortem (Fig. 3). Likewise, both clavicles were fused to the manubrium of the sternum (Fig. 4). Among other pathologies, mild degenerative osteoarthritis was recorded on the right temporomandibular joint, the shoulders, elbows, hips and knees. Bursitis was observed on the ischial bones, more pronounced on the left side (Fig. 5). Moderate healed periostitis is also present on the left tibia and fibula. In addition, several existing teeth show carious lesions and dental abscesses, particularly on the molars, along with several antemortem tooth losses. Enamel hypoplasia was also noted on the anterior teeth. The skull has

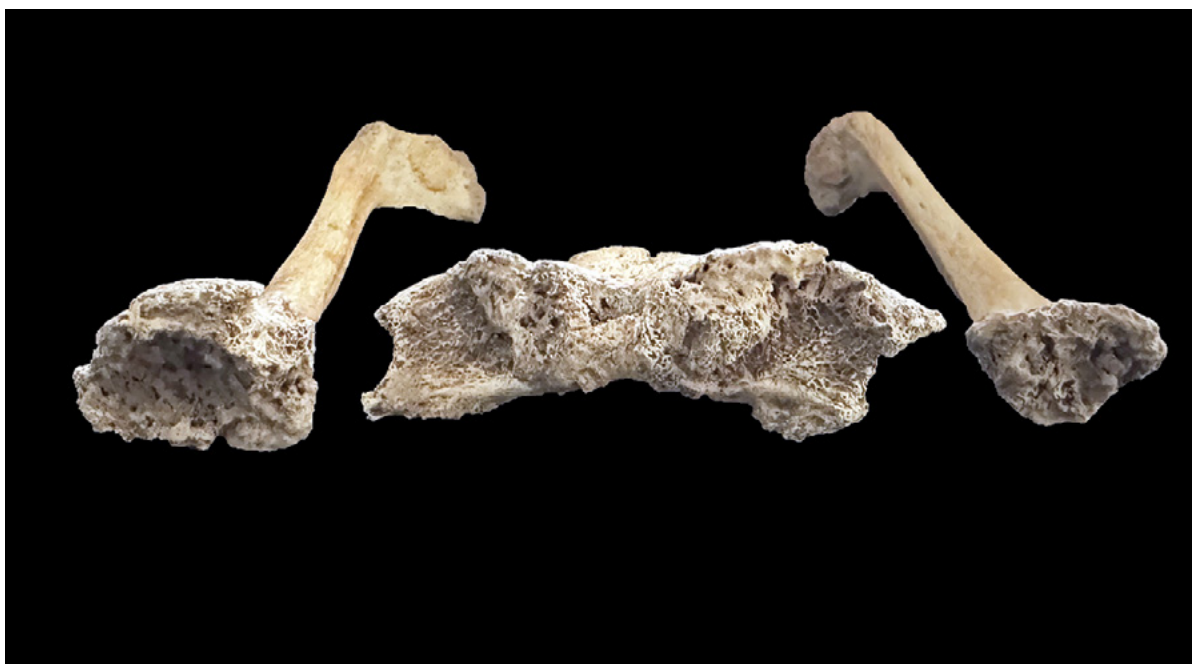⁴³ ŠLAUS 2006.

⁴⁴ *Ibid.*



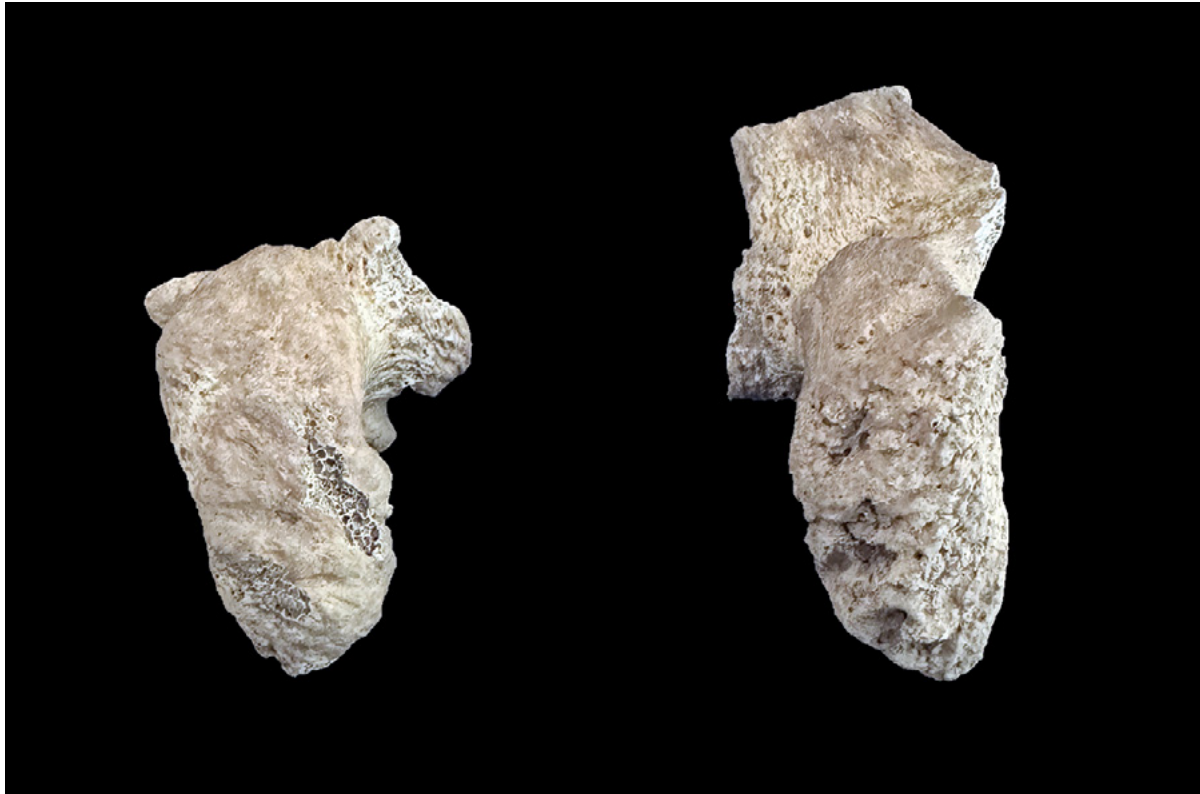SLIKA 3. *Zdjelične kosti s postmortalno oštećenom, ali jasno vidljivom ankilozom sakroilijačnih zglobova (snimila A. Uglešić)*

FIGURE 3 *Pelvic bones with post-mortem damage but clearly visible ankylosis of the sacroiliac joints (photo by A. Uglešić)*



SLIKA 4. *Promjene na spojevima manubrija prsne kosti i obje ključne kosti (snimila A. Uglešić)*

FIGURE 4 *Changes at the articulations of the manubrium of the sternum and both clavicles (photo by A. Uglešić)*



SLIKA 5. *Burzitis na sjednim kostima* (snimila A. Uglešić)
 FIGURE 5 *Bursitis on the ischial bones* (photo by A. Uglešić)

S obzirom na to da je ovdje riječ o osteološkim ostacima vrlo mladog muškarca koji je bolovao od posljednjeg stadija ankilozantnog spondilitisa, može se reći da je bolest napredovala vrlo brzo i agresivno. Uz današnja saznanja o tijeku i simptomima bolesti, kao i činjenici da sužavanje intervertebralnog prostora kod vratnih kralježaka posljedično dovodi do kompresije leđne moždine,⁴⁵ nije nelogično zaključiti da je ova osoba najvjerojatnije i umrla od ove teške bolesti.

RASPRAVA

Dijagnoza ankilozantnog spondilitisa (AS) može biti zahtjevna, osobito kad je riječ o analizi osteološkog materijala, u kojem nedostaju ligamenti i druga meka tkiva čije bi patološke promjene dodatno potvrdile prisutnost bolesti. Morfološke promjene na kostima karakte-

an unusual appearance reminiscent of artificially deformed crania; however, this phenomenon will be addressed in future research.

Given that these are the osteological remains of a very young man who was suffering from the final stage of ankylosing spondylitis, it can be said that the disease progressed very rapidly and aggressively. With current knowledge of the course and symptoms of the disease, as well as the fact that narrowing of the intervertebral space in the cervical region leads to compression of the spinal cord,⁴⁵ it is reasonable to conclude that this individual most likely died from this severe condition.

DISCUSSION

The diagnosis of ankylosing spondylitis (AS) can be challenging, especially when analysing osteological material in which ligaments and

⁴⁵ WOLF 2012: 15–26; DUYAR 2019: 1105.

⁴⁵ WOLF 2012: 15–26; DUYAR 2019: 1105.

ristične za AS mogu biti prisutne i kod drugih spondiloartropatija, kao i kod pojedinih oblika degenerativnih, infektivnih ili metaboličkih bolesti. U ovom slučaju razmotrene su sljedeće diferencijalne dijagnoze: difuzna idiopatska koštana hiperostoza (DISH), reaktivni artritis, meloreostoza, reumatoidni artritis i psorijatični artritis.

Difuzna idiopatska skeletna hiperostoza (engl. *diffuse idiopathic skeletal hyperostosis*, DISH) jest bolest kod koje dolazi do osifikacije ligamenata kralježnice. Naziva se još i Forestierova bolest, a javlja se kod osoba srednje do starije životne dobi, s većom učestalošću među muškarcima.⁴⁶ Iako točan uzrok nastanka ove bolesti još uvijek nije potpuno razjašnjen, njezina pojava najčešće se povezuje s čimbenicima poput poodmakle dobi, pretilosti, dijabetesa II. tipa, metaboličkih poremećaja, genske predispozicije te mikrotrauma.⁴⁷ DISH najčešće zahvaća kralježnicu, iako se ponekad može pojaviti i na drugim dijelovima, poput lakta, ivera (*patella*) ili Ahilove tetive, pri čemu dolazi do kalcifikacije i/ili osifikacije mekih tkiva i ligamenata. Najistaknutije je obilježje bolesti osifikacija prednjega uzdužnog ligamenta kralježnice, pri čemu su zahvaćena najmanje četiri susjedna kralješka. Ova je formacija najčešće ograničena na desnu stranu prsne kralježnice, ponajviše od 4. do 12. prsnog kralješka.⁴⁸ Zbog sličnosti kod ankilozе kralježaka, DISH se vrlo često pri analizi osteološkog materijala zamijeni s AS-om.⁴⁹ Međutim, između ove dvije bolesti postoje znatne razlike koje omogućuju njihovu pouzdanu diferencijaciju. Prije svega, javljaju se u različitim životnim razdobljima – AS se najčešće razvija u drugom ili

other soft tissues are absent, as pathological changes in these would further confirm the presence of the disease. Morphological changes on the bones characteristic of AS may also occur in other spondyloarthropathies, as well as in certain forms of degenerative, infectious or metabolic diseases. In this case, the following differential diagnoses were considered: diffuse idiopathic skeletal hyperostosis (DISH), reactive arthritis, melorheostosis, rheumatoid arthritis and psoriatic arthritis.

Diffuse idiopathic skeletal hyperostosis (DISH) is a condition characterised by ossification of the spinal ligaments. It is also known as Forestier's disease and occurs in middle-aged to older individuals, with a higher prevalence among men.⁴⁶ Although the exact cause of this condition is still not fully understood, its occurrence is most commonly associated with factors such as advanced age, obesity, type II diabetes, metabolic disorders, genetic predisposition and microtrauma.⁴⁷ DISH most commonly affects the spine, although it can also appear in other areas, such as the elbow, the *patella* or the Achilles tendon, where it results in calcification and/or ossification of soft tissues and ligaments. The most prominent feature of the disease is ossification of the anterior longitudinal ligament of the spine, involving at least four adjacent vertebrae. This formation is most often limited to the right side of the thoracic spine, predominantly between the 4th and 12th thoracic vertebrae.⁴⁸ Because of the similarity in vertebral ankylosis, DISH is very often mistaken for AS when analysing osteological material.⁴⁹ However, there are significant differences between the two conditions that allow for reliable dif-

⁴⁶ FORESTIER, ROTES-QUEROL 1950: 321-330; ORTNER 2003.

⁴⁷ DENKO, MALEMUD 2006: 292-297; VERLAAN, ONER, MAAT 2007: 1129-1130; KHUDAVERDYAN *et al.* 2021: 92.

⁴⁸ ORTNER 2003; ROGERS, WALDRON 2001: 357-365; VENTADES *et al.* 2018: 46-47; WHITE, BLACK, FOLKENS 2011.

⁴⁹ AUFDERHEIDE, RODRÍGUEZ-MARTÍN 1998; ROBERTS, MANCHESTER 2005; ŠLAUS, NOVAK, ČAVKA 2012: 3988-3989; VENTADES *et al.* 2018: 46-47.

⁴⁶ FORESTIER, ROTES-QUEROL 1950: 321-330; ORTNER 2003.

⁴⁷ DENKO, MALEMUD 2006: 292-297; VERLAAN, ONER, MAAT 2007: 1129-1130; KHUDAVERDYAN *et al.* 2021: 92.

⁴⁸ ORTNER 2003; ROGERS, WALDRON 2001: 357-365; VENTADES *et al.* 2018: 46-47; WHITE, BLACK, FOLKENS 2011.

⁴⁹ AUFDERHEIDE, RODRÍGUEZ-MARTÍN 1998; ROBERTS, MANCHESTER 2005; ŠLAUS, NOVAK, ČAVKA 2012: 3988-3989; VENTADES *et al.* 2018: 46-47.

trećem desetljeću života (rijetko i u četvrtom desetljeću), dok se DISH tipično pojavljuje u srednjoj ili starijoj dobi.⁵⁰ Također, progresija AS-a dovodi do izgleda „bambusova štapa”, dok kod DISH-a kralježnica poprima izgled „tekućeg voska” (engl. *flowing wax*). Osim toga, DISH ne uzrokuje ankilozu sakroilijačnih i kostovertebralnih zglobova, što je učestala karakteristika AS-a.⁵¹

Reaktivni artritis, u starijoj literaturi poznat i kao Reiterov sindrom, predstavlja neinfektivno upalno stanje koje se razvija kao posljedica bakterijske infekcije urogenitalnog ili gastrointestinalnog trakta, često u kombinaciji s autoimunim i genetski uvjetovanim čimbenicima.⁵² Klinički i patološki se manifestira sakroileitismom, pri čemu su promjene na sakroilijačnim zglobovima često asimetrične,⁵³ te ankilozom kralježaka uz očuvanje intervertebralnog prostora. Karakteristična je i pojava slobodnih kralježaka između kralježaka zahvaćenim ankilozom (engl. *skip lesions*).⁵⁴ Najčešće zahvaća donje ekstremitete,⁵⁵ a u rijetkim slučajevima može dovesti do deformacije stopala koju obilježava izražena resorpcija i ankiloza u području stopala.⁵⁶ Stanje se najčešće javlja kod muškaraca u dobi od 20 i 40 godina.⁵⁷ Usporedbom navedenih simptoma s patološkim promjenama uočenima na kosturu pronađenom na Žumberku mogu se prepoznati određene sličnosti, no uočavaju se i ključne razlike. Najvažnija razlika leži u činjenici da kod ovog kostura nema zahvaćenosti donjih ekstremiteta, kao ni asimetrične zahvaćenosti sakroilijačnog dijela, što su česte značajke reaktivnog artritisa. Do-

ferentiation. First and foremost, they occur at different stages of life – AS most commonly develops in the second or third decade (rarely in the fourth), whereas DISH typically appears in middle or older age.⁵⁰ In addition, the progression of AS produces the characteristic bamboo spine, while DISH is marked by an appearance reminiscent of flowing wax. Furthermore, DISH does not cause ankylosis of the sacroiliac or costovertebral joints, which is a common feature of AS.⁵¹

Reactive arthritis, known in older literature as Reiter's syndrome, is a non-infectious inflammatory condition that develops as a consequence of a bacterial infection of the urogenital or gastrointestinal tract, often in combination with autoimmune and genetically determined factors.⁵² In clinical and pathological terms, it manifests as sacroiliitis, with changes in the sacroiliac joints often being asymmetrical,⁵³ and as ankylosis of the vertebrae with preservation of the intervertebral space. Another characteristic feature is the presence of free vertebrae between ankylosed segments ('skip lesions').⁵⁴ It most commonly affects the lower limbs,⁵⁵ and in rare cases may lead to deformation of the foot, marked by pronounced resorption and ankylosis in the foot region.⁵⁶ The condition most commonly occurs in men between the ages of 20 and 40.⁵⁷ When the symptoms described above are compared with the pathological changes observed on the skeleton from Žumberak, certain similarities can be recognised, but key differences are also evident. The most significant difference lies in the fact that this skel-

⁵⁰ OLIVIERI *et al.* 2009: 321–328; DUYAR 2019: 1104–1105.

⁵¹ ARRIAZA 1993: 263–278; ZIMMERMAN, KELLEY 1982; ŠLAUS, NOVAK, ČAVKA; 3988–3989; KHUDEVARDYAN *et al.* 2021: 92.

⁵² PAVELKA *et al.* 2020; TAUROG, GENSLER, HAROON 2022: 2790–2801; CAWLEY, PAINE 2015: 73.

⁵³ WALDRON 2009.

⁵⁴ ROGERS *et al.* 1987: 179–193.

⁵⁵ AUFDERHEIDE, RODRÍGUEZ-MARTÍN 1998; WALDRON 2009.

⁵⁶ CAWLEY, PAINE 2015: 73; MARTEL 1979: 12–23.

⁵⁷ TAUROG, GENSLER, HAROON 2022: 2790–2801; PAVELKA *et al.* 2020; GALOVÁ *et al.* 2022: 1879.

⁵⁰ OLIVIERI *et al.* 2009: 321–328; DUYAR 2019: 1104–1105.

⁵¹ ARRIAZA 1993: 263–278; ZIMMERMAN, KELLEY 1982; ŠLAUS, NOVAK, ČAVKA; 3988–3989; KHUDEVARDYAN *et al.* 2021: 92.

⁵² PAVELKA *et al.* 2020; TAUROG, GENSLER, HAROON 2022: 2790–2801; CAWLEY, PAINE 2015: 73.

⁵³ WALDRON 2009.

⁵⁴ ROGERS *et al.* 1987: 179–193.

⁵⁵ AUFDERHEIDE, RODRÍGUEZ-MARTÍN 1998; WALDRON 2009.

⁵⁶ CAWLEY, PAINE 2015: 73; MARTEL 1979: 12–23.

⁵⁷ TAUROG, GENSLER, HAROON 2022: 2790–2801; PAVELKA *et al.* 2020; GALOVÁ *et al.* 2022: 1879.

datno, kod analiziranog kostura uočena je i zahvaćenost intervertebralnog prostora, što nije tipično obilježje reaktivnog artritisa.

Meloreostoza je rijetka bolest kostiju koju karakterizira hiperostoza, što naposljetku dovodi do deformacija i koštane ankiloze.⁵⁸ Riječ je o bolesti od koje se može oboljeti u bilo kojoj životnoj dobi, ali se najčešće otkriva u adolescenciji ili ranoj odrasloj dobi. Jednako često obolijevaju muškarci i žene. Nepredvidiva je, sporo se razvija i može pogoditi bilo koju kost, ali najčešće zahvaća duge kosti donjih ekstremiteta. Promjene na kralježnici i rebrima znatno su rjeđe.⁵⁹ Točna etiologija bolesti još nije potpuno razjašnjena, no pretpostavlja se da određenu ulogu imaju somatske mutacije i poremećaji.⁶⁰ Usporedimo li navedene karakteristike meloreostoze s promjenama zabilježenima na kosturu muškarca iz groba 313 s lokaliteta Žumberak, malo je vjerojatno da je riječ o toj bolesti. Naime, meloreostoza iznimno rijetko zahvaća kralježnicu, dok je kod ovog pojedinca prisutna gotovo potpuna ankiloza kralježaka. Uz to, na kostima udova nisu uočene ankilozantne promjene. Sve navedeno sugerira da je dijagnoza ankilozantnog spondilitisa vjerojatnija.

Reumatoidni artritis (RA) jest autoimuna bolest prepoznatljiva po uništavanju zglobnog tkiva.⁶¹ Obično simetrično zahvaća nekoliko sinovijskih zglobova pridodanog kostura (engl. *appendicular skeleton*), a najčešće zglobove šake, koji su ujedno i prvo mjesto na kojem se simptomi javljaju.⁶² Nakon toga najčešće uništava koljena, temporomandibularne zglobove, zglobove pešća, ramena i laktova.⁶³ Kao i u slučaju AS-a, kod reumatoidnog je artritisa

eton shows no involvement of the lower limbs, nor any asymmetrical involvement of the sacroiliac region, both of which are common features of reactive arthritis. Additionally, involvement of the intervertebral space was observed in the analysed skeleton, which is not a typical feature of reactive arthritis.

Meloreostosis is a rare bone disease characterised by hyperostosis, which ultimately leads to deformities and bony ankylosis.⁵⁸ It is a condition that can develop at any age, but it is most commonly detected in adolescence or early adulthood. Men and women are affected with equal frequency. It is unpredictable, progresses slowly and may involve any bone, although it most commonly affects the long bones of the lower limbs. Changes in the spine and ribs are much rarer.⁵⁹ The exact aetiology of the disease is still not fully understood, but somatic mutations and disorders are thought to play a role.⁶⁰ When the characteristics of meloreostosis are compared with the changes recorded on the skeleton of the man from Grave 313 at the Žumberak site, it is unlikely that this condition was present. The fact is that cases in which meloreostosis affects the spine are extraordinarily rare, whereas this individual exhibits an almost complete ankylosis of the vertebrae. Furthermore, no ankylosing changes were observed on the bones of the limbs. All of this suggests that a diagnosis of ankylosing spondylitis is more likely.

Rheumatoid arthritis (RA) is an autoimmune disease characterised by the destruction of joint tissue.⁶¹ It typically affects several synovial joints of the appendicular skeleton symmetrically, most commonly the joints of the hand, which are also the first sites where symptoms appear.⁶²

⁵⁸ CAMPBELL, PAPADEMETRIOU, BONWGLIO 1968: 1281–1304; KALBERMATTEN *et al.* 2001: 48–52; ETHUNANDAN *et al.* 2004: 1062–1065; ŠLAUS, NOVAK, ČAVKA 2012: 3989.

⁵⁹ KALBERMATTEN *et al.* 2001: 48–52; HOANG *et al.* 2020; IORDACHE *et al.* 2023: 2–3.

⁶⁰ KANG *et al.* 2020.

⁶¹ RADU, BUNGAU 2021: 1.

⁶² WALDRON 2009; ORTNER 2003.

⁶³ ORTNER 2003; ŠLAUS, NOVAK, ČAVKA 2012: 3989; ROBERTS, MANCHESTER 2005.

⁵⁸ CAMPBELL, PAPADEMETRIOU, BONWGLIO 1968: 1281–1304; KALBERMATTEN *et al.* 2001: 48–52; ETHUNANDAN *et al.* 2004: 1062–1065; ŠLAUS, NOVAK, ČAVKA 2012: 3989.

⁵⁹ KALBERMATTEN *et al.* 2001: 48–52; HOANG *et al.* 2020; IORDACHE *et al.* 2023: 2–3.

⁶⁰ KANG *et al.* 2020.

⁶¹ RADU, BUNGAU 2021: 1.

⁶² WALDRON 2009; ORTNER 2003.

sama etiologija nepoznata, međutim, prema dosadašnjim istraživanjima, genska komponenta igra važnu ulogu.⁶⁴ Za razliku od AS-a, reumatoidni artritis više pogađa žene nego muškarce (3 : 1). Kod reumatoidnog artritisa kosti osovinskog kostura (engl. *axial skeleton*) rijetko su zahvaćene, a ako i jesu, tada promjene najčešće pronalazimo samo na vratnoj kralježnici. Obično se ne povezuje sa sakroilitisom i ankilozom kralježnice.⁶⁵ Prema navedenome, muškarac iz Žumberka nije mogao bolovati od reumatoidnog artritisa s obzirom na to da nema nikakve promjene na kostima šake koje su karakteristične za tu bolest. Isto tako, promjene na kralježnici vidljive su u svim regijama kralježnice, a ne samo u vratnoj kralježnici, kako je to najčešće slučaj kod RA-a. Kako je već ranije spomenuto, ankiloza kralježnice se obično ne povezuje s RA-om.

Psorijatični artritis jest upala mišićno-koštanog sustava povezana s kožnom psorijazom. Podjednako pogađa žene i muškarce, najčešće u dobi od 40 do 50 godina.⁶⁶ Bolest zahvaća periferne ili sakroilijačne zglobove te kralježnicu,⁶⁷ ali sakroilijačni su zglobovi nešto rjeđe pogođeni. Promjene koje se javljaju nisu simetrične i bilateralne.⁶⁸ Učestalost zahvaćenosti zglobova ruku i nogu gotovo je jednaka. Za psorijatični artritis karakteristično je i to da teška erozija radi promjene na falangama ruku i nogu, poznate pod nazivom „olovka u šalici” (engl. *pencil-in-cup*).⁶⁹ Isto tako, kod ove bolesti sačuvan je intervertebralni prostor te postoje nespojeni, slobodni kralješci između koštanih blokova koje sačinjavaju dva ili više kontinuiranih kralježaka.⁷⁰ Usljed toga kralježnica nema izgled „bambusova štapa” koji

It subsequently most often affects the knees, the temporomandibular joints, the wrist joints, the shoulders and the elbows.⁶³ As in the case of AS, the aetiology of rheumatoid arthritis remains unknown; however, according to current research, the genetic component plays an important role.⁶⁴ Unlike AS, rheumatoid arthritis affects women more often than men (3 : 1). In rheumatoid arthritis, the bones of the axial skeleton are rarely involved; when they are, changes are most commonly found only in the cervical spine. It is generally not associated with sacroiliitis or ankylosis of the spine.⁶⁵ Accordingly, the man from Žumberak could not have suffered from rheumatoid arthritis, as there are no changes on the hand bones that would be characteristic of this condition. Likewise, the changes on the spine are present in all regions: not only in the cervical region, as is most commonly the case in RA. As mentioned earlier, ankylosis of the spine is generally not associated with RA.

Psoriatic arthritis is an inflammatory disorder of the musculoskeletal system associated with cutaneous psoriasis. It affects women and men equally, most commonly between the ages of 40 and 50.⁶⁶ The disease involves the peripheral or sacroiliac joints and the spine,⁶⁷ although the sacroiliac joints are somewhat less frequently affected. The changes that occur are not symmetrical or bilateral.⁶⁸ The frequency of involvement of the hand and foot joints is nearly the same. Psoriatic arthritis is also characterised by severe erosion caused by changes on the phalanges of the hands and feet, known as the pencil-in-cup deformity.⁶⁹ In this condition, the intervertebral space is preserved, and unfused, free vertebrae are present between the

⁶⁴ FOX 2001: 1085–1102.

⁶⁵ AUFDERHEIDE, RODRÍGUEZ-MARTÍN; WALDRON 2009.

⁶⁶ OCAMPO, GLADMAN 2019.

⁶⁷ WALDRON 2009.

⁶⁸ RESNICK 1989: 523–532; WALDRON 2009; ROGERS, WALDRON 1995: 357–365.

⁶⁹ ROGERS *et al.* 1987.

⁷⁰ WALDRON 2009; PAPARO *et al.* 2014: 156–163.

⁶³ ORTNER 2003; ŠLAUS, NOVAK, ČAVKA 2012: 3989; ROBERTS, MANCHESTER 2005.

⁶⁴ FOX 2001: 1085–1102.

⁶⁵ AUFDERHEIDE, RODRÍGUEZ-MARTÍN; WALDRON 2009.

⁶⁶ OCAMPO, GLADMAN 2019.

⁶⁷ WALDRON 2009.

⁶⁸ RESNICK 1989: 523–532; WALDRON 2009; ROGERS, WALDRON 1995: 357–365.

⁶⁹ ROGERS *et al.* 1987.

TABLICA 1. Pregled diferencijalnih dijagnoza i njihovih karakteristika (izradile: A. Adamić Hadžić, A. Uglešić)
TABLE 1 Overview of the differential diagnoses and their characteristics (made by A. Adamić Hadžić and A. Uglešić)

Karakteristike / Characteristics	DISH	Reaktivni artritis / Reactive arthritis	Meloreostoza / Melorheostosis	Reumatoidni artritis / Rheumatoid arthritis	Psorijatični artritis / Psoriatic arthritis	Ankilozantni spondilitis / Ankylosing spondylitis
Spol / Sex	češće muškarci / more common in men	najčešće muškarci / most common in men	podjednako žene i muškarci / equally common in women and men	češće žene / more common in women	podjednako žene i muškarci / equally common in women and men	češće muškarci / more common in men
Dob / Age	srednja ili starija dob / middle and older age	od 20 do 40 godina / between 20 and 40 years	najčešće adolescencija ili rana odrasla dob / most often adolescence or early adulthood	srednja ili starija dob / middle and older age	od 40 do 50 godina / between 40 and 50 years	od 20 do 40 godina / between 20 and 40 years
Distribucija / Distribution	najčešće prsna kralježnica, a ponekad lakat, iver i Ahilova tetiva / most commonly the thoracic spine, sometimes the elbow, patella and Achilles tendon	najčešće donji ekstremiteti, stopalo i kralježnica / most commonly the lower limbs, feet and spine	najčešće duge kosti donjih ekstremiteta, promjene na kralježnici i rebrima rjeđe / most commonly long bones of the lower limbs, spinal and rib involvement less common	simetrični zglobovi šaka i stopala, koljena, temporomandibularni zglobovi, ramena i laktovi, rijetko vratna kralježnica / symmetrical joints of the hands and feet, knees, temporomandibular joints, shoulders and elbows; cervical spine involvement less common	periferni ili sakroilijski zglobovi, kralježnica, zglobovi ruku i nogu / peripheral or sacroiliac joints, spine, joints of the arms and legs equally often	sakroilijski zglobovi, kralježnica, kostovertebralni zglobovi, ramena, temporomandibularni zglobovi i zglobovi koljena / sacroiliac joints, spine, costovertebral joints, shoulders, temporomandibular joints, knee joints
Tipične lezije / Typical lesions	<i>flowing wax</i> na prednjim trupovima kralježaka / <i>flowing wax</i> on the anterior surfaces of vertebral bodies	asimetrične promjene, skip lezije / asymmetrical changes, skip lesions	<i>candle wax dripping</i>	periarтикуларне lezije / periarticular lesions	<i>pencil-in-cup</i>	sindezmozofiti, bamboo spine / Syndesmophytes, bamboo spine
Zahvaćenost sakroilijskih zglobova / Sacroiliac joint involvement	ne postoji / absent	postoji, ali je asimetrična / present but asymmetrical	ne postoji / absent	postoji, ali obično sekundarno / present but usually secondary	postoji, ali je asimetrična / present but asymmetrical	postoji, simetrična je / present and symmetrical
Osteoproliferacija / Osteoproliferation	masivna, glatka i kontinuirana / massive, smooth, continuous	diskretna, ali uz erozije / discrete, but with erosions	izražena, nepravilna, lokalna / pronounced, irregular, localised	ne postoji, pretežno destrukcija / absent; predominantly destruction	kombinacija erozije i proliferacije / combination of erosion and proliferation	sindezmozofiti / syndesmophytes
Erozije / Erosions	ne postoje / absent	česte, nepravilne / common, irregular	ne postoje / absent	česte i tipične / common and typical	kombinacija erozija i proliferacije / combination of erosion and proliferation	rijeđe i manje izražene / rare and less pronounced
Očuvanost intervertebralnog prostora / Preservation of intervertebral space	prisutna / present	prisutna / present	prisutna / present	sušena / reduced	prisutna / present	nije prisutna / absent

je karakterističan za ankilozantni spondilitis.⁷¹ Četvrtasti izgled tijela kralježaka također je rjeđa pojava nego u slučaju AS-a.⁷² S obzirom na navedene karakteristike psorijatičnog artritisa, izgledno je da muškarac iz Žumberka nije bolovao od te bolesti jer se psorijatični artritis javlja u dobi od 40 do 50 godina, a muškarac je umro prije dosezanja te dobi. Promjene na kosturu muškarca izrazito su teške pa se može pretpostaviti da se sam početak bolesti kod njega najvjerojatnije javio prije dvadesete godine. Također, ova osoba nema prisutne promjene na falangama ruku. Osim toga, kod ovog je muškarca intervertebralni prostor tek blago sačuvan između nekoliko kralježaka, ali i ti su kralješci u posteriornom dijelu međusobno spojeni.

Svaka od navedenih diferencijalnih dijagnoza pokazuje određene sličnosti s kosturom iz groba 313 na lokalitetu Žumberak – crkva sv. Nikole biskupa, zbog čega je bilo nužno razmotriti ih pojedinačno kako bi se mogle isključiti te kako bi se moglo doći do konačne dijagnoze (tab. 1).

Prisutnost brojnih karakterističnih obilježja snažno upućuje na to da je ovaj pojedinac bolovao od ankilozantnog spondilitisa. Usporedba ovoga nalaza s onim iz Anatolije,⁷³ kao i s kriterijima koje je autor primijenio za postavljanje iste dijagnoze, dodatno potkrepljuje ovu pretpostavku. Naime, i u ovom slučaju zabilježeni su sljedeći simptomi karakteristični za AS:

1. bilateralna i simetrična ankiloza sakroilijačnih zglobova
2. ankiloza svih kralježaka
3. osifikacija spinalnih ligamenata
4. ankiloza svih kostovertebralnih zglobova
5. kvadratni oblik tijela kralježaka
6. karakterističan izgled „bambusova štapa”
7. razvoj izražene lordoze i kifoze te
8. kalcifikacija intervertebralnih diskova.

⁷¹ PAPARO *et al.* 2014: 156–163.

⁷² RESNICK 1974: 523–532.

⁷³ DUYAR 2019: 1102–104.

bony blocks composed of two or more contiguous vertebrae.⁷⁰ As a result, the vertebral column does not exhibit the characteristic bamboo spine appearance associated with ankylosing spondylitis.⁷¹ A squaring of the vertebral bodies is also less common than in AS.⁷² Given these characteristics of psoriatic arthritis, it is unlikely that the man from Žumberak suffered from this disease, as psoriatic arthritis typically develops between the ages of 40 and 50, and he died before reaching that age. The pathological changes on his skeleton are severe, suggesting that the onset of the disease most likely occurred before the age of twenty. In addition, this individual shows no changes on the phalanges of the hands. Moreover, the intervertebral space is only slightly preserved between a few vertebrae, yet even those vertebrae are fused to one another on the posterior side.

Each of the differential diagnoses listed shows certain similarities to the skeleton from Grave 313 at the Žumberak – Church of St Nicholas the Bishop site, which made it necessary to consider them individually in order to exclude them and reach a final diagnosis (Tab. 1).

The presence of numerous characteristic features strongly indicates that this individual suffered from ankylosing spondylitis. A comparison of this case with one from Anatolia,⁷³ as well as with the criteria used by that author to establish the same diagnosis, further supports this conclusion. Specifically, the following symptoms characteristic of AS were recorded in the Anatolian case:

1. bilateral and symmetrical ankylosis of the sacroiliac joints,
2. ankylosis of all vertebrae,
3. ossification of the spinal ligaments,
4. ankylosis of all costovertebral joints,
5. squaring of the vertebral bodies,
6. the characteristic bamboo-spine appearance,

⁷⁰ WALDRON 2009; PAPARO *et al.* 2014: 156–163.

⁷¹ PAPARO *et al.* 2014: 156–163.

⁷² RESNICK 1974: 523–532.

⁷³ DUYAR 2019: 1102–104.

Dodatno, kod ovoga je pojedinca uočena i ankiloza između kondila zatiljne kosti i prvog vratnog kralješka, kao i između ključnih kostiju i manubrija prsne kosti. Također, prisutnost burzitisa na sjednim kostima dodatno potkrepljuje početnu hipotezu. Dijagnoza je podržana i usporedbom s drugim objavljenim slučajevima u literaturi koji prikazuju slične osteološke obrasce.⁷⁴

ZAKLJUČNA RAZMATRANJA

Detaljnou analizom kostura muškarca iz groba 313 na lokalitetu Žumberak – sv. Nikola biskup zaključeno je da je najvjerojatnije riječ o uznapredovanom obliku ankilozantnog spondilitisa s posljedičnim komplikacijama koje su mogle dovesti do smrti osobe. Promjene na kralježnici, sakroiliječnim i kostovertebralnim zglobovima ukazuju na progresivnu upalnu bolest koja je vjerojatno započela u adolescenciji, najvjerojatnije prije dvadesete godine života.

Do smrti, u dobi od 25 do 35 godina, bolest je napredovala do potpune ankiloze kralježnice, bilateralne ankiloze rebara te izraženih deformacija u obliku kifoze i kompenzatorne lordoze. Takve promjene često uzrokuju znatno narušavanje kvalitete života – uključujući kroničnu bol, ograničenu pokretljivost i otežano disanje, koje može dovesti do respiratorne insuficijencije. Može se pretpostaviti da je upravo ta bolest bila neposredan uzrok smrti u ovoj relativno mladoj dobi.

Radi preciznijeg postavljanja dijagnoze provedena je detaljna diferencijalna dijagnostika kojom su isključeni drugi slični patološki entiteti. Na temelju rasporeda i morfologije patoloških promjena, opsega zahvaćenosti kralježnice i zglobova te usporedbe s kriterijima iz relevantne paleopatološke literature, dijagnoza

7. the development of pronounced lordosis and kyphosis, and
8. calcification of the intervertebral discs.

In addition, this individual exhibited ankylosis between the occipital condyles and the first cervical vertebra, as well as between the clavicles and the manubrium of the sternum. The presence of bursitis on the ischial bones further supports the initial hypothesis. The diagnosis is further supported by comparison with other published cases in the literature, which display similar osteological patterns.⁷⁴

CONCLUDING REMARKS

A detailed analysis of the skeleton of the man from Grave 313 at the Žumberak – St Nicholas the Bishop site indicates that the most probable diagnosis is an advanced form of ankylosing spondylitis with secondary complications that may have led to his death. The changes on the spine, sacroiliac joints and costovertebral joints point to a progressive inflammatory disease that probably began in adolescence, most likely before the age of twenty.

By the time of his death, between the ages of 25 and 35, the disease had progressed to complete ankylosis of the spine, bilateral ankylosis of the ribs, and pronounced deformities in the form of kyphosis and compensatory lordosis. Such changes often cause a severe deterioration in quality of life – including chronic pain, restricted mobility and impaired breathing, which may lead to respiratory insufficiency. It can be assumed that this disease was the immediate cause of his death at this relatively young age.

To establish the diagnosis more precisely, a detailed differential diagnostic assessment was carried out, which excluded other similar pathological conditions. Based on the distri-

⁷⁴ ŠLAUS, NOVAK, ČAVKA 2012: 3985–3992; GALOVÁ *et al.* 2022: 1873–1881; DUYAR 2019: 1100–1108; KHUDA-VERDYAN *et al.* 2021: 85–100.

⁷⁴ ŠLAUS, NOVAK, ČAVKA 2012: 3985–3992; GALOVÁ *et al.* 2022: 1873–1881; DUYAR 2019: 1100–1108; KHUDA-VERDYAN *et al.* 2021: 85–100.

ankilozantnog spondilitisa pokazuje se kao najvjerojatnija.

Važan aspekt nalazišta jest i kontekst ukopa. Pojedinaac nije bio izdvojen iz uobičajenog grobnog rasporeda, što upućuje na to da unatoč znatno narušenoj pokretljivosti i ovisnosti o pomoći, nije bio društveno marginaliziran. Time se otvara prostor za razmatranje stavova zajednice prema bolesnima. Šlaus, Novak i Čavka bilježe slične slučajeve iz srednjeg vijeka, ali ti su pojedinci doživjeli više od 45 godina, što sugerira dugotrajnu skrb i podršku zajednice.⁷⁵ U ovom slučaju bolest je započela rano i napredovala brzo s obzirom na to da vjerojatno nije bilo načina da se tijekom bolesti ublaži.

Ovaj nalaz predstavlja prvi dokumentirani slučaj ankilozantnog spondilitisa iz novovjekovnog konteksta u kontinentalnoj Hrvatskoj. Time znatno pridonosi paleopatološkoj literaturi i razumijevanju distribucije, kliničkih manifestacija i društvenih implikacija ove bolesti u arheološkim populacijama.

Zahvale

Zahvaljujemo doc. dr. sc. Ani Azinović Bebek, voditeljici istraživanja, i dr. sc. Sebastijanu Stinglu na ustupljenim informacijama o kontekstu groba te na omogućenom uvidu u podatke istraživanja, čime su znatno doprinijeli realizaciji ovog rada.

tribution and morphology of the pathological changes, the extent of involvement of the spine and joints, and comparison with criteria from the relevant palaeopathological literature, ankylosing spondylitis emerges as the most probable diagnosis.

An important aspect of the site is also the burial context. The individual was not separated from the usual burial arrangement, indicating that despite his severely limited mobility and dependence on assistance he was not socially marginalised. This opens space for considering the community's attitudes towards the sick. Šlaus, Novak and Čavka record similar cases from the medieval period, but those individuals lived beyond the age of 45, suggesting long-term care and support provided by their communities.⁷⁵ In this case, the disease began early and progressed rapidly, as most likely there were no means of alleviating its course.

This find represents the first documented case of ankylosing spondylitis from an early modern context in continental Croatia. It therefore makes a significant contribution to the palaeopathological literature and to the understanding of the distribution, clinical manifestations and social implications of this disease in archaeological populations.

Acknowledgements

We extend our gratitude to Assoc. Prof. Ana Azinović Bebek, PhD, head of the research, and to Sebastijan Stingl, PhD, for providing information on the grave context and for granting access to the research data, thereby making an important contribution to the completion of this study.

*Translation and proof-reading:
ETNOtrend d.o.o.*

⁷⁵ ŠLAUS, NOVAK, ČAVKA 2012.

⁷⁵ ŠLAUS, NOVAK, ČAVKA 2012.

LITERATURA / BIBLIOGRAPHY

- ARRIAZA, B. T. 1993, Seronegative Spondyloarthropathies and Diffuse Idiopathic Skeletal Hyperostosis in Ancient Northern Chile, *American Journal of Physical Anthropology*, 91, 263–278.
- AUFDERHEIDE, A. C., RODRÍGUEZ-MARTÍN, C. 1998, *The Cambridge Encyclopedia of Human Paleopathology*, Cambridge: Cambridge University Press.
- AZINOVIĆ BEBEK, A. 2007, Žumberak – crkva sv. Nikole biskupa, *Hrvatski arheološki godišnjak*, 3/2006, 184–185.
- AZINOVIĆ BEBEK, A. 2009, Novovjekovni nalazi u grobovima 17. i 18. stoljeća oko crkve sv. Nikole biskupa u Žumberku, *Vjesnik Arheološkog muzeja u Zagrebu*, 42(1), 463–488.
- AZINOVIĆ BEBEK, A. 2011, Žumberak – crkva sv. Nikole biskupa, *Hrvatski arheološki godišnjak*, 7/2010, 293–295.
- AZINOVIĆ BEBEK, A. 2012, Žumberak – crkva sv. Nikole biskupa, *Hrvatski arheološki godišnjak*, 8/2011, 292–293.
- AZINOVIĆ BEBEK, A. 2013, Žumberak – crkva sv. Nikole biskupa, *Hrvatski arheološki godišnjak*, 9/2012, 333–335.
- AZINOVIĆ BEBEK, A. 2014, Lokalitet: Žumberak – crkva sv. Nikole biskupa, *Hrvatski arheološki godišnjak*, 10/2013, 251–253.
- AZINOVIĆ BEBEK, A. 2015, Žumberak – crkva sv. Nikole biskupa, *Hrvatski arheološki godišnjak*, 11/2014, 272–275.
- AZINOVIĆ BEBEK, A. 2017, Arheološka istraživanja, u/in: *Crkva sv. Nikole biskupa u Žumberku*, Azinović Bebek, A. (ur./ed.), Zagreb: Hrvatski restauratorski zavod, 32–51.
- AZINOVIĆ BEBEK, A., JANEŠ, J. 2016, Groblje oko crkve sv. Nikole biskupa u Žumberku, u/in: *Groblja i pogrebni običaji u srednjem i ranom novom vijeku na prostoru sjeverne Hrvatske*, Krznar, S., Sekelj Ivančan, T., Tkalčec, T. Belaj, J. (ur./ed.), Zagreb: Institut za arheologiju, 123–139.
- BASS, W.M., GREGG, J.B., PROVOST, P.E. 1974, Ankylosing spondylitis (Marie Strumpel disease) in historic and prehistoric Northern Plains Indians. *Plains Anthropological Society*, 19:303–305.
- BENNETT, D. L., OHASHI, K., EL-KHOURY, G. Y. 2004, Spondyloarthropathies: Ankylosing Spondylitis and Psoriatic Arthritis, *Radiologic Clinics of North America*, 42, 121–134.
- BETTENCOURT, B. F., FORONI, I., COUTO, A. R., LIMA, M., BRUGES-ARMAS, J. 2015, Genetics in Ankylosing Spondylitis—Beyond HLA-B*27, u/in: *Clinical and Molecular Advances in Ankylosing Spondylitis*, Bruges-Armas, J. (ur./ed.), Croatia: InTech, 103–134.
- BONCZAROWSKA, J. H., WYSOCKA, J., DRUPKA, B., DA SILVA, N. A., KRAUSE-KYORRA, B., KRZEPKOWSKI, M. 2025, The Outcasts, the Sick, and the Undead: Atypical Burials of the Late Medieval to Modern Greater Poland, *Scientific Reports*, 15(1). doi: 10.1038/s41598-025-04425-2.
- BOURKE, J. B. 1971, The palaeopathology of the vertebral column in Ancient Egypt and Nubia, *Medical History*, 15, 363–375.
- BROWN, M. A. 2008, Breakthroughs in Genetic Studies of Ankylosing Spondylitis, *Rheumatology*, 47, 132–137.
- BUIKSTRA, J. E., UBELAKER, D. H. 1994, *Standards for Data Collection from Human Skeletal Remains*, Fayetteville: Arkansas Archeological Survey Research Series No. 44.
- CAMPBELL, C. J., PAPADEMETRIOU, T., BONWGLIO, M. 1968, Melorheostosis, *Journal of Bone and Joint Surgery (American Volume)*, 50A, 1281–1304.

- CAWLEY, W. D., PAINE, R. R. 2015, Skeletal Indicators of Reactive Arthritis: A Case Study Comparison to Other Skeletal Conditions, Such as Rheumatoid Arthritis, Ankylosing Spondylitis, Ankylosing Sero-negative SpA, and DISH, *International Journal of Paleopathology*, 12, 70–74. doi: 10.1016/j.ijpp.2015.10.001.
- DE KEYSER, F., BAETEN, D., VAN DEN BOSCH, F., DE VOS, M., CUVELIER, C., MIELANTS, H., VEYS, E. 2002, Gut Inflammation and Spondyloarthropathies, *Current Rheumatology Reports*, 4, 525–532.
- DENKO, C. W., MALEMUD, C. J. 2006, Body Mass Index and Blood Glucose: Correlations with Serum Insulin, Growth Hormone, and Insulinlike Growth Factor-1 Levels in Patients with Diffuse Idiopathic Skeletal Hyperostosis (DISH), *Rheumatology International*, 26, 292–7.
- DIVECHA, H., SATTAR, N., RUMLEY, A., CHERRY, L., LOWE, G. D., STURROCK R. 2005, Cardiovascular Risk Parameters in Men with Ankylosing Spondylitis in Comparison with Noninflammatory Control Subjects: Relevance of Systemic Inflammation, *Clinical Science*, 109, 171–176.
- DUYAR, I. 2019, A Case of Ankylosing Spondylitis from the Excavations at Kılıçlı Necropolis (Sinope, Northern Turkey) and its Implications on the Antiquity of the Disease in Anatolia, *International Journal of Osteoarchaeology*, 29(6), 1100–1108. doi: 10.1002/oa.2823.
- ELYAN, M., KHAN, M. A. 2006, Diagnosing Ankylosing Spondylitis, *The Journal of Rheumatology*, 33(Suppl. 78), 12–23.
- ETHUNANDAN, M., KHOSLA, N., TILLEY, E., WEBB, A. 2004, Melorheostosis Involving the Craniofacial Skeleton, *Journal of Craniofacial Surgery*, 15, 1062–1065.
- FALYS, C. G., PRANGLE, D. 2015, Estimating Age of Mature Adults from the Degeneration of the Sternal End of the Clavicle, *American Journal of Physical Anthropology*, 156(2), 203–214. doi: 10.1002/ajpa.22639.
- FEDORINA, A., DOBROVOLSKAYA, M., KRASNIKOVA, A., SHPOLYANSKIY, S., GUSEVA, V., KORZHIKOVA, E. 2022, Caring for the Sick in a Medieval Rural Community: A Study Based on Paleopathological and Archaeological Data from Medieval Rus', *International Journal of Paleopathology*, 37, 30–40.
- FELDTKELLER, E., LEMMEL, E.M., RUSSELL, A.S. 2002, Ankylosing spondylitis in the pharaohs of ancient Egypt, *Rheumatology International*, 23:1–5.
- FORESTIER, J., ROTES-QUEROL, J. 1950, Senile Ankylosing Hyperostosis of the Spine, *Annals of the Rheumatic Diseases*, 9, 321–330.
- FOX, D. 2001, Etiology and Pathogenesis of Rheumatoid Arthritis, u/in: *Arthritis and Allied Conditions*, Koopman, W. (ur./ed), Philadelphia: Lippincott Williams and Wilkins, 1085–1102.
- GALOVÁ, J., TOKOĽOVÁ, S., PETREJČÍKOVÁ, E., TAJKOV, P., BALOGH, Á., CHMELÍK, M., SLOVÁKOVÁ, P., BOROŇOVÁ, I., 2022, Ankylosing Spondylitis on Unidentified Individual from Early Modern Times Found in Reformed Church (Silická Brezová, Slovakia): a Case-based Review, *Rheumatology International*, 42, 1873–1881. doi: 10.1007/s00296-022-05155-8.
- HOANG, V. T., VAN, H. A. T., CHANSOMPHOU, V., TRINH, C. T. 2020, The Dripping Candle Wax Sign of Melorheostosis, *SAGE Open Medical Case Report*, 8, doi: 10.1177/2050313X20940564.
- IORDACHE, S., CURSARU, A., ȘERBAN, B., COSTACHE, M., SPIRIDONICĂ, R., CREȚU, B., CÎRSTOIU, C. 2023, Melorheostosis: A Review of the Literature and a Case Report, *Medicina*, 59(5), 869. doi: 10.3390/medicina59050869.
- JANEŠ, A. 2017, Keramički, stakleni i metalni nalazi, u/in: *Crkva sv. Nikole biskupa u Žumberku*, Azinović Bebek, A. (ur.), Zagreb: Hrvatski restauratorski zavod, 52–61.

- KALBERMATTEN, N. T., VOCK, P., RÜFENACHT, D., ANDERSON, S. E. 2001, Progressive Melorheostosis in the Peripheral and Axial Skeleton with Associated Vascular Malformations: Imaging Findings Over Three Decades, *Skeletal Radiology*, 30, 48–52.
- KANG, H., JHA, S., IVOVIC, A., FRATZL-ZELMAN, N., DENG, Z., MITRA, A., CABRAL, W. A., HANSON, E. P., LANGE, E., COWEN, E. W., *et al.* 2020, Somatic SMAD3-activating Mutations Cause Melorheostosis by Up-Regulating the TGF- β /SMAD Pathway, *Journal of Experimental Medicine*, 217, e20191499.
- KHAN, M. A. 1998, Spondyloarthropathies. Ankylosing Spondylitis: Clinical Features, u/in: *Rheumatology*, 2nd edn., Klippel, J., Dieppe, P. (ur./eds.), London: Mosby, 1–10.
- KHAN, M. A. 2002, Spondyloarthropathies, u/in: *Atlas of Rheumatology*, Hunder G. G. (ur./ed.), Philadelphia: Current Medicine, 141–167.
- KHAN, M. A. 2003, Clinical Features of Ankylosing Spondylitis, u/in: *Rheumatology*, Hochberg M., Silman A., Smolen J., Weinblatt M., Weinblatt M. (ur./eds.), London: Mosby: A Division of Harcourt Health Sciences Ltd, 1161–1181.
- KHUDAVERDYAN, A. Y., DEVEJYAN, S. H., DAVTYAN, R. H., YENGIBARYAN, A. A., HOVHANESYAN, A. A., VARDANYAN, S. A. 2021, Female with Ankylosing Spondylitis From the 7th–6th century BCE Lori Berd burial (Armenia), *Anthropological Review*, 84(1), 85–100. doi: 10.2478/anre-2021-0005.
- KLALES, A. R., OUSLEY, S. D., VOLLNER, J. M. 2012, A Revised Method of Sexing the Human Innominate Using Phenice's Nonmetric Traits and Statistical Methods, *American Journal of Physical Anthropology*, 149, 104–114.
- KRAMAR, C. 1981, A case of ankylosing spondylitis in Medieval Geneva, *Ossa*, 8, 115–129.
- LAZA, I. M., HERVELLA, M., DE-LA-RUA, C. 2016, Genetic markers in a medieval case of ankylosing spondylitis, *Journal of Rheumatology*, 43, 679–681.
- LEDEN, I., GÖTHERSTRÖM, A., DRENZEL, L., SVENSSON, B. 2009, HLA-B27 sequences identified in a medieval skeleton with ankylosing spondylitis, *Annals of the Rheumatic Diseases*, 68, 757–758.
- LOVEJOY, C. O., MEINDL, R. S., PRYZBECK, T. R., MENSFORTH, R. P. 1985, Chronological Metamorphosis of the Auricular Surface of the Ilium: A New Method for the Determination of Age at Death, *American Journal of Physical Anthropology*, 68: 15–28.
- LUNARDINI, A., MINOZZI, S., CATALANO, P., CARAMELLA, D., FORNACIARI, G. 2008, A severe case of ankylosing spondylitis from the Roman Imperial Age (I-II century AD), *Journal of Paleopathology*, 20, 29–35.
- OLIVIERI, I., BAROZZI, L., PADULA, A., DE MATTEIS, M., PAVLICA, P. 1998, Clinical Manifestations of Seronegative Spondylarthropathies, *European Journal of Radiology*, 27 (Suppl 1), S3–6.
- OLIVIERI, I., D'ANGELO, S., PALAZZI, C., PADULA, A., MADER, R., KHAN, M. A. 2009, Diffuse Idiopathic Skeletal Hyperostosis: Differentiation from Ankylosing Spondylitis, *Current Rheumatology Reports*, 11, 321–328.
- ORTNER, D. J., PUTSCHAR, W. G. J. 1981, *Identification of Pathological Conditions in Human Skeletal Remains*, Smithsonian Contributions to Anthropology No. 28. Washington, DC: Smithsonian Institution Press.
- ORTNER, D. J. 2003, *Identification of pathological conditions in human skeletal remains*, 2nd edition, San Diego: Academic Press.
- PÁLFI, G. Y., PANUEL, M., GYETVAI, A., MOLNÁR, E., BENDE, L., DUTOUR, O. 1996, Advanced-stage ankylosing spondylitis in a subject in the 8th century, *Journal of Radiology*, 77, 283–285.

- PAPARO, F., RAVELLI, M., SEMPRINI, A., CAMELLINO, D., GARLASCHI, A., CIMMINO, M. A., ROLLANDI, G. A., LEONE, A. 2014, Seronegative Spondyloarthropathies: What Radiologists Should Know, *Journal of Radiology and Medicine Imaging*, 119, 156–163.
- PAVELKA, K., ŠENOLT, L., VENCOVSKY, J., *et al.* 2020, *Revmatologie*, u/in: *Interna*, Češka R. (ur./ed.), Praha: Triton, 659–713.
- PFEIFFER, S. 1991, Estimation of Age at Death, u/in: *An Investigation of a Military Cemetery from the War of 1812*, Pfeiffer, S., Williamson, S. R. (ur./eds.), Toronto: Dundurn Press, 167-175.
- PHENICE, T. W. 1969, A Newly Developed Visual Method of Sexing the Os Pubis, *American Journal of Physical Anthropology*, 30, 297–301.
- RADU, A. F., BUNGAU, S. G. 2021, Management of Rheumatoid Arthritis: An Overview, *Cells*, 10, 2857. doi: 10.3390/cells10112857.
- RASHID, T., WILSON, C., EBRINGER, A. 2013, The Link Between Ankylosing Spondylitis, Crohn's Disease, *Klebsiella*, and Starch Consumption, *Clinical and Developmental Immunology*, 2013, 872632. doi: 10.1155/2013/872632.
- RESNICK, D. 1974, Patterns of Peripheral Joint Disease in Ankylosing Spondylitis, *Radiology*, 110(3), 523–532.
- RESNICK, D., NIWAYAMA, G. 1988, *Diagnosis of Bone and Joint Disorders*, 2nd edn., Philadelphia: Saunders.
- RESNICK, D. 1989, Inflammatory Disorders of the Vertebral Column: Seronegative Spondyloarthropathies, Adult-Onset Rheumatoid Arthritis, and Juvenile Chronic Arthritis, *Clinical Imaging*, 13(4), 253–268.
- ROBERTS, C., MANCHESTER, K. 2005, *The Archaeology of Disease*, 3rd edn., Ithaca: Cornell University Press.
- ROGERS, J., WALDRON, T., DIEPPE, P., WATT, I. 1987, Arthropathies in Palaeopathology: the Basis of Classification According to most Probable Cause, *Journal of Archaeological Science*, 14, 179–193. doi: 10.1016/0305-4403(87)90005-7.
- ROGERS, J., WALDRON, T. 1995, *A Field Guide to Joint Disease in Archaeology*, New York: John Wiley & Sons, Inc.
- ROGERS, J., WALDRON, T. 2001, DISH and the Monastic Way of Life, *International Journal of Osteoarchaeology*, 11(5), 357–365. doi: 10.1002/oa.574.
- MARTEL, W. 1979, Radiological Manifestations of Reiter's Syndrome, *Annals of the Rheumatic Diseases*, 38, 12–23.
- MEINDL, R. S., LOVEJOY, C. O. 1985, Ectocranial Suture Closure: A Revised Method for the Determination of Skeletal Age at Death Based on the Lateral-Anterior Sutures, *American Journal of Physical Anthropology*, 68, 57–66.
- OCAMPO, D. V., GLADMAN, D. D. 2019, Psoriatic Arthritis, *F1000Research*, 8 (F1000 Faculty Rev), 1665. doi: 10.12688/f1000research.19144.1.
- SAN-MILLÁN, M., TURBON, D., RISSECH, C. 2017, New Approach to Age Estimation of Male and Female Adult Skeletons Based on the Morphological Characteristics of the Acetabulum, *International Journal of Legal Medicine*, 131(2).
- SARIGU, M., FLORIS, G. U., FLORIS, R. 2012, Sardinian museum of anthropology and ethnography: A case of ankylosing spondylitis from Sardinia, *Journal of Biological Research*, 85, 254–255.
- SEKULIĆ, P. 2017, Poglavlje o području Žumberačkog gorja u razdoblju kasnog srednjeg i ranog novog vijeka, u/in: *Crkva sv. Nikole biskupa u Žumberku*, Azinović Bebek, A. (ur./ed.), Zagreb: Hrvatski restauratorski zavod, 14–19.

- SIEPER, J., BRAUN, J., RUDWALEIT, M., BOONEN, A., ZINK, A. 2002, Ankylosing Spondylitis: an Overview, *Annals of the Rheumatic Diseases*, 61(Suppl. 3), iii8–18.
- SIEPER, J., PODDUBNYI, D. 2017, Axial Spondyloarthritis, *The Lancet*, 390, 73–84.
- SOKER, G., GULEK, B., TUFAN, M. A., SOKER, E., KELLE, O. A. B. 2014, Early diagnosis of hip joint involvement of ankylosing spondylitis using magnetic resonance imaging in the absence of clinical and x ray findings, *Archives of Rheumatology*, 29, 99-104.
- SOKER, G., BOZKIRLI, E. D., SOKER, E., GULEK, B., ARSLAN, M., MEMIS, D., YILMAZ, C. 2016, Magnetic Resonance Imaging Evaluation of Shoulder Joint in Patients with Early Stage of Ankylosing Spondylitis: A Casecontrol Study, *Diagnostic Interventional Imaging*, 97, 419–424.
- ŠLAUS, M. 2006, *Bioarheologija. Demografija, zdravlje, traume i prehrana starohrvatskih populacija*, Zagreb: Školska knjiga.
- ŠLAUS, M., NOVAK, M., ČAVKA, M. 2012, Four Cases of Ankylosing Spondylitis in Medieval Skeletal Series from Croatia, *Rheumatology International*, 32, 3985–3992. doi:10.1007/s00296-011-2343-7.
- TAUROG, J. D., GENSLER, L. S., HAROON, N. 2022, Spondyloarthritis, u/in: *Harrison's Principles of Internal Medicine*, McGraw Hill LLC, 2790–2801.
- TSAI, W. C. 2012, HLA-B27 and Ankylosing Spondylitis, u/in: *Clinical and Molecular Advances in Ankylosing Spondylitis*, Bruges-Armas J. (ur./ed.), Croatia: InTech, 73–84.
- VAN DER LINDEN, S., VAN DER HEIJDE, D. 1998, Ankylosing Spondylitis: Clinical Features, *Rheumatic Disease Clinics of North America*, 24, 663–676.
- VAN DER LINDEN, S., VAN DER HEIJDE, D., BRAUN, J. 2005, Ankylosing spondylitis, u/in: *Kelley's textbook of rheumatology*, 7th ed., Harris, E. J., Budd R., Firestein G. S., Genovese M. C., Sergent J. S., Sledge C. B. (ur./eds.), Philadelphia: Elsevier Saunders, 1125–1141.
- VENTADES, N. G., LAZA, I. M., HERVELLA, M., DE-LA-RÚA, C. 2018, A Recording Form for Differential Diagnosis of Arthropathies, *International Journal of Paleopathology*, 20, 45–49. doi:10.1016/j.ijpp.2018.01.004.
- VERLAAN, J. J., ONER, F. C., MAAT, G. J. R. 2007, Diffuse Idiopathic Skeletal Hyperostosis in Ancient Clergymen, *European Spine Journal*, 16(8), 1129–1135. doi:10.1007/s00586-007-0342-x.
- WALDRON, T. 2009, *Paleopathology*, Cambridge: Cambridge University Press.
- WALKER, P. L. 2008, Sexing Skulls Using Discriminant Function Analysis of Visually Assessed Traits, *American Journal of Physical Anthropology*, 136(1), 39–50. doi: 10.1002/ajpa.20776.
- WHITE, T. D., BLACK, M. T., FOLKENS, P. A. 2011, *Human Osteology*, 3rd edn., San Diego: Academic Press.
- WOLF, J. 2012, Clinical Features of Ankylosing Spondylitis, u/in: *Clinical and Molecular Advances in Ankylosing Spondylitis*, Bruges-Armas J. (ur./ed.), Croatia: InTech, 15–26.
- ZIMMERMAN, M., KELLEY, M. 1982, *Atlas of Human Paleopathology*, New York: Praeger.