

A Case of Porokeratosis Ptychotropica Treated with Cryotherapy

Porokeratosis encompasses a group of dermatoses characterized by marked keratinization of epidermis with distinct histological identification of cornoid lamellae of invaginated epidermis (1).

Porokeratosis ptychotropica is a rare variant of porokeratosis, presenting as one or more red or brown plaques in the intergluteal and genital areas (2). Affecting predominantly adult men, it remains as uncommon as it is unexplained, with sporadic appearance and unknown physiopathology (3).

Diagnosis is based on histology and therapeutic approaches used include topical corticosteroids, systemic retinoids, imiquimod, 5-fluorouracil, laser therapy and cryotherapy (2,4). However, resistance to treatment and recurrences are very frequent, and treatment results are often poor (4). We report a case of porokeratosis ptychotropica successfully treated with cryotherapy.

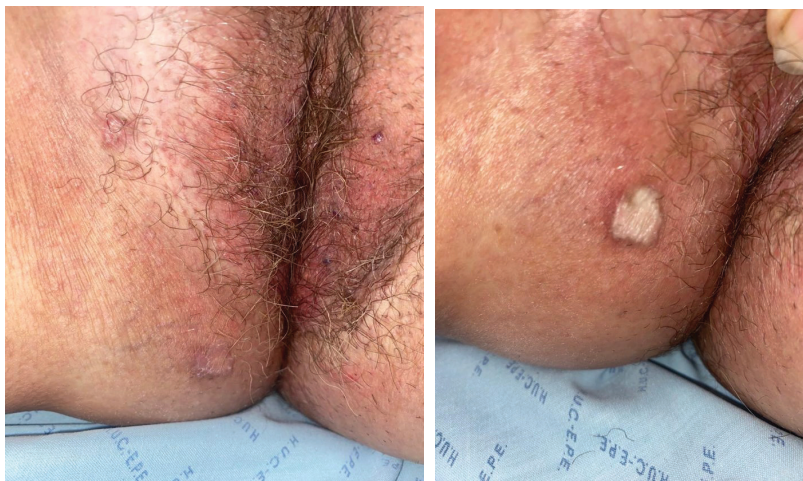A 76-year-old female with no prior relevant history was referred due to a one-year-long history of cutaneous lesions in the intergluteal region which had not responded to topical or oral antifungal. On observation, she presented two annular erythematous lesions in the right perivulvar and intergluteal region, with 1 and 2 cm of diameter, respectively (Figures

1 a and b). The lesions presented elevated margins, coarse on palpation, with central superficial scaling, associated with moderate pruritus (Figure 2). No other relevant findings were apparent on examination.

An incisional biopsy of the larger lesion was performed. Histological examination showed moderately acanthotic and slightly irregular epidermis which contained a narrow cornoid lamella with a small column of parakeratosis, sitting on an area of hypogranulosis with dyskeratotic keratinocytes (Figure 3).

Based on these findings, a diagnosis of porokeratosis ptychotropica was established. Two cycles of cryotherapy were performed (20 seconds per lesion). On follow-up, total resolution of lesions was observed, with residual hypopigmentation without significant scarring being observed.

Porokeratosis ptychotropica (also known as verrucous porokeratosis of the gluteal cleft) is a rare, idiopathic disorder first described in 1995 by Luckert *et al.*, characterized by appearance of porokeratosis lesions in the gluteal or genital regions⁵. These are typically reddish-brown verrucous papules and plaques, which coalesce, expand centrally and may develop peripheral satellite lesions or porokeratosis in other areas, and which are typically pruriginous (2,6). It



Figures 1 a and b. Erythematous lesions in perivulvar and intergluteal region

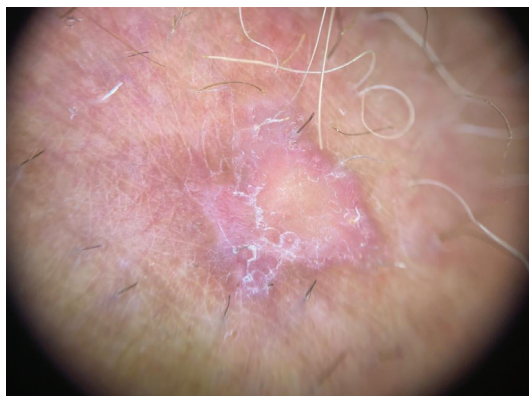

Figure 2. Elevated, erythematous margin with central superficial scaling.

has a marked male predominance, corresponding to >90% cases reported in clinical case series, and affects mainly adults (7). Case presentation is typically sporadic, but familial distribution suggesting an autosomal dominant transmission has been described in some cases (7).

Lesions typically have a chronic course, persisting for years prior to a diagnosis is established. Clinical differential diagnosis includes psoriasis, which porokeratosis ptychotropica often emulates, acrodermatitis enteropathica, lichen planus verrucosus, and tuberculosis verrucosa cutis. Lesion biopsy is essential to establish a diagnosis, exclude other differentials and rule out malignant transformation, which can occur in up to 7.5% of porokeratotic lesions, most frequently as squamous cell carcinoma^{7,8}. Histological examination reveals a digitate epidermis with parakeratosis columns over keratinocytes, as well as dyskeratotic keratinocytes and hypogranulosis. Multiple concentric cornoid lamellae combined with digitate epidermis is the hallmark of porokeratosis ptychotropica.

Therapeutic options are controversial and include topical corticosteroids, topical tacrolimus, PUVA, systemic retinoids, imiquimod, 5-fluorouracil, CO₂ or excimer laser therapy, and cryotherapy^{2,4}. Results are generally poor, with frequent persistence of lesions, recurrence after an initially successful treatment is also common (6,7).

We report an extremely rare case of porokeratosis ptychotropica affecting a female patient. This case is also unique due to the successful treatment of the lesions with cryotherapy; further case series using this treatment option may validate it as an acceptable standard treatment for small lesions of porokeratosis ptychotropica.

References

1. Browning, J. *Dermatology* Edited by Jean L. Bolog-

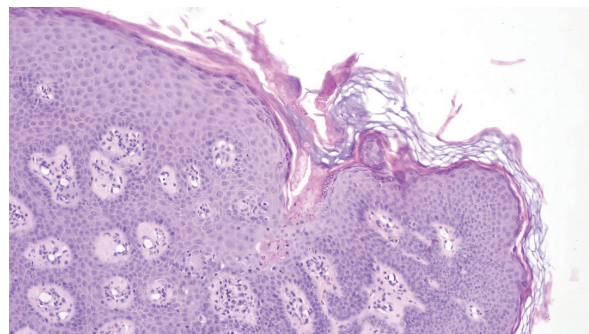


Figure 3. Moderately acanthotic and irregular epidermis with narrow cornoid lamella and small column of parakeratosis.

- nia Julie V. Schaffer Lorenzo Cerroni Fourth edition China: Elsevier, 2018, ISBN 978-0-7020-6275-9
2. Yeo J, Winhoven S, Tallon B. Porokeratosis ptychotropica: a rare and evolving variant of porokeratosis. *J Cutan Pathol.* 2013;40(12):1042-7.
3. Liu W, Liu JW, Ma DL. Porokeratosis Ptychotropica. *JAMA Dermatol.* 2019;155(7):845.
4. Wang Q, Wan H, Liu W, Zhang L. Porokeratosis ptychotropica: A giant lesion in a Chinese man. *Australas J Dermatol.* 2017;58(3):e149-e150.
5. Lucker GP, Happle R, Steijlen PM. An unusual case of porokeratosis involving the natal cleft: porokeratosis ptychotropica? *Br J Dermatol.* 1995;132(1):150-1.
6. Tebet AC, Oliveira TG, Oliveira AR, Moriya FS, Oliveira J Filho, Cucé LC. Porokeratosis ptychotropica. *An Bras Dermatol.* 2016;91(5 suppl 1):134-136.
7. Takiguchi RH, White KP, White CR Jr, Simpson EL. Verrucous porokeratosis of the gluteal cleft (porokeratosis ptychotropica): a rare disorder easily misdiagnosed. *J Cutan Pathol.* 2010;37(7):802-7.
8. Ryoo YW, Kim Y, Yun JM, Kim SA. Porokeratosis ptychotropica: a case report. *J Yeungnam Med Sci.* 2022 5. doi: 10.12701/jyms.2022.00549. Epub ahead of print.

**Duarte Flor, Joana Xara, Francisco Martins,
Ines Courinho, Jose Carlos Cardoso**

Centro Hospitalar e Universitário de Coimbra, EPE

Corresponding author:

Duarte Flor

Centro Hospitalar e Universitário de Coimbra
Rua Carlos Alberto Correia Ribeiro, Lote A9, Lagoa, Lagoa, Portugal
djnflor@gmail.com