

MR-HSG as a safe, reliable, and underused method

Barbara Škrabal¹, Tihana Šitum¹, Daniel Čorak¹, Domagoj Dokozić², Krešimir Musić², Nikola Gotovac^{1,3}

¹ Department of Clinical Radiology, Požega County General Hospital, Požega, Croatia

² Department of Gynecology and Obstetrics, Požega County General Hospital, Požega, Croatia

³ Faculty of Dental Medicine and Health, Osijek, Croatia

Corresponding author: Barbara Škrabal, email: barbara.skrabal.1@gmail.com

DOI: [10.55378/rv.50.1.2](https://doi.org/10.55378/rv.50.1.2)

Abstract

Introduction: Hysterosalpingography (HSG) is the gold standard for assessing fallopian tube patency, but it involves ionizing radiation and iodinated contrast medium. Magnetic resonance hysterosalpingography (MR-HSG) allows assessment of tubal patency without ionizing radiation, while offering superior visualization of pelvic soft tissues.

Aim: To evaluate the diagnostic value of MR-HSG in assessing fallopian tube patency, with particular emphasis on the MRI protocol, and to compare the findings with those obtained using conventional HSG.

Materials and methods: Fifty patients were included. All underwent MR-HSG followed immediately by HSG. During MR-HSG, a diluted gadolinium contrast solution was administered in the uterine cavity. The protocol consisted of T2-weighted sequences and dynamic T1-weighted imaging. The presence of contrast solution adjacent to the ovaries and in the pouch of Douglas was recorded as an indicator of tubal patency. Agreement between the methods was assessed using Cronbach's alpha coefficient.

Results: Bilateral tubal occlusion was confirmed in 6 cases (12%). Cronbach's alpha demonstrated excellent agreement between the methods (0.97 for the left ovary; 0.84 for the right ovary; 0.80 for the pouch of Douglas). No adverse effects were observed.

Conclusion: MR-HSG is an effective, well-tolerated method with high agreement with HSG. Its advantages include the absence of ionizing radiation and superior visualization of pelvic soft tissues. MR-HSG may be considered a reliable alternative to HSG.

Keywords: MR-HSG, HSG, tubal patency, MRI, gadolinium contrast, infertility, pelvic imaging

Introduction

Hysterosalpingography (HSG) is a radiological diagnostic procedure used to evaluate fallopian tube patency and uterine morphology in the clinical assessment of women with primary or secondary infertility [1,2]. Unlike HSG, which uses ionizing radiation, and sonohysterosalpingography (US HSG), which uses ultrasound, magnetic resonance imaging can also be used to visualize tubal patency and uterine morphology (MR-HSG) [2–9]. MR-HSG is performed without ionizing radiation following intrauterine administration of a gadolinium-based contrast agent. MR-HSG enables detailed evaluation of the uterus, fallopian tubes, ovaries, and surrounding structures [3,10]. This study aimed to demonstrate how the dynamic nature of MR-HSG enables assessment of tubal patency comparable to that obtained with conventional HSG.

Materials and methods

The study included 50 patients referred for MR-HSG (Airis II, Hitachi, Japan; Aera, Siemens Healthineers, Germany) as part of an infertility evaluation, followed immediately by conventional HSG. HSG was performed on a digital radiography/fluoroscopy (DRF) system (Axiom Luminos dRF, Siemens Healthineers, Germany) using an iodinated contrast agent (iobitridol; Xenetix 350 mg I/mL; Guerbet, France). To facilitate direct comparison, MR-HSG and HSG were performed within 10 minutes of each other.

The study was conducted at Požega County General Hospital, Croatia, between 2012 and 2015. Initial data collection began in 2012, and the cohort was subsequently expanded through additional patient enrolment during the study period. Written informed consent was obtained from all participants. Ethics committee approval was granted in 2012, prior to study initiation, and covered

both the preliminary dataset presented at ECR 2014 and the expanded dataset analysed in the present study.

All images were obtained at the Department of Radiology, Požega County General Hospital, Croatia.

Patients

The primary indication for HSG is the evaluation of female infertility. Infertility, according to the World Health Organization, is defined as the inability to achieve a pregnancy after 12 months of regular unprotected sexual intercourse [11]. MRI is also used when uterine or tubal anatomical/pathological abnormalities are suspected, including fibroids, polyps, adenomyosis, and congenital malformations [2,3,8,10]. Only women with primary infertility were included in this study.

Preparation of the contrast solution

For MR-HSG, a diluted gadolinium contrast solution was prepared by adding 1 mL of gadolinium contrast agent (gadoteric acid; Dotarem, 0.5 mmol/mL; Guerbet, France) to 100 mL of normal saline. During imaging, 10–40 mL of the prepared solution was administered into the uterine cavity using a 50-mL syringe in three separate aliquots, allowing real-time assessment of contrast passage through the fallopian tubes and reducing discomfort during injection. Although automated pump injection is possible, for safety and practical reasons, we did not use this approach. The solution was warmed to 37 °C to improve patient comfort.

Patient preparation

The examination is scheduled during the follicular phase of the menstrual cycle, most commonly between days 7 and 10 to minimize artifacts related to endometrial thickening and to exclude pregnancy [12].

The procedure is preceded by gynaecologic preparation, including placement of an intrauterine balloon catheter and inflation of the balloon with saline. Correct catheter placement is confirmed by ultrasound. Patients should be instructed to empty the urinary bladder before MR imaging. Rectal gas typically does not produce significant artifacts at 1.5T; however, bowel preparation is recommended at 3T and higher field strengths.

The patient is positioned supine on the scanner table. A syringe filled with 50 mL of the prepared contrast solution is connected to the intrauterine catheter. Imaging is performed using a multichannel flexible body coil, as in standard pelvic MRI examinations.

MRI acquisition protocol

T2-weighted sequences

T2-weighted sequences are acquired first for anatomical orientation and assessment of the uterus and ovaries, including the endometrium and myometrium, as well as the fallopian tubes and surrounding pelvic structures. They are particularly useful for detecting fibroids, adenomyosis, hydrosalpinx, and congenital or other uterine malformations. Due to their high sensitivity to fluid, they are also

helpful in identifying free pelvic fluid that may be present prior to contrast administration. Imaging is initially performed in the sagittal plane (Figure 1). Subsequent acquisitions are then planned in an oblique transverse (axial) or coronal plane to optimize visualization of the uterus and ovaries, ideally including all three structures within a single imaging block.

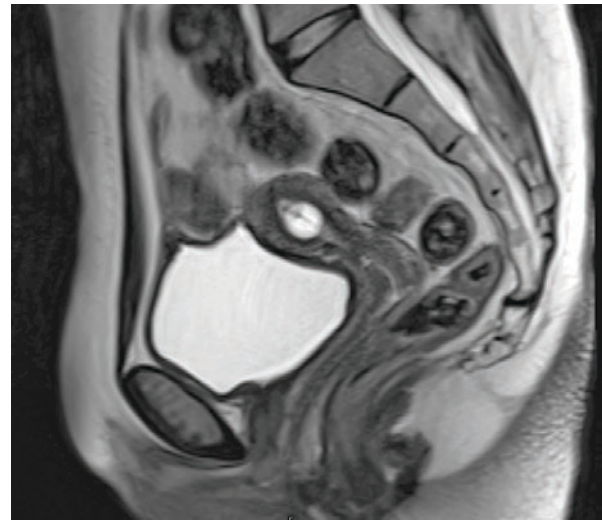


Figure 1. Sagittal T2-weighted image of the uterus demonstrating the catheter balloon within the uterine cavity.

Dynamic T1-weighted sequences

MR-HSG uses serial imaging during contrast administration. Imaging is performed in an oblique plane as described above. Repeated acquisitions with contrast injection during short pauses provide better insight into tubal patency, i.e., spillage of contrast into the pelvic cavity. Heavily T1-weighted sequences (Figure 2), similar to angiographic sequences, are typically used.

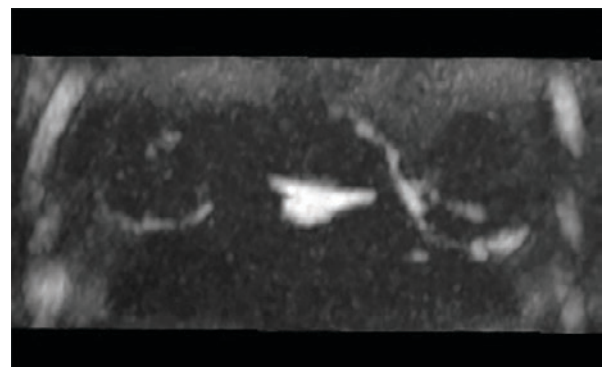


Figure 2. 3D T1-weighted image showing the contrast solution within the uterine cavity and around the ovaries after intrauterine administration through the catheter.

T1 sequences after contrast administration

After completion of contrast administration, an additional 3D T1 gradient-echo sequence (with Dixon or other fat-suppression technique) is acquired in the coronal plane

(Figure 3). This sequence uses a larger field of view (FOV) than the dynamic acquisition. It does not need to be obtained in oblique planes, given its high spatial resolution and suitability for multiplanar reconstructions. Since the contrast solution is administered intrauterinely rather than intravenously, imaging can be repeated if necessary (in the presence of artifacts).

This sequence is useful for depicting contrast retained within the fallopian tubes; the presence of contrast within the lumen or the tubal wall may suggest pathological changes such as hydrosalpinx, chronic inflammation, or obstruction.

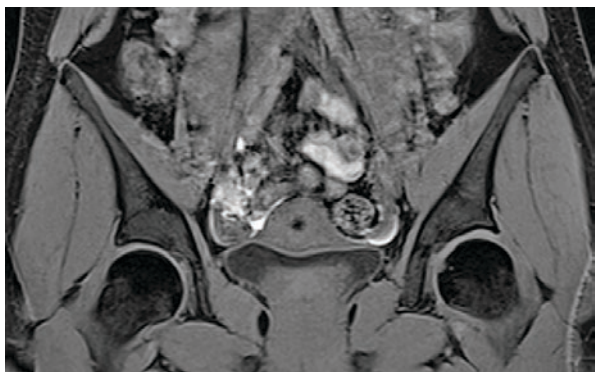

Figure 3. Visualization of the uterus (with the catheter balloon visible), the ovaries, and the contrast solution surrounding them using a 3D T1 technique in the coronal plane.

Additional sequences in MR-HSG

In addition to the standard protocol, MR-HSG may also include 2D T1 SE FS sequences, STIR, or T2 SE sequences with motion-artifact suppression techniques (BLADE, PROPELLER, etc.), depending on artifacts from bowel motion or arterial pulsation, clinical findings, or suspicion of associated pathology. Their use is not routine; rather, they are applied selectively when there is concern for additional pathology beyond the basic assessment of tubal patency.

The decision to include these sequences depends on the individual clinical scenario and is intended to increase diagnostic yield. MRI provides very good to excellent visualization of uterine and ovarian structures in many pathological conditions, and in such cases, these additional sequences should be utilized. If there is no indication, they are avoided to prevent unnecessary prolongation of the examination.

Completion of the examination

After imaging, the catheter balloon is deflated using a syringe (filled with 1–2 mL of saline), and the catheter is gently removed. Although catheter removal is not mandatory, we recommend it to reduce the risk of discomfort. The patient is then observed for about 10 minutes (usually in the outpatient gynaecology clinic) and discharged home.

Outcome measures

The primary outcome measure was assessment of tubal patency on MR-HSG and HSG by recording the presence of

contrast solution adjacent to the ovaries and in the pouch of Douglas, and analysis of agreement between the methods using Cronbach's alpha coefficient.

Data collection and analysis

Each patient underwent MR-HSG followed by conventional HSG, allowing direct comparison of tubal patency. Data on contrast presence in the pouch of Douglas and around the left and right ovaries were recorded during both procedures. Measurements were performed by a radiologist with more than 15 years of experience. Results were entered into a table for further analysis. Statistical analysis was performed using MedCalc (MedCalc Software Ltd., Ostend, Belgium); for each parameter, Cronbach's alpha was calculated as a measure of internal consistency.

Results

In total, 52 women with primary infertility consented to MR-HSG followed by HSG. In one patient, the catheter was mistakenly placed in the vagina, and one patient withdrew during the procedure; both were excluded (4%). Bilateral tubal occlusion was recorded in 6 patients (12%). Among these, five reported more intense pain during contrast administration, as expected in cases of tubal obstruction. All other patients reported discomfort, but none experienced pain severe enough to prevent completion of the examination. The study was completed after 50 patients had successfully undergone both examinations.

Patients were 21–37 years old (mean 28.6 ± 4 years).

Table 1. Presence of gadolinium/iodinated contrast as an indicator of tubal patency recorded on MR-HSG (Figure 5) and HSG (Figure 4). A total of 50 patients were analysed. Numbers (n) indicate the number of patients in whom contrast was present adjacent to the left or right ovary or in the pouch of Douglas on MR-HSG and HSG images.

| MR-HSG | | | HSG | | |
|--------|-------|---------|------|-------|---------|
| Left | Right | Douglas | Left | Right | Douglas |
| 37 | 37 | 41 | 38 | 33 | 37 |

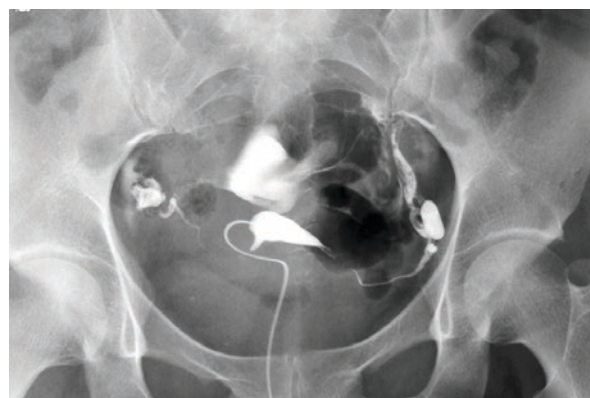

Figure 4. HSG demonstrating the uterus and fallopian tubes, with contrast seen around the ovaries and in the pouch of Douglas.

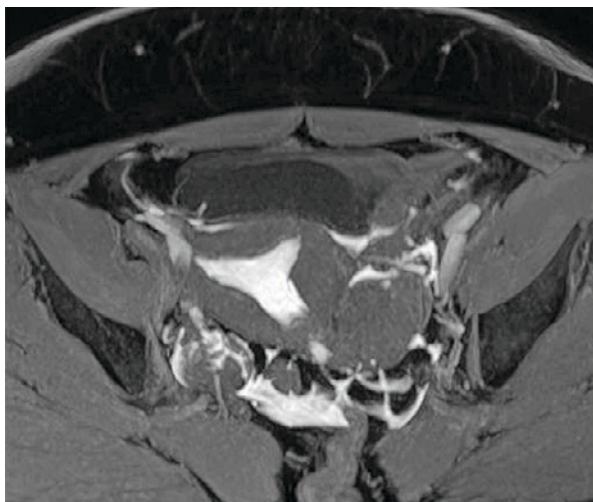


Figure 5. Multi-planar reconstruction from 3D T1-weighted images acquired after MR-HSG. The contrast solution is visible within the uterine cavity, around the ovaries, and in the pouch of Douglas.

After assessing the presence of gadolinium contrast solution (in all patients in whom both HSG and MR-HSG were successfully performed), adjacent to the left and right ovary and in the pouch of Douglas, Cronbach's alpha coefficient was calculated as a measure of congruence (Table 2).

Table 2. Congruence between HSG and MR-HSG measurements assessed using Cronbach's alpha coefficient. Higher values indicate better agreement. Values in parentheses represent the 95% lower confidence limit.

| MR-HSG vs. HSG | Cronbach's Alpha |
|------------------|------------------|
| Left ovary | 0.97 (0.96) |
| Right ovary | 0.84 (0.75) |
| Pouch of Douglas | 0.80 (0.68) |

No adverse effects (such as infection, bleeding, or ectopic pregnancy) were observed after MR-HSG or conventional HSG. The examination was completed within 10 minutes in all cases.

Discussion

Among the 6 patients with bilateral tubal occlusion (12%), five reported pain during contrast administration, while the others experienced discomfort that was not severe enough to interrupt the procedure. Cronbach's alpha results indicate excellent agreement between conventional HSG and MR-HSG when the presence of contrast adjacent to the ovary is used as an indicator of tubal patency. Agreement is slightly lower when contrast in the pouch of Douglas is used as the patency indicator. These findings also warrant consideration of ultrasound-guided HSG, where fluid in the pouch of Douglas is commonly interpreted as evidence of tubal patency. There are also studies using Doppler imaging as well as 3D and 4D techniques, although it is not entirely clear which method is predominantly used in routine practice [4-7].

Fewer patients showed reduced patency on conventional HSG than on MR-HSG. This difference may be explained by the higher viscosity of iodinated contrast medium, which may not flow as readily through the fallopian tubes as the gadolinium solution used for MR-HSG.

Advantages of MR-HSG

Compared with traditional methods, MR-HSG offers several advantages: complete absence of ionizing radiation, detailed visualization of the uterus and ovaries, the ability to detect other pelvic pathology independent of tubal patency, and better tolerability in most cases [2,3,10].

Contribution of the radiologic technologist

The radiologic technologist is actively involved in patient preparation, examination performance, and optimization of the MR protocol. This includes confirming patient identity and obtaining informed consent, ensuring correct positioning and clear communication to minimize discomfort, preparing and administering contrast solution, planning imaging planes, as well as optimizing image quality. The technologist monitors the patient throughout the examination, recognizes discomfort, and responds to potential complications.

Practical guidance for radiologic technologists:

- **Communication:** explain each step to reduce anxiety and ensure cooperation. Clear communication and reassurance improve cooperation and may reduce patient anxiety during positioning and contrast administration.
- **Comfort:** ensure the patient remains still and breathes normally to minimize motion artifacts and avoid the need for additional medication.
- **Safety:** review MR contraindications (e.g., metallic implants) and potential contrast-related issues.
- **Image quality:** adjust the protocol as needed to obtain diagnostically adequate images.

Managing discomfort and pain

Mild discomfort during contrast administration is expected. However, severe or sharp pain requires immediate action: the injection should be stopped immediately and, in critical cases, the radiologist or gynaecologist should be consulted. The patient should be asked to localize the discomfort or pain, and this information should be documented and reported to the radiologist. Even minimal contrast administration can have diagnostic value, but the injection should never be forced. Patient safety is always the priority.

Conclusion

MR-HSG is a safe and accurate diagnostic method for assessing fallopian tube patency and the morphology of the female reproductive system. In addition to the absence of ionizing radiation, it provides high-quality imaging and improved patient comfort.

Successful implementation relies on appropriate patient preparation and strict protocol compliance by the radiologic technologist. Our study demonstrates high diagnostic accuracy, and the procedure was well tolerated by most patients.

Although our results support the effectiveness of MR-HSG, it should be emphasized that similar studies conducted across multiple institutions have reported comparable findings. Wider implementation of MR-HSG in clinical practice is essential to improve its availability and facilitate its integration into routine care, ultimately benefiting our patients.

Acknowledgements

We thank senior nurse Tihomira Pavlešić for her invaluable support in implementing MR-HSG at Požega County General Hospital.

References

1. Carbonnel M, Pirtea P, De Ziegler D, Ayoubi JM. Uterine factors in recurrent pregnancy losses. *Fertil Steril*. 2021. Mar;115(3):538-45.
2. Dishuck CF, Perchik JD, Porter KK, Gunn DD. Advanced Imaging in Female Infertility. *Curr Urol Rep*. 2019. Nov;20(11):77.
3. Devine K, Dolitsky S, Ludwin I, Ludwin A. Modern assessment of the uterine cavity and fallopian tubes in the era of high-efficacy assisted reproductive technology. *Fertil Steril*. 2022. Jul;118(1):19-28.
4. Bauşic A, Coroleucă C, Coroleucă C, Comandaşu D, Matasariu R, Manu A, et al. Transvaginal Ultrasound vs. Magnetic Resonance Imaging (MRI) Value in Endometriosis Diagnosis. *Diagnostics*. 2022. Jul;12(7):1767.
5. El Said AY, Mahmoud NA, Khater HM. Comparative study between MRI and Ultrasound in evaluation of Uterine lesions. *Benha Med J*. 2025. Feb;0(0):0-0.
6. Chhabra P, Daugherty R, LeNoir AM, Grilli C, Makai G, Patel N, et al. Comparison of Contrast-Enhanced Ultrasound Versus Magnetic Resonance Imaging in the Detection and Characterisation of Uterine Leiomyomas. *J Ultrasound Med*. 2020. Sep;40(6):1147-53.
7. Faivre E, Fernandez H, Deffieux X, Gervaise A, Frydman R, Levailant JM. Accuracy of Three-Dimensional Ultrasonography in Differential Diagnosis of Septate and Bicornuate Uterus Compared with Office Hysteroscopy and Pelvic Magnetic Resonance Imaging. *J Minim Invasive Gynecol*. 2012. Jan;19(1):101-6.
8. Grimbizis GF, Gordts S, Di Spiezio Sardo A, Brucker S, De Angelis C, Gergolet M, et al. The ESHRE/ESGE consensus on the classification of female genital tract congenital anomalies. *Hum Reprod*. 2013. Jun 14;28(8):2032-44.
9. Grimbizis GF, Di Spiezio Sardo A, Saravelos SH, Gordts S, Exacoustos C, Van Schoubroeck D, et al. The Thessaloniki ESHRE/ESGE consensus on diagnosis of female genital anomalies. *Hum Reprod*. 2015. Nov;31(1):2-7.
10. DeBenedictis C, Ghosh E, Lazarus E. Pitfalls in Imaging of Female Infertility. *Semin Roentgenol*. 2015. Oct;50(4):273-83.
11. World Health Organization. Infertility [Internet]. Geneva: WHO; [cited 2025 Oct 11]. Available at: <https://www.who.int/news-room/fact-sheets/detail/infertility>
12. Prepare for a Hysterosalpingogram (HSG) Exam [Internet]. UCSF Radiology; [cited 2025 Oct 11] Available at: <https://radiology.ucsf.edu/patient-care/prepare/hysterosalpingogram>

MR-HSG kao sigurna, pouzdana i nedovoljno korištena metoda

Sažetak

Uvod: Histerosalpingografija (HSG) predstavlja zlatni standard za procjenu prohodnosti jajovoda, no uključuje izlaganje ionizirajućem zračenju i primjenu jednog kontrastnog sredstva. Magnetska rezonancijska histerosalpingografija (MR-HSG) omogućuje procjenu prohodnosti jajovoda bez ionizirajućeg zračenja, uz superiornu vizualizaciju mekih tkiva zdjelice.

Cilj: Procijeniti dijagnostičku vrijednost MR-HSG u procjeni prohodnosti jajovoda, s posebnim naglaskom na MRI protokol, te usporediti nalaze s onima dobivenima konvencionalnom HSG metodom.

Materijali i metode: U istraživanje je uključeno pedeset pacijentica. Sve su podvrgnute MR-HSG pretrazi, nakon čega je odmah slijedila HSG. Tijekom MR-HSG-a u šupljinu maternice aplicirana je razrijeđena otopina gadolinijskog kontrasta. Protokol se sastojao od T2-vagnih sekvenci i dinamičkog T1-vaganog snimanja. Prisutnost kontrastne otopine uz jajnike i u Douglasu bilježena je kao pokazatelj prohodnosti jajovoda. Podudarnost metoda procijenjena je Cronbachovim alfa koeficijentom.

Rezultati: Bilateralna opstrukcija jajovoda potvrđena je u 6 slučajeva (12%). Cronbachova alfa pokazala je izvrsnu podudarnost između metoda (0,97 za lijevi jajnik; 0,84 za desni jajnik; 0,80 za Douglasov prostor). Nisu zabilježene nuspojave.

Zaključak: MR-HSG je učinkovita i dobro podnošljiva metoda s visokom podudarnošću u odnosu na HSG. Prednosti uključuju izostanak ionizirajućeg zračenja i superiornu vizualizaciju mekih tkiva zdjelice. MR-HSG može se smatrati pouzdanom alternativom HSG-u.

Ključne riječi: MR-HSG, HSG, prohodnost jajovoda, magnetska rezonancija, gadolinij, tubarna opstrukcija, neplodnost, zdjelica