



## WINGED SCAPULA DUE TO NERVE INJURY: A CASE SERIES ON KINESIOLOGY-BASED REHABILITATION

### ODIGNUTA LOPATICA ZBOG OZLJEDE ŽIVCA: PRIKAZ SLUČAJEVA O REHABILITACIJI TEMELJENOJ NA KINEZILOGIJI

Nina Špiljak-Vučinović<sup>1</sup>, Silvija Mahnik<sup>2</sup>, Mirta Zekan Vučetić<sup>3</sup>, Ana Aljinović<sup>2</sup>

<sup>1</sup>Institute of Emergency Medicine of Krapina-Zagorje County, Krapina, Croatia

<sup>2</sup>Department of Orthopedic Surgery, University Hospital Center Zagreb, Zagreb, Croatia;

<sup>3</sup>Department of Radiology, University Hospital Sveti Duh, Zagreb, Croatia.

Cite as: Špiljak-Vučinović N, Mahnik S, Aljinović A, Zekan Vučetić M. Scapular winging due to nerve injury: A case series on kinesiology-based rehabilitation. Croat Sports Med J. 2026; 41(1):5-12.

Corresponding author: Silvija Mahnik, silvija.mahnik@gmail.com

DOI: 10.69589/hsv.41.1.1

#### ABSTRACT

Winged scapula (scapula alata – lat.) a specific manifestation of scapular dyskinesis typically arises from neuromuscular impairments that affect periscapular muscle stabilization. The most common causes are injuries to the long thoracic nerve or spinal accessory nerve, resulting in characteristic medial or lateral winging due to paralysis of the serratus anterior or trapezius muscles, respectively. This case series presents four patients with winged scapula of varying etiology: one due to isolated long thoracic nerve injury, two following spinal accessory nerve damage after thyroid cancer surgery, and one idiopathic case. Diagnostic assessment included physical examination, electromyography, nerve conduction studies, and magnetic resonance imaging. All patients underwent individualized rehabilitation programs that focused on muscle strengthening, scapular stabilization, and biofeedback techniques. Rehabilitation led to pain reduction and functional improvement in all cases, although some degree of winged scapula persisted in the patients with irreversible nerve injury. These findings highlight the importance of early recognition and a multidisciplinary, kinesiology-based approach to optimize outcomes in patients with scapular dyskinesis.

**Keywords:** *Scapular dyskinesis, Shoulder biomechanics, Biofeedback therapy, Kinesiological rehabilitation*

#### SAŽETAK

Odignuta lopatica (scapula alata-lat.) odnosno krilasta lopatica, specifičan je oblik lopatične diskineze koji najčešće nastaje kao posljedica neuromišićnih oštećenja koja narušavaju stabilizaciju mišića ramenog obruča. Najčešći uzroci su ozljede dugog torakalnog živca ili spinalnog akcesornog živca, što dovodi do karakterističnog medijalnog ili lateralnog izbočenja lopatice uslijed paralize prednjeg zupčastog mišića (m. serratus anterior) ili trapeziusa. Ova serija slučajeva prikazuje četiri bolesnika s odignućem lopatice različite etiologije: jedan slučaj izolirane ozljede dugog torakalnog živca, dva slučaja oštećenja spinalnog akcesornog živca nakon operacije raka štitnjače te jedan idiopatski slučaj. Dijagnostička obrada uključivala je klinički pregled, elektromioneurografiju te magnetsku rezonanciju. Svi pacijenti bili su uključeni u individualizirane rehabilitacijske programe usmjerene na snaženje mišića ramenog obruča, stabilizaciju lopatice i primjenu biofeedback tehnike. Rehabilitacija je rezultirala smanjenjem boli i poboljšanjem funkcije kod svih pacijenata, iako je određeni stupanj odignuća lopatice zaostao kod onih s ireverzibilnim oštećenjem živca. Rezultati ovog prikaza slučajeva naglašavaju važnost ranog prepoznavanja te multidisciplinarnog, kineziološki usmjerenog pristupa u poboljšanju ishoda kod bolesnika s lopatičnom diskinezom.

**Ključne riječi:** *odignuta lopatica, biomehanika ramena, biofeedback terapija, kineziološka rehabilitacija*

## INTRODUCTION

Winged scapula (*scapula alata*- lat.) is a rare clinical condition characterized by abnormal posterior protrusion of the scapula resulting from weakness or paralysis of the stabilizing periscapular muscles. Depending on the muscle involved, winging may be medial or lateral<sup>13</sup>. This dysfunction significantly impairs upper limb mobility and shoulder biomechanics, often presenting with pain, reduced strength, and difficulty in performing overhead or lifting tasks<sup>2,9</sup>.

The most common causes of winged scapula are nerve injuries, particularly affecting the long thoracic nerve (LTN) or spinal accessory nerve (SAN)<sup>13</sup>. The LTN innervates the serratus anterior muscle, which is anatomically divided into three segments: superior (ribs 1–2 to the superior scapular angle), intermediate (ribs 2–4 to the medial border), and inferior (ribs 5–10 to the inferior angle)<sup>8</sup>. This muscle plays a crucial role in scapular stabilization and abduction. Injury to the LTN leads to paralysis of the serratus anterior and results in medial winged scapula, often accompanied by shoulder pain and limited forward elevation<sup>9,16</sup>.

The first case of winged scapula caused by LTN injury and serratus anterior paralysis was described by Velpeau in 1837<sup>7</sup>. The incidence of isolated serratus anterior paralysis is estimated at 0.0026% to 0.21%<sup>5, 15</sup>. Vastamäki and Kauppila (1993) reported the largest series to date, identifying strenuous activity, trauma, idiopathic causes, invasive procedures, infection, and anesthesia as potential etiologies<sup>17,19</sup>.

The SAN, which is the eleventh cranial nerve, innervates the trapezius and sternocleidomastoid muscles. Injury to this nerve results in lateral winged scapula due to trapezius weakness, which leads to shoulder drooping and impaired scapular elevation<sup>16</sup>. SAN injuries are commonly iatrogenic and occur during cervical lymph node biopsies (3–8%) or radical neck dissections (60–80%)<sup>1, 3, 12</sup>.

In addition to LTN and SAN involvement, other less common causes of winged scapula include viral neuropathies, neuroinflammatory disorders, toxin exposure, compressive lesions, C7 radiculopathy, and dorsal scapular nerve neuropathy<sup>2, 13</sup>.

From a kinesiological perspective, winged scapula represents disruption of the coordinated muscle activation required for optimal scapulohumeral and glenohumeral functions. Proper scapular motion and stabilization are essential for force transfer during upper limb movement, postural control, and athletic performance<sup>20</sup>. Impairments in these mechanisms can lead to compensatory movement patterns, increased risk of injury, and long-term functional deficits<sup>10</sup>.

Kinesiology based rehabilitation strategies emphasize precise assessment of scapular kinematics, targeted muscle activation, and neuromuscular retraining. Interventions often include progressive resistance training, proprioceptive exercises, electromyographic biofeedback (EMG BFB)

therapy, and manual therapy, with the goal of restoring dynamic scapular control<sup>4, 14</sup>. During rehabilitation, an EMG BFB, as a neuromuscular reeducation device, is used to record the muscle action potentials responsible for muscle contraction and display them as visual or auditory signals<sup>18</sup>. This provides the patient with real-time feedback on the intensity of muscle activation, helping them learn to optimize contraction during exercise. Surface electrodes were placed on the target muscle and were connected to the device. The muscle activity is shown on the screen as a line graph, enabling the patient to better understand and improve voluntary muscle control.

In cases where conservative, kinesiology-based rehabilitation fails, surgical approaches may be considered. Recent evidence suggests that techniques such as serratus anterior plication combined with pectoralis minor release can significantly improve pain, function, and mobility in patients with refractory scapular dyskinesis associated with neurological symptoms<sup>11</sup>.

This case series aimed to illustrate the clinical and functional diversity of winged scapula resulting from different nerve injuries and to highlight the importance of individualized, kinesiology-based rehabilitation in optimizing recovery and restoring upper limb function. All patients provided informed consent for the publication of clinical data and images.

## CASE REPORT - ONE

A 25-year-old man presented to our outpatient clinic with right shoulder weakness and occasional pain (Figure 1). The patient's medical history was unremarkable. Five months prior, he experienced sudden, severe pain in the right shoulder while playing table tennis. Since then, he has reported pain when lifting heavy objects, and his primary complaint has been reduced shoulder strength. Physical examination revealed winged scapula and limited active forward elevation to 130°, whereas the passive range of motion remained full and painless (Figure 2). Musculoskeletal ultrasound and cervical spine magnetic resonance imaging (MRI) showed no pathological findings. Electromyographic (EMG) and nerve conduction studies (NCS) demonstrated decreased compound muscle action potential (CMAP) amplitudes in the right LTN, consistent with LTN neuropathy. The patient was referred to a kinesiology-based rehabilitation program focused on restoring scapular stability and neuromuscular control. The intervention included targeted strengthening exercises for the rotator cuff and scapular stabilizing muscles (particularly the serratus anterior and lower trapezius), using elastic resistance and closed kinetic chain exercises. EMG BFB therapy assisted in re-education of the serratus anterior muscle to enhance selective muscle activation and motor control. The program also incorporated proprioceptive training and postural correction strategies, progressively increasing task complexity over six weeks.

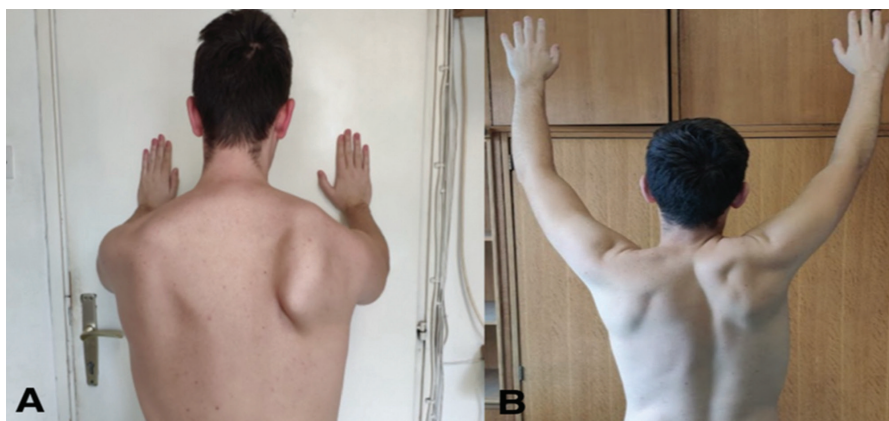

Figure 1. Winged scapula of the right shoulder caused by the long thoracic nerve neuropathy. Posterior view of the patient during wall push-up test demonstrates prominent medial scapular border and winging of the right scapula (A). Limited active forward elevation of the right upper extremity (B).

Slika 1. Odignuta lopatica desnog ramena uzrokovana neuropatijom dugog torakalnog živca. Stražnji pogled na pacijenta tijekom testa sklekova uz zid pokazuje istaknuti medijalnu rub lopatice i odignutost desne lopatice (A). Ograničeno aktivno podizanje gornjeg desnog ekstremiteta prema naprijed (B).

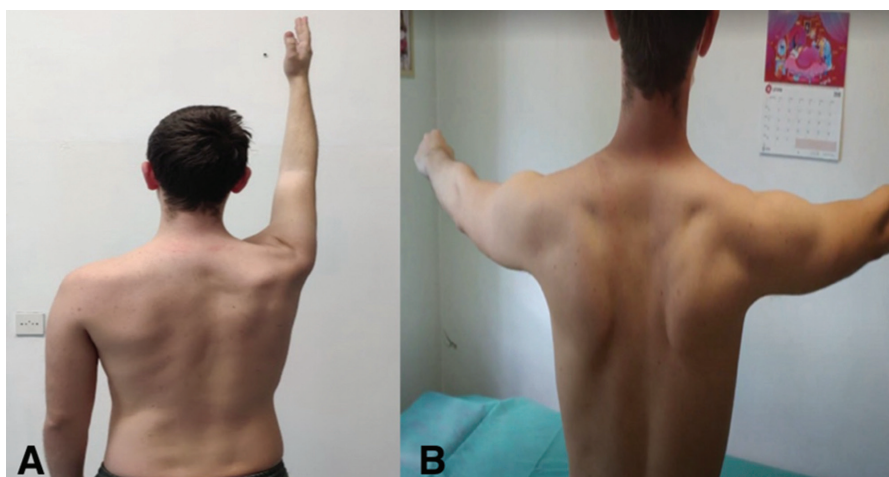


Figure 2. Improved shoulder elevation following kinesiology-based rehabilitation. Posterior view after rehabilitation shows improved active elevation of the right upper extremity and better scapular control (A). Winged scapula is significantly reduced compared to initial presentation. Posterior view of the patient during active bilateral shoulder abduction following completion of the rehabilitation program. The scapulae remain stable and symmetrical, indicating improved neuromuscular coordination and reduced winged scapula (B).

Slika 2. Poboljšana elevacija ramena nakon kineziološke rehabilitacije. Stražnji pogled pokazuje poboljšanu aktivnu elevaciju gornjeg desnog ekstremiteta i bolju kontrolu lopatice (A). Pomicanje lopatice značajno je smanjeno u usporedbi s početnim prikazom. Stražnji pogled na pacijenta tijekom aktivne bilateralne abdukcije ramena nakon završetka rehabilitacijskog programa. Lopatice ostaju stabilne i simetrične, što ukazuje na poboljšanu neuromuskularnu koordinaciju i smanjeno odizanje lopatice (B).

Upon completion, the patient reported improved shoulder function, reduced pain, and greater endurance during daily and overhead activities, although mild scapular asymmetry persisted (Figure 2).

## CASE REPORT -TWO

A 20-year-old female patient presented to our outpatient clinic with right shoulder pain and muscle weakness

following surgery for metastatic papillary thyroid cancer. Physical examination revealed a depressed right shoulder, compensatory hypertrophy of the middle trapezius, and weakened and painful abduction and elevation (Figure 3). Winged scapula is evident on the right side. EMG and NCS confirmed the presence of SAN lesions. A kinesiology-based rehabilitation program was prescribed to restore scapular stability and improve the neuromuscular coordination of the affected musculature. The intervention included targeted

strengthening exercises of the upper and lower trapezius, serratus anterior, and rotator cuff muscles. Special emphasis was placed on restoring symmetrical scapular motion through closed-chain activities, postural retraining, and motor control drills. Trapezius muscle re-education was guided by EMG BFB therapy to facilitate isolated activation and reduce compensatory patterns. Progressive resistance exercises were integrated using elastic bands and isometric holds in the controlled scapular planes. After six weeks of therapy, the patient demonstrated reduced shoulder pain, improved scapular symmetry, and increased strength in active abduction and elevation. Enhanced control of the

trapezius muscle was evident during clinical testing and functional tasks, such as reaching and lifting (Figure 4).

### CASE REPORT -THREE

A 34-year-old female patient presented to our outpatient clinic one month after undergoing surgery for metastatic papillary thyroid cancer. She reported left cervical pain and restricted mobility of the left arm. Clinical examination revealed lateral winged scapula, limited shoulder anteflexion, and active abduction restricted to 90° (Figure 5). She also reported a sensory loss on the left side of the

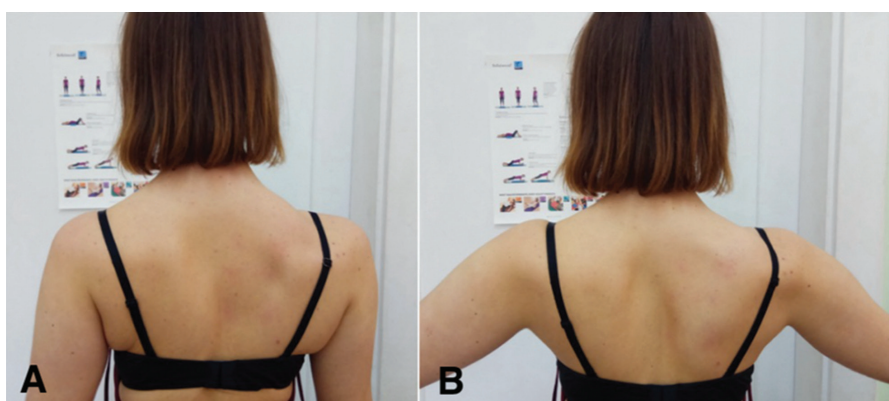


Figure 3. Scapular asymmetry at rest in a patient with spinal accessory nerve lesion. Posterior view during initial clinical assessment shows a depressed right shoulder and mild winged scapula at rest, consistent with trapezius weakness following spinal accessory nerve injury post-thyroid cancer surgery (A). Posterior view of the patient demonstrating reduced scapular stability and mild winging of the right scapula during active arm abduction (B).

Slika 3. Asimetrija lopatice u mirovanju kod pacijenta s lezijom SAN-a. Stražnji pogled tijekom početne kliničke procjene pokazuje spušteno desno rame i blago odizanje lopatice u mirovanju, što je u skladu sa slabošću trapezoidnog mišića nakon ozljede SAN-a nakon operacije raka štitnjače (A). Stražnji pogled na pacijenta koji pokazuje smanjenu stabilnost lopatice i blago odizanje desne lopatice tijekom aktivne abdukcije ruke (B).

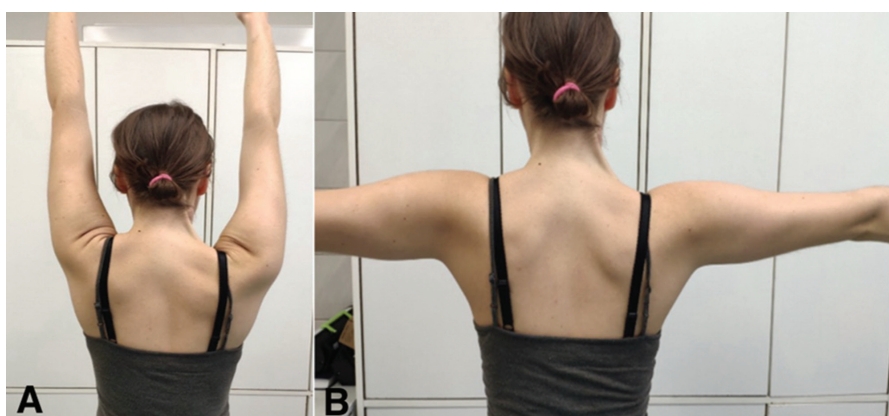

Figure 4. Posterior view of the patient during active overhead arm elevation after six weeks of rehabilitation. The scapulae remain stable and symmetrical, reflecting enhanced neuromuscular coordination and improved activation of the trapezius and serratus anterior muscles (A). Coordinated and stable scapular positioning during active shoulder abduction, demonstrating improved neuromuscular control and trapezius function after targeted rehabilitation (B).

Slika 4. Stražnji pogled na pacijenta tijekom aktivnog podizanja ruke iznad glave nakon šest tjedana rehabilitacije. Lopatice ostaju stabilne i simetrične, što odražava poboljšanu neuromuskularnu koordinaciju i poboljšanu aktivaciju trapeziusa i prednjeg nazubljenog mišića (A). Koordinirano i stabilno pozicioniranje lopatice tijekom aktivne abdukcije ramena pokazuje poboljšanu neuromuskularnu kontrolu i funkciju trapeziusa nakon ciljane rehabilitacije (B).

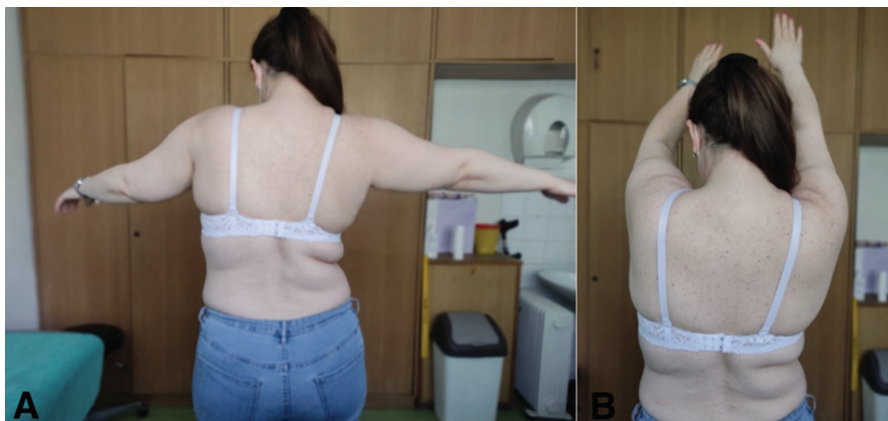

Figure 5. Winged scapula and impaired abduction following spinal accessory nerve resection. Posterior view of the patient during active shoulder abduction demonstrates lateral winging of the left scapula and limited abduction range (A). Limited active shoulder anteflexion, with compensatory trunk motion and poor control of the left scapula (B).

Slika 5. Odizaanje lopatice i oštećena abdukcija nakon resekcije SAN-a. Stražnji pogled na pacijenta tijekom aktivne abdukcije ramena pokazuje lateralno pomicanje lijeve lopatice i ograničen raspon abdukcije (A). Ograničena aktivna antefleksija ramena, s kompenzacijskim pokretom trupa i slabom kontrolom lijeve lopatice (B).

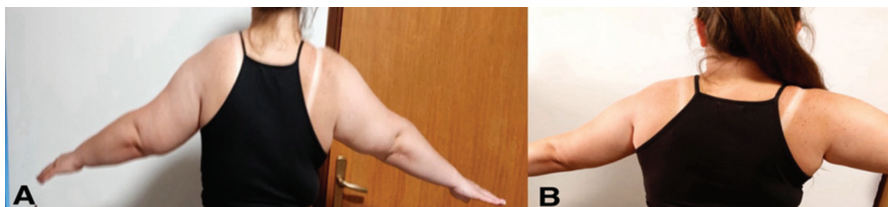

Figure 6. Posterior view of the patient after rehabilitation, showing active arm abduction with residual compensatory trunk lateral flexion to assist movement on the left side (A). The patient demonstrates more symmetrical shoulder abduction with reduced trunk compensation and improved control of the left scapula, following targeted kinesiology-based therapy after spinal accessory nerve resection (B).

Figure 6. Stražnji pogled na pacijenta nakon rehabilitacije, koji prikazuje aktivnu abdukciju ruke s rezidualnom kompenzacijskom lateralnom fleksijom trupa radi pomoći pri kretanju na lijevoj strani (A). Nakon ciljane kineziološke terapije poslije resekcije spinalnog akcesornog živca pacijent pokazuje simetričniju abdukciju ramena sa smanjenom kompenzacijom trupa i poboljšanom kontrolom lijeve lopatice, (B).

neck. In this case left SAN was resected due to tumor infiltration, resulting in paresis of the trapezius muscle. A kinesiology-guided rehabilitation program was initiated to restore the scapular control and upper limb function. The patient underwent individualized therapeutic exercises focused on strengthening scapular stabilizers and rotator cuff muscles, along with proprioceptive neuromuscular facilitation (PNF) techniques. EMG BFB therapy was used to facilitate neuromuscular re-education of the trapezius muscle. Proprioceptive taping was applied to support scapular positioning and reduce compensatory movement patterns. MRI of both shoulders, the cervical spine, and the brachial plexus revealed no direct compressive neuropathy or inflammatory lesions, although multiple enlarged cervical lymph nodes were noted. NCS confirmed the presence of axonal neuropathy in the left SAN. Over the course of six months, the patient demonstrated functional improvement, with active abduction increasing to 120°, although she continued to experience shoulder pain. A conservative approach was recommended after

neurosurgical consultation. Follow-up revealed improved active abduction to 160° in the scapular plane, accompanied by compensatory shoulder motion and temporary residual pain that gradually resolved. The structured physical therapy program contributed to improved scapular control, reduced pain, and gradual return of shoulder mobility, despite the persistent effects of nerve injury (Figure 6).

#### CASE REPORT - FOUR

A 33-year-old female patient presented with right scapular weakness that had developed nine months earlier following an exercise session. The morning after the workout, she experienced pain in the right scapular, shoulder, and cervical regions, radiating to the right elbow. Initial assessment led to a cycle of physical therapy targeting presuming cervical radiculopathy, with minimal clinical improvement. Upon reevaluation, physical examination revealed marked right winged scapula during anteflexion, with restricted terminal anteflexion and abduction of the

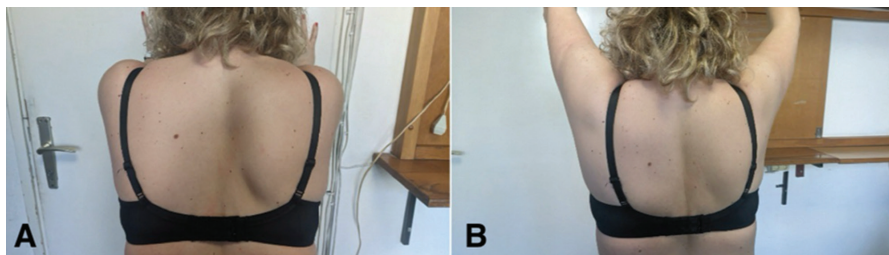


Figure 7. Winged scapula of the right shoulder during wall push-up. Posterior view demonstrates prominent medial border and elevation of the right scapula during wall push-up test (A). Medial displacement and prominence of the right scapular border during bilateral shoulder anteflexion (B).

Slika 7. Pomicanje lopatice desnog ramena tijekom skleka uz zid. Stražnji pogled pokazuje istaknuti medijalni rub i elevaciju desne lopatice tijekom testa (A). Medijalni pomak i istaknutost desnog ruba lopatice tijekom bilateralne fleksije ramena (B).

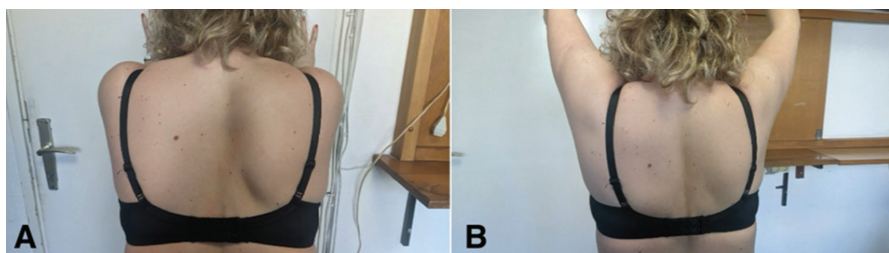


Figure 8. Patient undergoing surface electromyographic biofeedback (EMG BFB) therapy with electrodes placed over scapular stabilizers to facilitate selective muscle activation and neuromuscular control (A). Posterior view after completion of rehabilitation shows improved active elevation with reduced winged scapula and restored functional shoulder movement (B).

Slika 8. Pacijent podvrgnut površinskoj elektromiografskoj biofeedback terapiji (EMG BFB) s elektrodama postavljenim preko stabilizatora lopatice kako bi se olakšala selektivna aktivacija mišića i neuromuskularna kontrola (A). Stražnji pogled nakon završetka rehabilitacije pokazuje poboljšanu aktivnu elevaciju sa smanjenim trzanjem lopatice i obnovljenim funkcionalnim pokretom ramena (B).

right shoulder (Figure 7). The radiographic and ultrasound findings were unremarkable. EMG and NCS revealed no evidence of brachial plexus or LTN injuries. Nevertheless, the clinical presentation was suggestive of winged scapula related to the presumed LTN dysfunction. A kinesiology-based rehabilitation program was initiated, which included individualized therapeutic exercise, biofeedback-assisted motor retraining, and scapular stabilization techniques (Figure 8). The protocol focused on the activation of the serratus anterior and lower trapezius muscles using closed-chain exercises, neuromuscular control drills, and posture correction. Additional modalities included ultrasound therapy and proprioceptive strategies for shoulder stabilization. Five months after initiating therapy, follow-up MRI of the brachial plexus and thoracic spine showed no pathology accounting for winged scapula. Remarkably, the pain in the right scapular and shoulder regions resolved completely. The patient regained full active range of motion without functional limitations, although winged scapula remained evident during arm elevation (Figure 8). Based on the clinical course and therapeutic response, the presentation was considered most consistent with idiopathic or subclinical LTN neuropathy that was not captured by electrophysiological studies.

## DISCUSSION

Although winged scapula is a rare clinical phenomenon, injuries to the LTN and SAN should be considered in patients presenting with shoulder pain, weakness, or abnormal scapular motion. Early recognition is essential because delayed diagnosis may lead to persistent dysfunction, maladaptive movement patterns, and secondary musculo-skeletal complications.

A thorough clinical examination, including observation of scapular positioning during dynamic upper limb tasks, is crucial for identifying scapular dyskinesis. While electrodiagnostic studies such as EMG and NCS remain the gold standard for confirming nerve injury, their sensitivity may be limited in subclinical or chronic cases. As observed in one of our patients, clinical presentation can strongly suggest LTN neuropathy despite normal electrophysiological findings, underscoring the importance of clinical judgment.

Rehabilitation played a key role in improving the outcomes across all four cases. A kinesiology-based approach centered on individualized exercise programs, neuromuscular re-education, and scapular stabilization has proven effective in restoring shoulder function and reducing

pain. Special emphasis was placed on EMG BFB therapy to facilitate activation of the serratus anterior or trapezius muscle, depending on the involved nerve. This intervention was well tolerated and enabled patients to achieve greater voluntary muscle control, especially in the early recovery stages when visible improvement was limited<sup>20</sup>. In cases of irreversible nerve injury, winged scapula persisted; however, pain resolution and restoration of functional range of motion were achieved. These findings support previous literature indicating that targeted rehabilitation may compensate for muscular deficits even when full anatomical recovery is not possible. In cases where conservative treatment fails or nerve damage is irreversible, surgical options such as nerve transfers, muscle transfers, and scapulothoracic fusion may be considered<sup>6</sup>, as well as newer techniques such as serratus anterior plication combined with pectoralis minor release, which have been associated with improvements in pain, function, and mobility in patients with refractory scapular dyskinesis<sup>11</sup>.

## CONCLUSION

Early recognition of winged scapula and associated nerve injuries is critical for preserving upper-limb function. Individualized kinesiology-based rehabilitation, particularly when neuromuscular biofeedback and focused scapular control strategies are included, can lead to significant improvements in pain, strength, and mobility. This case series supports the essential role of kinesiology in the interdisciplinary management of scapular dyskinesis and highlights the value of functional assessment and active therapeutic intervention in cases of neurogenic shoulder dysfunction.

## References

1. Bigliani LU, Perez-Sanz JR, Wolfe IN. Treatment of trapezius paralysis. *J Bone Joint Surg Am.* 1985;67(6):871-7.
2. Didesch JT, Tang P. Anatomy, etiology, and management of scapular winging. *J Hand Surg Am.* 2019;44(4):321-30.
3. Donner TR, Kline DG. Extracranial spinal accessory nerve injury. *Neurosurgery.* 1993;3.
4. Dubravčić-Šimunjak S. i sur. Fizikalni čimbenici u fizioterapiji. Zagreb: Hrvatski zbor fizioterapeuta, 2023. 2(6):907-10.
5. Fardin P, Negrin P, Dainese R. The isolated paralysis of the serratus anterior muscle: clinical and electromyographical follow-up of 10 cases. *Electromyogr Clin Neurophysiol.* 1978;18(5):379-86.
6. Galano GJ, Bigliani LU, Ahmad CS, Levine WN. Surgical treatment of winged scapula. *Clin Orthop Relat Res.* 2008;466(3):652-60.
7. Gooding BWT, Geoghegan JM, Wallace WA, Manning PA. Scapular winging. *Shoulder Elbow.* 2014;6(1):4-11.
8. Keros P, Pećina M. Funkcijska anatomija lokomotornoga sustava, drugo dopunjeno izdanje, Zagreb: Ljevak, 2020.
9. Kibler WB, McMullen J. Scapular dyskinesis and its relation to shoulder pain. *J Am Acad Orthop Surg.* 2003;11(2):142-51.
10. Kim SH, Cynn HS, Yi CH, Lee JH, Baik SM. Comparison of the effects of isometric horizontal abduction on shoulder muscle activity during wall push-up plus and wall slide in individuals with scapular winging. *J Sport Rehabil.* 2023;32(4):395-401.
11. Koukos C, Montoya F, Marty A, Friedrich MJ, Cucchi D. Combined Serratus Anterior Plication and Pectoralis Minor Release Improves Clinical Outcomes in Refractory Scapular Dyskinesis with Neurological Involvement. *J Shoulder Elbow Surg.* 2026.
12. Leipzig B, Suen JY, English JL, Barnes J, Hooper M. Functional evaluation of the spinal accessory nerve after neck dissection. *Am J Surg.* 1983;146(4):526-30.
13. Martin RM, Fish DE. Scapular winging: anatomical review, diagnosis, and treatments. *Curr Rev Musculoskelet Med.* 2008;1(1):1-11.
14. Morante de Los Reyes A, Bacle G, Chaves C, Tranier M, Jacquot A, Corcia P, Laulan J, Roulet S. Scapular winging due to rhomboid muscle paralysis: clinical assessment of 4 cases and anatomic study of the dorsal scapular nerve. *J Shoulder Elbow Surg.* 2022;31(12):2595-601.
15. Overpeck DO, Ghormley RK. Paralysis of the serratus magnus muscle: caused by lesions of the long thoracic nerve. *JAMA.* 1940;114(20).
16. Pećina M, Krmpotić-Nemanić J, Markiewitz AD. Spinal accessory nerve syndrome; Long thoracic nerve compression. In: *Tunnel syndromes. Peripheral nerve compression syndromes.* Third Edition. Boca Raton: CRC Press 2001. pp.33-7; pp.73-7.
17. Pećina M, Pećina HI, Borić I. Sindromi kompresije perifernih živaca u sportaša – Tunelarni sindromi. U: Pećina M. i sur. *Sportska medicina, 2., dopunjeno i obnovljeno izdanje,* Zagreb: Medicinska naklada, 2025., pp. 402-8.
18. Tang YY, Cui Z, Kim TH. The effects of scapular stabilization exercises accompanied by spine stabilization exercises using an unstable surface on muscle activities for subjects with scapular winging. *Int J Hum Mov Sports Sci.* 2023;11(1):77-87.
19. Vastamäki M, Kauppila LI. Etiologic factors in isolated paralysis of the serratus anterior muscle: a report of 197 cases. *J Shoulder Elbow Surg.* 1993;2(5):240-3.
20. Yesilyaprak SS, Karabay D, Turksan HE, Erduran M. Shoulder abduction strength is correlated with acromiohumeral distance in patients with acute subacromial impingement syndrome symptoms but not with supraspinatus tendon thickness regardless of disease stage. *Kinesiology.* 2022;54(2):307-15.