







## LETTERS TO THE EDITOR

# A knotted central venous catheter discovered at removal: when resistance should prompt imaging, not traction

Tomić Mahečić T<sup>1,2,\*</sup> , Babić A<sup>1,3</sup> , Balenović I<sup>1</sup>, Karmelić D<sup>1</sup> , Biličić L<sup>1</sup>, Vukšić A<sup>1</sup>, Bošnjak I J<sup>1</sup> ,  
Baronica R<sup>1</sup> , Crkvenac Gregorek A<sup>1</sup> 

<sup>1</sup>Department of Anesthesiology and ICU, University Hospital Centre Zagreb, Zagreb, Croatia  · <sup>2</sup>University of Zagreb School of Medicine, Zagreb, Croatia  · <sup>3</sup>Policlinic Duduković Kisić, Zagreb

\*Corresponding author: Tina Tomić Mahečić, Department of Anesthesiology and ICU, University Hospital Centre Zagreb, Zagreb, Croatia;  
University of Zagreb School of Medicine, Zagreb, Croatia  
E-mail: [ttomic@kbc-zagreb.hr](mailto:ttomic@kbc-zagreb.hr)

## Letter

Dear Editor,

Central venous catheter (CVC) placement is routine in acute care, yet mechanical complications remain clinically important. Most attention rightly focuses on arterial puncture, pneumothorax, infection, and thrombosis. Knot formation at the distal end of a standard multilumen CVC is uncommon and easily missed when the line functions normally during use.

We wish to report a case that illustrates this hazard.

A patient required central venous access for prolonged intravenous therapy. A double-lumen catheter was inserted into the right internal jugular vein without immediate complications; blood aspiration and infusion through both lumens were satisfactory. No post-procedure chest radiograph was obtained. The catheter remained in place for one week and delivered treatment without dysfunction.

On planned removal, the operator encountered firm resistance over the final 5–6 cm of the catheter. Further withdrawal was stopped. A bedside ultrasound in the operating room showed the catheter still within the vein, with neither inflow nor outflow through the lumens. After cautious attempts at non-operative removal failed, a vascular surgeon was consulted.

Operative exploration under local anaesthesia confirmed the presence of a knot at the distal end of the catheter (Figure 1). The line was removed intact. The patient recovered without haemorrhage or infection.

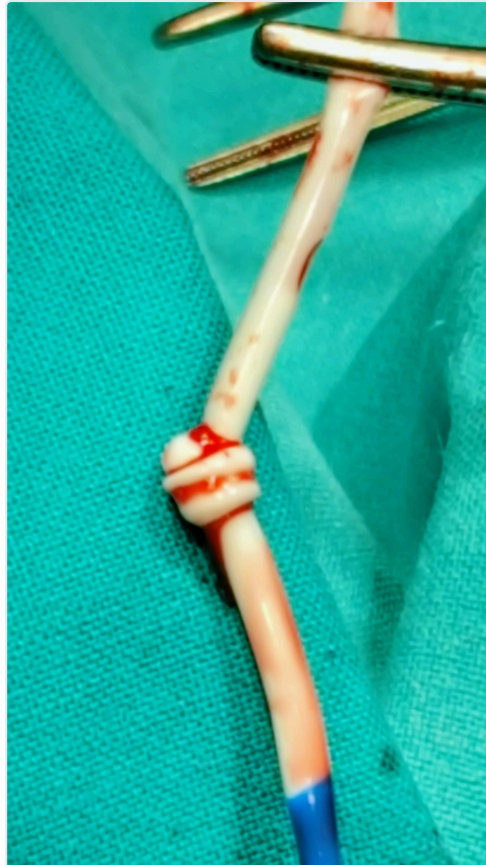


Figure 1. The explanted double-lumen central venous catheter, held on forceps, showing a knot at its distal end confirmed at operative exploration.

Although CVC knotting is rare and is described mainly in case reports and small series (1,2), it is not merely theoretical. Proposed mechanisms include guidewire looping, vascular tortuosity, excessive catheter length with intravascular coiling, and loop tightening during withdrawal (3). Reports of knotting in pulmonary artery catheters suggest incidences of roughly 0.2–2.5% in selected settings (3); comparable figures for routine CVCs are not well established, which may contribute to under-recognition.

This case supports several practical points. First, resistance during removal should be treated as a mechanical problem until proven otherwise; forced traction risks fracture and embolisation (3,5). Second, imaging—ultrasound or radiography—should precede further manipulation when withdrawal is not smooth (3,5). Third, routine post-insertion imaging may disclose malposition or coiling before the catheter is used for days without symptoms (2,3). In our patient, normal function during infusion did not exclude a distal abnormality that became apparent only at removal.

Operator experience and ultrasound guidance reduce many insertion-related complications (4), but they do not eliminate rare mechanical events (1,3). Clinicians should remain aware that a CVC which appears to work well may still harbor a distal knot (1,2).

We hope this report encourages colleagues to stop, image, and seek specialist input when catheter removal is unexpectedly difficult.

Sincerely,

#### REFERENCES

1. Erkiılıç E, Aksoy M, Gümüş T, Sarı S, Kesimci E. Jugular venous catheterization: a case of knotting. *Case Rep Med.* 2015;2015:810346.
2. Hayaran N, Goyal N, Joy S, Jain A. Coiling of central venous catheter: a rare and preventable complication. *Anesth Essays Res.* 2017;11(3):773-775.

3. Eisen LA, Narasimhan M, Berger JS, et al. Mechanical complications of central venous catheters. *J Intensive Care Med.* 2006;21(1):40-46.
4. Teja B, Bosch NA, Diep C, et al. Complication rates of central venous catheters: a systematic review and meta-analysis. *JAMA Intern Med.* 2024;184(5):474-482.
5. Urevick AJ, Briscoe WE, Harpstead E, et al. Use of a guidewire as an adjunct for the safe removal of a stuck indwelling central venous catheter at risk for breaking. *Am Surg.* 2023;89(9):3898-3899.

---

Cite as: Tomić Mahečić T, Babić A, Balenović I, Karmelić D, Biličić L, Vukšić A, et al. A knotted central venous catheter discovered at removal: when resistance should prompt imaging, not traction. *CJAIM* 2026;2(1):65–67.

