

Histological comparison of spleen and kidney tissue from farmed and wild European sea bass (*Dicentrarchus labrax* L.)

Božidar KURTOVIĆ*, Emin TESKEREDŽIĆ and Zlatica TESKEREDŽIĆ

*Laboratory for Aquaculture, Department for marine and environmental research,
Ruđer Bošković Institute, Bijenička cesta 54, 10 000 Zagreb, Croatia*

**Corresponding author, e-mail: bkurtovi@irb.hr*

The aim of this study was to investigate the effect of intensive farming on spleen and kidney histology. The study was carried out on sea bass reared intensively in sea-cages and fed with complete commercial diets. The control group of sea bass was wild fish caught in Tarska Bay, Istria. The investigation was focused on histological changes in spleen and kidney. Microscopic evaluation revealed that the number of melanomacrophage centers (MMC) was significantly higher ($p < 0.5$) in spleen and kidney tissues from farmed fish. Atrophy and lysis of glomerular tufts were more pronounced in the kidney of reared fish, but this difference was significant ($p < 0.5$) only for atrophy. While necrotic lesions were more pronounced in the kidney tubules of reared fish, the degree of lesion development was not significant ($p > 0.5$) compared to the control. There were no differences in the occurrence of degenerative and inflammatory lesions in the kidney.

Key words: histology, kidney, spleen, stress, Sea bass

INTRODUCTION

The European sea bass (*Dicentrarchus labrax*) is the most important marine fish species reared in the Mediterranean region. Nevertheless, there has been no systematic review of normal histology for this species and reports describing histopathology related to intensive aquaculture are very limited and incomplete. There are, however, descriptions of normal histology for some select fish species (YASUTAKE & WALES, 1983; ROCHA & MONTEIRO, 1999).

Since teleost fish have no medullary cavity in their bones, the spleen and kidney serve as the primary haemopoietic organs (AGIUS & ROBERTS, 2003). As fish have no lymph nodes, the spleen alone plays an essential role in antigen trapping (PRESS, 1998).

The kidney of a fish receives the vast majority of postbranchial blood and renal lesions may be expected to be good indicators of environmental stress (HINTON & LAURÉN, 1990).

Melanomacrophage centers (MMC) are physiological features in fish spleen and kidney (AGIUS & ROBERTS, 2003). They are believed to be functional equivalents of the germinal centres of spleen and lymph nodes in mammals (ELLIS, 1980). MMC may contain four types of brown pigments: melanin, lipofuscin, ceroid and hemosiderin (COUILLARD *et al.*, 1999). WOLKE *et al.* (1985) first suggested MMC as potential monitors of fish health. MONTERO *et al.* (1999) found that stressful situations related to aquaculture practices have resulted in increased numbers of splenic and kidney MMC. Clinical studies have shown an association of MMC with highly

resistant intracellular bacteria such as mycobacteria and renibacteria and parasites such as *Myxobolus* spp. (ROBERTS, 2001).

There is evidence of glomerular and tubular lesions in fish kidney as a consequence of nephrotoxic effects of pesticides (VISOOTTIVISETH *et al.*, 1999) as well as antibiotics used in aquaculture (HICKS & GERACI, 1984). Lesions in kidney interstitial tissue are mainly associated with viral and bacterial infections (ROBERTS, 2001). Several renal pathological conditions, characterised by nephrolithiasis and granuloma, have been reported in cultured fish. Etiology is, at least partly, associated with nutrition (PAPERNA, 1987).

The present study was undertaken to determine the effect of intensive fish rearing on spleen and kidney histology in European sea bass by comparison with wild fish of the same species.

MATERIAL AND METHODS

Fish

The study was carried out on two groups of sea bass, one farmed and one wild. In order to exclude the effect of seasonality all samplings were undertaken in April. Farmed fish were sampled on the fish farm, located in the northern Adriatic Sea (45°08,031' N; 13°44,203' E), in which they were reared in floating cages and fed with a commercial diet (crude proteins 44%, crude fat 18%, ash 7.4% and fibre 3.4%). Samples were collected three times within the period 2003-2005, during which 10 fish were taken in each collection. In total, 30 fish (23 males and 7 females) were sampled from the cultured population. Weight and total length of the farmed fish were 174–323 g and 245-300 mm. All fish were sexually mature and had been kept in sea cages for 22-24 months. The control group were wild fish, sampled during the harvesting of Tarska Bay (45°18,465' N; 13°36,546' E), Adriatic Sea, Croatia (belonging to the same water body and microclimate as the farm in question). The fishing was carried out in April, 2003, when 20 fish (12 males and 8 females) were collected. Weight and total length of wild fish were 220-442 g and

285-375 mm. All fish were sexually mature and 2-3 years old. Fish were aged by counting the annual rings on their scales (EATON, 1996). After capture, fish were held in containers filled with oxygenated seawater for no more than 4 hours before processing.

Water analysis

During the investigation on the farm, sea temperature (UC-12 Digital DO/O₂ Temp. meter-Central Kagaku) ranged from 11.5°C to 13.3°C, salinity (SPR-N refractometer Atago, Japan) ranged from 38 to 39 and oxygen (UC-12 Digital DO/O₂ Temp. meter-Central Kagaku) ranged from 9.1 mg L⁻¹ to 9.4 mg L⁻¹. At the collection site for wild fish, temperature, salinity and oxygen were 15.6°C, 25 and 9.9 mg L⁻¹, respectively.

Histological examination

Prior to dissection and sampling, fish were humanely euthanized with an overdose of MS-222 (Sigma Chemical Co, St. Louis, USA) in seawater. Samples of the spleen and kidney from each fish were placed in 10% neutral buffered formalin. After fixation, samples were automatically dehydrated (Reichert-Jung, histokinette 2000) by passage through a series of ethanol solutions of increasing concentrations, followed by impregnation in paraffin (termed hell-paraffin). Paraffin blocks were sectioned 5µm thick on a microtome (Leitz 1512), and resultant sections were stained with hematoxylin and eosin according to the manufacturers instructions (Thermo Shandon). Histological samples of the spleen (Fig. 1) and kidney (Fig. 4) were examined by light microscope (Olympus BH-2) at 40x to 1000x magnification. The degree of congestion and number of MMC were evaluated in the spleen. The degree of splenic congestion was graded from 1 to 3 according to the following criteria: 1- all blood vessels partially filled with blood; 2- all blood vessels filled with blood and moderately distended; 3- all blood vessels filled with blood and highly distended. The number of MMC was recorded

in 3 randomly selected fields at 200x magnification. In the posterior kidney the number of MMC, occurrence of inflammatory changes and degenerative lesions on kidney glomeruli and tubules were analysed. The number of MMC was recorded in 3 randomly selected fields at 200x magnification. Glomerular (atrophy and lysis of glomerular tuft) and tubular lesions (hyaline and/or vacuolar degeneration, necrosis) were evaluated by counting affected glomeruli or tubuli in 3 randomly selected fields at 400x magnification. Accumulation of inflammatory cells was evaluated in 3 randomly selected fields at 200x magnification and graded from 0 to 3 according to the number of fields affected.

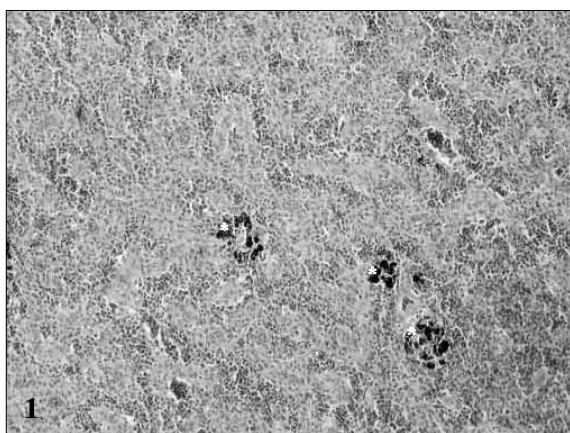


Fig. 1. Spleen from wild sea bass. Only few MMC and lack of blood congestion, H&E 200X

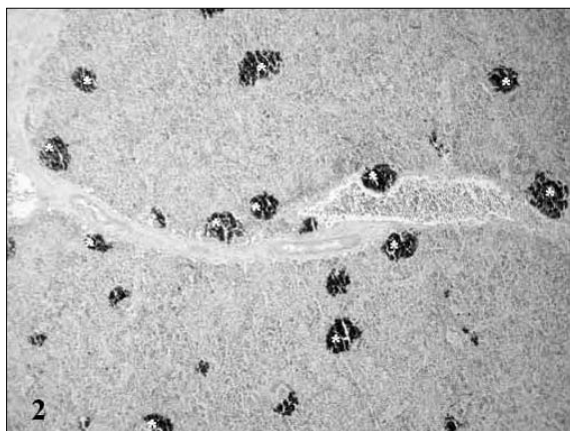


Fig. 2. Spleen from farmed sea bass. Numerous MMC (*), H&E 100X

Statistical analysis

For the statistical analysis, SigmaStat software (SigmaStat for Windows, 1994-, Jandel Corporation, San Rafael, California, USA) was used. Differences in the mean number of MMC, atrophied and lytic glomeruli and necrotic tubules were analysed using the Student t-test. Differences in the frequency of degenerative and inflammatory lesions in the kidney and the degree of splenic congestion were analysed using the chi-square test. For all statistics, a p value of <0.05 was considered as significant.

RESULTS

Spleen

Most of the fish from both populations had mild to moderate splenic congestion (Fig. 2). The degree of splenic congestion did not differ significantly between farmed and wild fish ($\chi^2 = 0.25$; $p > 0.05$).

MMC in the spleen were numerous and well-defined (Fig. 3). They varied in colour from yellow to dark brown. The mean number of MMC was 32.38 ± 13.36 in farmed fish and 12.90 ± 2.49 in wild fish. The difference was significant ($t = 7.67$; $p < 0.05$).

Kidney

Glomerular lesions consisted of the atrophy (Fig. 5) and lysis of the glomerular tuft. The number of atrophied glomeruli was 1.61 ± 1.08 in farmed fish and 0.70 ± 0.8 in wild fish. Statistical analysis revealed that the difference was significant ($t = 3.5$; $p < 0.05$). The number of lytic glomeruli was 0.61 ± 0.71 in farmed fish and 0.55 ± 0.69 in wild fish. However, this difference was not significant ($t = 0.3$; $p > 0.05$). Inflammatory changes (accumulation of mononuclear cells) among tubules (Fig. 6) and degenerative lesions (vacuolar and/or hyaline degeneration) in the tubular epithelia (Fig. 7), as well as the number of necrotic tubules (Fig. 8) amongst the kidney tubules, were evaluated. The accumulation of inflammatory cells was

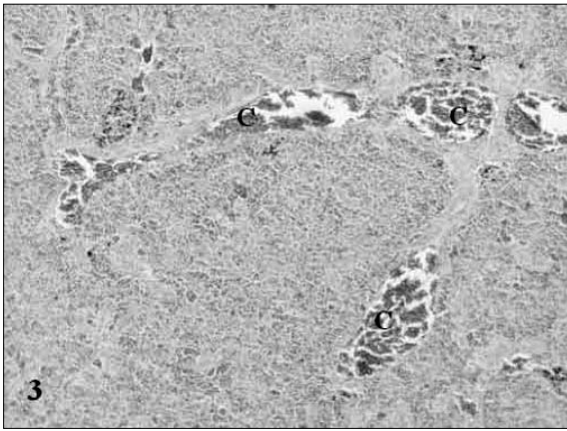


Fig. 3. Spleen from farmed sea bass. Congested blood vessels (C), H&E 100X

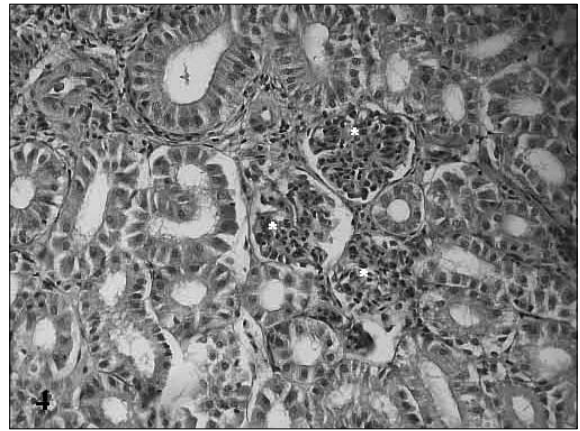


Fig. 4. Kidney from wild sea bass. Note normally developed glomerular tufts (*), H&E 400X

more frequent among tubules in farmed fish, but not significantly ($\chi^2 = 1.16$; $p > 0.05$).

Degenerative changes were found in 7 out of 30 farmed fish and 6 out of 20 fish from the wild population. Nevertheless, the difference in the frequency of occurrence of degenerative changes was not significant ($\chi^2 = 0.65$; $p > 0.05$). Necrotic lesions were more pronounced in farmed fish.

The number of necrotic tubules was 0.71 ± 1.04 in farmed fish and 0.60 ± 0.82 in wild fish, however, this difference was not significant ($t = 0.44$; $p > 0.05$).

In the kidney interstitium the number of MMC was evaluated. In most fish MMC were dark brown to black in colour. The mean number

was 2.0 ± 1.97 in farmed fish and 0.55 ± 1.09 in wild fish. The difference was statistically significant ($t = 3.37$; $p < 0.05$).

DISCUSSION

The physiological response to stress is well described in freshwater fish, particularly salmonids (PICKERING, 1993; LAITINEN & VALTONEN, 1994), while the data relating to marine fish are very limited (PAPOUTSOGLOU *et al.*, 1999). There are also few published reports of the histological response in fish to stressful conditions.

MMC are a nonspecific response and numerous factors are involved in their formation and

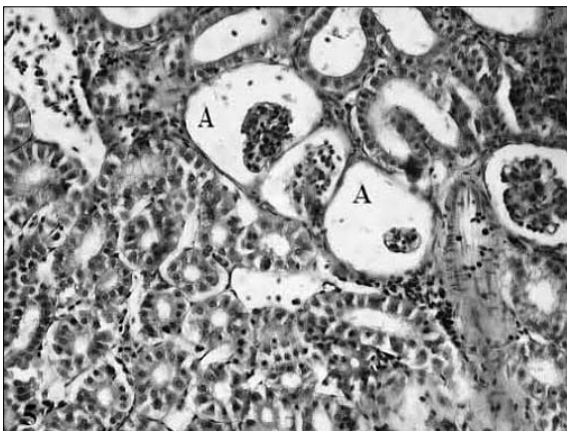


Fig. 5. Kidney from farmed sea bass. Atrophy of glomerular tuft (A), H&E 400X

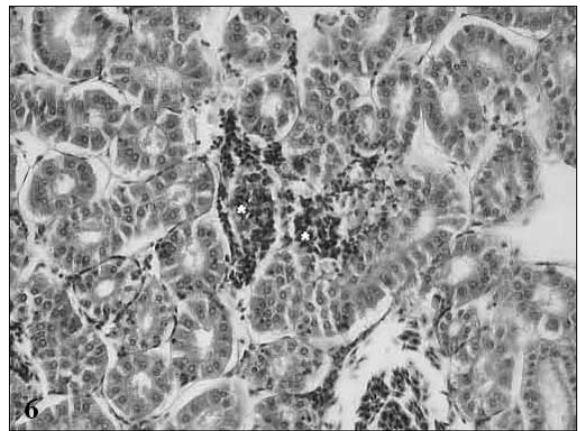


Fig. 6. Kidney from farmed sea bass. Accumulation of inflammatory cells (*), H&E 400X

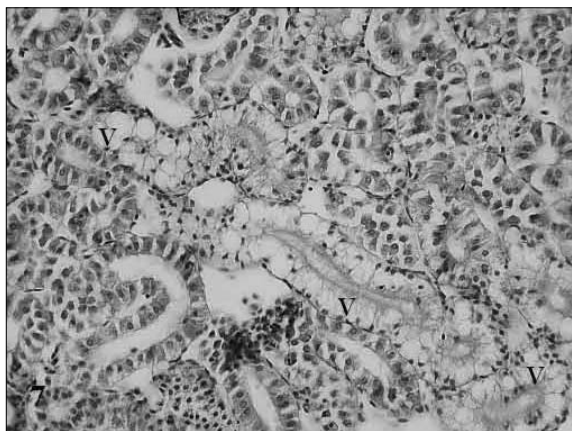


Fig. 7. Kidney from farmed sea bass. Vacuolar degeneration of tubular epithelial cells (V), H&E 400X

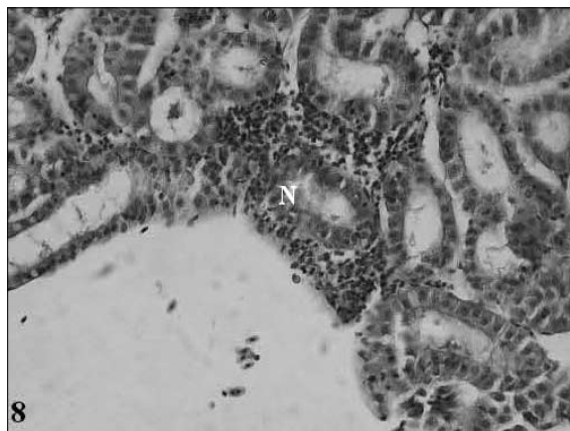


Fig. 8. Kidney from farmed sea bass. Tubular necrosis (N), H&E 400X

distribution. They are the deposition site for materials of exogenous (metals, biologically active particles) and endogenous (melanin, lipofuscin, ceroid, hemosiderin) origin. It is therefore necessary to understand how MMC are affected directly (metabolic effects of stress) and indirectly (nutritional deficiencies/ imbalance). High stocking density is considered a common stressful factor in intensive fish production (VIJAYAN & LEATHERLAND, 1988). There are published data on changes in the number of MMC caused by environmental changes (FOURNIE *et al.*, 2001). The present study revealed that the mean number of MMC was significantly higher ($p < 0.05$) in the spleens of farmed fish. This agrees with the results of MONTERO *et al.* (1999), who found increased numbers of splenic MMC with higher fish stocking density.

The mean number of MMC was also statistically higher ($p < 0.05$) in the kidneys of farmed fish. This agrees with previous literature reports (MONTERO *et al.*, 1999). Unlike splenic MMC, kidney MMC appear to be more influenced by the deficiency of antioxidants, particularly vitamin E. Vitamin E deficiency results in lipofuscin/ceroid accumulation secondary to increased lipid peroxidation (BLAZER & WOLKE, 1983). Vitamin E deficiency has also been reported to increase erythrocyte fragility, leading to the accumulation of hemosiderin (OBACH *et al.*, 1993).

Glomerular changes (atrophy and lysis of glomerular tuft) were more pronounced in the kidneys of farmed fish, though this was statistically significant only for atrophy ($p < 0.05$). There are no available reports of glomerular lesions associated with the effects of stress or improper feeding and there are only a few reports on glomerular lesions caused by water pollution (THIYAGARAJAH *et al.*, 1989) and nephrocalcinosis (ROBERTS, 2001).

Necrotic lesions were more pronounced in farmed fish although the difference with those observed in wild fish was not significant. There were no differences in the occurrence of degenerative lesions and accumulation of inflammatory cells in the kidneys of cultured and wild fish. Since the renal tubular epithelium has as its major function the excretion of divalent ions, pollution with heavy metals is likely to cause degenerative and necrotic changes (TRUMP *et al.*, 1989). THIYAGARAJAH *et al.* (1989) described similar lesions in fish from polluted waters. LAUREN *et al.* (1989) described hyaline degeneration of the renal tubular epithelium in rainbow trout as a result of oral intake of the antibiotic fumagilin. HICKS & GERACI (1984) described vacuolar degeneration in fish fed high doses of the antibiotic erythromycin. Vacuolar epithelial degeneration was a result of lysosomal distension.

CONCLUSION

The results of the present study indicate that the intensive culture of the European sea bass results in changes in the histology of spleen and kidney. However, further evaluations are required to determine the specific effects of the intensive culture process (commercial diet, stocking den-

sity and various technological aspects) on the histology of these organs of the sea bass.

ACKNOWLEDGEMENTS

We would like to thank Dr. David EDWARDS, FAO Aquaculture and fisheries consultant, for having edited the article.

REFERENCES

- AGIUS, C. & R.J. ROBERTS. 2003. Melano-macrophage centers and their role in fish pathology. *J. Fish Dis.*, 26: 499-509.
- BLAZER, V.S. & R.E. WOLKE. 1983. Ceroid deposition, retinal degeneration and renal calcium oxalate crystals in culture clownfish. *J. Fish Dis.*, 6: 365-376.
- COUILLARD, C.M., P.J. WILLIAMS., S.C. COURTENAY & G.P. RAWN. 1999. Histopathological evaluation of Atlantic tomcod (*Microgadus tomcod*) collected at estuarine sites receiving pulp and paper mill effluent. *Aquat. Toxicol.*, 44: 263-278.
- EATON, D.R. 1996. The identification and separation of wild-caught and cultivated sea bass (*Dicentrarchus labrax*) Fisheries Research Technical Report no. 103, Directorate of Fisheries Research, Lowestoft, 12 pp.
- ELLIS, A.E. 1980. Antigen-trapping in the spleen and kidney of the plaice (*Pleuronectes platessa* L.). *J. Fish Dis.*, 3: 413-426.
- FOURNIE, J.W., J.K. SUMMERS., L.A. COURTNEY, V.D ENGLE & V.S. BLAZER. 2001. Utility of splenic macrophage aggregates as an indicator of fish exposure to degraded environments. *J. Aquat. Anim. Health*, 13: 105-116.
- HICKS, B.D. & J.R., GERACI. 1984. A histological assesment of damage in rainbow trout, *Salmo gairdneri* Richardson fed rations containing erythromycin. *J. Fish Dis.*, 7: 457-66.
- HINTON, D.E. & D.J., LAURÉN. 1990. Integrative Histopathological Approaches to Detecting Effects of Environmental Stressors on Fishes. *Am. Fish. Soc. Symp.*, 8: 51-66.
- LAITINEN, M. & T. VALTONEN. 1994. Cardiovascular ventilatory and total activity responses of brown trout to handling stress. *J. Fish Biol.*, 45: 933-942.
- LAURÉN, D.J., A. WISHKOVSKY, J.M. GROFF, R.P. HEDRICK & D.E. HINTON. 1989. Toxicity and pharmacokinetics of the antibiotic fumagilin in yearling rainbow trout (*Salmo gairdneri*). *Toxicol. Appl. Pharm.*, 98: 444-453.
- MONTERO, D., V.S. BLAZER, J. SOCORRO, M.S. IZQUIERDO & L. TORT. 1999. Dietary and culture influences on macrophage aggregate parameters in gilthead seabream (*Sparus aurata*) juveniles. *Aquaculture*, 179: 523-534.
- OBACH, A.,C. QUENTEL & F. BAUDIN LAURENCIN. 1993. Effects of α -tocopherol and dietary oxidized fish oil on the immune response of sea bass (*Dicentrarchus labrax*). *Dis. Aqu. Org.*, 15: 175-185.
- PAPERNA, I. 1987. Systemic Granuloma of Sparid Fish in Culture. *Aquaculture*, 67: 53-58.
- PAPOUTSOGLOU, S.E., H. MILIOU, S. CHADIO, N. KARAKATSOULI & A. ZARKADA. 1999. Studies on stress responses and recovery from removal in gilthead sea bream *Sparus aurata* (L.) using recirculated seawater system. *Aquac. Eng.*, 21: 19-32.
- PICKERING, A.D. 1993. Growth and stress in fish production. *Aquaculture*, 11: 51-63.
- PRESS, C.M. 1998. Immunology of fishes. In: P.P. Pastoret, P. Griegel, H. Bazin & A. Govaerts (Editors). *Handbook of vertebrate immunology*. Academic Press, San Diego, pp 3-62.
- ROBERTS, R.J. 2001. *Fish Pathology*, 3rd Edition. W.B. Saunders, Philadelphia, 367 pp.
- ROCHA, E. & A.F. MONTEIRO. 1999. Histology and Cytology of Fish Liver: A Review. In: D.N. Saksena (Editor). *Ichthyology: Recent*

- Research Advances. Science Publishers Inc., Enfield, New Hampshire, pp. 321-344.
- THIYAGARAJAH, A., D.A. ZWERNER & W.J. HARGIS. 1989. Renal lesions in estuarine fishes collected from the Elizabeth river, Virginia. *JEPTO*, 9: 261-268.
- TRUMP, B.F., R.T. JONES & S. SAHAPHONG. 1989. Cellular effect of mercury on fish kidney tubules. In: R.J. Roberts (Editor). *Fish Pathol.*, Bailliere Tindall, London, pp. 100-106.
- VIJAYAN, M.M. & J.F. LEATHERLAND. 1988. Effects of stocking density on the growth and stress-response in brook charr, *Salvelinus fontinalis*. *Aquaculture*, 75: 159-170.
- VISOOTTIVISETH, P., T. THAMAMARUITKUN, S. SAHAPHONG, S. RIENGROJPITAK & M. KRUA-
RACHUE. 1999. Histopathological effects of triphenyltin hydroxide on liver, kidney and gill of Nile tilapia (*Oreochromis nilotica*). *Appl. Organomet. Chem.*, 12:749-763.
- WOLKE, R.E.G., C.J. GEORGE & V.S. BLAZER. 1985. Pigmented macrophage accumulations (MMC, PMB): possible monitors of fish health. In: W.J. Hargis (Editor). Washington D.C., NOAA Technical Report NMFS, 25, pp. 93-97.
- YASUTAKE, W.T. & J.H. WALES. 1983. Microscopic anatomy of salmonids: an atlas. In: W.T. Yasutake & J.H. Wales (Editors). U.S. Fish and Wildlife Service Resource Publication 150, 190 pp.

Received: 21 May 2008

Accepted: 18 September 2008

Usporedba histološke slike slezene i bubrega lubina (*Dicentrarchus labrax* L.) iz uzgoja i prirodne populacije

Božidar KURTOVIĆ*, Emin TESKEREDŽIĆ i Zlatica TESKEREDŽIĆ

*Laboratorij za istraživanje i razvoj akvakulture, Zavod za istraživanje mora i okoliša,
Institut «Ruđer Bošković», Bijenička cesta 54, 10 000 Zagreb, Hrvatska*

* Kontakt adresa, e-mail: bkurtovi@irb.hr

SAŽETAK

Svrha ovog rada bila je istražiti utjecaj intenzivnog uzgoja, na histološku sliku slezene i bubrega lubina. Istraživani su lubini iz intenzivnog uzgoja, uzgajani u kavezima i hranjeni industrijski proizvedenom kompletnom hranom, a kao kontrolna skupina poslužili su lubini iz prirodne populacije uzorkovani prilikom izlovljavanja ribe iz Tarske uvale, Istra. Istraživanje je bilo usmjereno na histološke promjene u slezeni i bubrezima. Rezultati histološke pretrage pokazali su da je prosječan broj MMC-a značajno povećan ($p < 0,05$) u slezeni i bubregu riba iz uzgajane populacije. Promjene na glomerulima (atrofija i liza glomerularnog pleteža kapilara) bile su izraženije kod riba iz uzgoja, ali samo atrofija statistički značajno ($p < 0,05$). Na bubrežnim kanalićima riba iz uzgajane populacije bile su izraženije nekrotične promjene, iako ne statistički značajno ($p > 0,05$). Nije utvrđena razlika u učestalosti degenerativnih promjena i nakupljanju upalnih stanica.

Ključne riječi: histologija, bubreg, slezena, stres, lubin