

## Bisalbuminemija kod bolesnika iz Hrvatske sa sarkoidozom

### Bisalbuminemia in a male Croatian patient with sarcoidosis

Ana-Maria Šimundić<sup>1</sup>, Marijana Miler<sup>1</sup>, Nora Nikolac<sup>1</sup>, Elizabeta Topić<sup>1</sup>, Dubravka Čaržavec<sup>2</sup>, Branka Milanović<sup>1</sup>, Vladimir Stančić<sup>2</sup>

<sup>1</sup>Klinički zavod za kemiju, KB „Sestre milosrdnice“, Zagreb

<sup>1</sup>University Department of Chemistry, Sestre milosrdnice University Hospital, Zagreb, Croatia

<sup>2</sup>Klinika za unutarnje bolesti, KB „Sestre milosrdnice“, Zagreb

<sup>2</sup>University Department of Internal Medicine, Sestre milosrdnice University Hospital, Zagreb, Croatia

#### Sažetak

**Uvod:** Urođena bisalbuminemija je rijetka bolest, najčešće prisutna u benignom obliku, dosad opisivana u nekoliko patoloških stanja. Već su opisane dvije genske varijante kod dvije hrvatske obitelji. U ovom radu izvještavamo o novom slučaju bisalbuminemije kod bolesnika iz Hrvatske sa sarkoidozom.

**Metode:** Bolesnik je, od strane liječnika opće prakse, upućen u KB „Sestre milosrdnice“ na dijagnostički pregled pod sumnjom na sarkoidozu. Napravljena je kapilarna elektroforeza proteina u serumu s automatiziranim uređajem za kapilarnu elektroforezu.

**Rezultati:** Temeljem laboratorijskih i patoloških nalaza potvrđena je sarkoidoza. Elektroforezom u serumu otkrivene su dvije različite frakcije albumina. Dodatna frakcija albumina bila je sporo migrirajuća. Ta sporo migrirajuća frakcija činila je 0,48, a normalna 0,51 ukupnog albumina. Sestra bolesnika također je imala bisalbuminemiju.

**Zaključak:** Ovo je novi slučaj urođene bisalbuminemije kod bolesnika sa sarkoidozom. Ima li bisalbuminemija ikakve veze sa sarkoidozom, potrebno je tek razjasniti. Svaki slučaj pojave urođenih ili stečenih frakcija albumina trebao bi probuditi pažnju medicinskih biokemičara i kliničara, jer bi mogao pružiti uvid u evoluciju proteina kao i u fizičke, kemijske i molekularne karakteristike albumina.

**Ključne riječi:** bisalbuminemija; kapilarna zonska elektroforeza; genetička heterogenost; sarkoidoza; albumin u serumu

#### Abstract

**Background:** Inherited bisalbuminemia is rare, mostly benign state, which has so far been described in several pathological conditions. Two genetic variants have already been described in two Croatian families. Herein we report a new case of bisalbuminemia in a Croatian male patient with sarcoidosis.

**Methods:** The patient was referred by a general practitioner to our hospital for a diagnostic work up for suspected sarcoidosis. Serum capillary protein electrophoresis was performed with automated capillary electrophoresis system.

**Results:** Based on laboratory and pathologic findings, diagnosis of sarcoidosis was confirmed. Serum electrophoresis revealed two distinct albumin bands. Additional albumin variant was slow-migrating. The slow and a normal band made up for 0.48 and 0.51 of the total albumin, respectively. The patient's sister was also bisalbuminemic.

**Conclusions:** This is a new case of inherited bisalbuminemia in a patient with sarcoidosis. Whether bisalbuminemia has any relevance to sarcoidosis, remains to be elucidated. Clinical chemists and clinicians should be alerted by every case of either inherited or acquired albumin variant, because it could provide insight into the protein evolution as well as the physical, chemical and molecular characteristics of albumin.

**Key words:** bisalbuminemia; capillary zone electrophoresis; genetic heterogeneity; sarcoidosis; serum albumin

*Pristiglo: 18. studenog 2008.*

*Prihvaćeno: 15. prosinca 2008.*

*Received: November 18, 2008*

*Accepted: December 15, 2008*

#### Uvod

Bisalbuminemija predstavlja rijedak poremećaj karakteriziran pojavom dviju vrpca u albuminskoj frakciji prilikom elektroforeze proteina u serumu. (1). Taj poremećaj albumina može biti urođen ili stečen. Albumin u serumu nije

#### Introduction

Bisalbuminemia represents a rarely encountered abnormality, characterised by the occurrence of bicuspid electrophoretic pattern in the albumin fraction detected on serum electrophoresis (1). This albumin abnormality may

glikoliziran, negativnog je naboja i čini najveći dio plazmatskih proteina. Minchiotti i sur. nedavno su iscrpno izvjestili o mutacijama i polimorfizmima na genu za albumin (2). Dosad je poznato 77 mutacija, od kojih 65 rezultira bisalbuminemijom u serumu, a 12 analbuminemijom (stanje koncentracije albumina u serumu niže od 1 g/L). Urođena bisalbuminemia je autosomno dominantno stanje (3) koje se pojavljuje s učestalošću od 1:1.000 do 1:10.000 (4). Stečeni oblici bisalbuminemije opisani su u bolesnika koji su primili visoke doze penicilina (5,6) te u bolesnika s ascitesom i pseudocistom gušterače (7).

Iako je u većini slučajeva benigna, bisalbuminemia se opisuje u nekoliko patoloških stanja, kao što su nefrotički sindrom (8,9), kronična bolest bubrega (10), Alzheimerova bolest (11) i benigna monoklonska gamopatija (12). Dvije genske varijante već su opisane kod dvije hrvatske obitelji: sporo migrirajući albumin *Zagreb* i brzo migrirajući albumin *Krapina* (13, 14).

U ovom članku izvještavamo o bisalbuminemiji kod četrdesetšestogodišnjaka iz Hrvatske, koji boluje od sarkoidoze. Koliko nam je poznato bisalbuminemia još nije opisana u bolesnika s sarkoidozom.

## Materijali i metode

### Prikaz slučaja

Četrdesetšestogodišnjak iz Hrvatske (M.L.), nepušač, upućen je od strane liječnika opće prakse na Kliniku za unutarnje bolesti Kliničke bolnice "Sestre milosrdnice" (Zagreb, Hrvatska) na dijagnostički pregled sa simptomima *erythema nodosum* donjih ekstremiteta i bilateralne hilarne limfadenopatije. Bolesnik nije imao temperaturu, nije kao je umor i bilo kakve probleme u dišnom sustavu. Njegova je anamneza uključivala hiperlipidemiju u posljednjih 15 godina i povećano konzumiranje alkohola (1 litra vina dnevno) tijekom posljednje dvije godine. Bolesnik je, prema svojim riječima, tijekom prethodnog tjedna 3 dana preventivno uzimao azitromicin zbog moguće bolesti prenosive ubodom kukca. Tijekom dva tjedna prije dolaska u našu Kliniku, bolesnik je bio na pretragama u drugim ustanovama i dobiveni rezultati bili su sljedeći: scintigrafija kostiju donjeg dijela noge bila je uredna, rendgen donjeg dijela noge pokazao je osteoidni osteom u lijevoj potkoljenici, rendgen prsa otkrio je bilateralnu hilarnu limfadenopatiju, urinokultura je bila negativna, ultrazvuk bubrega pokazao je dvije male ciste na lijevom bubregu. Broj eritrocita, broj leukocita, C-reaktivni protein, mokraćna kiselina i reumatoidni faktor su također bili unutar granica referentnog raspona. Bolesnik je imao normalnu tjelesnu težinu i inače se dobro osjećao. Bolesnik je primljen u našu kliniku na daljnji dijagnostički pregled.

Bolesnik je dao informirani pismeni pristanak za objavljivanje ovog prikaza.

be both genetic and acquired. Serum albumin is non-glycosylated, negatively charged, most abundant plasma protein and its mutations and polymorphisms have recently been extensively reviewed by Minchiotti et al. (2). So far, there are 77 known mutations of the serum albumin gene, with 65 of them resulting in bisalbuminemia and 12 in analbuminemia (state of serum albumin concentration less than 1 g/L). Inherited bisalbuminemia is an autosomal dominant condition (3) which occurs with the cumulative frequency of 1:1000 to 1:10,000 (4). Acquired forms of bisalbuminemia are described in patients receiving high penicillin doses (5,6) and in patients with ascites or pancreatic pseudocyst (7).

Though being mostly benign, bisalbuminemia has been described in several pathological conditions such as nephrotic syndrome (8,9), chronic kidney disease (10), Alzheimer disease (11) and benign monoclonal gammopathy (12). Two genetic variants have already been described in two Croatian families i.e. slow-migrating albumin *Zagreb* and fast-migrating albumin *Krapina* (13,14).

In this article we report a case of bisalbuminemia in a 46-year-old Croatian male patient with sarcoidosis. To the best of our knowledge, bisalbuminemia in sarcoidosis has not yet been reported.

## Materials and methods

### Case history

A 46-year-old non-smoking male Croatian (M. L.) was referred by a general practitioner to the University Department of Internal Medicine, Sestre milosrdnice University Hospital (Zagreb, Croatia) for a diagnostic work-up with symptoms of *erythema nodosum* of lower extremities and bilateral hilar lymphadenopathy. The patient was afebrile, denied fatigue and any respiratory symptoms. His past medical history included hyperlipidemia for the last 15 years and excessive alcohol consumption (1 liter of wine daily) for the last two years. The patient claimed he had received a three-day prophylactic course of azithromycin during the previous week for diseases transmitted by insect bite. Prior to his visit to our Department, the patient had during a two-week period undergone some examinations elsewhere and obtained the following results: bone scintigraphic examination of the lower leg showed no abnormalities, radiograph of the lower leg showed *osteoid osteoma* in the left tibia, chest radiograph revealed enlarged bilateral pulmonary hila, urine culture was negative, kidney ultrasound showed two small cysts on the left kidney. Red blood cell count (RBC), white blood cell count (WBC), C-reactive protein, uric acid, rheumatoid factor were also within referent interval. The patient was of normal body weight and otherwise well. He was admitted to our Department for further diagnostic wor-

## Metode

Naš standardni dijagnostički pregled u slučaju sumnje na sarkoidozu uključuje standardni elektrokardiogram (EKG) te rendgen pluća. Bolesnika je pregledao pulmolog. Napravljena je i spirometrija, kako bi se procijenio forsirani vitalni kapacitet (engl. *forced vital capacity*, FVC), forsirani ekspiracijski volumen u prvoj sekundi (engl. *forced expiratory volume in 1 second*, FEV1) te omjer FEV1/FVC.

Od bioloških uzoraka, uzeti su mokraća, serum i plazma (EDTA i citrat), kako bi se načinile rutinske laboratorijske pretrage. Biokemijski parametri određeni su na automatiziranom biokemijskom analizatoru Olympus AU2700 (Olympus, Hamburg, Njemačka). Hematološki i koagulacijski parametri određeni su automatiziranim analizatorima Cell-Dyn Sapphire (Abbott Laboratories, Abbott Park, IL, SAD), odnosno BCS Coagulation Analyzer (Dade Behring, Marburg, Njemačka).

Koncentracije imunoglobulina IgA, IgG i IgM određene su nefelometrijom na automatiziranom analizatoru BN II (Dade Behring, Marburg, Njemačka).

Kapilarna elektroforeza proteina u serumu napravljena je automatiziranim sustavom za kapilarnu elektroforezu Capillarys System (Sebia, Issy-les-Moulineaux, Francuska) prema uputama proizvođača reagensa Capillarys protein(E) 6 (Sebia, Issy-les-Moulineaux, Francuska). Ukratko, uzorci se razrjeđuju u analizatoru u omjeru (1:10) i zatim se injektiraju na anodnom kraju silikonskih kapilara. Molekule s nabojem odvajaju se u bazičnom puferu (pH 9,9) prema elektroforetskoj pokretljivosti na 300 V. Odvajanje proteina odvija se u kapilarama, a proteini se detektiraju na katodnom kraju kapilara pri 200 nm.

Dijagnoza sarkoidoze postavljena je na osnovi bolesnikove anamneze, kliničkih simptoma i laboratorijskih i patoloških nalaza.

## Rezultati

Medicinskim pregledom otkriveno je slijedeće: rendgen bolesnikovih pluća potvrdio je prethodno primijećenu bilateralnu hilarnu limfadenopatiju, bez ikakvih promjena u intersticiju. Spirometrija je pokazala normalnu plućnu funkciju: forsirani ekspiracijski volumen u prvoj sekundi (FEV1) od 4,491 (118%) i forsirani vitalni kapacitet (FVC) od 5,221 (115%); omjer FEV1/FVC bio je 0,95.

Hematološki, koagulacijski te većina biokemijskih parametara bili su unutar granica referentnog raspona, s iznimkom koncentracije ukupnog kolesterola (7,7 mmol/L; preporučena vrijednost <5,0 mmol/L), koncentracije LDL-kolesterola (5,3 mmol/L; preporučena vrijednost <3,0 mmol/L) i aktivnosti angiotenzin-konvertirajućeg enzima (engl. *angiotensin-converting enzyme*, ACE) (64,5 U/L; referentni raspon <52 U/L) koje su bile povišene. Koncentracija imunoglobulina IgM, IgA i IgG u serumu bila je unutar granica referentnog raspona.

k-up. Written consent was obtained from the patient to publish this report.

## Methods

Our standard diagnostic work-up for suspected sarcoidosis included: standard 12-lead electrocardiogram (EKG), chest X-ray radiography. The patient was seen by a pulmonologist. He underwent spirometry examination to assess the forced vital capacity (FVC), forced expiratory volume in 1 second (FEV1) and the FEV1/FVC ratio.

Urine, serum and plasma (EDTA and citrate) were collected for routine laboratory tests. Biochemistry parameters were assayed on automated Olympus AU2700 clinical chemistry analyzer (Olympus, Hamburg, Germany). Haematology and coagulation parameters were determined with automated analyzers Cell-Dyn Sapphire (Abbott Laboratories, Abbott Park, IL, USA) and BCS Coagulation Analyzer (Dade Behring, Marburg, Germany), respectively.

Immunoglobulin IgA, IgG and IgM concentrations were determined by nephelometry using the automated BN II analyzer (Dade Behring, Marburg, Germany).

Serum capillary protein electrophoresis was performed with automated capillary electrophoresis Capillarys System (Sebia, Issy-les-Moulineaux, France) according to manufacturer's instruction for Capillarys protein(E) 6 kit (Sebia, Issy-les-Moulineaux, France). Briefly, the samples, automatically diluted with buffer (1:10), were injected at the anodic end of silica capillaries. Charged molecules were separated by their electrophoretic mobility in an alkaline buffer (pH 9.9) at 300 V. Protein separation was performed in capillaries and direct detection of proteins was made at 200 nm at the cathodic end of the capillary.

Diagnosis of sarcoidosis was made based on patient history, compatible clinical features along with laboratory and pathologic findings (15).

## Results

Medical examination revealed the following: patient chest radiography confirmed previously observed enlarged bilateral pulmonary hila, without any interstitial changes. Spirometry revealed normal ventilation: forced expiratory volume in one second (FEV1) of 4.94l (118%), and forced vital capacity (FVC) of 5.22l (115%); FEV1/FVC ratio was 0.95.

Haematological, coagulation and most of the biochemical parameters were within the normal range with the exception of total cholesterol (7.7 mmol/L; recommended value <5.0 mmol/L), LDL-cholesterol concentration (5.3 mmol/L; recommended value <3.0 mmol/L) and angiotensin-converting enzyme (ACE) activity (64.5 U/L; referent range <52 U/L) which were elevated. The patient

Elektroforeza serumskih proteina otkrila je dvije različite frakcije albumina na anodnom kraju (Slika 1.). Frakcije su bile nejednakih relativnih količina. Nova vrsta albumina bila je sporije migrirajuća nego standardni albumin. Ukupna koncentracija proteina bila je 65 g/L, s omjerom albumina prema globulinu 1,63 (referentni raspon 0,80–2,00). Udjeli sporo migrirajućeg i normalnog albumina bile su 0,48, odnosno 0,51 od ukupnog albumina. Tri, odnosno šest mjeseci nakon prvog posjeta klinici ponovno smo ispitali serum bolesnika, koji je još uvijek imao bisalbuminemiju.

Bolesnikova najbliža rođakinja (sestra, D.L.) također je pristala dati uzorak krvi. Elfelogram serumskih proteina njenog uzorka bio je identičan slici našeg bolesnika s bisalbuminemijom (M.L.), što je ukazalo na nasljednu prirodu te vrste albumina.

## Rasprava

Prije više od 50 godina više je autora opazilo bisalbuminemiju (1,16,17) i od tada je taj poremećaj intenzivno ispitivalo nekoliko istraživačkih skupina. Dosad je velika većina promjena molekule albumina opsežno okarakterizirana (2). Ta su saznanja čvrsta osnova za daljnja istraživanja o svojstvima vezanja liganda na molekule albumina (18,19,14). Iako su opisane frakcije s promijenjenim afinitetom prema trijodtironinu ( $T_3$ ) i tiroksinu ( $T_4$ ) (20), te masnim kiselinama (21), izgleda da je ukupan učinak promjene sekvence aminokiseline na karakteristike vezanja liganda zanemariv i od manjega kliničkog značaja. Nadalje, o bisalbuminemiji se dosad najčešće izvještavalo kao o benignom stanju, zapaženom kao popratna poja-

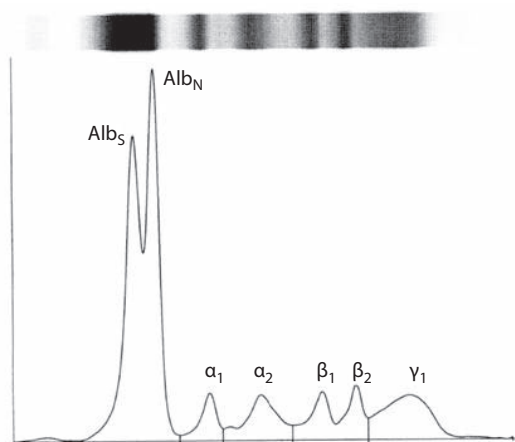
had serum IgM, IgA and IgG immunoglobulin concentrations within the normal range.

Serum electrophoresis revealed two distinct albumin bands at anodic end (Figure 1). The bands were of unequal relative amounts. New albumin variant band had slower mobility compared to normal albumin. Total protein concentration was 65 g/L, with the albumin to globulin ratio of 1.63 (reference range: 0.80–2.00). Slow-migrating and normal band concentrations were 0.48 and 0.51 of the total albumin, respectively. The patient's serum was re-examined and remained bisalbuminemic three and six months after his first visit.

The patient's first degree relative (sister, D. L.) also consented to give blood sample. Her serum electrophoretic pattern was identical to our bisalbuminemic patient (M. L.), which indicated the inheritable nature of the albumin variant.

## Discussion

Bisalbuminemia was observed by several authors more than 50 years ago (1,16,17) and it has been under intense investigation by several research groups ever since. So far, vast majority of albumin molecular defects have been extensively characterized (2). Those data have provided solid basis for further studies on the ligand binding properties of the albumin molecule (14,18,19). Although variants with altered affinity to triiodothyronine ( $T_3$ ) and thyroxine ( $T_4$ ) (20), fatty-acids (21) have been described, the overall effect of the amino-acid sequence change on the ligand-binding properties is supposed to be negligible and of minor clinical significance. Furthermore, bi-



**SLIKA 1.** Kapilarna elektroforeza proteina u serumu od bolesnika sa sarkoidozom. Proteini u serumu odijeljeni su u sljedeće frakcije: Alb<sub>S</sub> (novopronađena frakcija albumina spore migracije), Alb<sub>N</sub> (standardni albumin), α<sub>1</sub>, α<sub>2</sub>, β<sub>1</sub>, β<sub>2</sub> i γ globulini.

**FIGURE 1.** Capillary electrophoresis of serum proteins from a patient with sarcoidosis. Serum proteins are separated into following fractions: Alb<sub>S</sub> (newly encountered slow-migrating albumin variant), Alb<sub>N</sub> (normal albumin), α<sub>1</sub>, α<sub>2</sub>, β<sub>1</sub>, β<sub>2</sub> and γ globulins.

va osnovnoj bolesti ili patološkom stanju. Jedinu iznimku predstavlja obiteljska bisalbuminijska hipertrijodotironinemija o kojoj su prvi put izvijestili Sunthorntheparakul i sur. (22) kod članova obitelji s Tajlanda s klinički normalnom funkcijom gušterače i visokom koncentracijom ukupnog  $T_3$  u serumu. Nakamura i sur. (23) pružili su daljnje dokaze o ulozi frakcija albumina kao uzroka hipertrijodotironinemije u podlozi kod 56-godišnje Japanke. Klinički bi endokrinolozi uvijek trebali uzeti u obzir moguću prisutnost frakcija albumina kod bolesnika s povišenom koncentracijom  $T_3$  i  $T_4$  ako ne postoje drugi očigledni razlozi za to povećanje. Više je autora prikazalo nadmoćnost kapilarne zonske elektroforeze (engl. *capillary zone electrophoresis*, CZE) u usporedbi s elektroforezom u agaroznom gelu (engl. *agarose gel electrophoresis*), zbog bitno poboljšanog razdvajanja albumina,  $\alpha_1$  i  $\alpha_2$  frakcija (1,12). Stoga, ako se sumnja na prisutnost frakcija albumina, treba provesti kapilarnu zonsku elektroforezu, budući da je to metoda prvog izbora za takve slučajeve.

U ovom smo radu prikazali jedan novi slučaj urođene bisalbuminemije kod bolesnika sa sarkoidozom. Prema našim spoznajama bisalbuminemija do sada nije opisana u bolesnika sa sarkoidozom. Sarkoidoza je bolest nepoznate etiologije, koja zahvaća više organa s višestrukim kliničkim manifestacijama i patološkim nalazima. Ima li pojava bisalbuminemije ikakve važnosti za etiopatofiziološki mehanizam ove bolesti jest pitanje koje tek treba razjasniti. Mi, nažalost, trenutno nismo bili u mogućnosti dalje istražiti sekvencu DNA, kao niti strukturne i funkcionalne osobine ove frakcije albumina. Naš je cilj takvu analizu napraviti u suradnji s drugim istraživačkim skupinama.

I medicinski biokemičari i liječnici bi uvijek trebali biti na oprezu kod svakog novog slučaja pojave urođenih i stečenih frakcija albumina, jer bi to moglo pružiti nove podatke o evoluciji proteina kao i o fizičkim, kemijskim i molekularnim karakteristikama molekule albumina, što može dovesti do otkrića i razvoja novih potencijalnih pristupa terapiji. Ako se, pak, dokaže da je stečena, slučaj bisalbuminemije može ukazati na neko osnovno patofiziološko stanje, kao npr. pseudocistu gušterače, pružajući liječniku dodatne kliničke informacije koje mogu pomoći pri postavljanju diferencijalne dijagnoze.

### Zahvala

Ovaj je rad nastao uz potporu Ministarstva znanosti, obrazovanja i športa Republike Hrvatske; broj projekta: 134-1340227-0200. Nadalje, autori žele iskazati svoju zahvalnost prof. dr. sc. Slavici Dodig iz Dječje bolnice Srebrnjak, za svesrdnu pomoć i vrlo korisne savjete tijekom pripreme rukopisa.

salbuminemia has so far most commonly been reported as benign condition, found as a concomitant phenomenon, secondary to the underlying disease or pathological condition. The only exception is familial dysalbuminemic hypertriiodothyroninemia, first reported by Sunthorntheparakul et al. (22) in a clinically euthyroid members of a Thai family that presented with high serum total  $T_3$  concentration. Further evidence on the role of albumin variant as the underlying cause of hypertriiodothyroninemia was provided by Nakamura et al. (23) in a report on a 56-year-old Japanese female. Clinical endocrinologists should always consider the presence of possible albumin variant in a patient with elevated  $T_3$  and  $T_4$  when there are no other obvious reasons for this increase. Capillary zone electrophoresis (CZE) has been shown by some authors to be superior to agarose gel electrophoresis because of the substantially improved separation of albumin,  $\alpha_1$  and  $\alpha_2$  fractions (12,24). Therefore, when the presence of albumin variant is suspected, CZE should be performed since it is the electrophoretic method of choice for this purpose.

In this study, we present a new case of inherited bisalbuminemia in a patient with sarcoidosis. To the best of our knowledge, bisalbuminemia has never been previously reported in sarcoidosis. Sarcoidosis is a multisystem disease of unknown aetiology with multiple clinical manifestations and pathological findings. Whether the occurrence of bisalbuminemia has any relevance to the etiopathophysiological mechanism of this disease remains to be elucidated. At this moment we were unfortunately not able to further explore the nucleic acid sequence as well as the structural and functional characteristics of this albumin variant. It is our aim to perform such analysis in collaboration with some other research groups.

Both clinical chemists and medical doctors should always be alerted by every new case of either inherited or acquired albumin variant because it could provide some new data on the protein evolution as well as the physical, chemical and molecular characteristics of the albumin molecule, which may lead to the discovery and development of some new potential therapeutic approaches. If proven to be acquired, bisalbuminemia finding may point to some underlying pathophysiological condition such as pancreatic pseudocysts, offering the physician some additional clinical information which may help in differential diagnosis.

### Acknowledgement

This study was supported by the Ministry of Science, Education and Sports, Republic of Croatia; project number: 134-1340227-0200. The authors would also like to thank to Prof. Slavica Dodig, PhD (Srebrnjak Children's Hospital), for very useful comments and kind assistance in preparing this manuscript.

**Adresa za dopisivanje:**

Ana-Maria Šimundić  
 Klinički zavod za kemiju  
 KB "Sestre milosrdnice"  
 Vinogradska 29  
 10000 Zagreb  
 e-pošta: am.simundic@gmail.com

**Corresponding author:**

Ana-Maria Šimundić  
 Clinical Institute of Chemistry  
 Sestre milosrdnice University Hospital  
 Vinogradska 29  
 10000 Zagreb  
 Croatia  
 e-mail: am.simundic@gmail.com

**Literatura/References**

1. Sarcione EJ, Aungst W. Studies in bisalbuminemia: Binding properties of the two albumins. *Blood* 1962;20:156-64.
2. Minchiotti L, Galliano M, Kragh-Hansen U, Peters T Jr. Mutations and polymorphisms of the gene of the major human blood protein, serum albumin. *Hum Mutat* 2008;29:1007-16.
3. Kumit DM, Phillip BW, Bruns GA. Confirmation of the mapping assignment of human serum albumin to chromosome 4 using a cloned human albumin gene. *Cytogenet Cell Genet* 1982;34:282-8.
4. Tárnoky AL. Genetic and drug-induced variation in serum albumin. *Adv Clin Chem* 1980;21:101-46.
5. Arvan DA, Blumberg BS, Melartin L. Transient "bisalbuminemia" induced by drugs. *Clin Chim Acta* 1968;22:211-8.
6. Rocha J, Bohner J, Kömpf J. Transient bisalbuminemia: separation by isoelectric focusing of human albumin fractions linked to different numbers of benzylpenicilloyl groups. *Electrophoresis* 1995;16:1031-3.
7. Kobayashi S, Okamura N, Kamoi K, Sugita O. Bisalbumin (fast and slow type) induced by human pancreatic juice. *Ann Clin Biochem* 1995;32:63-7.
8. Hoang MP, Baskin LB, Wians FH Jr. Bisalbuminuria in an adult with bisalbuminemia and nephrotic syndrome. *Clin Chim Acta* 1999;284:101-7.
9. Ahmad J, Khan AS, Siddiqui MA, Tewari SG, Khan RU. Bisalbuminemia in nephrotic syndrome (a case report). *Jpn J Med* 1984;23:45-7.
10. Ejaz AA, Krishna M, Wasilik A, Knight JD. Bisalbuminemia in chronic kidney disease. *Clin Exp Nephrol* 2004;8:270-3.
11. Shetty JK, Prakash M, Gopalakrishna K. Bisalbuminemia in an adult male with Alzheimer's disease. *Indian J Med Sci* 2007;61:356-7.
12. Kalambokis G, Kitsanou M, Kalogera C, Kolios G, Seferiadis K, Tsianos E. Inherited bisalbuminemia with benign monoclonal gammopathy detected by capillary but not agarose gel electrophoresis. *Clin Chem* 2002;48:2076-7.
13. Dodig S, Cepelak I, Benko B, Raos M, Branovic K. Bisalbuminemia in two Croatian families. *Arch Med Res* 2000;31:608-12.
14. Kragh-Hansen U, Campagnoli M, Dodig S, Nielsen H, Benko B, Raos M, et al. Structural analysis and fatty acid-binding properties of two Croatian variants of human serum albumin. *Clin Chim Acta* 2004;349:105-12.
15. Judson MA. Sarcoidosis: clinical presentation, diagnosis, and approach to treatment. *Am J Med Sci* 2008;335:26-33.
16. Knedel M. Double albuminemia, a new hereditary protein anomaly. *Blut* 1957;3:129-34.
17. Wuhrmann F. Double albumin peak as a hereditary blood protein anomaly. *Schweiz Med Wochenschr* 1959;89:150-2.
18. Reed RG. Ligand-binding properties of albumin Parklands: Asp365----His. *Biochim Biophys Acta* 1988;965:114-7.
19. Kragh-Hansen U, Chuang VT, Otagiri M. Practical aspects of the ligand-binding and enzymatic properties of human serum albumin. *Biol Pharm Bull* 2002;25:695-704.
20. Sarcione EJ, Aungst CW. Bisalbuminemia associated with albumin thyroxine-binding defect. *Clin Chim Acta* 1962;7:297-8.
21. Minchiotti L, Kragh-Hansen U, Nielsen H, Hardy E, Mercier A-Y, Galliano M. Structural characterization, stability and fatty acid-binding properties of two French genetic variants of human serum albumin. *Biochim Biophys Acta* 1999;1431:223-31.
22. Sunthornthepvarakul T, Likitmaskul S, Ngongarmratana S, Angsingha K, Kitvitayasak S, Scherberg NH, et al. Familial dysalbuminemic hypertriiodothyroninemia: a new, dominantly inherited albumin defect. *J Clin Endocrinol Metab* 1998;83:1448-54.
23. Nakamura S, Kajita Y, Ochi Y. Familial dysalbuminemic hypertriiodothyroninemia in a Japanese kindred. *Intern Med* 2000;39:50-4.
24. Jaeggi-Groisman SE, Byland C, Gerber H. Improved sensitivity of capillary electrophoresis for detection of bisalbuminemia. *Clin Chem* 2000;46:882-3.