

Potential prophylactic role of aminoguanidine in diabetic retinopathy and nephropathy in experimental animals

AMANY HASSAN M. EI SHAZLY^{1,*}
ATEF MOHAMED MAHMOUD²
NEVINE SALAH DARWISH³

¹Department of Pharmacology
²Biochemistry and
³Histology Research
Institute of Ophthalmology
Giza, Egypt

This study sought to determine the potential prophylactic and antioxidant effects of aminoguanidine in experimentally induced diabetes. Four groups of Wistar rats, each composed of ten rats, were used. Two groups served as control. In group 3, diabetes was induced by a single intraperitoneal injection of streptozotocin (65 mg kg⁻¹). In group 4, diabetes was induced and treated with aminoguanidine (100 mg kg⁻¹ daily) orally for 3 months. Levels of serum glucose, glutathione peroxidase, glutathione reductase and erythrocytes catalase were analyzed on day 90 of the experiment. Retinal and kidney specimens were examined histopathologically after sacrifice of the animals. A significant antioxidant effect of aminoguanidine and its prophylactic role in diabetic retinopathy and nephropathy were observed in experimental animals.

Keywords: aminoguanidine, diabetic retinopathy, nephropathy, nitric oxide, glycated end product, antioxidants

Accepted February 9, 2009

Diabetes mellitus (DM) complications were attributed to deposition of glycosylation products on the interstitial tissue proteins and blood vessel walls, forming irreversible advanced glycosylation end products (AGEs) (1). In diabetic retinopathy, deposition of AGEs and plasma proteins in basement membranes resulted in retinal capillary closure, retinal hemorrhages and micro-aneurysms (2). AGEs altered the expression of certain genes that affect cellular growth, differentiation, inflammation and angiogenesis, which are the basis of ischemic and proliferative diabetic retinopathy (3). Moreover, hyperglycemia stimulated inducible nitric oxide synthetase enzyme (iNOS) and nitric oxide (NO) synthesis (4, 5). NO and iNOS modulated the proinflammatory and profibrotic pathways in the progression of diabetic nephropathy (6). Additionally, endogenous antioxidant enzymes such as serum catalase, glutathione peroxidase (GPx) and increased glutathione reductase (GR) were reported to decrease in chronic hyperglycemia (7). A synergistic relation between AGEs and serum antioxidant enzymes was suggested (8).

* Correspondence; e-mail: Amany.namaky@yahoo.com; Amany.namaky@gmail.com

Aminoguanidine is a breaker of AGEs (9) and a selective blocker of iNOS with an antioxidant effect. It can decrease the oxidative modification in leucocytes and plasma proteins in diabetic rats (10). Aminoguanidine ameliorated diabetic retinopathy after its oral administration in a diabetic rat model (3). Furthermore, it improved diabetic nephropathy in a diabetic rat model with preserved mesangial spaces, with no focal basement membrane thickening and low urinary albumin excretion (11).

In this article, the effect of aminoguanidine in preventing or ameliorating retinal and renal changes was investigated in experimentally induced diabetic rats as well as its relation to antioxidant activity.

EXPERIMENTAL

To induce an animal model of diabetes, Wistar strain rats were injected intraperitoneally with a dose of 65 mg kg⁻¹ streptozotocin (Sigma, Germany). About 25 % of the rats died during the following 72 hours. The blood glucose level of the living rats was measured after 48 hours, then weekly. Diabetes was defined as a fasting blood glucose level exceeding 120 mg per 100 mL.

Animals

Forty Wistar rats weighing 140–150 grams, aged 3 months, of both sexes were used. They were used in accordance with the institutional guidelines for use of animals in ophthalmic and vision research. Approval of the institutional authority for laboratory animal care and approval from the ethical committee were obtained. They were individually housed in separate cages under standardized temperature (25–28 °C), humidity (50–60 %), and light (12 hours light-dark) conditions. They were fed the standard diet and tap water for three months. Animals were divided into four groups of ten rats each. Group 1 animals received a uniform volume of distilled water (0.5 mL) once daily by means of a stomach tube (negative control). Group 2 animals received daily a single oral dose of aminoguanidine (100 mg kg⁻¹) dissolved in an appropriate volume of distilled water through a stomach tube (positive control), beginning on day 3 of the experiment. Group 3 diabetes model was induced and the animals were left untreated. Group 4 diabetes model was induced and the animals received a single oral dose of aminoguanidine (100 mg kg⁻¹) daily dissolved in an appropriate volume of distilled water through the stomach tube on day 3 upon induction of diabetes.

Biochemical analysis

Blood samples were taken on day 90 of the experiment. Levels of plasma glucose and creatinine were determined using commercial kits from Biocon (Germany). Glutathione peroxidase activity (GPx), glutathione reductase activity (GR) and catalase enzyme activity were determined by the colorimetric method described by kits from Diaclone France.

Histopathological examination

The animals were killed after 90 days by intravenous injection of toxic dose of a phenobarbital (Sigma, Germany). Eyes were enucleated and dissected. Retinas were immediately double fixed in 4 % glutaraldehyde buffer, followed by 1.3 % osmium tetroxide in phosphate buffer (pH 7.3), processed and embedded in araldite Cy 212. Semi-thin sections were stained with toluidine blue and examined by light microscopy (LM).

Renal tissues were dissected, fixed in 10 % formalin solution for 14–18 hours, processed in a series of graded ethanol and embedded in paraffin. Paraffin sections of 5- μ m thickness were obtained and stained with hematoxylin and eosin for light microscopic examination. The sections were examined and photographed with an Olympus light microscope (Olympus BX51, Olympus Optical Co., Japan) with an attached photograph machine (Olympus C-5050).

Statistical analysis

All results were expressed as mean \pm SD. Comparison between groups was performed using ANOVA followed by a *post hoc* test and paired Student's *t*-test.

RESULTS AND DISCUSSION

Biochemical analysis results are shown in Table I. The mean glucose and creatinine serum levels, activity of catalase, glutathione peroxidase and glutathione reductase in healthy control rats (groups 1 and 2) are displayed in Table I. Induction of diabetes for three months in group 3 rats produced a noticeable deterioration regarding these parameters: the glucose level was increased by 240 %, catalase and glutathione reductase level were decreased by 44 %, glutathione peroxidase was increased by 250 %, while creatinine was increased by 130 % *vs.* control group 1.

Treatment of diabetic model rats with aminoguanidine (group 4) markedly inhibited the above mentioned deterioration in catalase, glutathione peroxidase, and glutathione reductase reaching values that were not significant by different compared to both

Table I. Levels of glucose, catalase, glutathione peroxidase, glutathione reductase and creatinine in blood

Group	Glucose (mg per 100 mL)	Catalase (units g ⁻¹ Hb)	Glutathione peroxidase (units g ⁻¹ Hb)	Glutathione reductase (units g ⁻¹ Hb)	Creatinine (mg per 100 mL)
1	79.75 \pm 6.71 ^a	91.30 \pm 15.00	57.10 \pm 10.91	4.19 \pm 0.70	0.66 \pm 0.01 ^d
2	87.23 \pm 14.99 ^a	96.90 \pm 11.86	55.70 \pm 9.81	3.70 \pm 0.73	0.60 \pm 0.02 ^b
3	193.65 \pm 13.80 ^a	51.40 \pm 13.43 ^c	145.50 \pm 44.56 ^c	2.33 \pm 0.62 ^c	0.85 \pm 0.01 ^c
4	141.41 \pm 24.54 ^a	90.30 \pm 12.17 ^c	67.90 \pm 8.77 ^c	3.65 \pm 0.69 ^c	0.68 \pm 0.02 ^{b,c,d}

Data are expressed as mean \pm SD, *n* = 10.

Significant difference: ^{a-c} group 4 *vs.* groups 1, 2 and 3, resp. (*p* < 0.001), ^d group 4 *vs.* group 1 (*p* < 0.02).

control groups (1 and 2). These parameters were significantly improved compared to the untreated diabetic model values (group 3) ($p < 0.001$).

It was observed that the serum glucose and creatinine also improved to 177 and 103 % *vs.* the control group 1 values, respectively. However, they were still significantly higher than control groups 1 and 2 ($p < 0.001$, $p = 0.02$), but were also significantly lower compared to the diabetic model rats (group 3) ($p < 0.001$).

Histopathological examination of the retinas of control groups 1 and 2 showed normal pigment epithelium, outer and inner segments of the photoreceptors with normal finger shaped rods and dark triangle shaped cones. The outer nuclear layer showed normal nuclei and cytoplasm. The inner nuclear layer, outer and inner plexiform layers were normal with no vascularization. The ganglion cell layer appeared normal with occasional blood vessels (normal in rat retina) (Fig. 1a). The diabetic model (group 3) retinas showed the stages of diabetic retinopathy with vacuolation of the pigment epithelium, disruption and fragmentation of the photoreceptors (outer and inner segments); new blood vessels were noticed in the inner nuclear layer of the retinas (Fig. 1b). Aminoguanidine treated diabetic model (group 4) retinas showed marked improvement with minimal or no vacuolation of the pigment epithelium, slightly affected photoreceptors, especially their inner segments and neovessels were not detected (Fig. 1c).

Current histological results showed a marked improvement in the retinal tissues of the aminoguanidine treated model group (group 4). The pathological effects of AGEs in diabetic retinopathy are a consequences of AGE-induced alteration in the expression of a family of genes called the CCN family. These genes are responsible for retinal inflammation and angiogenesis, which are the basis of ischemic and proliferative diabetic retinopathy (3). These facts support and explain the beneficial effect of aminoguanidine as an AGEs breaker that preserved the integrity of these genes and abrogated the induction of retinopathy. The current results agree with those of Zheng *et al.* (13), who proved that aminoguanidine inhibited degeneration of the neuronal and vascular cells of the retina.

Renal specimens in the control groups showed normal glomeruli with the tuft of capillaries surrounded by Bowman's capsule and normal space separating the visceral

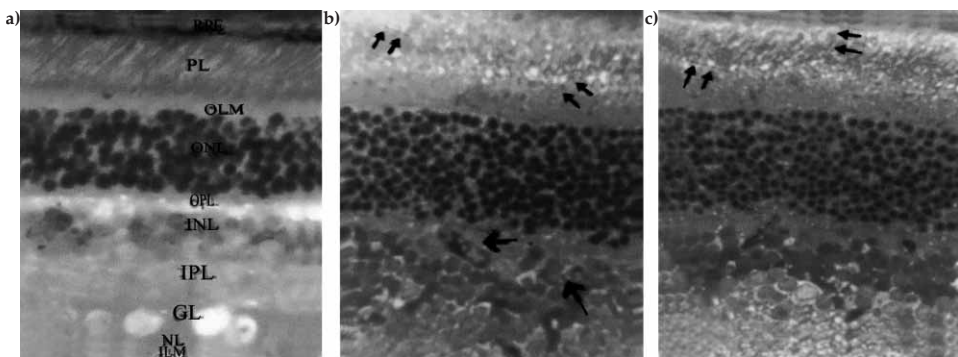


Fig. 1. Light micrograph (toluidine blue): a) normal rat retina, b) distortion and fragmentation of photoreceptors (small arrows) and newly formed blood vessels (big arrows), c) less vacuolation of pigment epithelium (arrows) (magnification 500x).

and parietal layers. Renal tubules were lined with acidophilic cuboidal epithelium and their lumens were patent (Fig. 2a). Diabetic model kidneys showed diabetic nephropathy with loss of renal architecture, thick and fused capillary walls of the renal corpuscles. Bowman's spaces were completely lost in some areas with thickening and adhesion between visceral and parietal layers. Epithelial linings of the tubules were swollen and vacuoles were noticed in their cytoplasm, with loss of the characteristic acidophilic stain. The lumens were totally obliterated (Fig. 2b). Renal tissues in group 4 (the treated model) showed capillary corpuscles swelling with reduced and maintained Bowman's spaces. Tubular epithelia swelled with the narrowing of their lumens (Fig. 2c).

In the present work, a significant impairment of the serum antioxidant enzymes was observed in the diabetic model rats (group 3). Glycation by AGEs and oxidation by stimulated nitric oxide and peroxynitrites production (induced by chronic hyperglycemia) may be responsible for the partial inactivation of these enzymes (9, 10). On treating the diabetic model rats with oral aminoguanidine (group 4), such impairment was abrogated markedly. This beneficial effect may be attributed to its powerful ability to break AGEs attached to the enzymes and to selective inhibition of the inducible nitric oxide synthase enzyme (stimulated by hyperglycemia) (8). Improvement in the serum antioxidant enzymes was previously confirmed by many authors (10, 12).

A significant increase in the serum creatinine level in diabetic model animals (group 3) was observed. It coincided with the observed disturbed renal histological picture. To explain the pathogenesis of diabetic nephropathy, evidence has been accumulated implicating the formation of AGEs as a major factor in its pathogenesis (11). The intracellular

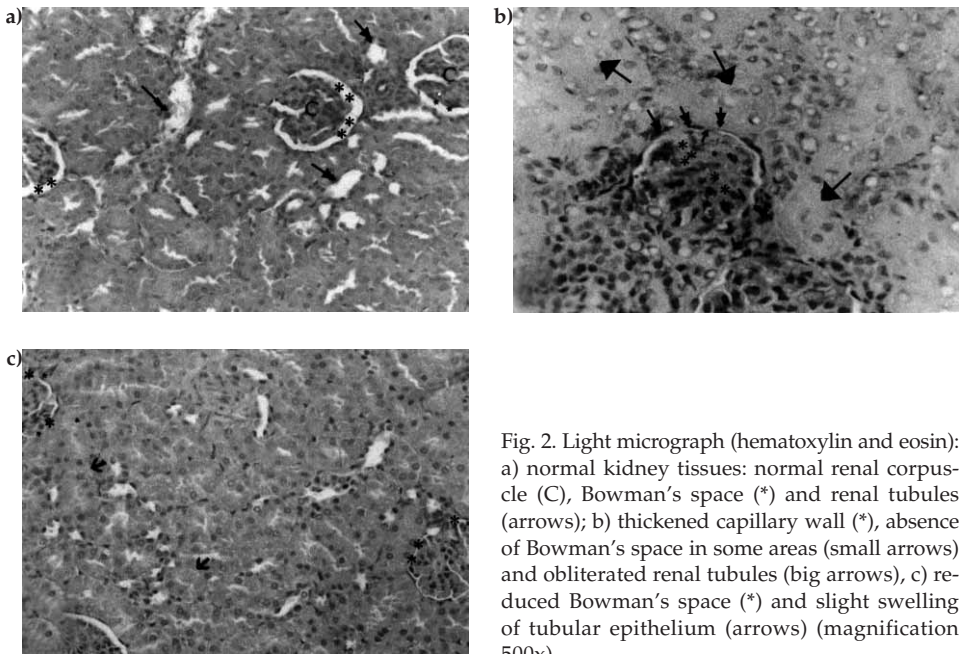


Fig. 2. Light micrograph (hematoxylin and eosin): a) normal kidney tissues: normal renal corpuscle (C), Bowman's space (*) and renal tubules (arrows); b) thickened capillary wall (*), absence of Bowman's space in some areas (small arrows) and obliterated renal tubules (big arrows), c) reduced Bowman's space (*) and slight swelling of tubular epithelium (arrows) (magnification 500x).

basic fibroblast growth factor produced by the renal endothelial cells was subjected to AGE modification following chronic hyperglycemia. Thereby a change of growth factor properties and reduction of the mitogenic cellular activities was observed (7). In addition, the high concentrations of nitric oxide (induced by hyperglycemia) act as a positive modulator of the proinflammatory and profibrotic pathways in the progression of renal disease (6). In the current study, aminoguanidine administration (group 4) was found to suppress markedly the renal histological changes in spite of chronic hyperglycemia. The kidney function was improved, as indicated by the improved creatinine level. This is explained by the aminoguanidine ability to ameliorate the overexpression of profibrotic cytokines. Also, it attenuated the type IV collagen deposition induced by AGEs contributing to the tubulointerstitial and glomerular lesions in diabetic mice (14–16). Moreover it ameliorated the renal morpho-functional changes caused by the overproduction of NO due to its ability to inhibit the inducible nitric oxide synthase enzyme (6).

CONCLUSIONS

Aminoguanidine, a glycated end product breaker and a selective inhibitor of inducible nitric oxide synthetase enzyme, was found to play a significant role in ameliorating retinal and renal pathologic changes induced by elevated blood glucose levels in diabetic rats. The alteration in catalase, glutathione reductase and peroxidase enzymes induced by the high glucose level was prevented by oral aminoguanidine, indicating its significant antioxidant effect. Further studies are recommended to elucidate its role in *diabetes mellitus* and to investigate its interactions with antidiabetic drugs.

REFERENCES

1. A. W. Stitt, Advanced glycation: an important pathological event in diabetic and age related ocular disease, *Br. J. Ophthalmol.* **25** (2001) 746–753; DOI: 10.1136/bjo.85.6.746.
2. A. W. Stitt, T. Bahduri, C. B. McMullen, T. A. Gardinger and D. B. Archer, Advanced glycation end products induce blood-retinal barrier dysfunction in normoglycemic rats, *Mol. Cell. Biol. Res. Commun.* **3** (2000) 380–88; DOI: 10.1006/mcbr.2000.0243.
3. J. M. Hughes, E. G. Kuiper, I. Klaassen, P. Canning, A. W. Stitt and J. Vanbezo, Advanced glycation end products cause increased CCN family and extracellular matrix gene expression in the diabetic rodent retina, *Diabetologia* **50** (2007) 1089–1098; DOI: 10.1007/s00125-007-0621-4.
4. H. Noh, K. H. Choi, D. S. Han and H. Y. Lee, High glucose increases inducible NO production in cultured rat mesangial cells. Possible role in fibronectin production, *Nephron*. **90** (2002) 78–85.
5. S. S. Ahanchi, V. N. Varu, N. D. Tsihlis, J. Martinez, C. G. Pearce, M. R. Kapadia, Q. Jiang, J. E. Saavedra, L. K. Keefer, J. A. Hrabie and M. R. Kibbe, Heightened efficacy of nitric oxide-based therapies in type II diabetes mellitus and metabolic syndrome, *Am. J. Physiol. Heart. Circ. Physiol.* **295** (2008) 2388–2398.
6. G. P. Bautista, L. G. Sanchez, C. U. Cristobal, E. Tapia, V. Soto and C. M. Avila, Chronic inhibition of NOS-2 ameliorates renal injury, as well as COX-2 and TGF-beta 1 over expression in 5/6 nephrectomized rats, *Nephrol. Diab. Transpl.* **21** (2006) 3074–3081.
7. H. J. Han, J. L. Lee, S. H. Park, J. H. Lee and M. Taub, High glucose induced oxidative stress inhibits Na/glucose transporter activity in renal proximal tubule cells, *Am. J. Physiol. Renal Physiol.* **288** (2004) F988–F998; DOI: 10.1152/ajprenal.00327.2004.

8. M. C. Thomas, H. U. Forbes and M. E. Cooper, Advanced glycation end products and diabetic nephropathy, *Am. J. Ther.* **12** (2005) S62–S72; DOI: 10.1097/01.mjt.0000178769.52610.69.
9. S. Varsan, P. Foiles and H. Founds, Therapeutic potential of breakers of advanced glycation end product–protein cross links, *Arch. Biochem. Biophys.* **419** (2003) 89–96.
10. V. Brodiak and N. O. Sybirua, Effect of aminoguanidine on oxidative modification of proteins in experimental diabetes mellitus in rats, *Ukr. Biochim. Zh.* **78** (2006) 114–119.
11. O. Azal, A. Yohem, B. Cakir, A. Baydar, A. Corakei and M. Kutli, Effects of aminoguanidine and tolrestat on the development of ocular and renal structural changes in experimental diabetic rats, *Diabetes Obes. Metab.* **4** (2002) 75–79; DOI: 10.1046/j.1463-1326.2002.00182.x.
12. G. R. Stoppa, M. Cesquini, E. A. Roma, S. H. Ogo and M. A. Torsoni, Aminoguanidine prevented impairment of blood antioxidant system in insulin dependent diabetic rats, *Life Sci.* **78** (2006) 1352–1361; DOI: 10.1016 /j.lfs. 2005.07.031.
13. L. Zheng, B. Gong, D. A. Hatala and T. S. Kern, Retinal ischemia and reperfusion causes capillary degeneration: similarities to diabetes, *Invest. Ophthalm. Vis. Sci.* **48** (2007) 361–367; DOI: 10.1167/ iovs.06-0510.
14. D. J. Kelly, R. E. Gilbert, A. J. Cox, T. Soulis, G. Jerums and M. E. Cooper, Aminoguanidine ameliorates overexpression of prosclerotic growth factors and collagen deposition in experimental diabetic nephropathy, *J. Am. Soc. Nephrol.* **12** (2001) 2098–2107.
15. H. Sugimoto, G. Grahovac, M. Zeisberg and R. Kalluri, Renal fibrosis and glomerulosclerosis in a new mouse model of diabetic nephropathy and its regression by bone morphogenic protein-7 and advanced glycation end product inhibitors, *Diabetes* **56** (2007) 1825–1833.
16. O. Adbelzaher, M. M. Adbelrahman, M. M. Hafez and F. M. Omran, Role of nitric oxide and reduced glutathione in the protective effects of aminoguanidine, gadolinium chloride and oleanolic acid against acetaminophen-induced hepatic and renal damage, *Toxicology* **234** (2007) 124–134.

S A Ž E T A K

Potencijalna profilaktička uloga aminogvanidina u dijabetičkoj retinopatiji i nefropatiji u eksperimentalnih životinja

AMANY HASSAN M. EL SHAZLY, ATEF MOHAMED MAHMOUD i NEVINE SALAH DARWISH

U ovom radu ispitivano je potencijalno profilaktičko i antioksidativno djelovanje aminogvanidina u eksperimentalno induciranom dijabetesu. Ispitivanja su provedena na četiri skupine od 10 štakora. Dvije skupine bile su kontrolne skupine, u trećoj skupini dijabetes je inducirano jednokratnom intraperitonealnom injekcijom streptozotocina 65 mg kg⁻¹, a u četvrtoj dijabetes je inducirano i tretirano aminogvanidinom 100 mg kg⁻¹ dnevno, peroralno, tijekom 3 mjeseca. Devedesetog dana eksperimenta analizirane su koncentracije glukoze, glutatona peroksidaze, glutatona reduktaze i eritrocitne katalaze u serumu. Životinje su žrtvovane, a uzorci retine i bubrega ispitivani su histopatološki. Uočeno je značajan antioksidativni učinak aminogvanidina i njegova profilaktička uloga u dijabetičkoj retinopatiji i nefropatiji.

Ključne riječi: aminogvanidin, dijabetička retinopatija, nefropatija, dušikov oksid, glikozilirani krajnji produkt, antioksidansi

Department of Pharmacology, Biochemistry and Histology, Research Institute of Ophthalmology, Giza, Egypt