

# A Study of Human Osseal Remains from Archaeological Excavations in Saint-Assumption Trinity Monastery (Staritsa, Tver District, Russia)

• Andrei V. Zinoviev •

Tver State University, Zoology Division

## Address for correspondence:

Tver State University

Zoology Division

Chaikovskogo pr. 70a

Tver 170002, Russia

E-mail: [m000258@tversu.ru](mailto:m000258@tversu.ru)

**Bull Int Assoc Paleodont. 2008;2(1):4-18.**

---

## Abstract

A number of human graves have been uncovered on the course of restoration activities in Saint-Assumption Trinity Monastery in Staritsa (Tver District, Russia) in 2005-2006. Dated from the middle of XV till the middle of XX centuries, they provide the first anthropological series ever studied for the city of Staritsa and form a part of extensive studies of medieval and post-medieval population of Tver region. Osteological materials from Saint-Assumption Trinity Monastery are of particular interest because they reflect peculiarities of anthropology and demography of churchmen over the period of several centuries. We have studied 163 skeletons in satisfactory and bad state of preservation.

**Keywords:** Russia; Bioarchaeology; Paleodontology

---

## Introduction

A number of human graves have been uncovered on the course of restoration activities in Saint-Assumption Trinity Monastery in Staritsa (Tver District, Russia) in 2005-2006. Dated from the middle of XV till the middle of XX centuries, they provide the first anthropological series ever studied for the city of Staritsa and form a part of extensive studies of medieval and post-medieval population of Tver region (1-4). Osteological materials from Saint-Assumption Trinity Monastery are also of particular interest because they reflect peculiarities of anthropology and demography of churchmen over the period of several centuries.

## Materials and methods

We have studied 163 skeletons in satisfactory and bad state of preservation (table with de-tailed date is too voluminous to insert in the article and can be sent separately upon the request). Due to the restrictions by construction pit's borders, not all the skeletons have been dug out in their entirety. However, this did not significantly influence the precision of sex or age determination. Age ranges for scattered bones have been set wider, but did not generally exceed 10 years. Besides determining age by traditional methods (5), we have utilized some additional ones (6-17). Preserved skulls brought the most accurate results in age determination (18-24), especially for kids, where the tooth eruption timing is a good indication of the age (25-27).

To calculate the height of the buried (in case of preservation of long bones) we applied a number of methods, utilizing the length of the so-called long tubular bones (5). Equations have been selected for specific proportions' types, determined by intermembral and tibiofemoral indices. The most universal equation turned out to be that of Debets (28). Some recent methods have also been used to make the height determination more accurate (29-38).

All the calculations and diagrams have been processed in Statistica 6.0.

## Results and Discussion

Total number of studied individuals reached 163. 68 skeletons out of this number were in relatively good condition, while others had been disturbed by a variety of causes, being represented by scattered bones.

Figure 1 shows two peaks of mortality – between 30 and 40 years and 50 and 60. This is not surprising and reflects usual situation for XV-XVIII century's cemeteries of Tver region (1,2). However, age-sex distribution of mortality, shown on Figure 2, different from that of contemporaneous cemeteries outside of monastery borders. Here, burials of generally older men outnumber those of women. And if the larger number of men's burials can be explained by the presence of monastery (not convent), generally young age of buried women poses a question.

Figure 3 with age-sex distribution of buried by centuries does not solve this question. It shows that the number of burials of women and younger individuals has been always proportional to that of men. XVI century is an exception. We did not find any women burials originating from this period. This is probably connected to the history of the monastery. Prior to the erection of the monastery in XVI century there was a wooden church with churchyard on this place. Buried there before XVI century match in sex-age distribution those from contemporaneous cemeteries of Tver (1,2). After the building of Saint-Assumption Trinity Monastery (it was moved here from the other place), there have been initially only churchmen buried on its territory. Then, a small number women (Figure 4) and younger individuals were allowed to be buried.

Distribution of men by age and centuries is quite informative (Figure 5) due to large sample size and the peculiarity of the institution most of them have served in. As has been noted above, the majority of men's burials belong to senior individuals. An average age of buried was 55-60 years, which is higher than corresponding age for contemporaneous cemeteries (40-50 years) of Tver (1-3). This indicates, that majority of burials might have belonged to churchmen, whose age had generally exceeded that of the rest of men.

Average men's height was  $168 \pm 2$  cm., that of women –  $156 \pm 3$  cm (Figure 6). Figure 7 shows two peaks in average men's height for XV and XVIII centuries. Both peaks significantly exceed (by 7-9 cm) the average date for the contemporaneous cemeteries of Tver (3). Further studies should be done to explain this fact.

The frequency of caries by individual teeth (Figure 8) almost matches that from the contemporaneous cemeteries of Tver (1,3) and corresponds to general scheme of predisposition of human teeth to caries (39).

Various degrees of deterioration of alveolar bone, from manifestation of mild gingivitis to serious degrees of periodontitis, were common among individuals older than 30-35 years (Figure 9, Figure 10). Periodontitis in Second World War Soviet soldier (determined by characteristic warfare artifacts) led to partial exposure of roots of M1 (Figure 9). This soldier had also an interesting anomaly in dental system. Figure 11 shows that lingual roots of both his maxillary first molars were not imbedded in alveolar sockets, residing during the life of the individual in tissues of soft palate.

Age of the complete teeth loss by buried in monastery can be determined in 60-70 years. This generally corresponds to data for modern inhabitants of studied and adjacent regions (40). In some cases this loss have happened earlier (Figure 12).

The level of dental hygiene is adequately represented by the development of tartar. Being best developed on lingual surfaces of incisors, it shows peak of accumulation by the age of 50-60 (4). High degree of tartar development in relatively young Soviet soldiers of Second World War points on relatively bad dental hygiene during warfare. Absence of third molars is not a rare case in human population (41,42). In our earlier works (1,2,4) we pointed out, that this state appears more frequently in women due to the relative short-ness of their facial skeleton. It is noteworthy, that even in present scarce material for women we met one case of partial adentia. This is not the case for men. In quite rich material, only two Soviet soldiers of Second World War showed a partial adentia.

One case of hyperdontia is recorded. Man of 28-32 years old had an additional tooth just behind the broken I1 (Figure 13). It resembled a canine and participated in occlusion.

So-called accessory or Inca bones have been recorded in sut. lambdoidea. Out of three configurations, one has not been previously recorded in our studies (1-4) (Figure 14).

Osteochondrotic changes in vertebral column are the most wide-spread problems among buried in the monastery. These changes have become especially pronounced by the age 60, some-times leading to ankylosis (Figure 15). Enduring longitudinal loading on vertebrate column due to the hard physical work caused a compression of

vertebral body of 50-55 years old man (Figure 16). This individual has been already mentioned as having early loss of all the teeth (Figure 12). His massive with well pronounced ridges for muscles' insertions skeleton indicates high enduring physical stresses, which underwent this man on the course of his professional activities.

Traces of terminal stage of syphilis have been found on the skull and some postcranial bones of man 50-55 years old (Figure 17). Unfortunately, his skeleton has been partially destroyed during construction works about a century ago, so it was not possible to determine precise age of burial.

Healed broken bones have discovered only in three cases. All of them relate to ulna: right ulna has been broken and healed in woman of 40-45 years old (Figure 18); two other bones – left ulnae – belong to senior men of 65-70 and 80+ years old. Trauma of this bone is among the most common, since ulna stays first on the way of strike when someone wants to protect itself with the hand.

Marks on bones from possible fatal wounds are rare. The right scapula of Second World War soldier has several holes of different size, which could point out missile wounds (Figure 19). Right parietal bone of senior men, buried before 1849, was perforated by two holes. Configuration and position of the holes point at some kind of cold steel weapon with two spikes, such as tooth (Figure 20).

### **On the organization of an ossuary**

Practice of organizing ossuaries is quite common in some parts of the world (11). This is not the case for European Russia. Thus, an ossuary from the studied bones, which we erected in the vault of Assumption Cathedral of Saint-Assumption Trinity monastery of Staritsa, is one of a few for the mentioned region. Bones has been sorted by kinds and stored in good-ventilated dry boxes, accessible for further research (Figure 21).

### **Acknowledgements**

I am very grateful to A.N Khokhlov (Tver Research and Restoration Archaeological Center, Tver, Russia) for the access to the collection. I also would like to thank T.M. Sivolapova (Tver Research and Restoration Archaeological Center, Tver, Russia), who provided accessory data and maximum of comfort on the course of the research.

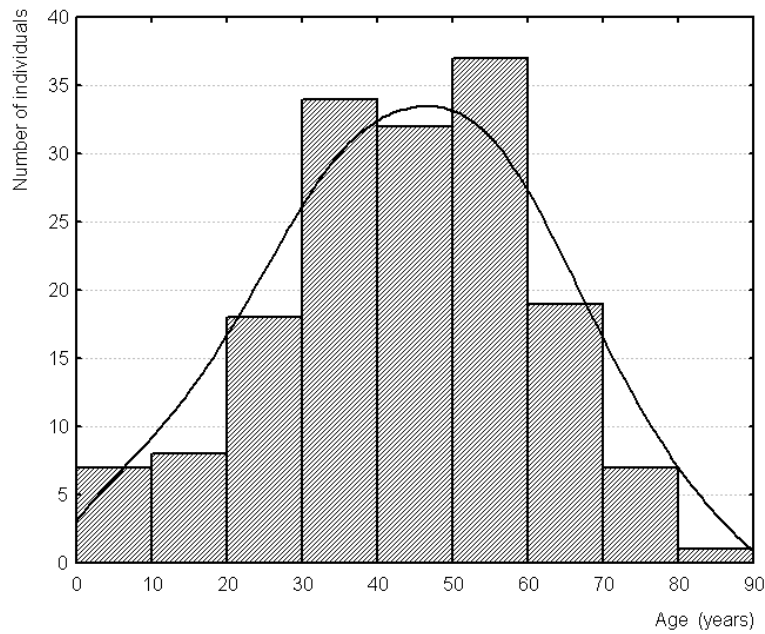


Figure 1 Age distribution of buried in Saint-Assumption Trinity Monastery of Staritsa

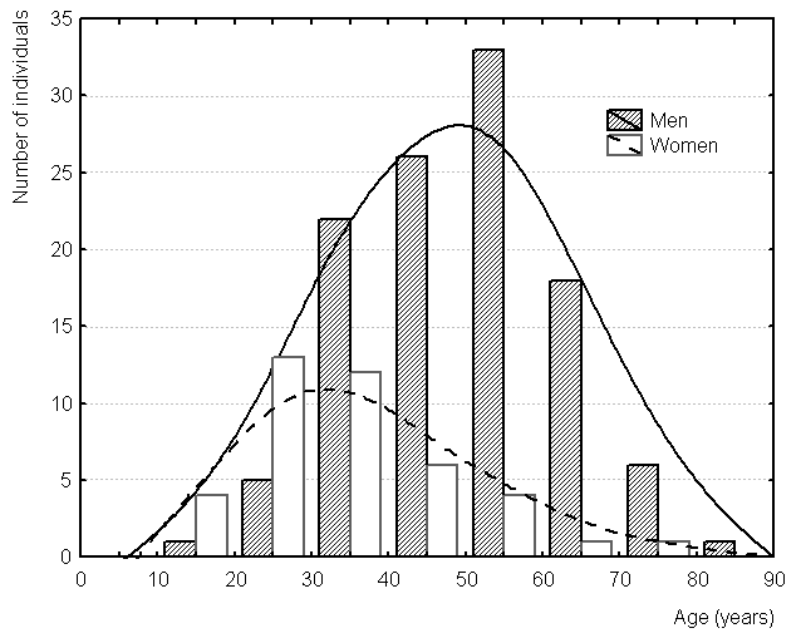


Figure 2 Age-sex distribution of buried in Saint-Assumption Trinity Monastery of Staritsa

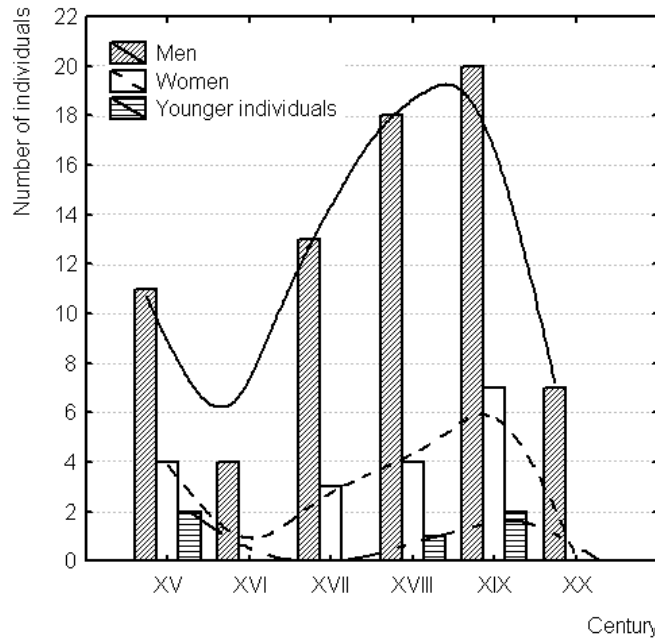


Figure 3 Age-sex distribution by centuries of buried in Saint-Assumption Trinity Monastery of Staritsa

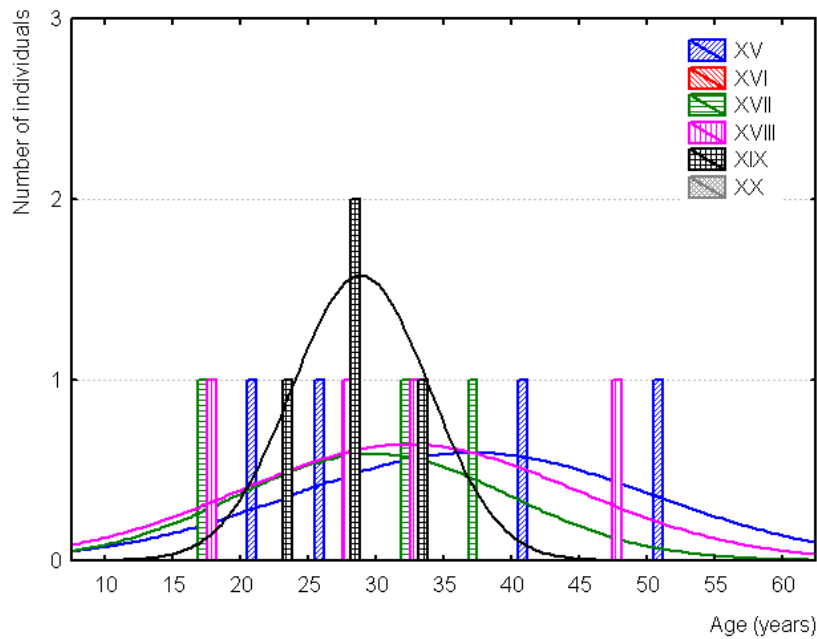


Figure 4 Age-century distribution of womens burials in Saint-Assumption Trinity Monastery of Staritsa

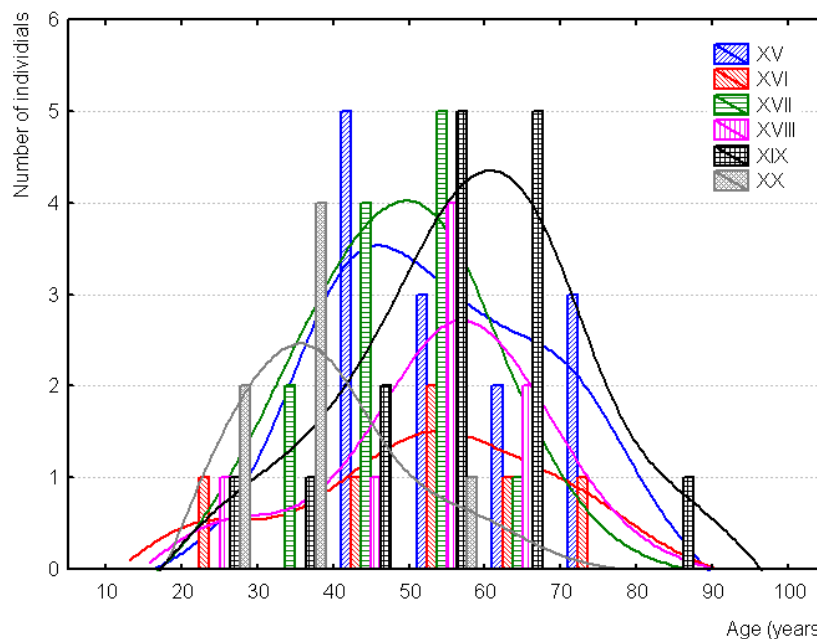


Figure 5 Age-century distribution of buried men in Saint-Assumption Trinity Monastery of Staritsa

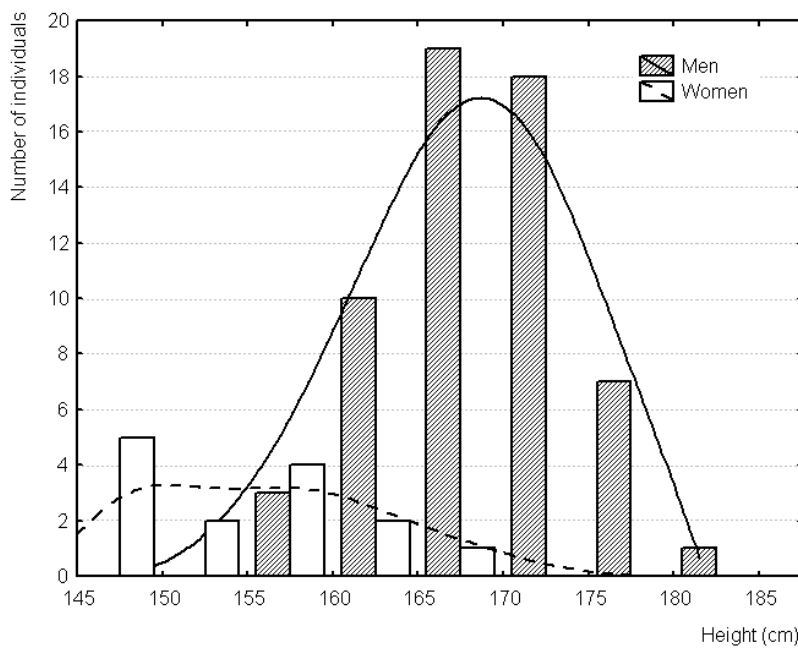


Figure 6 Age-height distribution of men and women, buried in Saint-Assumption Trinity Monastery of Staritsa



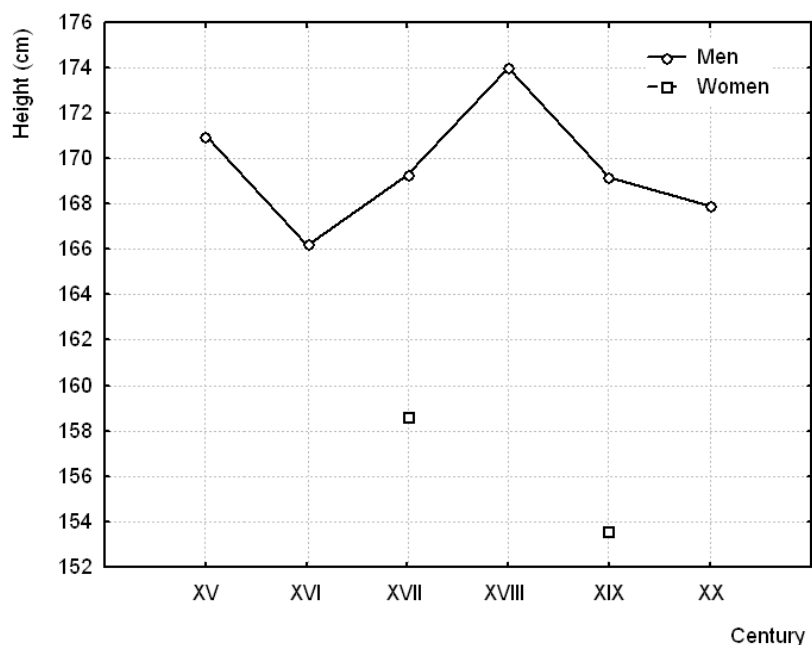


Figure 7 Oscillation of average height by centuries of men and women buried in Saint-Assumption Trinity Monastery of Staritsa

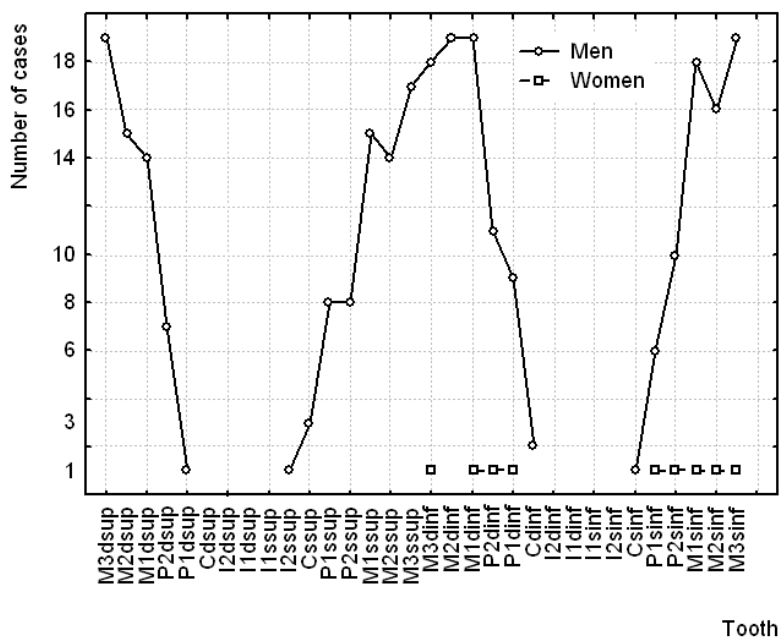


Figure 8 Cases of caries by individual teeth in men and women, buried in Saint-Assumption Trinity Monastery of Staritsa

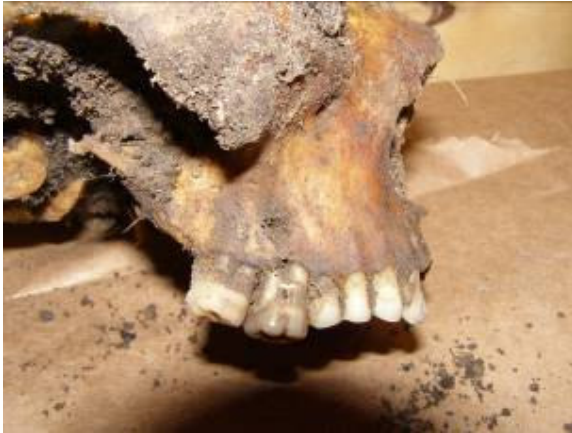

Figure 9 Parodontosis in 33-35 years old Second World War Soviet soldier (XX)

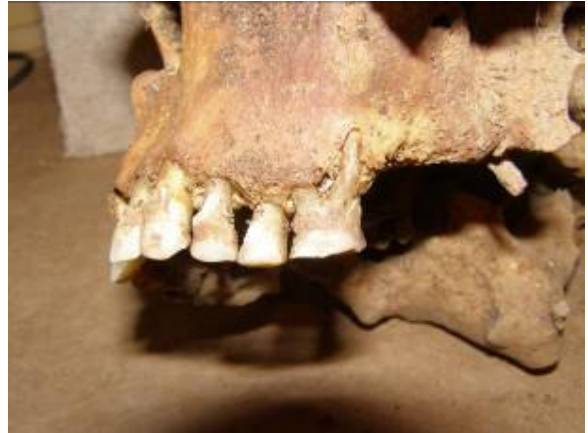

Figure 10 Parodontosis in 52-58 years old man (XVII-XVIII)

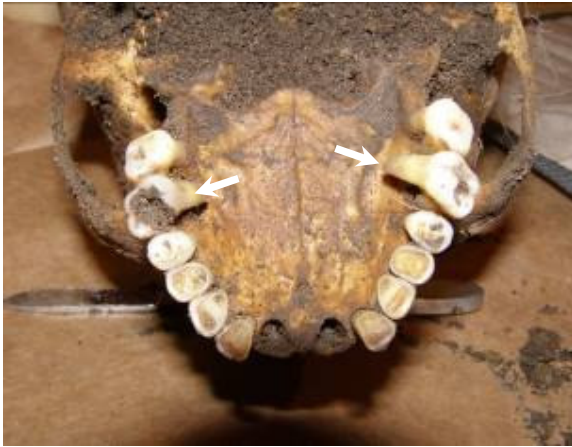

Figure 11 Anomalous exposure of M1 roots (white arrows) in 33-35 years old Second World War Soviet soldier (XX)

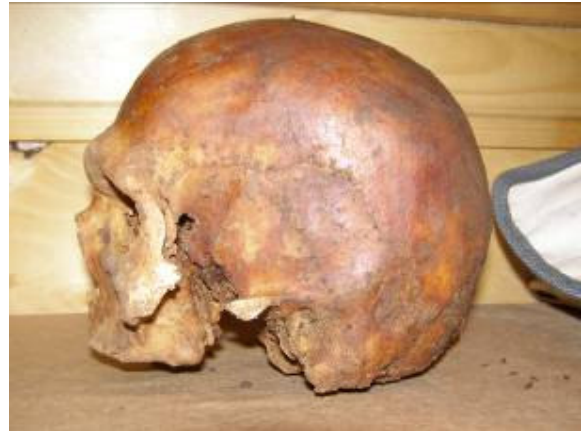

Figure 12 Skull of 50-55 years old man, who has lost to this age all the teeth (XV-XVI)

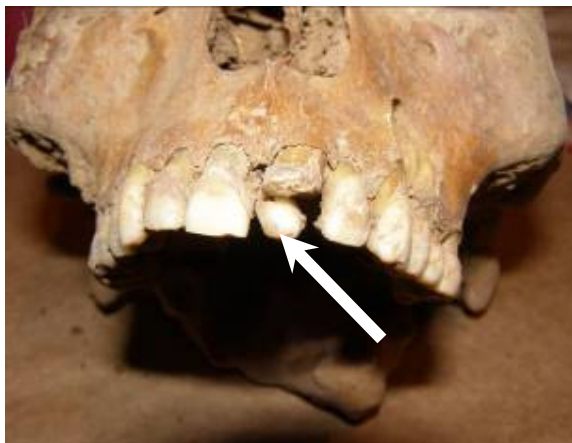

Figure 13 The case of hyperdentia in 28-32 years old man (arrow points an additional tooth)(XVII-XVIII)



Figure 14 Accessory bones in *sut. lambdaidea* of Second World War soldier (XX)



Figure 15 Ankylosis of two vertebrae in 60-70 years old man (earlier than XX)



Figure 16 Compression of vertebral body in 50-55 years old man (XV-XVI)

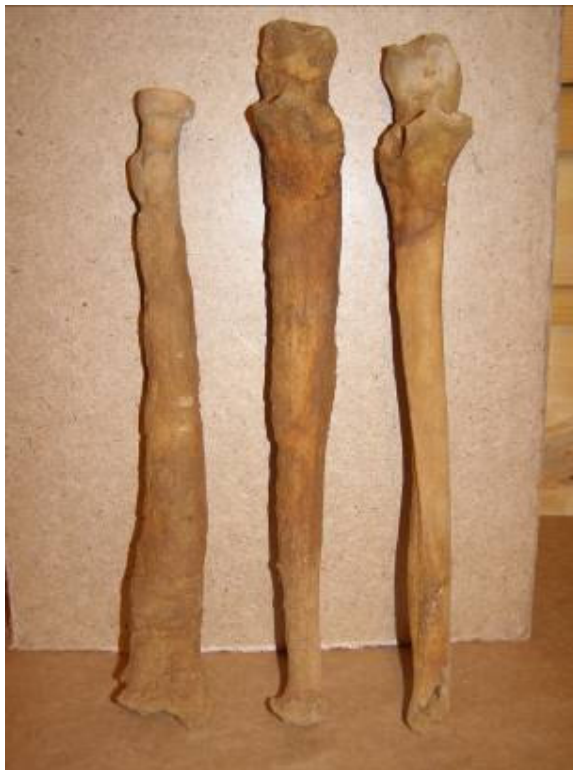

Figure 17 Ulnae and left radius of 50-55 years old man with syphilitic changes (century undetermined)



Figure 18 Broken and healed right ulna of 40-45 years old woman (century undetermined)



Figure 19 Right scapula of Second World War Soviet soldier with missile wounds (arrows)(XX)



Figure 20 Unhealed holes in right parietal bone of 70-75 years old man, probably made by spikes cold steel weapon, such as tooth (earlier 1842)



Figure 21 One of the two boxes of an ossuary, erected by the author in the vault of Saint-Assumption Trinity Monastery of Staritsa

## References

1. Zinoviev AV. [Some results of studying of anthropological material from late medieval ne-cropoles of Tver]. In: Zinoviev AV. Tver, Tver region and adjacent territories during Middle Ages Vol. 3. Tver: TRRC; 1999. p. 245-8.
2. Zinoviev AV. [To the characteristics of the anthropological collection from an excavation of Spas-Vysoky Monastery from middle suburban settlement of the city of Tver]. In: Zinoviev AV. City of Tver, Tver region and adjacent territories during Middle Ages. Vol. 5. Tver: TRRC; 2003. p. 106-8.
3. Zinoviev AV. [Some results of study of human and animal skeletal remains from

- excavations in Uchitel'skaya street area of the city of Tver]. Tver: TRRC; 2005.
4. Zinoviev AV. A study of human osseal remains from the "Cholera Cemetery" archaeological site (Tver, Russia). *Bull Int Assoc Paleodont.* 2007;1(2):12-7.
  5. Alexeev VP. [Osteometry]. Moscow: 1966.
  6. Todd T. Age changes in the pubic bones - the white male pubis. *Am J Phys Anthropol.* 1920;3:285-334.
  7. Brooks ST. Skeletal age at death: the reliability of cranial and pubic age indicators. *Am J Phys Anthropol.* 1955;13(4):567-97.
  8. Bass WM. *Human osteology: A laboratory and field manual.* Columbia: Missouri Archaeological Society; 1987.
  9. Brooks S, Suchey J. Skeletal age determination based on the os pubis: a comparison of the Acsadi-Nemesken and Suchey-Brooks methods. *Human Evol.* 1990;5:227-38.
  10. Buikstra J, Ubelaker DH. Standards for data collection from human skeletal remains. *Standards for Data Collection from Human Skeletal Remains: Proceedings of a Seminar at the Field Museum of Natural History organized by Jonathan Haas.* 1994.
  11. Ubelaker DH, Ripley CE. *The Ossuary of San Francisco Church, Quito, Ecuador: Human Skeletal Biology.* Washington: Smithsonian Institution Press; 1999.
  12. Mays S. *The archaeology of human bones.* London: Routledge; 1998.
  13. Haglund WD, Galloway A, Simmons T. *Practical forensic anthropology of human skeletal remains recovery analysis & resolution.* Crc Press. 2002.
  14. Schmitt A. Age-at-death assessment using the os pubis and the auricular surface of the ilium: a test on an identified Asian sample. *Int J Osteoarch.* 2004;14(1):1-6.
  15. Lovejoy CO, Meindl RS, Pryzbeck TR, Mensforth RP. Chronological metamorphosis of the auricular surface of the ilium: a new method for the determination of adult skeletal age at death. *Am J Phys Anthropol.* 1985;68(1):15-28.
  16. Kurki H. Use of the first rib for adult age estimation: a test of one method. *Int J Osteoarch.* 2005;15(5):342-50.
  17. Rissech C, Estabrook GF, Cunha E, Malgosa A. Using the acetabulum to estimate age at death of adult males. *J Forensic Sci.* 2006;51(2):213-29.
  18. Alexeev VP, Debets GF. [Cranio-metry. *Methods of Anthropological Research*].

Moscow: 1964.

19. Zvyagin VN. [Age morphology of human cranial sutures (to the methods of age determination in forensic medicine)]. Moscow: 1971.

20. Johanson G. Age determinations from human teeth. *Odont Revy* 1971;22 (Suppl.21): 1-126.

21. Chernyavskaya ZP. [Age determination by tooth abrasion in forensic medicine (dissertation)]. Leningrad: 1983.

22. Walker PL, Dean G, Shapiro P. Estimating age from tooth wear in archaeological populations - *Advances in Dental Anthropology*. New York: Alan R Liss P; 1991.

23. Solheim T. A new method for dental age estimation in adults. *Forensic Sci Int.* 1993;59(2):137-47.

24. Lampe H, Roetzscher K, Forensic odontology: age determination from adult human teeth. *Med and Law.* 1994;13:623-8.

25. Schour I, Massler M. *Development of the Human Dentition*. Chicago: American Dental Assoc; 1944.

26. Mamonova NN, Romanova GP, Kharitonov VM. [Preliminary treatment and determination of anthropological material in the field]. In: *Methods of Field Archaeological Studies*. Moscow: 1989.

27. De Vito C, Saunders SR. A discriminant function analysis of deciduous teeth to determine sex. *J Forensic Sci.* 1990;35(4):845-58.

28. Debets GF. [On the study of physical development of ancient people]. Moscow: 1963.

29. Lundy JK. The mathematical versus anatomical methods of stature estimate from long bones. *Am J Forensic Med Pathol.* 1985;6(1):73-6.

30. Rölsing FW. Körperhöhenrekonstruktion aus Skelettmaßen - Anthropologie: *Handbuch der Vergleichenden Biologie des Menschen*. Stuttgart: Gustav Fischer; 1988.

31. Sjøvold T. Estimation of stature from long bones utilizing the line of organic correlation. *Human Evol.* 1990;5(5):431-47.

32. Sjøvold T. Stature estimation from the skeleton. *Encyclopedia of Forensic Sciences*. London: Academic Press; 2000.

33. Jantz RL. Modification of the Trotter and Gleser female stature estimation

- formulae. *J Fo-rensic Sci.* 1992;37(5):1230-5.
34. De Mendonça MC. Estimation of height from the length of long bones in a Portuguese adult population. *Am J Phys Anthropol.* 2000;112(1):39-48.
35. Mall G, Hubig M, Büttner A, Kuznik J, Penning R, Graw M. Sex determination and estimation of stature from the long bones of the arm. *Forensic Sci Int.* 2001;117(1-2):23-30.
36. Duyar I, Pelin C. Body height estimation based on tibia length in different stature groups. *Am J Phys Anthropol.* 2003;122(1):23-7.
37. Formicola V. Stature reconstruction from long bones in ancient population samples: an approach to the problem of its reliability. *Am J Phys Anthropol.* 1993;90(3):351-8.
38. Duyar I, Pelin C, Zagyapan R. A new method of stature estimation for forensic anthropological application. *Anthrop Sci.* 2006;114(1):23-7.
39. Vodanović M, Brkić H, Slaus M, Demo Z. The frequency and distribution of caries in the mediaeval population of Bijelo Brdo in Croatia (10th-11th century). *Arch Oral Biol.* 2005;50(7):669-80.
40. Klychkov AV. [Effectiveness of adhesive materials in complete prosthesis (dissertation)]. Samara: SSMU; 2001.
41. Shinn DL. Congenitally missing third molars in a British population. *J Dent.* 1976;4(1):42-4.
42. Thompson GW, Popovich F, Anderson DL. Third molar agenesis in the Burlington Growth Centre in Toronto. *Community Dent Oral Epidemiol.* 1974;2(4):187-92.