

EPIZOOTIOLOGY OF GAME CERVID CYSTICERCOSIS

VALÉRIA LETKOVÁ, PETER LAZAR, JAROSLAV SOROKA,
MÁRIA GOLDOVÁ & JAN ČURLÍK

Department of Parasitology and Infectious Diseases, University of Veterinary
Medicine, Košice, Slovak Republic

Letková, V., Lazar, P., Soroka, J., Goldová, M. & Čurlík, J.: Epizootiology of game cervid cysticercosis. *Nat. Croat.*, Vol. 17, No. 4., 311–318, 2008, Zagreb.

The protection of game from diseases is important for several reasons. Mainly, this is concerned with the health of the animals themselves, which under the conditions obtaining in the Slovak Republic are at an increasing rate exposed to negative factors arising from the activities of man. Among other factors, exposure to diseases, including these caused by parasitic infections, is increasing. In order to assess the prevalence of *Taenia* species in wild carnivores, which is indicative of or related to infection in cervids, 323 animals were investigated. The taenias were represented by 7 species: *Taenia hydatigena* (Pallas, 1766), *Taenia krabbei* Moniez, 1879 (syn. *T. cervi* Christiansen, 1931), *Tetratirotaenia polyacantha* (Leucart, 1856), *Mesocestoides litteratus*, *M. lineatus* (Goeze, 1782), Ralliet, 1843 and *Echinococcus multilocularis*. The presence of *T. hydatigena* was established in 12 red foxes and two wolves and *T. krabbei* was found in one wolf and three foxes. The presence of cysticerci was investigated in 114 game ruminants *post-mortem* (32 red deer, 61 roe deer and 21 fallow deer). *Cysticercus tenuicollis* (*Taeniae hydatigena*) was found in 3 game species (red deer, roe deer, fallow deer) and cysticerci of *T. krabbei* in the myocard of red deer.

Key words: cysticercosis, red deer, roe deer, fallow deer

Letková, V., Lazar, P., Soroka, J., Goldová, M. & Čurlík, J.: Epizootologija cisticerkoze kod jelenske divljači. *Nat. Croat.*, Vol. 17, No. 4., 311–318, 2008, Zagreb.

Zaštita divljači od bolesti važna je zbog nekoliko razloga. Prvenstveno zbog zdravlja samih životinja, koje su u sadašnjim uvjetima u Slovačkoj pojačano izložene negativnim čimbenicima uzrokovanim ljudskom aktivnošću. Između ostalog, povećana je izloženost bolestima, uključujući one uzrokovane parazitima. Da bi se istražila učestalost *Taenia* vrsta kod divljih mesoždera, što je indikativno i za zaraženost cervida, pregledane su 323 životinje. Zastupljeno je 7 vrsta: *Taenia hydatigena* (Pallas, 1766), *Taenia krabbei* Moniez, 1879 (syn. *T. cervi* Christiansen, 1931), *Tetratirotaenia polyacantha* (Leucart, 1856), *Mesocestoides litteratus*, *M. lineatus* (Goeze, 1782), Ralliet, 1843 i *Echinococcus multilocularis*. Prisutnost *T. hydatigena* je utvrđena kod 12 lisica i dva vuka, a *T. krabbei* je nađena kod jednog vuka i tri lisice. Cisticerki su *post-mortem* istraženi kod 114 primjeraka divljih preživača (32 obična jelena, 61 srne i 21 jelena lopatara). *Cysticercus tenuicollis* (*Taeniae hydatigena*) je utvrđena kod tri vrste divljači (jelen obični, srna, jelen lopatar) a cisticerki *T. krabbei* u miokardu običnog jelena.

Ključne riječi: cisticerkoza, jelen obični, srna, jelen lopatar

Tab. 1. Spring stock and the harvest of game cervids in the Slovak Republic (hunting season 2006).

Game Species	Spring stock	Harvest
Red deer	39 738	12 771
Fallow deer	8 425	2 325
Roe deer	85 124	17 174

INTRODUCTION

Game ruminants are the most important part of game species in the Slovak Republic (Tab. 1).

During veterinary inspection of venison, larval stages of tapeworms were found (cysticerci of *T. hydatigena* and *T. krabbei*) in the abdominal cavity and striated muscles. The finding of *C. cervi* in roe deer is quite common as described by RUKAVINA *et al.* (1973) in the former Yugoslavia, KOLAŘ *et al.* (1978) in the Czech Republic, ROMANENKO (1988) in Russia and TROILO & KISZAK (1995) in Poland. Few data are available about the occurrence of *C. cervi* in red deer. GOLDOVÁ *et al.* (2004) describe the presence of *C. cervi* in the myocard of a two year old male red deer in Slovakia and presents its detailed morphology.

One important conclusion is that ruminant entrails should be disposed off properly and should not be fed to dogs or left for wild carnivores.

MATERIALS AND METHODS

- In order to assess cysticercosis in game ruminants, 114 animals of the following species were investigated during 2002 to 2007:

Cervus elaphus – European red deer – 32 animals

Capreolus capreolus – roe deer – 61 animals

Dama dama – fallow deer – 21 animals

- *Taenia hydatigena* and *Taenia cervi* were investigated in 302 red foxes (*Vulpes vulpes*), 6 wolves (*Canis lupus*), 3 wild cats (*Felis silvestris*), 7 badgers (*Meles meles*), 3 polecats (*Putorius putorius*), 1 raccoon dog (*Nyctereutes procyonides*), shot by hunters or killed by cars on the road (wild cats) in an area of East Slovakia.
- Prior to parasitological examination the red foxes were inspected for rabies at the State Veterinary and Food Institute.
- Helminthological autopsy, the digestive method, the intestinal scraping technique (IST, HOFER *et al.*, 2000) and sedimentation counting techniques (SCT, HOFER *et al.*, 2000) were used.
- Small intestines of carnivores were opened with gut scissors and were visually inspected for the presence of *E. multilocularis* and other cestodes. After removal of coarse intestinal contents, smear samples were taken from locations

at 10-cm intervals by scraping the mucosa with microscopic glass strips which were pressed on square polystyrene petri dishes (ECKERT *et al.*, 1991).

- Determination of tapeworms and cysticerci was performed according to the appropriate specification keys (KOZLOV, 1977; KHALIL & JONES, 1994).
- Cysticerci were obtained from the heart, and omentum, mesentery, liver, and lung.
- Tissue samples with cysticerci were fixed in 4 % neutral formaldehyde and subjected to routine paraffin processing. Histological sections (4–5 µm thick) were stained with haematoxylin–eosin (H–E).

RESULTS

A total of 322 wild carnivores, belonging to 6 species were investigated in order to establish the occurrence of *Taenia hydatigena* (Fig. 5) and *T. krabbei*. The taenias were represented by 8 species belonging to the Dipylidiidae, Mesocestoididae and Taeniidae families (Tab. 2).

Taenia hydatigena and *T. krabbei* were present only in two hosts, the red fox and wolf. Altogether 48 adult individuals of tapeworms were obtained from the small intestine.

- The presence of *Cysticercus tenuicollis* was found at various distribution rates in three species of game cervids. Numerous vesicles with transparent envelopes were macroscopically detected on the heart and lungs. Their localization was in the pericardium, under the epicardium of the heart and under the visceral pleura in the pulmonary parenchyma.

Tab. 2. Prevalence of cestodes species in wild carnivores

Host	<i>Vulpes vulpes</i>	<i>Canis lupus</i>	<i>Felis silvestris</i>	<i>Meles meles</i>	<i>Putorius putorius</i>	<i>Nyctereutes procyonides</i>
Number of animals / Prevalence%	302	6	3	7	3	1
Species						
<i>Dypilidium caninum</i>	2.31	33.3				+
<i>Mesocestoides</i> sp.	46.35	50.0		42.8		+
<i>Taenia crassiceps</i>	3.9	14.7				
<i>Taenia hydatigena</i>	7.94	33.3				
<i>Taenia ovis</i>	0.33					
<i>Taenia krabbei</i>	2.3	16.6				
<i>Tetratirotaenia polyacantha</i>	1.32					
<i>Echinococcus multilocularis</i>	6.95					

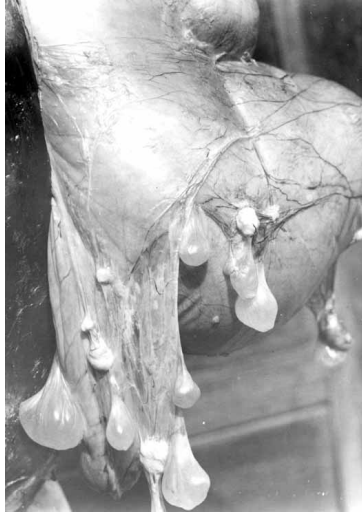

Fig. 1. *Cysticercus tenuicollis* in red deer (Photo orig. Ing. Mituch)

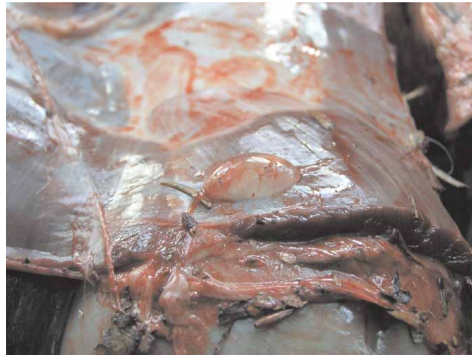

Fig. 2. *Cysticercus tenuicollis* in roe deer diaphragm (Photo orig. MVDr. P. Lazar)

From the given number of animals, fourteen were positive, with a total prevalence of 12.28 %. Among the individual hosts the highest invasion rate occurred in roe deer, followed by red deer and lastly fallow deer (Tab. 3). *C. tenuicollis* was found in one four year old host, localized on the mesentery, omentum, abdominal cavity (Figs. 1, 2, 3), lung (Fig. 4) and liver. *C. cervi* was found in the myocard of 2 red deer and 3 roe deer.

DISCUSSION

Taenia hydatigena is cosmopolitan in distribution and occurs in the small intestine of dogs, red foxes, wolves and other wild carnivores. The intermediate hosts are

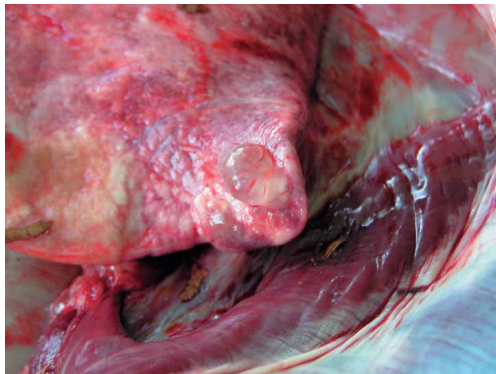


Fig. 3. *Cysticercus tenuicollis* in roe deer lung (Photo orig. MVDr. P.Lazar)

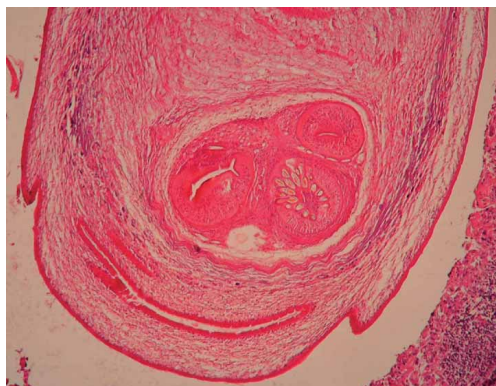

Fig. 4. Neck region of *Cysticercus cervi*: (H&E, heart, 20 x 10) (Photo orig. Prof. MVDr. M. Goldova, MVDr. Š. Tóth)

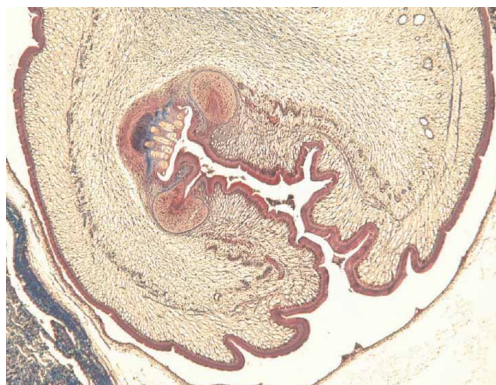


Fig. 5. Histological representation of invaginated scolex of *Cysticercus tenuicollis*: (Masson blue trichrome, lungs, 10 x 10) (Photo orig. Prof. MVDr. M. Goldova, MVDr. Š.Tóth)

Tab. 3. Prevalence of *Cysticercus tenuicollis* in game cervids.

Host	Number of animals	Positive animals	Prevalence %	Intensity	
				ø	Total
<i>Cervus elaphus</i>	32	3	8.4	5.6	17
<i>Capreolus capreolus</i>	61	9	14.75	2.88	26
<i>Dama dama</i>	21	2	9.5	3.0	6
Total	114	14	12.28	2.65	49

domestic and wild ruminants. Pigs and wild boars may be also infected (SOULSBY, 1982).

Mature cysticerci are up to 6 cm long and contain a single scolex invaginated into a long neck (Fig. 1).

Carnivores become infected by ingestion of the cysticercus. The prepatent period in the dog is 51 days, and the dogs may remain infected for one or more years.

There are few pathological changes that occur with *T. hydatigena* cysticerci infection, but severe infections can be hazardous to the animal's health. Cysts, varying in number from 1 to 75, can be present in the omentum and in the mesentery. In the case of extremely severe infection the viscera may become knotted together and organ function may be impaired. Degenerated cysts are replaced by caseous and calcareous debris and may damage tissue. Meandering streaks may be present in the liver due to larval parasite migration. If large numbers of larvae migrate through the liver parenchyma, tissue will be damaged and acute and fatal hepatitis may be the result. Infections of cloven-hoofed animals with cysticerci of *T. hydatigena* and *T. krabbei* are usually of little significance (MURAI & SUGAR, 1979). In the case of *T. krabbei*, infection may cause myositis or myocarditis because of the location of cysticerci in the myocard or striated muscles (TÓTH *et al.*, 2005) (Fig. 4). The cysticerci may influence the trophy quality of the males and also the venison quality. An unusual case, MCKENNA *et al.* (1980), however, records a young red deer calf which died with hepatitis cysticercosis. Prior to death, the calf was described as being moribund with subnormal temperature, cold extremities, pale mucous membranes, and severe abdominal pain.

T. krabbei is highly similar in all morphological criteria to *T. ovis* (PRIEMER *et al.*, 2002). According to FLUECK & JONES (2006) there is no possibility of differentiating between *T. o. ovis* and *T. o. krabbei* on morphological grounds with certainty, and several biological characteristics indicate the cysticercus may belong to *T. o. krabbei*. Red deer have been reported to be refractory to *T. o. ovis* infection whereas other potential intermediate hosts like cattle, goats, pigs and sheep have been shown to be refractory to *T. o. krabbei* (FLUECK & JONES, 2006).

The given results show that 12.3% of the three species of game cervids are infected by *Cysticercus tenuicollis*. Similar results have been reported from red deer in Belorussian Polesie (13%) (SHIMALOV & SHIMALOV, 2003), while in Hungary the corresponding figure is 19% (MURAI & SUGAR, 1979).

Game cysticercosis is a serious problem because helminthosis is involved, and this is often common for domestic as well as free living animals. This refers principally to domestic ruminants that share the grazing with game. Lambs are very susceptible to parasites and infection is usually fatal as describe by JENSEN & PIERSON (1975) and JURASEK (1981).

The relatively high percentage with which wild carnivores are invaded with *Taenia hydatigena* and *T. krabbei* (*T. ovis krabbei*) indicates that they play an important role, together with roaming dogs, or sheepdogs, in spreading cysticercosis to domestic or game ruminants in the open (CRAIG & CRAIG, 2005).

REFERENCES

- CRAIG, H. L. & CRAIG, P. S., 2005: Helminth parasites of wolves (*Canis lupus*): A species list and an analysis of published prevalence studies in Nearctic and Palaearctic populations. *Journal of Helminthology* **79**, 95–103.
- ECKERT, J., DEPLAZES, P., EWALD, D. & GOTTSTEIN, B., 1991: Parasitologische und immunologische Methoden zum Nachweis von *Echinococcus multilocularis* bei Füchsen. *Mitt Österr Ges Tropenmed Parasitol.* **13**, 25–30.
- FLUECK, W. T. & JONES, A., 2006: Potential existence of a sylvatic cycle of *Taenia ovis krabbei* in Patagonia, Argentina. **135**, 381–383.
- GOLDOVÁ, M., LAZAR, P., TÓTH, Š., LETKOVÁ, V., KONJEVIĆ, D. & ČURLÍK, J., 2004: Cysticercóza a sarkocystóza jeleða lesného (*Cervus elaphus*). *Folia venatoria* **34**, 188–194.
- JENSEN, R. & PIERSON, R. E., 1975: Cysticercosis from *Taenia hydatigena* in feedlot lambs. *JAVMA* **166**, 1183–1186.
- JURÁŠEK, V., 1981: Nález mladých foriem *Cysticercus tenuicollis* v mliečnom výkrme jahniat. *Veterinárství* **31**, 114.
- KHALIL, L. F., JONES, A. & BRAY, R. A., 1994: Keys to the Cestode Parasites of Vertebrates. CAB International, Wallington (UK), p. 665–673.
- KOLÁŘ, Z., ZAJÍČEK, D. & LÁVIČKA, M., 1978: Vývojová stadia *Taenia krabbei* Moniez, 1879 (*Cysticercus tarrandi*) u srnčí zvěře (*Capreolus capreolus*) v ČSR. *Vet. Med.* **23**, 251–256.
- MCKENNA, P. B., MACKENZIE, I. & HEATH, D. D., 1980: Fatal hepatitis cysticercosa in a red deer fawn. *New Zealand Veterinary Journal* **28**, 124.
- MIGAKI, G. & ZINTER, D. E., 1974: Hepatic lesions caused by *Cysticercus tenuicollis*. *JAVMA* **164**, 618–619.
- MURAI, E. & SUGAR, L. 1979: Taeniid species in Hungary (Cestoda, Taeniidae). I. Cysticercosis, coenurosis and hydatidosis of wild ungulates. *Parasitologia Hungarica* **12**, 41–52.
- PREMER, J., KRONE, O. & SCHUSTER, R., 2002: *Taenia krabbei* (Cestoda: Cyclophyllidea) in Germany and its delimitation from *T. ovis*. *Zool. Anz.* **241**, 333–375.
- ROMANENKO, L. N., 1988: Ultrastructure of the tegumentum surface of *Cysticercus ovis* and *C. tarrandi* from various intermediate hosts. *Trudy Vses. Inst. Gel'mintol.* **29**, 111–115.

- RUKAVINA, J., ČANKOVIĆ, M. & KUBELKA, D., 1973: Cisticerkoza (cervi) kod srna. *Veterinaria* **22**, 409–412.
- SHIMALOV, V. V. & SHIMALOV, V. T., 2003: Helminth fauna of cervids in Belorussian Polesie. *Parasitology Research* **89**, 75–76.
- SOULSBY, E. S. L., 1982: *Helminths, Arthropods and Protozoa of Domesticated animals*. Philadelphia, Lea and Febiger.
- TÓTH, Š., GOLDOVÁ, M., LAZAR, P., LETKOVÁ, V. & ČURLÍK, J., 2005: Histological staining methods in the diagnostics of deer cysticercosis. Book of Abstracts 1st International Symposium »Game and Ecology«. Brijuni, Republic of Croatia, Oct. 10–13 2005, p. 19
- TROPILO, J. & KISZAK, L., 1995: Cysticercosis in roe deer caused by *Cysticercus tenuicollis* and *C. cervi*. *Magazyn Weterynaryjny* **4**, 433.