

Goran Knežević, Davor Jokić, Dinko Knežević

Centralni gigantocelularni granulom agresivnog rasta: prikaz slučaja nakon višegodišnjeg praćenja

Central Giant Cell Granuloma of Aggressive Growth: Case Presentation after Monitoring for Several Years

Klinički zavod za oralnu kirurgiju Kliničke bolnice "Dubrava", Zagreb
Clinical Department of Oral Surgery, University Hospital "Dubrava", Zagreb

Sažetak

U radu je opisan centralni gigantocelularni granulom gornje čeljusti dijagnosticiran kod trogodišnje djevojčice. Bio je liječen kirurški, no ipak je u idućih osam godina dva puta recidivirao do veličine koja je razorila veći dio gornje čeljusti, resorbirala korijene frontalnih zuba i zaprijetila opsežnijim mutilirajućim zahvatom. U toj je fazi slučaj bio tretiran konzervativno, kirurškim pristupom te ga se pratilo još šest godina do potpunog izlječenja. Prikazano konačno stanje navodi autore na pitanje o tome jesu li radikalni kirurški zahvati potrebni u slučaju recidiva centralnih gigantocelularnih granuloma čeljusti.

Zaprimljen: 15. siječnja 2009.

Prihvaćen: 18. veljače 2009.

Adresa za dopisivanje

Prof. dr. sci. Goran Knežević
Klinički zavod za oralnu kirurgiju
Kliničke bolnice "Dubrava"
Av. G. Šuška 6, 10 000 Zagreb, Hrvatska
knezevic@sfzg.hr

Ključne riječi

gigantocelularni granulom

Uvod

Centralni gigantocelularni granulom čeljusti patološka je promjena s karakterističnom histološkom građom, razmjerno prepoznatljivom kliničkom slikom, nepatognomoničnim rendgenskim nalazom i nepredvidivim ponašanjem. Riječ je o reakciji organizma na neki podražaj, najvjerojatnije na koštano krvarenje koje može biti uzrokovano i traumom, a rezultat je tvorba ograničenoga rasta, češća kod djece i mlađih osoba. No, ima i slučajeva agresivnijega rasta te su oni u prošlosti bili uzrok češćim dijagnozama gigantocelularnog tumora čeljusti, a ponekad i neopravdano radikalnim i mutilirajućim kirurškim zahvatima (1-5).

Introduction

Central giant cell granuloma of the jaws is a pathological lesion of characteristic histological structure, relatively recognisable clinical features, non-pathognomonic radiographic finding and unpredictable behaviour. It is a reaction of the organism to an irritation, most probably to bone bleeding, which may be caused by trauma, resulting in a mass of restricted growth, which frequently occurs in children and young adults. However, there are cases of more aggressive growth, which in the past were often the reason for more frequent diagnoses of giant cell tumour of the jaws, and occasionally unjustified radical and mutilating surgical operations (1-5).

Tvorba vrlo slične kliničke i radiološke te identične patohistološke slike, ali sasvim druge etiologije, jest tzv. "smeđi tumor u hiperparatireoidizmu". Javlja se i uz primarni i sekundarni hiperparatireoidizam, pa u svakom susretu sa centralnim gigantocelularnim granulomom te drugim gigantocelularnim promjenama čeljusti, treba isključiti mogućnost endokrine etiologije i to odgovarajućim anamnestičkim pitanjima, laboratorijskim pretragama krvi i urina te ostalim dijagnostičkim postupcima. O tome i u proteklim godinama, a i danas postoji vrlo opsežna literatura(6-15).

U literaturi se za centralni gigantocelularni granulom javlja i naziv reparativni gigantocelularni granulom" (17) koji je godine 1953. uveo Jaffe (16), no valja ga izbjegavati jer nije riječ o reparaciji tkiva nego o reakciji na neki podražaj. Dakle, ako se već želi upotrijebiti naziv koji bi odredio patofiziološku narav promjene, tada je prikladnije reći reaktivni gigantocelularni granulom, bio on centralni ili periferni.

Već je rečeno da se tvorba nepredvidivo ponaša, što znači da katkada ograničeno raste, ali i onih vrsta koje rastu lokalno invazivno i sklonije su recidiviranju. Agresivan rast u histološkoj slici često prati i povećanje broja orijaških stanica mitotičkom aktivnošću stromalnih stanica, dok imunohistokemijska istraživanja nisu pokazala znatnije razlike između agresivnih i neagresivnih tvorbi (18). Nakon što se biopsijom odredi vrsta promjene i laboratorijski isključi mogućnost da tvorba ima endokrinu etiologiju, odabire se kirurški postupak i temeljito kiretira granulacijsko tkivo do zdrave kosti, a u slučaju recidiva kirurški se postupak ponavlja. Postoje podaci koji potvrđuju da je u liječenju neagresivnih, ali i agresivnih centralnih gigantocelularnih granuloma gornje čeljusti, dostatna temeljita kirurška kiretaža (19). Drugi, pak, smatraju da agresivne oblike granuloma treba radikalno ukloniti, što završava mutilacijom čeljusti. Ima također primjera uspješnog izlječenja centralnih granuloma aplikacijom kortikosteroida u samu koštanu promjenu. Ti se postupci opisuju kao jedini u liječenju (20-23) ili kao prva faza kojom se nastoji smanjiti tvorbu, kako bi naknadni kirurški zahvat bio što lakši (24).

A lesion which is very similar clinically, radiographically and with identical histopathological features, although completely different aetiology, is the so-called "brown tumour in hyperparathyroidism". This lesion occurs both with primary and secondary hyperparathyroidism and consequently when confronted with a central giant cell granuloma and with other giant cell jaw lesions the possibility of endocrine aetiology should be eliminated by the appropriate history questions, laboratory tests of blood and urine and other diagnostic procedures. In this regard very comprehensive literature can be found (6-15).

Throughout the literature the term for central giant cell granuloma, which was introduced in 1953 by Jaffe (16) can still be found, "Reparative giant cell granuloma" (17), which is a term that should be avoided as it is not a case of reparation of tissue but of reaction to a certain irritation. Thus when the need is to use a term to define the physiopathological nature of the lesion, then the term reactive giant cell granuloma is more appropriate, whether central or peripheral type.

As aforementioned lesion is of unpredictable behaviour, and thus there are cases of limited growth, and also those which grow locally invasively and which are more inclined to recurrence. Aggressive growth is frequently accompanied in the histological finding with an increased number of giant cells and mitotic activity of stromal cells, while immunohistochemical examinations do not show significant differences between aggressive and non-aggressive masses (18). After the type of lesion has been determined by biopsy, and laboratory tests excluded the possibility that the lesion is of endocrine aetiology, the procedure is surgical and thorough curettage of the granulation tissue is performed up to healthy bone. In the case of recurrence the surgical operation is repeated. There are data which confirm that thorough surgical curettage is sufficient in the treatment of non-aggressive central giant cell granuloma and also aggressive central giant cell granuloma of the maxilla (19). Others however consider that aggressive forms of granuloma should be radically removed, which leads to mutilation of the jaws. There are also examples of successful treatment of central granuloma by application of corticosteroids in the bone lesion itself. These procedures are described as the only ones in the treatment (20-23) or as the first phase of treatment by which an attempt is made to reduce the lesion in order that the following surgical operation is less mutilative (24).

Prikaz slučaja

Djevojčica u dobi od 3 godine bila je dovedena na pregled zbog plavo-crvenkastoga zadebljanja na alveolarnom grebenu gornje čeljusti u predjelu mliječnog očnjaka i prvog mliječnog kutnjaka s desne strane. Roditelji su tvorbu uočili dva mjeseca ranije te su uočili da postupno raste. Nakon laboratorijske obrade bio je obavljen zahvat u općoj inhalacijskoj anesteziji. Tada su izvađeni navedeni mliječni zubi te obavljena kiretaža promjene iz kosti s djelomičnom ekscizijom alveolarne gingive, sačuvani su zametci trajnih zuba. Pronađeno tkivo histološki je bilo građeno od vretenastih stanica raspoređenih u tračke između kojih su nađene mononuklearne stanice s piknotičkim jezgrama, mnogobrojne multinuklearne orijaške stanice te mjestimične mitoze. U blizini je bilo i nešto fragmenata koštanoga tkiva. Postoperativni tijek bio je bez poteškoća (Slika 1.).

Nakon pet godina djevojčica je ponovno došla zbog suspektnog recidiva distalno i iznad krune krivo položenog lateralnog trajnog sjekutića. Kroz desni je prosijavala plavičasta boja koštane promjene. Rendgenski je nalaz pokazao prosvjetljenje između korijena lateralnog sjekutića i krune retiniranog očnjaka. Korijen lateralnog sjekutića bio je djelomice resorbiran (Slika 2.).

Laboratorijski nalazi (Ca 2,51, P 1,35) nisu potvrdili mogućnost primarnog hiperparatiroidizma, a pedijatar nije povišene vrijednosti alkalne fosfatase ocijenio patofiziološki važnima. Zahvat je bio ponovljen u općoj inhalacijskoj anesteziji, a bila je obavljena kohleacija tkiva bez uklanjanja zuba i zubnih zametaka. Patohistološki ponovno je bilo nađeno tkivo koje odgovara centralnom gigantocelularnom granulomu s mnogobrojnim orijaškim stanicama, dosta krvnih žila s mjestima krvarenja te komadićima nekrotične kosti. Postoperacijski tijek bio je bez osobitih teškoća. Dijete je dolazilo na kontrolne preglede i bilo je upućeno na endokrinološku obradu kako bi se ponovno isključila mogućnost hiperparatiroidizma.

Zbog korektivnih kirurških zahvata na prstima ruku (egzostoze), roditelji sljedeće tri godine nisu dovodili dijete na kontrole. Javili su se u trenutku kad se pojavio klinički jasan recidiv promjene s deformacijom prednjeg dijela alveolarnog grebena. Radiološka obrada i CT-snimke pokazali su golem defekt gornje čeljusti koji je podizao dno nosa i širio se po njegovu dnu unatrag prema stražnjem rubu gornje čeljusti. Korijeni izniklih prednjih zuba djelomice su bili resorbirani, a zubi pomični (Slike 3, 4. i 5.).

Case Report

A three-year-old girl was referred to the Department for examination because of a blue-reddish swelling on the alveolar ridge of the maxilla in the region of the deciduous canine and first deciduous molar on the right side. The swelling, which had gradually increased in size, was first noticed by her parents two months prior to the examination. Following laboratory tests an operation was performed under general inhalation anaesthesia. The aforementioned deciduous teeth were extracted and curettage performed of the lesion from bone with partial excision of the alveolar gingiva and the germs of the permanent teeth preserved. Histologically the tissue found consisted of spindle cells, arranged in bands between which mononuclear cells with pyknotic nuclei were found, numerous multinuclear giant cells and scattered mitoses. Some fragments of bony tissue were found in the surroundings. Postoperative course passed without complication (Fig. 1).

After five years she was again referred to the Department because of a suspected recurrence distally and above the crown of a misplaced lateral permanent incisor. Bluish colour of the bony lesion showed through the gum. The radiographic finding showed translucence between the root of the lateral incisor and the crown of the impacted canine. The root of the lateral incisor was partially resorbed (Fig. 2). Laboratory findings (Ca 2.51, P 1.35) did not confirm the possibility of primary hyperparathyroidism, and the raised value of alkaline phosphatase was not considered by the paediatrician to be physiopathologically significant. The operation was repeated under general inhalation anaesthesia and curettage of tissue was performed without extraction of the tooth and teeth germs. Histopathologically tissue was again found which resembled central giant cell granuloma, with numerous giant cells, numerous blood vessels and areas of bleeding and small pieces of necrotic bone. Postoperative course passed without particular complications. The child was recalled for a check-up and endocrinological examination, and again the possibility of hyperparathyroidism was excluded.

Because of surgical corrective operations on the fingers of the hands (exostoses) the parents did not bring the child for a check-up during the following three years, i.e. up until the occurrence of clinically evident recurrence of the lesion with deformation of the anterior part of the alveolar ridge. Radiographic and CT examination showed a massive defect of the maxilla which raised the nasal floor and extended

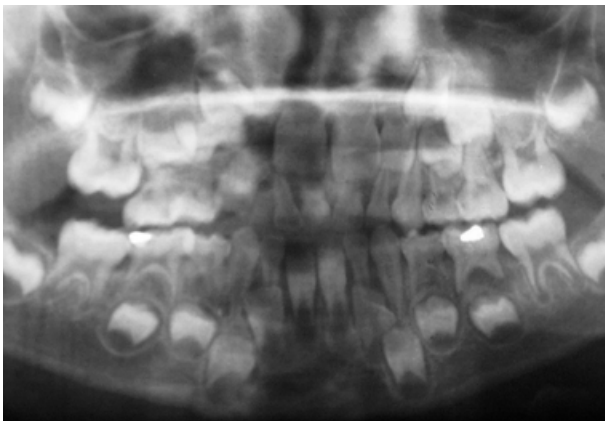
Bile su dvije mogućnosti kirurškog postupka. Ona prva radikalna značila bi veliko mutiliranje čeljusti s gubitkom velikoga dijela čeljusti i zuba, a druga konzervativna obuhvatila bi kohleaciju tkiva i uklanjanje zuba s resorbiranim korijenima.

U prvom zahvatu bila je obavljena biopsija tkiva i ponovno je dobivena dijagnoza centralnog gigan-tocelularnog granuloma, a zatim je u drugom zahvatu ponovljena kohleacija mekog tkiva koje je razorilo prednju stijenku maksile i kost sve do tubera. Prema kranijalno ostala je sačuvana samo sluznica dna nosa, a prema dolje nepčana sluznica. Izva-

along the nasal floor posteriorly up to the posterior edge of the maxilla. The roots of the erupted frontal teeth were partially resorbed and the teeth were mobile (Figs. 3,4,5).

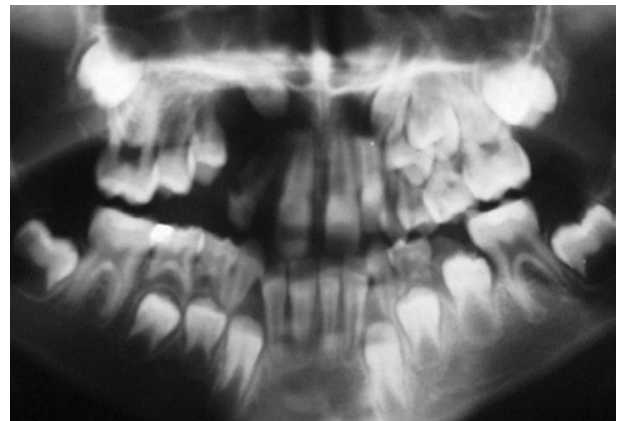Two surgical methods were possible. One radical, involving significant mutilation and loss of a large part of the jaw and teeth, and another conservative with coxheation of the tissue and extraction of the tooth with resorbed roots.

In the first operation tissue biopsy was performed and central giant cell granuloma again diagnosed. In the second operation coxheation was repeated



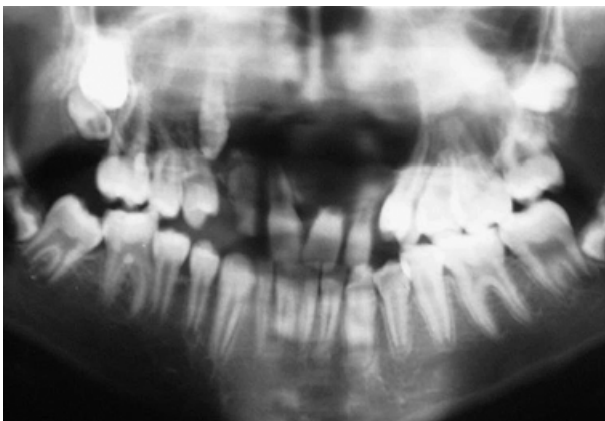
Slika 1. Ortopantomogramska snimka prije prvog kirurškog zahvata. Nema vidljivih promjena na mjestu tvorbe u gornjoj čeljusti.

Figure 1 Orthopantomogram prior to the first surgical operation. No visible changes at the site of the mass in the maxilla.



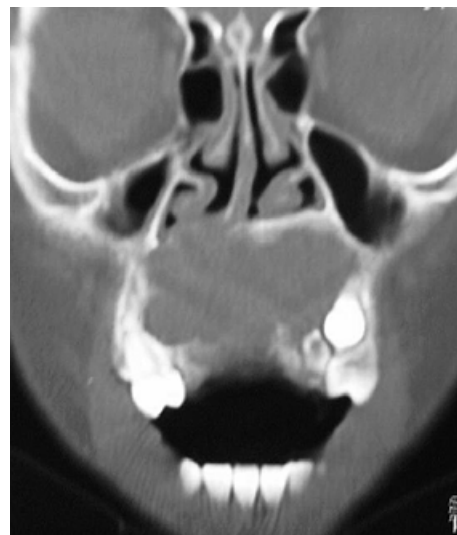Slika 2. Rendgenski nalaz prije drugog zahvata. Vidljivo je prosvjetljenje u gornjoj čeljusti.

Figure 2 Radiographic finding prior to the second operation. Visible translucency in the maxilla.



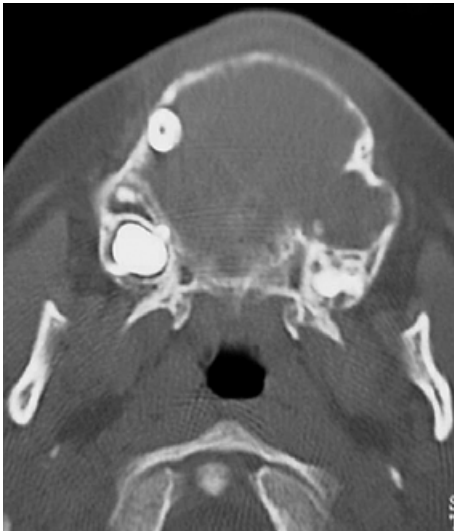Slika 3. Rendgenski nalaz pokazuje promjer defekta u gornjoj čeljusti

Figure 3 Radiographic finding showing the diameter of the defect in the maxilla.

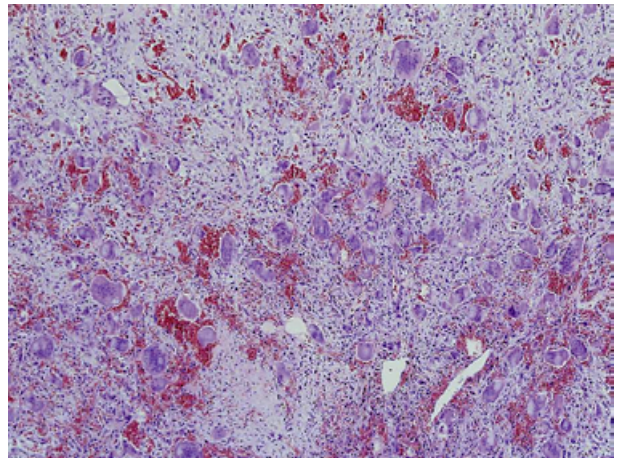


Slika 4. Sagitalni CT-presjek pokazuje opseg defekta u gornjoj čeljusti u razini očnjaka. Promjena se širi prema dnu nosa i maksilarnim sinusima.

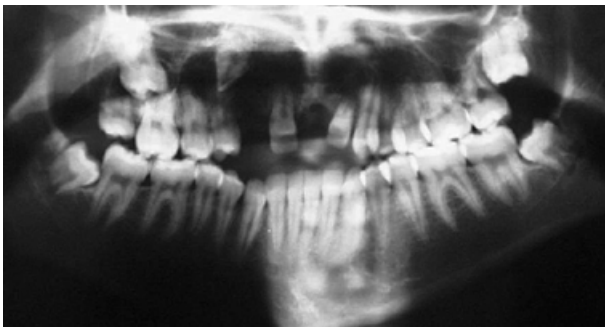
Figure 4 Saggital CT cross-section at the level of the canine showing the extent of the defect in the maxilla. The lesion spreading towards the nasal floor and maxillary sinuses.



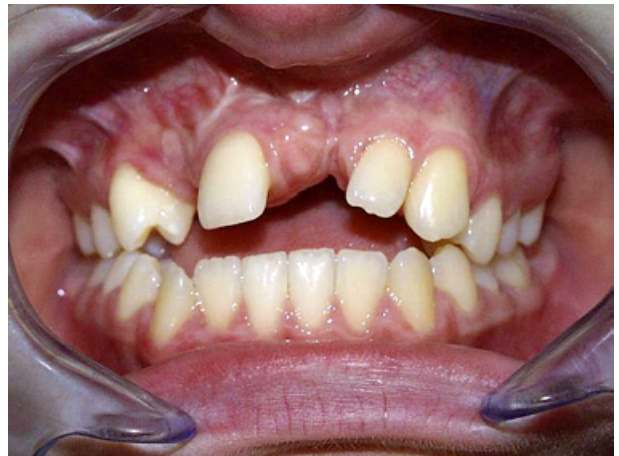Slika 5. Horizontalni CT-presjek pokazuje koliko je koštanoga tkiva razoreno granulomom
Figure 5 Horizontal CT cross-section showing the amount of bony tissue destroyed by the granuloma.



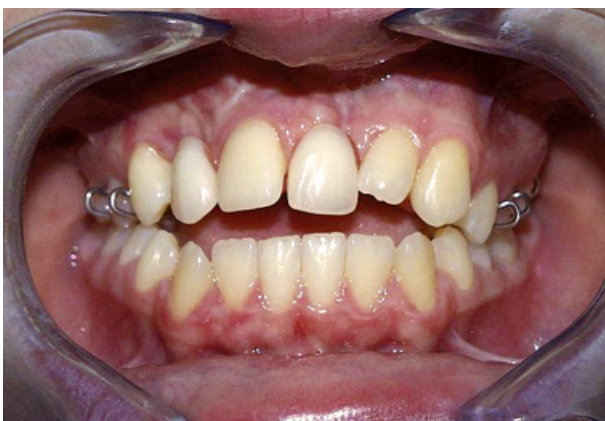Slika 6. Histološki izgled uzorka (HE 100 x) prof. Spomenka Manojlović, Odjel za patologiju Kliničke bolnice "Dubrava", Zagreb
Figure 6 Histologic appearance of the specimen (HE 100 x) prof. Spomenka Manojlović, Department of Pathology, University Hospital "Dubrava", Zagreb



Slika 7. Ortopantomogram prije posljednjeg kirurškog zahvata
Figure 7 Orthopantomogram prior to the final surgical operation.



Slika 8. Klinički izgled pacijentice prije posljednjeg kirurškog zahvata
Figure 8 Clinical appearance of the patient prior to the final surgical operation.



Slika 9. Izgled s privremenom ortodontskom napravom
Figure 9 Appearance with a temporary orthodontic appliance.

đeni su bili desni lateralni i lijevi centralni sjekutić potpuno resorbiranih korjenova, a ostali zubi su bili sačuvani. Šupljina je nakon toga ispunjena jodoformnom vrpcom koja je bila uklonjena u općoj anesteziji nakon pet dana, a otvor sašiven pojedinačnim šavovima. Uklonjeno je bilo 14 nepravilnih komada tkiva promjera jedan do dva centimetra, a patohistološki nalaz pokazao je da su svi građeni od guste mase stanica tipa fibrocita, među kojima se nalazilo i mnogo multinuklearnih orijaških stanica. Stroma je bila prožeta proširenim kapilarama i ekstravazatima eritrocita oko kojih su bile nakupine orijaških stanica. Nisu bili nađeni znaci polimorfizma, osim vrlo malo mitozna (Slika 6.).

U razdoblju postoperacijskog tijeka nije bilo komplikacija i pacijentica je dolazila na redovite kontrole. Ortodont je izradio mobilnu napravu kako bi minimalno povećao interdentalni prostor te nakon završetka rasta i razvoja omogućio protetsku rehabilitaciju. Gubitak kosti u gornjoj čeljusti onemogućio je znatniji pomak zuba. Na mjesto zuba koji manjkaju u zubnome nizu u ortodontsku su napravu iz estetskih razloga bili postavljeni umjetni zubi.

Nakon šest godina pacijentici, tada već djevojci od 17 godina, predloženo je vađenje gornjeg ocnjaka koji je ostao retiniran u čeljusti (Slika 7.).

Zub je bio izvađen iz izrazito tvrde kosti s kojom je bio ankilotično povezan. Preostali zubi su bili stabilni, ali zbog otvorenog zagriža do završetka rasta i razvoja čeljusti o daljnjoj terapiji brinuo se ortodont (Slike 8. i 9.), a nakon toga treba slijediti implantoprotetska rehabilitacija.

Rasprava

Klinička obilježja opisanog slučaja vrlo je teško objasniti. Nastanak centralnoga gigantocelularnog granuloma u dječjoj dobi nije neuobičajena i odgovara podacima iz literature (25-30). Barnes (31), kao veliki autoritet u patologiji glave i vrata, tvrdi da ta bolest ostaje i dalje nerješiva kontroverzija, ako se traži odgovor na pitanje je li riječ o reaktivnoj ili neoplastičnoj promjeni ili ako se postavi pitanje etiologije. S kojim etiološkim čimbenikom povezati njezin nastanak u dječjoj dobi, pitanje je

of the soft tissue which had destroyed the anterior wall of the maxilla and the bone up to the tuber. Cranially only the mucous membrane of the nasal floor remained preserved and towards the bottom of the palatal mucous membrane. The right lateral and left central incisor with completely resorbed roots were extracted and the remaining teeth preserved. The cavity was filled with Jodoform tape, which was removed after five days under general anaesthesia and the opening sutured with separate sutures. Fourteen irregular pieces of tissue were removed, 1-2 cm in diameter, and the histopathological finding showed that they all consisted of dense masses of cells, fibrocytic type, among which were many multinuclear giant cells. The stroma was permeated with enlarged capillaries and extravasated erythrocytes, around which there were accumulations of giant cells. No signs of polymorphism were found and very few mitoses (Fig 6).

Postoperative course passed without complications and the patient came for regular check-ups. A mobile appliance was fabricated by the orthodontist in order to minimally increase the interdental space and for prosthetic rehabilitation until the conclusion of growth and development. Loss of bone in the maxilla prevented more significant movement of the teeth. For aesthetic reasons artificial teeth were included in the orthodontic appliance in place of the missing teeth in the dental arch.

After six years the patient, now a seventeen-year-old girl, was advised to have the impacted upper canine extracted, which had remained impacted in the jaw (Fig. 7). The tooth was extracted from extremely hard bone with which it was ankylosically connected. The remaining teeth are stable. However, because of open bite further therapy until completion of growth and development of the jaws remains in the domain of the orthodontist (Figs. 8 & 9). After that implantoprothetic rehabilitation will follow.

Discussion

The clinical characteristics of the case presented are very hard to explain. Occurrence in childhood is not unusual and corroborates reports in the literature (25-30). Barnes (31), an unquestionable authority in the pathology of the head and neck, states that central giant cell granuloma of the jaws remains an unsolved controversy, particularly regarding the question of whether it is a case of a reactive or neoplastic lesion or whether it is a question of aetiology. Which etiological factor is connected with the occurrence

na koje nema odgovora, kao što uopće nema jasnog odgovora o sigurnom etiološkom čimbeniku. Intramedularno krvarenje i lokalna trauma ili hormonalni utjecaj povišene razine estrogena, samo su pretpostavke koje je nemoguće potvrditi, kao što ih i dosadašnja istraživanja nisu potvrdila (31).

Uporni recidivi mogu se objasniti suzdržanim kirurškim postupcima u odnosu prema zamecima trajnih zuba i okolnoj kosti. Solovitzky i suradnici (32) predlažu resekciju dijela čeljusti u svim slučajevima centralnih gigantocelularnih granuloma gornje čeljusti i sinusa, a u ostalim lokalizacijama preporučuju kiretažu s brušenjem kosti do zdravoga tkiva.

Provesti tako radikalni postupak tijekom prvog ili drugog kirurškog zahvata, značilo bi velik defekt dijela čeljusti i zuba, a radikalni zahvat kod trećega kirurškog zahvata uzrokovao bi potpuni gubitak frontalnog i nepčanog dijela gornje čeljusti.

Isto tako vrlo je teško objasniti prestanak rasta tvorbe nakon posljednjeg kirurškog zahvata, jer ni po čemu nije bio drugačiji od prijašnjih, osim u količini uklonjenoga granulomatozno promijenjenoga tkiva.

Zaključak

Smatramo da o svojstvima centralnoga gigantocelularnog granuloma nema važnijih informacija koje bi potvrđivale potrebu radikalnog kirurškog zahvata u slučajevima poslijeoperacijskih recidiva. Tome u prilog govore činjenice da o nastanku pravih, primarnih gigantocelularnih tumora čeljusti ugledni svjetski patolozi vrlo rijetke govore, jako su suzdržani i oprezni, te da je vrlo malo podataka o malignoj alteraciji centralnih gigantocelularnih granuloma čeljusti. Takve mogućnosti spominjale su se proteklih godina u razdoblju kada su se gigantocelularni granulomi podvrgavali terapijskom zračenju, što se danas ne preporučuje, posebice ne kod djece i mlađih osoba (31).

in childhood is a question to which there is no answer. Just as there is no answer with regard to the positive etiological factor. Intramedullary bleeding and local trauma or hormonal effects of raised levels of oestrogen remain mere presumptions, which are impossible to confirm, and the investigations have still not confirmed it until now (31).

Persistent recurrences can be explained by the reserved surgical procedures with regard to the germs of permanent teeth and the surrounding bone. Solovitzky et al (32) suggest resection of part of the jaw in all cases of central giant cell granuloma of the maxilla and sinuses, while in other localizations they recommend curettage with grinding of the bone up to healthy tissue. To perform such a radical procedure during the first or second surgical operation would involve a significant defect of part of the jaw and teeth and a radical procedure during the third surgical operation would cause complete loss of the anterior and palatal part of the maxilla.

In the present case it is difficult to explain why the lesion stopped growing after the last surgical operation, which in no way differed from the previous operations, apart from the amount of granulomously altered tissue removed.

Conclusion

In conclusion we consider that no significant information exists on the characteristics of central giant cell granuloma which confirms the need for a radical surgical operation in cases of postoperative recurrences. This is supported by the fact that information on the existence of true, primary giant cell tumours of the jaws among world pathologists is very rare, reserved and cautious, and that scarce data exist on malignant alteration of central giant cell granuloma of the jaws. Such possibilities were mentioned in the past and at a time when giant cell granulomas were subjected to therapeutic radiation, which today is not recommended, particularly for children and young adults (31).

Abstract

A central giant cell granuloma of the maxilla is presented, which was diagnosed in a three-year-old girl and surgically treated, and which recurred on two occasions in the following eight years to a size which destroyed a large part of the maxilla, resorbed the roots of the anterior teeth and threatened that it could lead to the need for a more extensive mutilating operation. In this phase the case was treated by a conservative surgical method and further monitored for six years until the complete healing of the central granuloma. The presented final condition prompted the authors to question whether a radical surgical operation is necessary in the case of recurrences of central giant cell granuloma of the jaws.

Received: January 15, 2009

Accepted: February 18, 2009

Address for correspondence

Prof. Goran Knežević
Clinical Department of Oral Surgery
University Hospital "Dubrava"
Av. G. Šuška 6, 10000 Zagreb
Croatia
knezevic@sfgz.hr

Key words

Granuloma, Giant Cell

References

- Knežević G. Gigantocelularne i druge patološke promjene čeljusti te njihov odnos prema hiperparatireoidizmu [dissertation]. Zagreb: Stomatološki fakultet; 1983.
- Knežević G, Bunarević A, Knežević F. Giant cell tumor of bone – does it ever occur in jawbones? Abstracts of the First International Congress on Oral Cancer and Jaw Tumours. Singapore; 1987. p. 170.
- Knežević G. Oralna kirurgija II. dio. Zagreb: Medicinska naklada; 2003.
- Knežević G. Preventivna važnost poznavanja gigantocelularnih promjena čeljusti. *Acta Stomatol Croat.* 1996;30(2):141-6.
- Knežević G, Virag M, Bunarević A. Gigantocellular tumors of the jaws in theory and practice. *Chir Maxillofac Plast.* 1983;13(1):11-7.
- Knežević G, Bagatin M. Centralni gigantocelularni granulom kao prvi klinički znak primarnog hiperparatireoidizma. *Acta Stomatol Croat.* 1985;19(2):101-12.
- Knežević G. Secondary hyperparathyroidism and pathological changes in the jaws of patients on long-term hemodialysis. *Chir Maxillofac Plast.* 1984;14(1):1-12.
- Knežević G, Uglešić V, Kobler P, Svajhler T, Bagatin M. Primary hyperparathyroidism: evaluation of different treatments of jaw lesions based on case reports. *Br J Oral Maxillofac Surg.* 1991;29(3):185-8.
- Knežević G. Secondary hyperparathyroidism and pathologic changes of jaws in patients on long term haemodialysis. Abstracts of 8th Congress of European Association for Maxillofacial Surgery. Madrid, Spain; 1986. p. 197.
- Knežević G. The evaluation of different medical treatments of primary hyperparathyroidism of jaws. Abstracts of 15th Congress of International Association for Maxillofacial Surgery. Belgrade; 1990. p. 8.
- Knežević G. Hyperparathyroidism: radiological study of jaw lesions in planning of medical treatment. Abstracts of 10th Congress of International Association of Dento-Maxillo-Facial Radiology. Seoul, Korea; 1994. p. 61.
- Knežević G. Primary hyperparathyroidism of jaws: surgical or non surgical management. Abstracts of the 14th Congress of International Association for Maxillofacial Surgery. Habana; 1989. p. 30.
- Knežević G. Značaj diferencijalne dijagnostike gigantocelularnih promjena čeljusti. *Knjiga sažetaka 1. Svjetskog kongresa hrvatskih stomatologa.* Zagreb, Croatia; 1994. p. 53.
- Daniels JS. Primary hyperparathyroidism presenting as a palatal brown tumor. *Oral Surg Oral Med Oral Pathol Oral Radiol Endod.* 2004;98(4):409-13.
- Lehnerdt G, Metz KA, Krüger C, Dost P. A bone-destroying tumor of the maxilla. Reparative giant cell granuloma or brown tumor? *HNO.* 2003;51(3):239-44.
- Jaffe HL. Giant-cell reparative granuloma, traumatic bone cyst, and fibrous (fibro-oseous) dysplasia of the jawbones. *Oral Surg Oral Med Oral Pathol.* 1953;6(1):159-75.
- Triantafyllidou K, Zouloumis L, Karakinaris G, Kalimeras E, Iordanidis F. Brown tumors of the jaws associated with primary or secondary hyperparathyroidism. A clinical study and review of the literature. *Am J Otolaryngol.* 2006;27(4):281-6.
- Kruse-Lösler B, Diallo R, Gaertner C, Mischke KL, Joos U, Kleinheinz J. Central giant cell granuloma of the jaws: a clinical, radiologic, and histopathologic study of 26 cases. *Oral Surg Oral Med Oral Pathol Oral Radiol Endod.* 2006;101(3):346-54.
- Rawashdeh MA, Bataineh AB, Al-Khateeb T. Long-term clinical and radiological outcomes of surgical management of central giant cell granuloma of the maxilla. *Int J Oral Maxillofac Surg.* 2006;35(1):60-6.
- Kermer C, Millesi W, Watzke IM. Local injection of corticosteroids for central giant cell granuloma. A case report. *Int J Oral Maxillofac Surg.* 1994;23(6 Pt 1):366-8.
- Abdo EN, Alves LC, Rodrigues AS, Mesquita RA, Gomez RS. Treatment of a central giant cell granuloma with intralesional corticosteroid. *Br J Oral Maxillofac Surg.* 2005;43(1):74-6.
- Carlos R, Sedano HO. Intralesional corticosteroids as an alternative treatment for central giant cell granuloma. *Oral Surg Oral Med Oral Pathol Oral Radiol Endod.* 2002;93(2):161-6.
- Adornato MC, Paticoff KA. Intralesional corticosteroid injection for treatment of central giant-cell granuloma. *J Am Dent Assoc.* 2001;132(2):186-90.
- Shohat I, Shoshani Y, Taicher S. Medical treatment of central giant cell granuloma of the jaws. *Refuat Hapeh Vehashinayim.* 2002;19(4):37-44.
- Lin YJ, Chen HS, Chen HR, Wang WC, Chen YK, Lin LM. Central giant cell granuloma of the mandible in a 7-year-old boy: a case report. *Quintessence Int.* 2007;38(3):253-9.
- Allen DT, Sheats RD. A central giant cell granuloma in a patient seeking orthodontic treatment. *J Am Dent Assoc.* 2001;132(9):1255-60.
- Stavropoulos F, Katz J. Central giant cell granulomas: a systematic review of the radiographic characteristics with the addition of 20 new cases. *Dentomaxillofac Radiol.* 2002;31(4):213-7.
- Regezi JA. Odontogenic cysts, odontogenic tumors, fibrous, and giant cell lesions of the jaws. *Mod Pathol.* 2002;15(3):331-41.
- Potter BJ, Tiner BD. Central giant cell granuloma. Report of a case. *Oral Surg Oral Med Oral Pathol.* 1993;75(3):286-9.
- Bodner L, Woldenberg Y, Bar-Ziv J. Radiographic features of large cystic lesions of the jaws in children. *Pediatr Radiol.* 2003; 33(1):3-6.
- Barnes L. *Surgical pathology of the head and neck.* 2nd ed. New York Basel: Marcel Dekker Inc. 2001; p. 1159-69.
- Stolovitzky JP, Waldron CA, McConnel FM. Giant cell lesions of the maxilla and paranasal sinuses. *Head Neck.* 1994;16(2):143-8.