

Expression of Vascular Endothelial Growth Factor in Proliferative Diabetic Retinopathy

Maja Merlak¹, Damir Kovačević¹, Tihomir Balog², Tanja Marotti², Tamara Mišljenović^{3,1}, Maša Mikuličić^{3,1} and Iva Dekaris^{2,4}

¹ Department of Ophthalmology, University Hospital »Rijeka«, Rijeka, Croatia

² Division of Molecular Medicine, Institute »Ruder Bošković«, Zagreb, Croatia

³ Eye Polyclinic »Dr. Luciana Pavičević«, Rijeka, Croatia

⁴ Eye Clinic »Svjetlost«, Zagreb, Croatia

ABSTRACT

The study included 20 patients with diabetes mellitus type I (DM I) and 16 with type II (DM II) suffering from proliferative diabetic retinopathy (PDR) for which they underwent vitrectomy. The quantity of VEGF and its receptors in the vitreous of investigated patients were measured by immunoassay and results compared between patients with DM I and II. The mean levels in the vitreous were significantly higher in diabetics with PDR and diabetes mellitus I (432.2 pg/mL, 1460.4 pg/mL and 1054.6 pg/mL) than in diabetics with PDR and diabetes mellitus II (147.5 pg/mL, 641.4 pg/mL and 448.5 pg/mL) and in control group (63.26 pg/mL). Considering that VEGF, VEGFR1 and VEGFR2 levels were significantly higher in diabetics with PDR than in controls and that the patients with DM I had higher levels than with DM II, anti-VEGF therapy might be beneficial for diabetics with PDR, especially those with DM I.

Key words: vascular endothelial growth factor – VEGF; VEGF receptor; vitreous, proliferative diabetic retinopathy

Introduction

It is known that vascularisation and proliferation have a main role in complications in patients with proliferative diabetic retinopathy (PDR). We studied the role of VEGF and its receptors in the development of vascularisation and proliferation in patients with PDR. We determined the quantity of VEGF and its receptors in the ocular fluids in patients with PDR in DM I and DM II. We aimed to establish whether VEGF level is increased in the vitreous of patients with PDR and how it depends on type of diabetes mellitus (DM I and DM II).

Diabetes mellitus is the most frequent endocrine disease in developed countries. The disease is estimated to be present in 2–5% of the world's population and diabetic retinopathy is the most frequent cause of legal blindness in the population of 30–70-year old.

The most difficult and long-lasting complications in diabetes mellitus are caused by the changes present in vessels, creating vessel damage and angiopathy in whole body as well as in the eye^{1,2}.

Physiopathology of diabetic retinopathy

The lesions that characterize diabetic retinopathy are the results of four main processes: the appearance of micro-aneurysms, increased vascular permeability, capillary occlusion and fibrous and neovascular proliferation^{2–4}.

An increase in the number of micro-aneurysms is considered a risk sign for progression of retinopathy. A further sign that indicates an even greater risk of progression of retinopathy is excessive permeability of the retinal vessels. The lack of pericytes compromise nutritional supply to the endothelial cells and impair the barrier function of these cells. Fluid leakage can range from micro-exudates to the macular edema, which can seriously reduce vision. Another lesion that can appear in diabetic retinopathy is capillary occlusion, which gives rise to an area of retinal ischemia. The resulting ischemia leads to the proliferation of vessels that seek out new routes to irrigate the affected area. The vessels are fragile and made up of endothelial cells that proliferate without the bene-

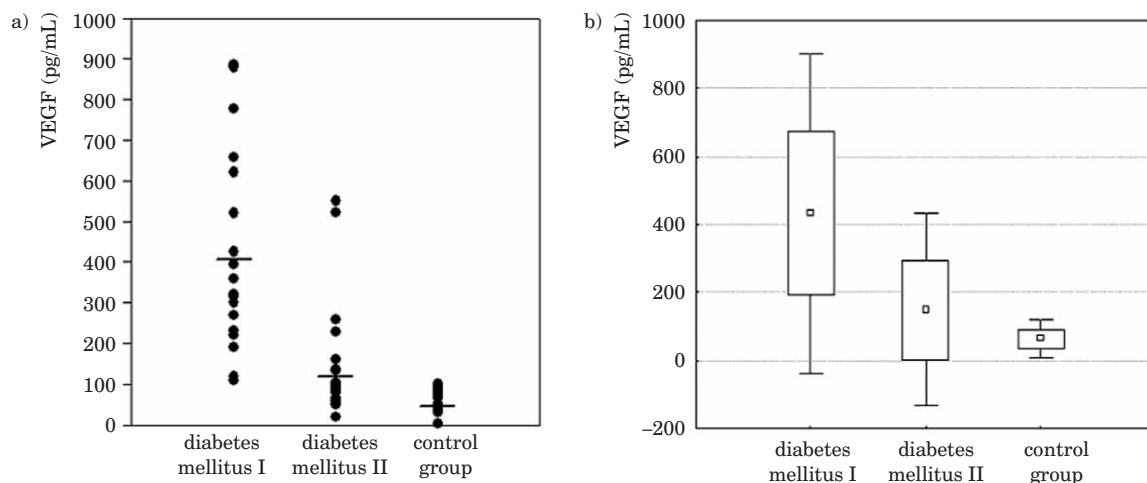


Fig. 1. VEGF levels in vitreous in patients with PDR (box plot).

fit of a consistent basement membrane. Sometimes the new vessels are surrounded by fibrous tissue, and the fibrovascular complex adheres to the posterior part of the vitreous cavity. Traction on the vitreous can rupture the weak structure of the new vessels and lead to vitreous hemorrhage or even retinal detachment²⁻⁶.

Biochemical alterations-first stage

Prolonged hyperglycemia is the key element to all alterations involved in the development of diabetic retinopathy. High concentrations of blood glucose lead to changes in cell metabolism such as: polyol pathway activation, diacylglycerol protein kinase C pathway activation, stimulation of cellular oxidative stress and changes in macromolecule structure and function via the formation of advanced glycation end products (AGEs). These biochemical alterations account the most of the cellular lesions that appear in diabetic retinopathy especially in the endothelium of retinal vessels, which lead to endothelial dysfunction⁷⁻⁹.

Second stage-endothelial dysfunction

Endothelial cells are able to release vascular growth factors that are important for vascular proliferation, an important step in the development of diabetic retinopathy. Of all the growth factors, vascular endothelial growth factor (VEGF) is the one most closely related with retinal vascularisation as it participates in the formation of new vessels that appear after retinal ischemia⁹.

Third stage-failure of retinal vascular function

Deficient antithrombotic function together with stimulation of platelet function may favor ischemic phenomena. These factors lead to a pathophysiological process that accounts for the many complex morphological lesions that appear in patients with diabetes who develop diabetic retinopathy¹⁰.

Therapeutic management of diabetic retinopathy

Development of drugs that prevent the appearance of diabetic retinopathy (DR) is a fundamental goal in current research. Early detection of the initial signs of diabetic retinopathy is crucial for the success of preventive measures.

Intensive control of glycemia is the foundation upon which all other preventive or therapeutic measures rest. Achieving HbA1c levels below 6.5% should be a major priority from the moment diabetes is diagnosed. Only a few conservative treatment options are available now for DR; however, they are only able to slow-down progression of the disease, which sometimes takes its sight-threatening course despite all the available treatment.

Anti-platelet drugs (aspirin, ticlopidine, dipyridamole, triflusal) delay the progression of diabetic retinopathy in its initial stages. Large clinical trials with PKC inhibitors are being carried out. Antioxidant drugs can control oxidative stress, which modulates all other mechanisms involved in the appearance of retinal lesions¹¹.

Vascular growth inhibitors deserve special mention, particularly for the prevention of proliferative diabetic retinopathy.

It may therefore be necessary to associate several groups of drugs that act through different mechanisms in order to deal with the multifactorial mechanisms that give rise to retinal lesions in diabetes mellitus¹².

Patients and Methods

The study included 36 patients with PDR; middle age 65.33; 27 male, (75%), 9 female (25%); 20 patients with DM I and 16 patients with DM II from the Department of Ophthalmology, University Hospital Rijeka, which were underwent vitrectomy from January 2006 to January 2008. In that period it was totally 116 patients who underwent vitrectomy. All diabetic patients that suffered from any other concomitant eye disease apart from PDR

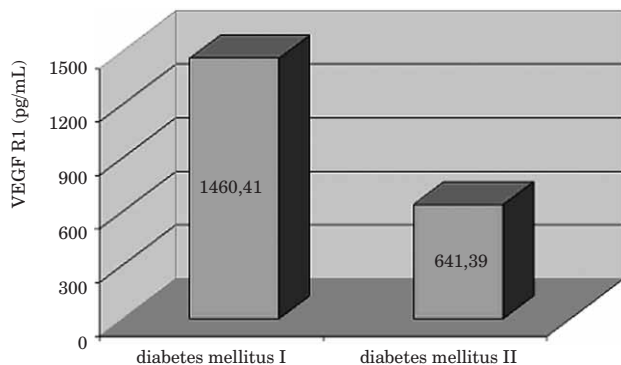


Fig. 2. VEGFR1 levels in vitreous of patients with PDR.

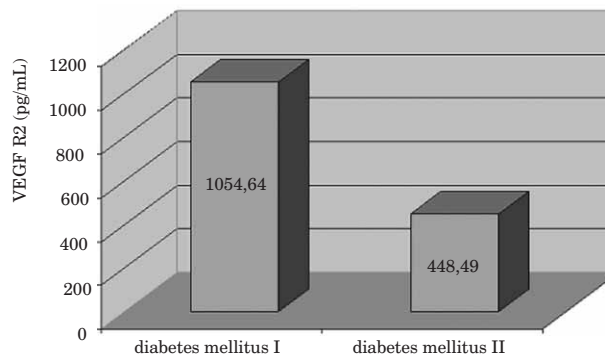


Fig. 3. VEGFR2 levels in vitreous of patients with PDR.

(or from any severe systemic inflammatory disease) were excluded from the study.

During the surgery the sample of vitreous were collected (with needle Medoject 23 G, syringe Brown 2 ccm) and stored at the -80°C till cytokine measurement. Controls consisted of the sample of vitreous taken from cadavers ($n=10$).

Quantity of VEGF, VEGFR1 and VEGFR2 in patients with PDR and either DM I or DM II were measured by immunoassay (ELISA, R&D Systems, USA), as well as vitreal samples from controls ($n=10$).

Results

The mean VEGF levels in the vitreous of diabetic patients (432.2 pg/mL and 147.5 pg/mL) were significantly higher than in controls (63.26 pg/mL, $p<0.005$). Moreover, diabetics with PDR and diabetes mellitus type I had significantly higher levels of VEGF (432.23 pg/mL) as compared to those with diabetes mellitus II (147.53 pg/mL, $p<0.005$) (Figure 1a and b).

Activity of VEGF is regulated by two distinct receptors: VEGFR1 and VEGFR2. The mean VEGFR1 level in the vitreous of patients with PDR and diabetes mellitus type I (1460.41 pg/mL) was significantly higher as compared to patients with PDR and diabetes mellitus type II (641.39 pg/mL, $p<0.005$) (Figure 2).

Similar result was also found with the other receptor – VEGFR2. Namely, the mean VEGFR2 level in the vitreous of diabetics with PDR and diabetes mellitus I (1054.64 pg/mL) was significantly higher than in diabetics with PDR and diabetes mellitus II (448.49 pg/mL, $p<0.005$) (Figure 3).

Discussion and Conclusion

In the last decade great advance has been achieved in the research of therapeutical possibilities to block the vascular endothelial growth factor (VEGF), particularly in diseases of the posterior eye segment such as ARMD (age related macular degeneration) and macular oedema in diabetic retinopathy. The best known anti-VEGF drugs

used to treat these pathologies are: pegaptanib sodium (Macugen), ranibizumab (Lucentis) and bevacizumab (Avastin).

When diabetes mellitus is diagnosed, in 5% of patients diabetic retinopathy is already present; with 80% incidence in insulin-dependent patients (diabetes mellitus type I) and 20% in insulin non-dependent diabetics (type II). Unfortunately, 50% of patients suffering from uncured proliferative diabetic retinopathy will become blind within 5 years starting from the first signs of diabetic retinopathy.

The impact of VEGF in the progress of diabetic retinopathy was first noted in 1994, when higher cytokine values in vitreous body of patients suffering from proliferative diabetic retinopathy¹³ have been recorded. Several recent studies have also suggested the impact of VEGF on ocular angiogenesis and progression of proliferative diabetic retinopathy^{13–15}. It is known from the literature that several other growth factors and cytokines apart from VEGF; such as interleukin-6, the insulin-similar growth factor and advanced AGEs, are also included in ocular angiogenesis.

However, there are no studies investigating the possible difference in vitreal VEGF levels depending on the type of diabetes (I and II). Therefore, we investigated whether vitreal VEGF values are higher in diabetic patients with PDR than in controls; and if there is any difference in VEGF level among diabetics with PDR suffering from diabetes type I or II. Our aim was to establish which diabetes type (or maybe both) would be theoretically more susceptible to anti-VEGF therapy.

The research was conducted within 2 years' period (2006–2008), during which 116 patients were subjected to vitrectomy surgery at our Department, out of which 36 diabetics with PDR were included into this study. Samples of vitreous were collected during surgery and VEGF (and its receptors) level was measured. Our results showed a significant increase of VEGF level in the vitreous body of all the patients with PDR in relation to the control group (63.26 pg/mL). This was particularly true with the group of patients suffering from diabetes mellitus type I (432.23 pg/mL), and slightly less (yet statistically significant!) with the group of patients with dia-

betes mellitus type I (147.53 pg/mL). Our results, therefore, indicate a substantial difference in VEGF production dependent on the type of diabetes that the patient suffers from. Increased levels of VEGF in vitreous of patients with PDR could be explained by presence of newly produced blood vessels, having more endothelial cells able to produce VEGF. Moreover in the newly produced blood vessels there are a higher number of circulating macrophages and monocytes which infiltrate the vitreous body and also produce VEGF. Thus, it is to be expected that formation of the first blood vessels will be followed by an incessant disease exacerbation (due to VEGF which induces ever-growing number of neo-vascularization) and that such a behavior could be suppressed by VEGF inhibition.

It is common knowledge that retinal pigmental epithelium produces VEGF¹⁶. Lately, the role of VEGF produced from monocytes and macrophagocytes infiltrating the vitreous body has been investigated, indicating their role in the progress of the proliferative diabetic retinopathy^{16–18}.

In the study¹⁹ where VEGF and erythropoietin levels in vitreous body have been measured on 73 patients with PDR and 71 patients with non-diabetic ocular pathology, the VEGF amount has been considerably higher with PDR patients (VEGF of 345.0 pg/mL – 363.9 pg/mL)¹⁹. The authors have found similar VEGF values as the ones in our study but they did not investigate the VEGF production related to the diabetes type, the feature that, according to our results, also affects the VEGF level. Their study has also revealed that the angiogenetic potential of erythropoietin (Epo) is equivalent to the VEGF in the vitreous body of the PDR-related patients¹⁹. Erythropoietin (Epo) is a glycoprotein with angiogenetic activity which stimulates proliferation, migration and angiogenesis *in vitro*.

Our research results have also revealed that in the vitreous body of PDR-related patients with diabetes mellitus type I significantly higher levels of VEGFR1 and VEGFR2 are present than in the vitreous body of the PDR-related patients with diabetes mellitus type II. These results suggest that PDR in diabetes mellitus type I is characterized by more prominent mitogenesis, angiogenesis and vascular permeability; therefore VEGF inhibition could potentially have stronger effect in PDR-patients with diabetes mellitus type I.

Similar as in our research, in the work of Akhiro Kakehashi et al, the measured VEGF level in the vitreous body and eye liquid of diabetic patients amounted to 695.7 pg/mL; considerably higher in respect to non-diabetics patients (25.9 pg/mL). The immuno-histological-chemical analysis of VEGF, VEGF receptors, AGEs and macrophagocytes in ocular tissues has revealed a considerably higher share of all three molecules in irises and neuro-vascular membranes of diabetic patients in respect to non-diabetics patients¹⁶.

Neovascular glaucoma is another complication in PDR patients, caused by iris rubeosis generated as the response to retinal ischemia²⁰. During our research period,

3 of our investigated patients with diabetic retinopathy developed neuro-vascular glaucoma. In these patients extremely high VEGF values have been recorded (from 777.100 pg/mL to 885.681 pg/mL); the fact that can be explained with reported data showing that apart from retinal pigment epithelium also the neuro-vascular membranes involved neuro-vascular glaucoma can produce VEGF. This phenomenon is further confirmed by the studies suggesting that VEGF and AGEs aggregation plays an essential role in development of retinal and iris neovascularization^{16–18}. The common therapy for neovascular glaucoma includes pan-retinal photocoagulation combined with medication and surgeries to suppress eye pressure²⁰, and our data point to a possible positive anti-VEGF therapy role in this disease.

Other authors have also reported an increased VEGF level in eye liquids and vitreous body in patients suffering from neovascular glaucoma^{20,21}. Anti-VEGF drugs can therefore lead to neovascular regression in the anterior eye segment, which was already confirmed in several studies which report rubeosis regression following the bevacizumab intra-vitreous application^{20,22–24}.

Considering the impact of diabetes mellitus stage on VEGF secretion, it has been established that VEGF tends to increase both in early and late stage of diabetic retinopathy^{16,25}. VEGF is attributed to induce leukocyte adhesion to retinal capillaries causing blood-retinal barrier damage and generating clinically visible bleeding in retina and vitreous body.

Epidemiology of Diabetes Intervention and Complications Study has reported that conventional four-year treatment tends to prevent diabetic retinopathy progression¹⁶. In the study the authors report that the findings of higher VEGF and AGEs levels in neovascular membranes, than the levels found in iris, speaks in favor of the fact that the retina is to be attributed to be the main VEGF source in diabetic eye. However, once the neovascular membranes are formed, interstitial tissue and macrophagocytes around the newly formed capillaries represents the main source and stimulus of VEGF production as seen with AMD related patients^{26,27}. The VEGF intra-ocular level obviously correlates essentially to formation of new blood vessels in the patients with diabetic retinopathy, but also to other retinal disorders where neovascularization is formed.

As previously mentioned, VEGF is the key factor for angiogenesis in numerous pathological eye neovascularizations, promotion of pathological inflammation, as well as endothelial dysfunction. Considering the results of our study, in which a significant increase of the vascular endothelial growth factor (VEGF) and its receptors was recorded in patients affected by diabetes mellitus (especially in those with DM type I), we believe that there is a possibility to improve the conditions of the aforementioned patients and to hasten their sight recovery by applying anti-VEGF therapy, be it by using the already known forms of such therapy, or by discovering new ways for blocking VEGFs (e.g. a soluble receptor which would competitively block the free VEGF).

REFERENCES

1. ALBERTI KG, Diabet Med, 15 (1998) 539. — 2. QUINN L, Nurs Clin North Am, 36 (2001) 175. — 3. AIELLO LP, GARDNER TW, KING GL, Diabetes Care, 21 (1998) 143. — 4. NEELY KA, QUILLEN DA, SCHACHAT AP, Med Clin North Am, 82 (1998) 847. — 5. KOHNER EM, SLEIGHTHOLM M, Ophthalmology, 93 (1986) 586. — 6. ANDERSON BJR, Ophthalmology, 87 (1980) 173. — 7. CUNHA-VAZ JG, Ophthalmologica, 214 (2000) 3777. — 8. DIABETES CONTROL AND COMPLICATIONS TRIAL RESEARCH GROUP, N Engl J Med, 329 (1993) 977. — 9. DE VRIESE AS, VERBEUREN TJ, VAN DE VOORDE J, Br J Pharmacol, 130 (2000) 963. — 10. GIUGLIANO D, CERIELLO A, PAOLISSO G, Diabetes Care, 19 (1996) 257. — 11. FERRIS FL III, DAVIS MD, AIELLO LM, N Engl J Med, 341 (1999) 667. — 12. EMLEN G, MALOTAUX JM, PONCHON M, Pharmacol Ther, 81 (1999) 37. — 13. OH H, SUZAMA K, OTANI A, J Biol Chem, (1999) 15732. — 14. JOUSSEN AM, POULAKI ML, KOIZUMI K, FASEB, 18 (2004) 1450. — 15. HOWARD F, FINE MD, JUDIT BAFFI MD, Am J Ophthalmol, 132 (2001) 794. — 16. DAVIDOFT HF, MOUSER JG, DERICK RJ, Retina, 26 (2006) 354. — 17. KAHOOK MY, SCHUMAN JS, NOECKER RJ, Ophthalmic Surg Lasers Imaging, 37 (2006) 144. — 18. MASON JO III, ALBERT MA JR, MAYS, 26 (2006) 839. — 19. MACKENSEN F, CARSTEN H, Retina, 28 (2008) 41. — 20. ADAMIS AP, MILLER JW, BERNAL MT, Am J Ophthalmol, 118 (1994) 445. — 21. CUNNINGHAM ETJR, ADAMIS AP, ALTAWHEEL M, 112 (2005) 1747. — 22. CHEN E, PARK CH, Retina, 26 (2006) 699. — 23. AIELLO LP, DAVIS MD, GIRACH A, 113 (2006) 2221. — 24. YANOFF M, FINE BS, BRUCKER AJ, 28 (1984) 505. — 25. VINOES SA, CHAN CC, VINOES MA, J Neuroimmunol, 89 (1998) 43. — 26. KONNER J, DUPONT J, Clin Colorectal Cancer, 4 (2004) 81. — 27. MILLER KD, CHAP LI, HOLMES FA, J Clin Oncol, 23 (2005) 792.

M. Merlak

*Department of Ophthalmology, University Hospital »Rijeka«, Krešimirova 42, 51000 Rijeka, Croatia
e-mail: maja.merlak@gmail.com*

EKSPRESIJA VASKULARNOG ENDOTELNOG FAKTORA RASTA U PROLIFERATIVNOJ DIJABETIČKOJ RETINOPATIJI

SAŽETAK

S obzirom da su vaskularizacija i vezivna proliferacija ključni faktori nastanka komplikacija u pacijenata sa PDR-om cilj ovog istraživanja bio je utvrditi postoji li povišenje VEGF-a u tih pacijenata i koliko ono ovisi o tipu dijabetesa. U ispitivanje je bilo uključeno 20 pacijenata sa DM tip I i 16 pacijenata sa DM tip II. Njima je za vrijeme operativnog zahvata vitrektomije uziman uzorak staklovine u kome je određivana količina VEGF-a i njegovih receptora (VEGFR1 i VEGFR2) ELISA testom. U staklovinama pacijenata sa PDR-om i dijabetes melitusom tipa I pronađena je značajno veća količina VEGF-a i njegovih receptora (432,2 pg/mL, 1460,4 pg/mL i 1054,6 pg/mL) nego u dijabetičara sa PDR-om i dijabetes melitusom tipa II (147,5 pg/mL, 641,4 pg/mL i 448,5 pg/mL) i u kontrolnoj skupini (63,26 pg/mL). Rezultati sugeriraju da primjena anti VEGF terapije ima smisla u dijabetičara sa PDR-om posebno u onih sa dijabetes melitusom tipa I.