

SINGLE INCISION LAPAROSCOPIC SURGERY (SILS) CHOLECYSTECTOMY: WHERE ARE WE?

Jakša Filipović Čugura¹, Josip Janković², Tomislav Kuliš³, Iva Kirac¹ and Miroslav Bekavac Bešlin¹

¹University Department of Surgery, Sestre milosrdnice University Hospital, Zagreb; ²Department of Surgery, Dr. Josip Benčević General Hospital, Slavonski Brod; ³University Department of Urology, Zagreb University Hospital Center, Zagreb, Croatia

SUMMARY – Laparoscopic cholecystectomy has become gold standard for cholecystectomy. The tendency of minimizing surgical trauma encourages the use of new approaches in laparoscopic surgery. Single incision laparoscopic surgery (SILS) cholecystectomy was first performed ten years ago; however, it is only recent technologic development that has enabled its wider acceptance. We report on a case of a 69-year-old female patient scheduled for elective laparoscopic cholecystectomy due to symptomatic ultrasonography verified cholelithiasis. A single 2.5-cm long semicircular supraumbilical skin incision was used. Pneumoperitoneum was established with the Veress access needle. Abdominal cavity was entered through three trocars: 10-mm trocar for camera and two 5-mm trocars, each placed 1 cm laterally and cranially from the 10-mm trocar. Antegrade cholecystectomy was performed without stay suture placement. Postoperative course was uneventful. The benefits of transition from standard laparoscopic approach to SILS will not be as obvious as was the transition from open to laparoscopic cholecystectomy. However, it cannot be overstated that every additional incision and trocar placement poses a risk of bleeding, organ damage and incisional hernia. SILS approach is feasible with standard and slightly modified instruments for standard laparoscopic cholecystectomy, thus posing minimal additional challenge to the laparoscopic surgeon. Accordingly, we believe that the use of this approach for cholecystectomy is worthwhile.

Key words: *Cholecystectomy – methods, Cholecystectomy, laparoscopic – methods; Case report*

Introduction

Recent advancement in surgical technology has enabled minimally invasive surgery to reduce the number and size of incisions, along with direct additional development into the natural-orifice transluminal endoscopic surgery (NOTES) and various forms of single-incision laparoscopic surgery (SILS). The advantages of minimally invasive surgery are reduced intraoperative stress and faster return to normal activities. Even though reduction from three to one incision does not strike as a clear benefit, indirect evidence for it is found in a study conducted by Bisgaard *et al.*¹, who report on lower one-

week morbidity in a group of patients submitted to laparoscopic cholecystectomy with downsized trocars. Based on these data, indications for procedures with modifications of standard laparoscopic approaches are broadening at experienced centers.

First experiences with SILS cholecystectomy were reported by Navarra *et al.*² in 1997 and with a different approach by Piskun and Rajpal in 1999³. Technical limitations postponed the full extent of its application until recently, when articulating and bent laparoscopic instruments and modified ports have become commercially available. There is a rising number of publications in the field. A number of procedures including cholecystectomy, appendectomy, urologic procedures, adrenalectomy, and bariatric procedures are currently being performed with this methodology. Our group has just been performing the first study with SILS totally extra-peritoneal (TEP) hernia repair. Although the early ex-

Correspondence to: *Josip Janković, MD*, Department of Surgery, Dr. Josip Benčević General Hospital, Ul. Andrije Štampara 42, HR-35000 Slavonski Brod, Croatia

E-mail: jjmrva@gmail.com

Received November 17, 2008, accepted December 1, 2008



Fig. 1. Position of trocars.

perience with SILS cholecystectomy is promising, additional studies are needed to develop a safe and effective technique to be able to compare it with laparoscopic cholecystectomy as the gold standard.

Case Report

A 69-year-old female patient with chronic cholecystitis and concrements in the gallbladder that were verified by ultrasound was scheduled for elective surgery. She had no significant comorbidities. The patient's body weight was 72 kg, height 160 cm and body mass index (BMI) 28 kg/m². The patient was placed and draped in standard manner. We made a single semicircular supraumbilical skin incision 2.5 cm long. After exposing the fascia, pneumoperitoneum was created with the Veress access needle. A 10-mm trocar was



Fig. 2. Intraoperative view.

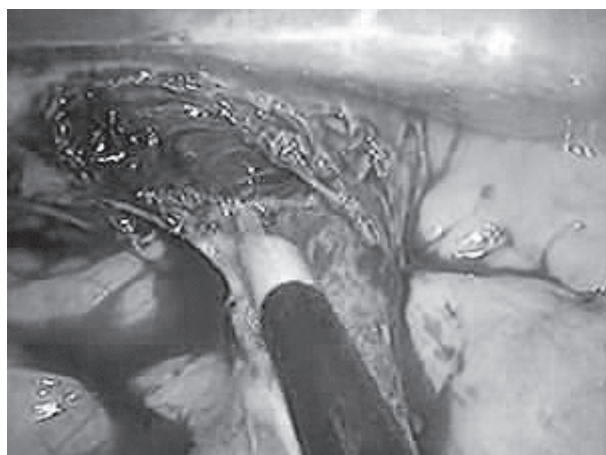


Fig. 3. Antegrade dissection.

then introduced and the abdominal cavity was explored with a 10-mm 30-degree camera. Two 5-mm trocars were then inserted into the abdominal cavity, each placed 1 cm laterally and cranially from the 10-mm trocar (Fig. 1). Since the operator usually performs laparoscopic cholecystectomy without retracting the cholecyst, there was no need for placing stay sutures. Antegrade cholecystectomy⁴ was performed (Figs. 2 and 3). The Calot triangle was exposed, all elements were identified, and cystic artery and cystic duct were clipped separately with a 5-mm clip applier. The gallbladder was emptied prior to removal and removed in an endobag through umbilical incision. The drain was inserted through the right 5-mm trocar (Fig. 4). The operation lasted 90 minutes. We used standard laparoscopic instruments, which proved to be technically demanding but feasible. Preoperatively, the patient received standard antibiotic



Fig. 4. Skin sutures and drain.

prophylaxis. Postoperative stay was uneventful. The drain was removed on the first postoperative day and the patient was discharged from the hospital 48 hours after the surgery.

Discussion

Laparoscopic cholecystectomy is the gold standard for cholecystectomy. At our institution, it has been performed since 1992 and over 6000 procedures have been carried out to the present. Apart from chronic cholecystitis and treatment of biliary pancreatitis and its complications⁵, acute cholecystitis is often solved by laparoscopic cholecystectomy. To our knowledge, SILS cholecystectomy has been performed twice before in Croatia, i.e. in Split (personal communication) and in Bjelovar⁶, however, their experience has not been published in the literature. We perceive this report as an attempt to introduce this approach outside laparoscopic surgery departments and to stimulate surgical centers in Croatia to share their new experiences not only *via* personal communication in order for all of us to systematically follow our work. Therefore, we hope that in the future we will have prospective multicenter trials on new methods instead of scarce case reports.

SILS cholecystectomy is a new step in minimally invasive surgery. The fact that laparoscopic cholecystectomy is currently the gold standard and is performed literally at almost every hospital worldwide, being considered safe and cost effective, should not prevent its further technical evolution. The benefit of transition from standard laparoscopic approach to SILS will not be as visible as it was for the transition from open to laparoscopic cholecystectomy. However, as stated in a study performed by Bisgaard *et al.*¹, further minimization is justified. It cannot be overstated that every incision and trocar placement poses a risk of bleeding, organ damage and incisional hernia. Moreover, since cosmetic effect is increasingly important to patients⁷, we should not neglect cosmetic improvement with SILS, especially when SILS is performed within umbilicus. The techniques of SILS cholecystectomy published to date^{2,3,8} used variations in stay suture placement. We believe that retrograde SILS cholecystectomy is feasible without them. Using SILS does not compromise patient safety since the placement and instruments used are the same or slightly modified in comparison to standard cholecystectomy. If necessary, conversion from SILS to standard cholecystectomy is possible at any point with-

out compromising patient safety or prolonging operative time. Triangulation has a status of dogma in laparoscopy. Adjacent placement of trocars in SILS or using multilumen ports definitely reduces triangulation, along with frequent crossing of instruments making this approach more demanding.

To conclude, the surgeon performing SILS has to be experienced in laparoscopy. Proper patient selection is also of great importance to reduce the rate of conversion until we acquire adequate experience. We used standard laparoscopic instruments and in spite of this being more demanding, there were no complications. In addition to standard laparoscopic instruments, articulating and bent instruments have now become commercially available. Our experience with reticulators was not so good because of the lack of firmness in grasping. Presently, we have only little experience with bent instruments, but hopefully a full range of modified instruments will be developed and ready for trial soon. This is ascertained by the very dynamic development of this field.

The increasing demands of patients for decision making requires popularization of the options currently available, along with due emphasis on the as yet questionable issues. This should not prevent us from answering our questions, which means that additional studies are needed to evaluate the applicability of SILS cholecystectomy.

References

1. BISGAARD T, KLARSKOV B, TRAP R, KEHLET H, ROSENBERG J. Microlaparoscopic vs conventional laparoscopic cholecystectomy: a prospective randomized double-blind trial. *Surg Endosc* 2002;16:458-64.
2. NAVARRA G, POZZA E, OCCHIONORELLI S, CARCOFORO P, DONINI I. One-wound laparoscopic cholecystectomy. *Br J Surg* 1997;84:695.
3. PISKUN G, RAJPAL S. Transumbilical laparoscopic cholecystectomy utilizes no incisions outside the umbilicus. *J Laparosc Adv Surg Tech A* 1999;9:361-4.
4. NERI V, AMBROSI A, FERSINI A, TARTAGLIA N, VALENTINO TP. Antegrade dissection in laparoscopic cholecystectomy. *JLS* 2007;11:225-8.
5. FILIPOVIC J, BEKAVAC-BESLIN M, VIROVIC L, SUPANC V, ZOVAK M, HRABAR D, DRUZIJANIC N. Minimally invasive treatment of causes and complications of biliary pancreatitis. *Hepatogastroenterology* 2005;52:1364-7.
6. DIKLIC D, LOVRIC J, KUCIC Z. Single port access (SPA) cholecystectomy, early experiences in Department of Surgery, General Hospital in Bjelovar. 9th Croatian Congress of Endoscopic Surgery, Osijek, October 9-11, 2008; p. 80.

7. DUNKER MS, STIGGELBOUT AM, Van HOGZAND RA, RINGERS J, GRIFFIOEN G, BEMELMAN WA. Cosmesis and body image after laparoscopic-assisted and open ileocolic resection for Crohn's disease. *Surg Endosc* 1998;12:1334-40.
8. TACCHINO R, GRECO F, MATERA D. Single-incision laparoscopic cholecystectomy: surgery without a visible scar. *Surg Endosc* 2008;Sep 25 (Epub ahead of print).

Sažetak

LAPAROSKOPSKA KOLECISTEKTOMIJA KROZ JEDAN REZ: GDJE SMO DANAS?

J. Filipović Čugura, J. Janković, T. Kuliš, I. Kirac i M. Bekavac Bešlin

Laparoskopska kolecistektomija je zlatni standard kod odstranjenja žučnog mjehura. Tendencija smanjivanja kirurške traume potiče primjenu novih pristupa u laparoskopskoj kirurgiji. Laparoskopska kolecistektomija kroz jedan rez je prvi puta primijenjena prije 10 godina, no tek je nedavno tehnološki napredak omogućio njeno prihvaćanje. Prikazujemo slučaj 69-godišnje bolesnice kojoj je indicirana kolecistektomija zbog simptomatske ultrazvučno dokazane kolelitijaze. Kroz polukružni rez kože iznad pupka dužine 2.5 centimetra uspostavljen je pneumoperitoneum Veressovom iglom te su u trbušnu šupljinu uvedena 3 troakara, 10-milimetarski za kameru te 2 radna troakara od 5 mm svaki 1 centimetar iznad i lateralno od prvog. Metodom SILS (*single incision laparoscopic surgery*) učinjena je anterogradna kolecistektomija bez postavljanja podupirućih šavova. Poslijeoperacijski tijek je protekao uredno. Prednost prelaska sa standardne laparoskopske kolecistektomije na SILS kolecistektomiju ne donosi toliko drastične prednosti u odnosu na prijelaz s klasičnog otvorenog pristupa na laparoskopski. Ipak, nikada nije dovoljno naglašavati kako svaki dodatni rez ili troakar sa sobom donosi dodatni rizik od krvarenja, oštećenja organa te incizijske hernije. Pristup SILS je izvediv pomoću standardnih i minimalno modificiranih laparoskopskih instrumenata, što postavlja tek neznatan dodatni izazov za laparoskopskog kirurga. Zbog svega navedenog smatramo da je primjena ovoga pristupa opravdana.

Ključne riječi: *Kolecistektomija – metode, Kolecistektomija, laparoskopska – metode; Prikaz slučaja*