

FIRST CASE OF SINGLE INCISION LAPAROSCOPIC SURGERY FOR TOTALLY EXTRAPERITONEAL INGUINAL HERNIA REPAIR

Jakša Filipović Čugura¹, Iva Kirac¹, Tomislav Kuliš², Josip Janković³ and Miroslav Bekavac Bešlin¹

¹University Department of Surgery, Sestre milosrdnice University Hospital; ²University Department of Urology, Zagreb University Hospital Center, Zagreb; ³Department of Surgery, Dr. Josip Benčević General Hospital, Slavonski Brod, Croatia

SUMMARY – Laparoscopic approach to inguinal hernia repair is indicated for recurrent and bilateral hernias or as patient choice in unilateral primary hernias. Totally extraperitoneal (TEP) approach has some advantages over transabdominal preperitoneal (TAPP) approach, but has proved to be more technically demanding. It cannot be emphasized enough that every incision and trocar placement poses a risk of bleeding, organ damage, incisional hernia and less favorable cosmetic effect. Single incision laparoscopic (SILS) TEP hernia repair has reduced the number of incisions to minimum. A 60-year-old male patient presented with unilateral right sided primary indirect inguinal hernia. Laparoscopic SILS TEP repair was performed: a single 2.5-cm infraumbilical incision was made, the anterior rectus sheath was incised and a balloon dissection device was inserted over the posterior rectus sheath, guided to the pubic symphysis and inflated, resulting in separation of the peritoneum from the rectus muscle. This creation of the extraperitoneal space allowed for laparoscopic dissection to take place. We used a 10-mm optical trocar and two 5-mm trocars placed 1 cm laterally from the optical port. The operation was free from complications and the operative time was 90 minutes. Postoperative recovery was uneventful. We report on, to our knowledge, the first case of SILS TEP hernia repair. Based on this experience, we believe that SILS TEP is feasible. Adjacent placement of trocars in SILS reduces triangulation which, along with frequent crossing of instruments, renders this approach more demanding. Cosmetic benefit is clear; however, it remains to evaluate patient recovery, postoperative pain and complications in comparison to standard TEP.

Key words: *Laparoscopy – methods; Hernia, inguinal – surgery; Case Report*

Introduction

Laparoscopic surgery has always been focused on minimization of surgical trauma and improvement of cosmetic effect. It should be stressed that laparoscopy has proved to be comparable to open surgery in the management of both benign and malignant diseases. Presently, there are two main directions which strive to augment the previously mentioned advantages: natural-orifice transluminal endoscopic surgery (NOTES) and single incision laparoscopic surgery (SILS).

Correspondence to: *Iva Kirac, MD*, University Department of Surgery, Sestre milosrdnice University Hospital, Vinogradska c. 29, HR-10000 Zagreb, Croatia

E-mail: ikirac@kbsm.hr

Received November 17, 2008, accepted December 1, 2008

Operations eligible for NOTES approach are determined by the availability of entry point or hollow organ, availability of endoscopic instruments and occasional necessity for hybrid or laparoscopic assistance. SILS, on the other hand, enables application of a wide range of already existing instruments implying lesser learning curve, lower costs as well as the lack of necessity for penetration through the hollow organ, which in itself carries certain complications. In both approaches, a reduced number of incisions aim at decreasing the morbidity of bleeding, incisional hernia and organ damage, and at improvement of the cosmetic result.

SILS laparoscopic appendectomy¹ and cholecystectomy² were first described in 1998, and were recognized again by Hirano *et al.* in 2005, when they used this ap-

proach in urology³. It was followed by SILS cholecystectomy and its application in obesity surgery^{4,5}. This break could be explained by technical support, which was insufficient until recently. Instruments enabling this renewed interest have now become commercially available, such as trocars modified for adjacent placement, special multilumen ports that allow for simultaneous multiple instrument insertion⁶, gelports⁷, articulating and bent instruments as well as adjusted laparoscopes.

There are, however, procedures in which laparoscopic approach remains a matter of debate despite all previous arguments, such as inguinal hernia repair. In experienced laparoscopic centers, there is a tendency of implementation of new technology in order to improve this procedure.

Case Report

A 60-year-old male patient presented with unilateral right sided primary indirect inguinal hernia. Laparoscopic SILS totally extraperitoneal (TEP) repair was performed under general anesthesia. Standard antibiotic prophylaxis was administered. The patient was placed in supine position with a 10° to 15° Trendelenburg tilt and with the arms resting against the body. A single 2.5-cm infraumbilical incision was made (Fig. 1), the anterior rectus sheath was incised and a balloon dissection device was inserted over the posterior rectus sheath, guided to the pubic symphysis and inflated, resulting in separation of the peritoneum from the rectus muscle. This creation of the extraperitoneal space allowed for laparoscopic dissection to take place. Then the bal-

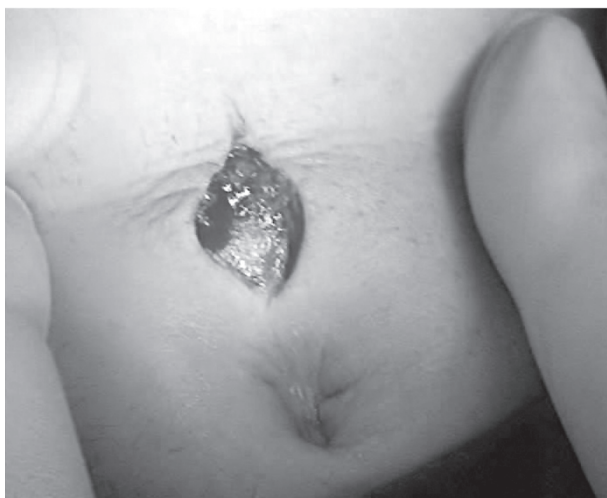

Fig. 1. Infraumbilical skin incision.

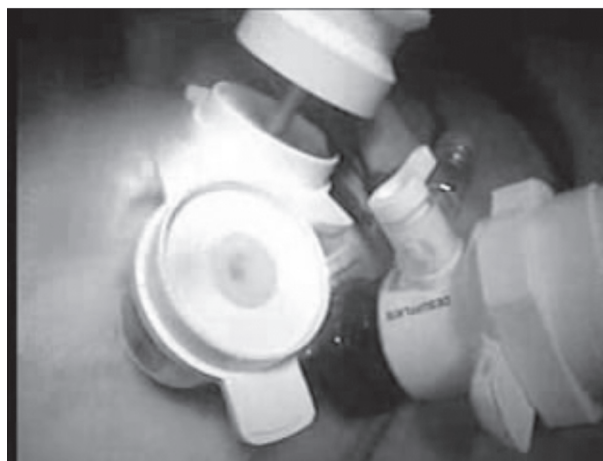

Fig. 2. Port placement.

loon device was removed and replaced with a 10-mm blunt-tip trocar for camera. Carbon dioxide was insufflated to a pressure not exceeding 12 mm Hg. Two 5-mm ports were inserted through the anterior sheath of the abdominal rectus muscle into now existing preperitoneal space, each placed 1 cm laterally from the laparoscope port (Fig. 2). The first step was to identify the key anatomic landmarks such as the pubic bone, Cooper's ligament, spermatic cord, inferior epigastric vessels running superiorly, and the type of hernia (direct hernia medially and indirect hernia laterally to the inferior epigastric vessels). The next step was to reduce the hernia sac from the inguinal wall (Fig. 3). The indirect hernia sac was reduced and separated from the spermatic cord. After the entire posterior floor had been dissected, double mesh was placed as previously described⁸(Fig.

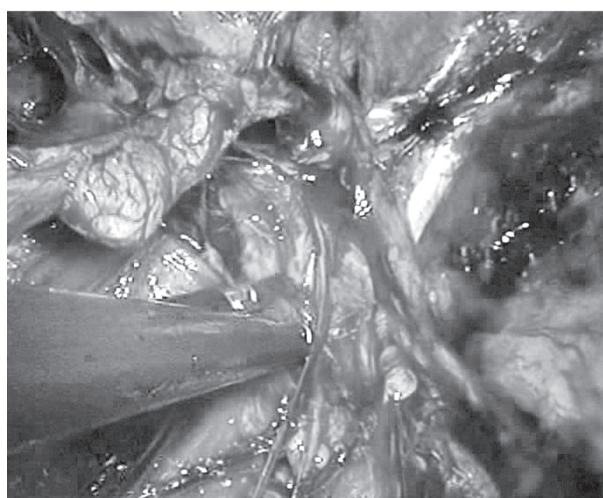


Fig. 3. Reposition of indirect hernia.



Fig. 4. Second MESH after placement.

4). The operation proceeded without complications and the operative time was 90 minutes. Postoperative recovery was uneventful. The patient was discharged after 48 hours.

Discussion

The ideal technique for effective inguinal hernia repair is still controversial. The benefits of laparoscopic technique over open technique have been reported for postoperative pain, discomfort and earlier return to work⁹⁻¹¹. Laparoscopically, meshes can be placed with two approaches either using transabdominal preperitoneal (TAPP) or route.

TAPP was associated with higher rates of port-site hernias and visceral injuries whilst there appear to be more conversions with TEP. Vascular injuries and deep/mesh infections were rare and there was no obvious difference between the groups. No studies reporting economic evidence were identified. Very limited data are available on learning effects but these data suggest that operators became experienced after having performed 30 to 100 procedures. However, based on the Cochrane 2005 systematic review¹², there are too little data to support either unanimously.

We opted for TEP for no entry into abdominal cavity is necessary, thus avoiding potential injury to intra-abdominal organs and structures. This approach is considered technically more demanding but since 1996, when we started using this technique, we have performed more than 1000 procedures without major complications. Presently, indications are bilateral and recurrent inguinal hernia¹⁵ and patient choice in case of primary hernia.

Our standard approach is a three-port access and single or double MESH placement after appropriate reposition and field preparation.

Even though reduction from three to one incision does not strike as a clear benefit, indirect evidence for it is found in a study carried out by Bisgaard *et al.*¹⁴, who report on lower morbidity in the group of patients undergoing laparoscopic cholecystectomy with downsized trocars in the first week. Based on such data, at experienced centers indications for procedures with modifications of standard laparoscopic approaches are broadening. To our knowledge, we report on the first case of SILS TEP hernia repair. Based on this experience, we believe that SILS TEP is feasible. Adjacent placement of trocars in SILS or using multilumen ports definitely reduces triangulation which, along with frequent crossing of instruments, renders this approach more demanding. Cosmetic benefit is noticeable; however, it remains to evaluate patient recovery, and reduction of postoperative pain and complications in comparison to standard TEP. Therefore, additional studies are expected to answer these issues.

References

1. ESPOSITO C. One-trocar appendectomy in pediatric surgery. *Surg Endosc* 1998;12:177-8.
2. PISKUN G, RAJPAL S. Transumbilical laparoscopic cholecystectomy utilizes no incisions outside the umbilicus. *J Laparoendosc Adv Surg Tech A* 1999;9:361-4.
3. HIRANO D, MINEI S, YAMAGUCHI K, YOSHIKAWA T, HACHIYA T, YOSHIDA T, ISHIDA H, TAKIMOTO Y, SAITOH T, KIYOTAKI S, OKADA K. Retroperitoneoscopic adrenalectomy for adrenal tumors *via* a single large port. *J Endourol* 2005;19:788-92.
4. TACCHINO R, GRECO F, MATERA D. Single-incision laparoscopic cholecystectomy: surgery without a visible scar. *Surg Endosc* 2008;Sep 25 (Epub ahead of print).
5. NGUYEN NT, HINOJOSA MW, SMITH BR, REAVIS KM. Single laparoscopic incision transabdominal (SLIT) surgery-adjustable gastric banding: a novel minimally invasive surgical approach. *Obes Surg* 2008;18:1492-4.
6. ROMANELLI JR, MARK L, OMOTOSHO PA. Single port laparoscopic cholecystectomy with the TriPort system: a case report. *Surg Innov* 2008;15:223-8.
7. PONSKY LE, CHERULLO EE, SAWYER M, HARTKE D. Single access site laparoscopic radical nephrectomy: initial clinical experience. *J Endourol* 2008;22:663-6.
8. GLAVAN E, MIJIC A, BEKAVAC-BESLIN M, FRANJIC DB, JURISIC D. Endoscopic extraperitoneal inguinal hernia repair with double mesh: indications, technique, complications, and results. *J Laparoendosc Adv Surg Tech A* 2005;15:586-90.

9. GRANT AM. Laparoscopic *versus* open groin hernia repair: meta-analysis of randomised trials based on individual patient data. *Hernia* 2002;6:2-10.
10. The MRC Laparoscopic Groin Hernia Trial Group. Laparoscopic *versus* open repair of groin hernia: a randomised comparison. *Lancet* 1999;354:185-90.
11. DOUEK M, SMITH G, OSHOWO A, STOKER DL, WELLWOOD JM. Prospective randomised controlled trial of laparoscopic *versus* open inguinal hernia mesh repair: five year follow up. *BMJ* 2003;326:1012-3.
12. WAKE BL, McCORMACK K, FRASER C, VALE L, PEREZ J, GRANT AM. Transabdominal pre-peritoneal (TAPP) *vs* totally extraperitoneal (TEP) laparoscopic techniques for inguinal hernia repair. *Cochrane Database Syst Rev* 2005:CD004703.
13. WATKIN D. Why does NICE not recommend laparoscopic herniorrhaphy? Patients must consider potential serious complications. *BMJ* 2002;325:339.
14. BISGAARD T, KLARSKOV B, TRAP R, KEHLET H, ROSENBERG J. Microlaparoscopic *vs* conventional laparoscopic cholecystectomy: a prospective randomized double-blind trial. *Surg Endosc* 2002;16:458-64.

Sažetak

PRVI SLUČAJ LAPAROSKOPSKE OPERACIJE KROZ JEDAN REZ ZA POTPUNO EKSTRAPERITONEJSKU PLASTIKU INGVINALNE HERNIJE

J. Filipović Čugura, I. Kirac, T. Kuliš, J. Janković i M. Bekavac Bešlin

Laparoskopski pristup plastici ingvinalne hernije je indiciran za rekurentne i obostrane hernije te kao bolesnikov izbor kod jednostranih primarnih hernija. Potpuno ekstrapertonejski pristup (*totally extraperitoneal*, TEP) je pokazao neke prednosti u odnosu na transabdominalni predperitonejski pristup (*transabdominal preperitoneal*, TAPP), ali se smatra tehnički zahtjevnijim. Nikada nije dovoljno naglašavati kako svaki dodatni rez ili troakar donosi dodatni rizik od krvarenja, oštećenja organa, incizijske hernije te smanjuje kozmetički učinak. TEP plastika hernije kroz jedan rez smanjuje ove rizike na najmanju mjeru. Šezdesetgodišnji bolesnik je primljen zbog jednostrane primarne indirektno hernije. Izvedena je laparoskopska operacija kroz jedan rez (*single incision laparoscopic surgery*, SILS) za TEP plastiku ingvinalne hernije: kroz jedan rez od 2,5 cm, kroz inciziju prednje fascije rektusa uveden je balon koji se po stražnjoj fasciji spustio do pubične simfize i insuflirao, čime se odvojio peritoneum od mišića rektusa. Nastanak predperitonejskog prostora omogućio je daljnju disekciju. Rabili smo 10-mm optički troakar te dva radna troakara od 5 mm koji su postavljeni 1 cm lateralno i kranijalno u odnosu na optički troakar. Operacija je prošla bez komplikacija. Poslijeoperacijski tijek je bio uredan. U ovom izvješću prikazujemo prvi slučaj zahvata SILS TEP. Prema našem iskustvu pristup je izvediv. Triangulacija je smanjena, što uz križanje instrumenata čini zahvat zahtjevnijim. Unatoč jasnom kozmetičkom rezultatu potrebno je procijeniti oporavak, poslijeoperacijsku bol te komplikacije u odnosu na standardni TEP.

Ključne riječi: *Laparoskopija – metode; Hernia, ingvinalna – kirurgija; Prikaz slučaja*