

Unusual Presentation of Anaplastic Large Cell Lymphoma with Clinical Course Mimicking Fever of Unknown Origin and Sepsis: Autopsy Study of Five Cases

Marina B. Mosunjac, J. Bruce Sundstrom, Mario I. Mosunjac

Department of Pathology and Laboratory Medicine, Emory University School of Medicine, Atlanta, Ga, USA

Aim To describe a subset of cases with the unusual clinical and histomorphological presentation of anaplastic large cell lymphoma (ALCL) mimicking fever of unknown origin (FUO) and sepsis.

Methods A pathology database was searched using full term Systematized Nomenclature of Medicine codes for ALCL to identify 23 ALCL cases from the period 1999-2006. Of those, five cases that did not have a correct premortem diagnosis were further analyzed to elucidate the reasons for delayed and incorrect pre-mortem diagnosis. The analyzed data included clinical presentation, duration of symptoms, duration of hospital stay, premortem presumed cause of death, white blood cell count, platelet count, anion gap and blood pH, liver enzymes (alanine aminotransferase, aspartate aminotransferase, lactate dehydrogenase, alkaline phosphatase), lactate, coagulation tests (prothrombin time, partial thromboplastin time, fibrinogen, D-dimers), microbiology cultures, and radiology and surgical pathology reports. Autopsy reports were reviewed for description of major gross findings, initial clinical diagnosis, and cause of death.

Results Five fatal and pre-mortem unrecognized ALCL cases were characterized by rapid decline, with histologic findings showing predominantly extranodal involvement, intravascular lymphomatosis, and hemophagocytosis. The cases were also characterized by unusual clinical manifestations including a FUO, sepsis, and disseminated intravascular coagulation-like picture, lactic acidosis, hepatosplenomegaly, and absence of significant peripheral adenopathy.

Conclusions There is a distinct group of ALCLs with unique and specific clinical, gross autopsy, and histopathologic findings. Recognition of this clinical variant may facilitate early detection and potentially timely diagnosis and therapy.

> **Correspondence to:**

Marina B. Mosunjac
Department of Pathology and Laboratory Medicine
Emory University School of Medicine
Room CG 42
Atlanta, GA 30303
mmosunj@emory.edu

> **Received:** January 17, 2008

> **Accepted:** July 23, 2008

> **Croat Med J. 2008;49:660-8**

> doi: 10.3325/cmj.2008.5.660

Anaplastic large cell lymphoma (ALCL) represents a fairly well-characterized group of T-cell lymphomas. In the current World Health Organization (WHO) classification, ALCL represents a unique diagnostic subcategory and comprises approximately 3% of adult and 10%-30% of childhood non-Hodgkin's lymphomas (1).

Defining features of ALCL include proliferation of predominantly large lymphoid cells with a characteristic growth pattern and strong expression of CD30. There are several histomorphological variants of ALCL including common type, monomorphic variant, lymphohistiocytic variant, small cell variant, mixed cell variant, giant cell variant, and sarcomatoid subtype (1). There are also three groups of ALCL according to molecular and clinical criteria as follows: primary systemic anaplastic lymphoma kinase protein (ALK)-positive anaplastic lymphoma, ALK-negative primary systemic anaplastic lymphoma, and primary cutaneous anaplastic lymphoma. ALK expression is caused by chromosomal translocation, most commonly t (2;5) (2,3). Most ALCLs in children and young adults express ALK protein and show favorable prognosis, while ALK-negative ALCLs are more heterogeneous and have a poor prognosis (4).

The classification of ALK-negative ALCLs is somewhat controversial. However, current genetic and biological research provides evidence that ALK-negative ALCLs are closely related to their ALK-positive counterparts (5).

Unusual clinical presentations including fever, liver failure, shock, oliguria, and adrenal insufficiency can be associated with all subtypes of ALCL, particularly in cases with the extranodal involvement (6-9). With such diverse and heterogeneous clinical presentation, correct clinical diagnosis is often difficult to establish and, thus, sometimes considerably delayed.

In this study, we characterized a distinct group of ALCL with unique and specific clinical, gross autopsy, and histopathologic findings. The clinical findings in these cases are different than previously described, and recognition of this clinical variant may facilitate early detection and potentially timely diagnosis and therapy.

Methods

The autopsy database at the Department of Pathology at Emory University was searched using Systematized Nomenclature of Medicine codes for all cases of ALCL from the period 1999-2006. A total of 23 cases that satisfied the strict cytomorphologic criteria and immunohistochemical staining pattern to confirm the diagnosis of ALCL were identified. Of those 23 cases, five cases did not have a correct pre-mortem diagnosis and were autopsied to determine the immediate cause of death and underlying disease process.

Cytomorphology and immunohistochemistry

The major cytomorphologic criteria include predominance of large cells with wrath-like nuclei, abundant eosinophilic cytoplasm, prominent pleomorphism, strong CD30 and clusterin expression in the cell membrane and Golgi in virtually each cell (2). Additional immunohistochemical stains were performed to exclude other types of lymphoma, primarily Hodgkin's lymphoma, ALK-1-positive B-cell lymphomas, and peripheral T-cell lymphomas.

The antibodies used included CD45RO, CD45RA, CD30, ALK-1, EMA, CD20, CD79a, CD43, CD3, CD2, CD4, CD43, CD15, PAX5, CD25, CD56, CD138, (DAKO Corporation, Carpinteria, CA, USA) and clusterin (Upstate Biotechnology, Lake Placid, NY, USA). Stains were performed on 5- μ m sections of formalin-fixed, paraffin-embedded tissues with the use of the

standard avidin-biotin-complex technique on automated DAKO Autostainer (DAKO) with appropriate positive and negative controls (10).

In-situ hybridization with Epstein-Barr virus (EBV) encoded small RNA (EBER) oligonucleotides was performed to test for the presence of EBV small RNA on formalin-fixed paraffin-embedded sections using DAKO automated stainer.

All hematoxylin and eosin and immunohistochemically stained slides were reviewed by two pathologists.

Clinical and laboratory data

Clinical and laboratory data were obtained from patients' charts. Antemortem clinical data included clinical presentation, duration of symptoms, duration of hospital stay, radiology and surgical pathology reports, and antemortem presumed cause of death. Antemortem laboratory data included white blood cell count, platelet count, anion gap and blood pH, liver enzymes (alanine aminotransferase, aspartate aminotransferase, lactate dehydrogenase, alkaline phosphatase), lactate, coagulation tests (prothrombin time, partial thromboplastin time, fibrinogen, D-dimers), and microbiology cultures.

Autopsy reports were reviewed for description of major gross findings, initial clinical diagnosis, and cause of death.

Results

Of 23 cases of ALCL identified by Systematized Nomenclature of Medicine database search, five were further studied.

Of five cases, there were two male and three female patients, ranging in age from 9 to 77 years (Table 1). All five patients presented with fever of unknown origin (FUO). Other symptoms on admission were nonspecific pain, cough, shortness of breath, fatigue,

malaise, and night sweats. In case 5, a primary symptom was waxing and waning skin rash with recurrent epistaxis, while case 4 (a 9-year-old boy) presented with asthma-like symptoms. Duration of symptoms varied from one week to three months (Table 1).

Autopsies were performed in all cases due to the unexplained cause of death. Clinical causes of death stated on autopsy request forms were mostly nonspecific and included wide variety of mostly generalized diagnoses such as respiratory, renal, or liver failure, intracerebral hemorrhage, status asthmaticus, and malignancy. Systemic involvement by lymphoma was not clinically suspected in any case. Sepsis, FUO, and a disseminated intravascular coagulation (DIC)-like picture dominated in majority of cases. Case 5 had previously diagnosed cutaneous ALCL; however, systemic spread was not suspected clinically and was overridden by the overwhelming septic picture (Table 1). In case 1, there was a pending report on the fine needle aspiration of the axillary lymph node and a bone marrow biopsy at the time of the autopsy. A diagnosis of ALCL was reached on both of those specimens; however, reports were issued after completion of the autopsy.

Laboratory data

The most common laboratory findings at admission were increased white blood cell count ($6.2-62 \times 10^3/\mu\text{L}$ white blood cells) with neutrophilia and left shift, thrombocytopenia ($26-108 \times 10^3/\mu\text{L}$ platelets), and abnormal coagulation tests suggesting DIC (in 4 of 5 patients). Lactic acidosis with increased anion gap was seen in four of five cases. Abnormal levels of liver enzymes (alanine aminotransferase, aspartate aminotransferase, and alkaline phosphatase) were also seen in four cases associated with microscopic and/or gross liver involvement. Routine microbiology cultures were negative in all but one patient (case 5)

Table 1. Demographic and clinical characteristics of patients diagnosed postmortem with anaplastic large cell lymphoma with fever of unknown origin as the most common clinical presentation and sepsis as the most common pre-mortem diagnosis*

Case No.	age/sex/race	Characteristics			clinical pre-mortem diagnosis
		clinical presentation	duration of symptoms prior to hospitalization	duration of hospital stay (days)	
1	33/male/white	FUO, back pain, dry cough	3 mo	6	sepsis, DIC, cranial hemorrhage
2	48/female/white	FUO, hepatic failure, DIC, food poisoning	1 mo	2	acute liver failure, DIC
3	77/female/white	FUO, abdominal pain, sepsis, dyspnea/ confusion, St/post CABG	1 week	5	sepsis
4	9/male/black	FUO, malaise, cough	2 weeks	6	asthma, sepsis
5	45/female/hispanic	FUO, SOB, sepsis, epistaxis, skin rash	1 mo	11	DIC, sepsis, malignancy

*Abbreviations: FUO – fever of unknown origin; DIC – disseminated intravascular coagulation; St/post CABG – previous surgery site coronary artery bypass graft; SOB – shortness of breath.

Table 2. Laboratory data of five patients with anaplastic large cell lymphoma at admission showing septic-like findings with neutrophilia, thrombocytopenia, abnormal coagulation tests suggesting disseminated intravascular coagulation, lactic acidosis with increased anion gap, and abnormal liver enzymes. Microbiology cultures were negative in all but one patient with *Staphylococcus aureus* identified in urine*

Case No.	Laboratory data							
	White blood cell count (10 ³ /µL)	Platelet count (10 ³ /µL)	Aspartate aminotransferase/alanine aminotransferase (U/L)	Alkaline phosphatase (U/L)	Ph/anion gap/mEq/L	Lactate (mmol/L)	PT (s)/PTT(s)/fibrinogen (mg/dL)/D-Dimer (ng/mL)	Microbiology
1	18.4	26	152/25	192	7.06/30	11.1	19/39/621	negative
2	14.7	53	1791/327	868	-/15	6.19	28/91/117/9883	negative
3	32.0	108	42/14	116	-/19	4.2	15.4/29.5	negative
4	62.0	504	-	-	7.19/26	-	-	negative
5	6.2	51	29/22	73	-/20	6.7	12/19.6/558	urine: coagulase-negative staphylococcus
Reference range	(3.6-11.1)	(150-400)	(7-40/17-63)	(30-110)	(7.34-7.45 /5-20)	(0.5-2.20)	(11-14/24-39/250-450)	

*Abbreviations: PT – prothrombin time, PTT – partial thromboplastin time.

Table 3. Gross pattern of tissue and organ involvement by anaplastic large cell lymphoma in five patients*

Case No.	Gross pattern of involvement by lymphoma			
	Nodal involvement	Extranodal involvement	Hemophagocytosis	Intravascular spread
1	mediastinal, hilar, retroperitoneal	liver: 3700 g; spleen: 1110 g; bone marrow; thyroid; small bowel	-	+
2	small retroperitoneal	bone marrow; liver: 1759 g; gallbladder; large bowel; lungs; urinary bladder	+	+
3	small retroperitoneal, mediastinal	epicardial nodules; right adrenal gland	-	+
4	hilar, mediastinal, abdominal	anterior mediastinal mass; esophageal submucosa; lung (left lower lobe); colonic submucosa	+	+
5	none	skin; liver: 3660 g; spleen: 900 g; lung; kidneys	-	+

*The most common extranodal sites of involvement were the liver, lung, and bowel followed by the spleen, mediastinum, and bone marrow.

in whom *Staphylococcus aureus* was identified in the urine. Numerous other serological and polymerase chain reaction microbiology tests were performed on several patients including Legionella, Cryptococcus, acid fast bacilli, cytomegalovirus, and hepatitis test, and were all negative (Table 2). All patients tested negative for human immunodeficiency virus and only two patients were tested for Human T-lymphotrophic virus 1 and 2, and both had negative results. Extensive toxicology workup was negative in case 2, which presented as acute liver failure with no masses and presumed food poisoning.

Imaging studies

Only patient 3 had chest findings on computer tomography, showing a large pre- and retrosternal mass that was thought to represent malignancy or scar tissue at the previous coronary artery bypass grafting surgery site.

In other cases, minor findings such as small (1 cm in diameter) para-aortic lymph nodes (case 1) and edema of the gallbladder (case 2) were identified (Table 3).

Gross autopsy findings

In our study, ALCL in all of the cases presented predominantly as extranodal disease. In ad-

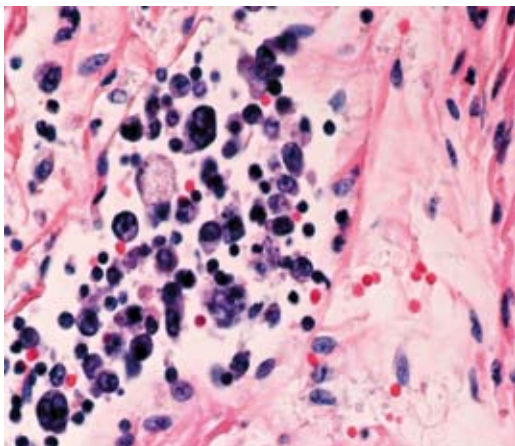


Figure 1. Vessel distended by numerous large lymphoma cells (hematoxylin and eosin, $\times 600$).

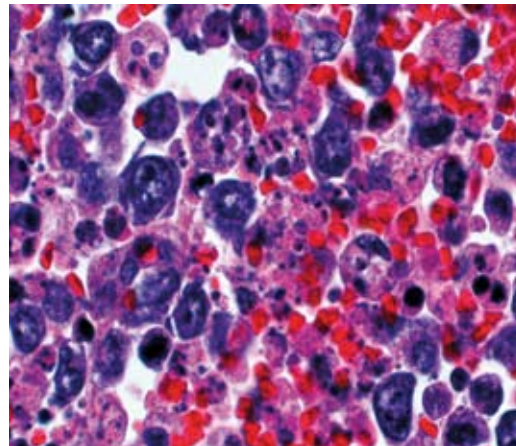


Figure 3. Hemophagocytosis showing red blood cells engulfed by histiocytes surrounded by large lymphoma cells (hematoxylin and eosin, $\times 600$).

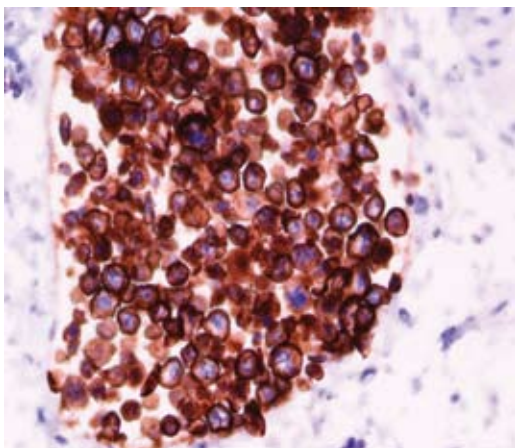


Figure 2. Strong and diffuse cytoplasmic and membranous CD30 expression in anaplastic large cell lymphoma cells showing intravascular spread (CD30, $\times 600$).

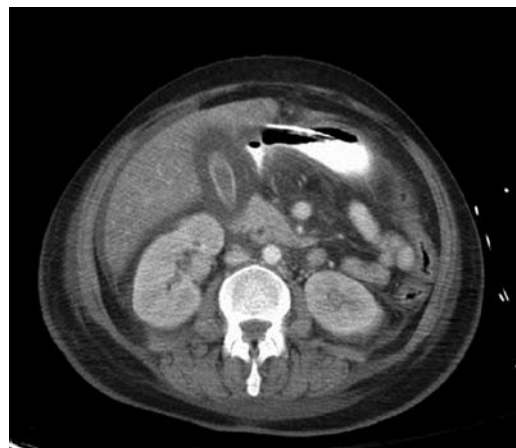

Figure 4. Computed tomography scan of the abdomen showing non-specific gallbladder edema, enlarged liver, and slightly enlarged retroperitoneal lymph nodes.

dition to extranodal sites, four of five patients had involvement of the lymph nodes (Table 3). Only one case showed enlargement of easily accessible peripheral lymph nodes within the axilla, while the other four cases presented with slight enlargement of deep-seated retroperitoneal, mediastinal, and abdominal lymph nodes.

Two cases showed extranodal mediastinal involvement, while three cases showed involvement of the mediastinal lymph nodes. The most common extranodal sites of involvement were the liver (in three cases), lungs (in

three cases), bowel (in three cases), spleen (in two cases), mediastinum (in two cases), and bone marrow (in two cases). Less common sites included single cases involving the heart, kidney, adrenal gland, urinary bladder, and gallbladder.

Two general gross patterns of extranodal involvement were identified. The first pattern was a distinct, dominant gross tumor mass. The second pattern was diffuse microscopic involvement with no distinct masses on gross examination. Cases with massive hepatosplenomegaly showed diffuse changes in the liver,

with microscopic expansion of portal tracts and sinusoidal spaces by lymphoma cells, and diffuse multiple infarctions of splenic parenchyma. The largest and most impressive gross finding was a mediastinal mass in case 3, measuring 5 cm in diameter. Lung involvement ranged from diffuse microscopic foci (case 2) and small subpleural nodules (case 5) to larger solid parenchymal masses (case 4).

Diffuse microscopic involvement was demonstrated as submucosal clusters of malignant cells in hollow organs such as the gallbladder, urinary bladder, esophagus, and bowel. Interstitial/parenchymal microscopic involvement was seen in solid organs such as kidneys, lungs, the thyroid, and pancreas. Distinct intravascular spread of lymphoma was observed in all cases (Figures 1 and 2). In two cases, hemophagocytosis was observed in the bone marrow and lymph nodes (Figure 3). In addition, case 2 had no solid gross lesions or significantly enlarged lymph nodes, with only abnormal imaging findings demonstrating thickened gallbladder wall (Figure 4). This prompted extensive tissue sampling during the autopsy, followed by meticulous examination to identify focal and microscopic disease.

Microscopic and immunohistochemical findings

All five patients were diagnosed according to strict morphological and immunophenotypic WHO criteria for ALCL (1). All patients showed morphological features of common variant with pleomorphic embryo or hallmark nuclei, wreath-like giant cells, strong CD30 and clusterin expression with a membrane, and Golgi distribution in majority of cells and characteristic perinuclear eosinophilic region (2).

All cases were strongly positive for CD30 and clusterin and negative for B-cell markers (CD20, PAX-5, CD79a), CD15, CD4, CD3, and CD138. All but case 1 were ALK-negative. EMA and CD43 were positive in three

cases. CD45RO and CD45RA were expressed in two and one of five cases, respectively. Only case 5 showed expression of CD56. All five cases were strongly positive for CD25.

Distinct intravascular spread of lymphoma cells was observed in all five cases. In two cases, hemophagocytic syndrome was identified in the bone marrow and lymph nodes.

Only case 5 showed evidence of EBV by EBER in situ hybridization.

Discussion

Most of Hodgkin and non-Hodgkin lymphomas present diagnostic difficulties, but are typically diagnosed prior to autopsy. The role of autopsy in these cases is to identify the immediate cause of death and common complications, such as the extent and type of fungal infection (11-14). Classic symptoms, including weight loss and night sweats, combined with enlarged and easily accessible peripheral lymph nodes, usually result in an early and correct diagnosis. As seen in our series, 18 of 23 cases of ALCL were diagnosed accurately and timely due to relatively classic presentation and accessible lymph nodes or superficial masses amenable to excisional biopsy. The remaining five cases of ALCL remained clinically unrecognized. The majority of our patients initially presented with a relatively uniform clinical picture including FUO, high white blood cell counts, decreased platelet counts, and a DIC-like picture. Such clinical presentations naturally prompted extensive and mostly negative microbiology and serology tests in search for a cause(s) of presumed infection and/or sepsis. Sepsis-like presentation was usually followed by rapid decline in metabolic functions with increased anion gap and significant lactic acidosis, reinforcing the initial impression of sepsis. Several case reports and clinical studies showed similar presentation in ALCL patients, in which the clinical manifestations

were supportive of systemic infection (15-17). It has been proposed that systemic symptoms and the aggressive course of the disease might be related to increased expression of cytokines, such as G-CSF and IL-6 or IL-2 (18). Janik et al (19) showed increased levels of soluble IL-2 receptor in serum of patients with ALK-positive ALCL. Our study somewhat confirms Janik's observation by showing strong membranous expression of IL-2 receptor (CD25) in all of our cases. However, in contrast to Janik's cases, all but one of our cases were ALK-negative.

Lactic acidosis is a rare life-threatening and ominous metabolic complication associated with hematologic malignancies; less than 30 cases associated with lymphomas have been described in the literature (20,21). Among these, most were B-cell lymphomas, and no cases of ALCL-associated lactic acidosis have been described. In our study, lactic acidosis was a surprisingly frequent finding, observed in three of five cases. It has been postulated that a high rate of glycolysis in the tumor cells produces a large quantity of lactate and, in cases with liver involvement, an imbalance between lactate production and utilization occurs (22). However, treatment with chemotherapy usually results in a resolution of lactic acidosis in most of the cases (23). Three of five cases with lactic acidosis in our study showed massive involvement of liver by ALCL tumor cells.

Only two cases of intravascular spread of ALCL have been reported (24,25). In our study, all cases showed evidence of intravascular involvement in a variety of organs, including submucosal vessels of the hollow organs, the thyroid, skin, pancreas, liver, kidneys, and lungs. Such widespread extranodal solid organ involvement is in contrast with cases with the central nervous system and skin involvement described in literature (26,27). Only a few case reports of extranodal spread in other organs are available (28-33). The presence of intravas-

cular tumor cells and tumor embolization may represent an underlying cause of the DIC-like picture in our patients (34,35). Direct interaction between endothelial cells and lymphoma cells may distort hemostatic balance, triggering hemorrhage or secretion of pro-coagulants by the tumor cells itself and may lead to consumptive coagulopathy.

Hemophagocytosis represents a morphologic finding of activated macrophages engulfing hematopoietic elements secondary to a variety of causes including congenital disorders, infection, and neoplastic and immunologic disorders (36). Together with fever, cytopenia, hepatosplenomegaly, and DIC, it is associated with hemophagocytic syndrome. Hemophagocytosis was observed in two of five patients, presenting with fever, hepatosplenomegaly, DIC-like picture, and thrombocytopenia. However, the presence of leukocytosis in those cases did not entirely support classical clinical criteria of hemophagocytic syndrome. While non-Hodgkin's lymphoma associated with hemophagocytic syndrome has been frequently observed, ALCL has been reported in only rare cases (36). The cause and exact pathophysiologic mechanisms of hemophagocytosis associated with lymphomas are unclear and the possible role of cytokines (tumor necrosis factor α and interleukins 2 and 6) produced by lymphoma cells has been suggested. The same cytokines play a role in the lymphoma-associated septic-like picture with FUO and leukocytosis and, therefore, suggest a combined pathophysiologic effect (37-39). Only a few case reports of hemophagocytosis associated with ALCL have been described so far (36,38). Similar to our series, in two pediatric ALCL cases associated with hemophagocytosis patients were initially given a misdiagnosis of infection/sepsis (40).

The role of EBV in hemophagocytic syndrome has been described in immunocompetent and immunocompromised patients

(41). In our series, one patient (case 5) with positive EBV in situ hybridization had no evidence of hemophagocytic syndrome, which means that our study does not support the role of EBV virus in triggering hemophagocytic syndrome (42).

This autopsy study describes a subset of ALCL cases with rapid decline, unfavorable prognosis, distinctive clinical presentation, and gross and histologic findings. Recognition of a combination of symptoms including septic and DIC-like picture, lactic acidosis, hepatosplenomegaly, and absence of significant lymphadenopathy should trigger aggressive clinical workup to rule out the possibility of lymphoma. A meticulous examination of the peripheral blood smears and early bone marrow and biopsies based on computed tomography and magnetic resonance imaging of even slightly enlarged and deeply situated lymph nodes are recommended to yield an early diagnosis of ALCL.

References

- Jaffe ES. Anaplastic large cell lymphoma: the shifting sands of diagnostic hematopathology. *Mod Pathol.* 2001;14:219-28. [Medline:11266530](#) [doi:10.1038/modpathol.3880289](#)
- Thompson MA, Stumph J, Henrickson SE, Rosenwald A, Wang Q, Olson S, et al. Differential gene expression in anaplastic lymphoma kinase-positive and anaplastic lymphoma kinase-negative anaplastic large cell lymphomas. *Hum Pathol.* 2005;36:494-504. [Medline:15948116](#) [doi:10.1016/j.humpath.2005.03.004](#)
- Tremprat P, Villalva C, Xerri L, Armstrong F, Duplantier MM, Delsol G, et al. Gene expression profiling in anaplastic large cell lymphoma and Hodgkin's disease. *Leuk Lymphoma.* 2004;45:2001-6. [Medline:15370244](#) [doi:10.1080/10428190410001713189](#)
- Attard-Montalto SP, Saha V, Norton AJ, Kingston JE, Eden OB. Anaplastic large cell lymphoma in childhood. *Med Pediatr Oncol.* 1993;21:665-9. [Medline:8413001](#) [doi:10.1002/mpo.2950210911](#)
- Campo E, Chott A, Kinney MC, Leoncini L, Meijer CJ, Papadimitriou CS, et al. Update on extranodal lymphomas. Conclusions of the Workshop held by the EAHP and the SH in Thessaloniki, Greece. *Histopathology.* 2006;48:481-504. [Medline:16623775](#) [doi:10.1111/j.1365-2559.2006.02369.x](#)
- Cai G, Inghirami G, Moreira A, Sen F. Primary hepatic anaplastic large-cell lymphoma diagnosed by fine-needle aspiration biopsy. *Diagn Cytopathol.* 2005;33:106-9. [Medline:16007654](#) [doi:10.1002/dc.20307](#)
- Savopoulos CG, Tsesmeli NE, Kaiafa GD, Zantidis AT, Bobos MT, Hatzitolios AI, et al. Primary pancreatic anaplastic large cell lymphoma, ALK negative: a case report. *World J Gastroenterol.* 2005;11:6221-4. [Medline:16273656](#)
- Suzuki N, Tsuji H, Nakamura S, Asabe H, Sueishi K, Fujishima M. An autopsy case of Ki-1 lymphoma associated with hepatic failure. *Am J Gastroenterol.* 1998;93:115-7. [Medline:9448189](#) [doi:10.1111/j.1572-0241.1998.115_c.x](#)
- Dalton RR, Rassidakis GZ, Atwell C, Wang S, Oyarzo MP, Medeiros LJ. Differential expression of cyclin D3 in ALK+ and ALK- anaplastic large cell lymphoma. *Hum Pathol.* 2005;36:806-11. [Medline:16084951](#) [doi:10.1016/j.humpath.2005.05.013](#)
- Childs G, Unabia G. Application of the avidin-biotin-peroxidase complex (ABC) method to the light microscopic localization of pituitary hormones. *J Histochem Cytochem.* 1982;30:713-6. [Medline:6286753](#)
- Ostrow S, Diggs CH, Sutherland J, Wiernik PH. Causes of death in patients with non-Hodgkin's lymphoma. *Cancer.* 1981;48:779-82. [Medline:7248904](#) [doi:10.1002/1097-0142\(19810801\)48:3<779::AID-CNCR2820480320>3.0.CO;2-3](#)
- Pfaffenbach B, Donhuijsen K, Pahnke J, Bug R, Adamek RJ, Wegener M, et al. Systemic fungal infections in hematologic neoplasms. An autopsy study of 1,053 patients [in German]. *Med Klin (Munich).* 1994;89:299-304. [Medline:8072452](#)
- Cen X, Ma M, Guo H, Wu S, Wang Y, Qiu Z, et al. Primary extranodal lymphomas: analyses of clinical characteristics and misdiagnoses of 139 cases [in Chinese]. *Beijing Da Xue Xue Bao.* 2003;35:143-5. [Medline:12920829](#)
- Hochberg FH, Baehring JM, Hochberg EP. Primary CNS lymphoma. *Nat Clin Pract Neurol.* 2007;3:24-35. [Medline:17205072](#) [doi:10.1038/ncpneuro0395](#)
- Ezzat AA, Raja MA, Akhtar M, Bazarbashi SM, Tulbah A, Wierzbicki RF. Ki-1 large cell lymphoma: a clinical study of 12 cases. *Ann Saudi Med.* 1995;15:25-8. [Medline:17587894](#)
- Andres E, Perrin AE, Maloisel F, Marcellin L, Goichot B. Primary hepatic anaplastic large cell Ki-1 non-Hodgkin's lymphoma and hereditary hemochromatosis: a fortuitous association? *Clin Lab Haematol.* 2003;25:185-6. [Medline:12755796](#) [doi:10.1046/j.1365-2257.2003.00510.x](#)
- Onciu M, Behm FG, Raimondi SC, Moore S, Harwood EL, Pui CH, et al. ALK-positive anaplastic large cell lymphoma with leukemic peripheral blood involvement is a clinicopathologic entity with an unfavorable prognosis. Report of three cases and review of the literature. *Am J Clin Pathol.* 2003;120:617-25. [Medline:14560573](#) [doi:10.1309/WH8PNU9PK4RRV852](#)
- Harada Y, Yamada S, Murakami S, Mine S, Momosaka Y, Tsukada J, et al. Ki-1 lymphoma with nodular involvement in liver and spleen: possible role of cytokines in systemic manifestation of fever and leukocytosis. *Dig Dis Sci.* 2000;45:2240-6. [Medline:11215747](#) [doi:10.1023/A:1026652906038](#)
- Janik JE, Morris JC, Pittaluga S, McDonald K, Raffeld M, Jaffe ES, et al. Elevated serum-soluble interleukin-2 receptor levels in patients with anaplastic large cell lymphoma. *Blood.* 2004;104:3355-7. [Medline:15205267](#) [doi:10.1182/blood-2003-11-3922](#)
- Sillos EM, Shenep JL, Burghen GA, Pui CH, Behm FG, Sandlund JT. Lactic acidosis: a metabolic complication of hematologic malignancies: case report and review of the literature. *Cancer.* 2001;92:2237-46. [Medline:11745277](#) [doi:10.1002/1097-0142\(20011101\)92:9<2237::AID-](#)

- [CNCR1569>3.0.CO:2-9](#)
- 21 Osorio S, Bernis C, de La Camara R. Lactic acidosis in non-Hodgkin's lymphoma and response to chemotherapy. *Haematologica*. 2002;87:ELT05. [Medline:11836182](#)
 - 22 Stacpoole PW. Lactic acidosis and other mitochondrial disorders. *Metabolism*. 1997;46:306-21. [Medline:9054475](#) [doi:10.1016/S0026-0495\(97\)90259-6](#)
 - 23 De Keulenaer B, Van Outryve S, De Backer A, Van Overbeke L, Daelemans R, Van Marck E, et al. Symptomatic lactic acidosis due to relapse of T-cell acute lymphoblastic leukaemia in the kidney. *Nephrol Dial Transplant*. 2003;18:1214-6. [Medline:12748358](#) [doi:10.1093/ndt/fgf053](#)
 - 24 Takahashi E, Kajimoto K, Fukatsu T, Yoshida M, Eimoto T, Nakamura S. Intravascular large T-cell lymphoma: a case report of CD30-positive and ALK-negative anaplastic type with cytotoxic molecule expression. *Virchows Arch*. 2005;447:1000-6. [Medline:16189700](#) [doi:10.1007/s00428-005-0080-6](#)
 - 25 Ko YH, Han JH, Go JH, Kim DS, Kwon OJ, Yang WI, et al. Intravascular lymphomatosis: a clinicopathological study of two cases presenting as an interstitial lung disease. *Histopathology*. 1997;31:555-62. [Medline:9447388](#) [doi:10.1046/j.1365-2559.1997.3310898.x](#)
 - 26 Ponzoni M, Terreni MR, Ciceri F, Ferreri AJ, Gerevini S, Anzalone N, et al. Primary brain CD30+ ALK1+ anaplastic large cell lymphoma ('ALKoma'): the first case with a combination of 'not common' variants. *Ann Oncol*. 2002;13:1827-32. [Medline:12419758](#) [doi:10.1093/annonc/mdf300](#)
 - 27 Abdulkader I, Cameselle-Teijeiro J, Fraga M, Rodriguez-Nunez A, Allut AG, Forteza J. Primary anaplastic large cell lymphoma of the central nervous system. *Hum Pathol*. 1999;30:978-81. [Medline:10452512](#) [doi:10.1016/S0046-8177\(99\)90253-8](#)
 - 28 Venizelos ID, Rombis V, Tulupidis S, Garipidou V. Primary anaplastic large cell lymphoma of the kidney. *Leuk Lymphoma*. 2003;44:353-5. [Medline:12688357](#) [doi:10.1080/1042819021000030027](#)
 - 29 Chang SE, Park IJ, Huh J, Choi JH, Sung KJ, Moon KC, et al. CD56 expression in a case of primary cutaneous CD30+ anaplastic large cell lymphoma. *Br J Dermatol*. 2000;142:766-70. [Medline:10792229](#) [doi:10.1046/j.1365-2133.2000.03423.x](#)
 - 30 Amagai M, Kawakubo Y, Tsuyuki A, Harada R. Lymphomatoid papulosis followed by Ki-1 positive anaplastic large cell lymphoma: proliferation of a common T-cell clone. *J Dermatol*. 1995;22:743-6. [Medline:8586753](#)
 - 31 Au WY, Yeung CK, Chan HH, Wong RW, Shek TW. CD30-positive cutaneous T-cell lymphoma with concurrent solid tumour. *Br J Dermatol*. 2002;146:1091-5. [Medline:12072086](#) [doi:10.1046/j.1365-2133.2002.04702.x](#)
 - 32 Audouin J, Le Tourneau A, Diebold J, Reynes M, Tabbah I, Bernadou A. Primary intestinal lymphoma of Ki-1 large cell anaplastic type with mesenteric lymph node and spleen involvement in a renal transplant recipient. *Hematol Oncol*. 1989;7:441-9. [Medline:2553576](#) [doi:10.1002/hon.2900070607](#)
 - 33 Azua-Romeo J, Alvarez-Alegret R, Serrano P, Mayayo E. Primary anaplastic large cell lymphoma of the testis. *Int Urol Nephrol*. 2004;36:393-6. [Medline:15783113](#) [doi:10.1007/s11255-004-0750-3](#)
 - 34 Arber D, Bilbao J, Bassion S. Large-cell anaplastic (Ki-1-positive) lymphoma complicated by disseminated intravascular coagulation. *Arch Pathol Lab Med*. 1991;115:188-92. [Medline:1847037](#)
 - 35 Tsuda H. Hemophagocytic syndrome (HPS) in children and adults. *Int J Hematol*. 1997;65:215-26. [Medline:9114593](#) [doi:10.1016/S0925-5710\(96\)00560-9](#)
 - 36 Wong KF, Chan JK, Ng CS, Chu YC, Lam PW, Yuen HL. Anaplastic large cell Ki-1 lymphoma involving bone marrow: marrow findings and association with reactive hemophagocytosis. *Am J Hematol*. 1991;37:112-9. [Medline:1648880](#) [doi:10.1002/ajh.2830370209](#)
 - 37 Gudgin E, Rashbass J, Pulford KJ, Erber WN. Primary and isolated anaplastic large cell lymphoma of the bone marrow. *Leuk Lymphoma*. 2005;46:461-3. [Medline:15621840](#)
 - 38 Mozer-Lisewska I, Mazur-Melewska K, Kowala-Piaskowska A, Sluzewski W. Features of generalized infections masking basic disease: non-Hodgkin's large cell anaplastic lymphoma and hemophagocytic syndrome shown in two patients. [in Polish]. *Pol Merkur Lekarski*. 2003;14:133-5. [Medline:12728673](#)
 - 39 Okajima K, Uchiba M, Murakami K, Okabe H, Takatsuki K. Plasma levels of soluble E-selectin in patients with disseminated intravascular coagulation. *Am J Hematol*. 1997;54:219-24. [Medline:9067501](#) [doi:10.1002/\(SICI\)1096-8652\(199703\)54:3<219::AID-AJH8>3.0.CO;2-Z](#)
 - 40 Sevilla DW, Choi JK, Gong JZ. Mediastinal adenopathy, lung infiltrates, and hemophagocytosis: unusual manifestation of pediatric anaplastic large cell lymphoma: report of two cases. *Am J Clin Pathol*. 2007;127:458-64. [Medline:17276937](#) [doi:10.1309/CQGUUF5BUVJE0YU5](#)
 - 41 Eakle JF, Bressoud PF. Hemophagocytic syndrome following an Epstein-Barr virus infection: a case report and literature review. *J Ky Med Assoc*. 2000;98:161-5. [Medline:10816985](#)
 - 42 Hellier I, Dereure O, Segondy M, Guillot B, Balder P, Guillou JJ. Unlikely role of Epstein-Barr virus in the pathogenesis of primary cutaneous CD30+ anaplastic large cell lymphoma. *Eur J Dermatol*. 2001;11:203-8. [Medline:11358725](#)