



Umbilical serum tumor necrosis factor- α and interleukin-6 in chorioamnionitis

DARKA KORDIĆ¹
VESNA KOŠEĆ²
JOSIP JUKAČ¹

¹Department of Oncology and Nuclear Medicine, Sisters of Mercy University Hospital, Zagreb, Croatia

²Department of Obstetrics and Gynecology, Sisters of Mercy University Hospital, Zagreb, Croatia

Correspondence:

Darka Kordić
Department of Oncology and Nuclear Medicine
Sisters of Mercy University Hospital
Vinogradska 29, 10000 Zagreb, Croatia
E-mail: dkordic@kbsm.hr

Abstract

Background and Purpose: The term chorioamnionitis describes both clinical symptoms of intrauterine infection and antenatal inflammatory processes in the placental tissue. We studied umbilical serum tumor necrosis factor- α (TNF- α) and interleukin-6 (IL-6) content in clinical chorioamnionitis with/without histological inflammation and in histological chorioamnionitis without clinical signs.

Materials and Methods: We examined amniotic and placental tissues and umbilical cord blood samples (111) from 40 patients with clinical chorioamnionitis and 71 without it. We stratified patients according to clinical and histological findings. Umbilical serum concentrations of TNF- α and IL-6 were determined with immunoassay. To estimate systemic inflammation in infants, we used cut off values >15 pg/mL for TNF- α and >11 pg/mL for IL-6. To analyze the results, we applied methods of nonparametric statistics.

Results: In clinical chorioamnionitis, median umbilical serum concentrations of TNF- α and IL-6 were elevated only when histological inflammation (all $P < 0.001$) was present. In histological chorioamnionitis without clinical signs, median concentrations of TNF- α and IL-6 were also elevated ($P < 0.001$, < 0.048). The percentage of elevated cytokines was higher in chorioamnionitis with than without placental inflammation. Cytokine patterns were different in chorioamnionitis patients and controls.

Conclusion: Associated clinical and histological chorioamnionitis and histological chorioamnionitis enhanced inflammatory cytokine concentrations and the percentage of elevated cytokine values. The contribution of clinical chorioamnionitis without placental inflammation to umbilical serum cytokine content was minor.

INTRODUCTION

The term chorioamnionitis describes a clinical symptom complex suggestive of intrauterine infection that may include some combination of maternal fever, membrane rupture (1), elevated white blood cell count, abdominal pain and foul smelling vaginal discharge (2). The term chorioamnionitis also describes antenatal inflammatory processes in placental tissue with specific histological features, often associated with preterm birth, preterm premature fetal membrane rupture, increased risk of neonatal sepsis and death (3). However, placental tissue inflammation is present in about two thirds of patients with clinical

TABLE 1

Clinical and histological findings for the study population.

Characteristic	No clinical chorioamnionitis (n=71)	Clinical chorioamnionitis (n=40)	P value
Maternal age			
Median	32.0	29.1	NS
5%–95% range	26.4–37.0	23.7–34.0	
Parity			
Primiparous	36/71 (51%)*	23/40 (57%)	NS
Multiparous	35/71 (49%)	17/40 (43%)	NS
Gestation at delivery			
Weeks	39.7 \pm 1.2	35.2 \pm 3.2	0.030
Preterm premature membrane rupture	0 (0%)	40 (100%)	<0.01
Histologic chorioamnionitis			
Absent	53/71 (75%)	21/40 (53%)	<0.01
Present	18/71 (25%)	19/40 (47%)	<0.01

*Number of positive (% positive)

symptom complex known as chorioamnionitis (1, 4), while almost three-fourths of the cases with histological evidence of inflammation are clinically silent (5). Severity and duration of intra-uterine inflammation and its possible spread to the fetus are critical for the clinical outcome of infant (6). Many authors have detected elevated umbilical cord inflammatory cytokines in chorioamnionitis (6), yet the particular contribution of histological or clinical inflammation to cytokine elevation remains unclear. In histological chorioamnionitis, elevated umbilical serum TNF- α and IL-6 (7) were observed, together with elevated TNF- α (8), raised IL-6 with stable TNF- α concentrations (9) and elevated IL-6 (10–12). In clinical chorioamnionitis, elevated IL-6 was found frequently, while TNF- α was detected less often (13–16). We conducted the present study to investigate the contribution of clinical and histological chorioamnionitis to elevated umbilical serum TNF- α and IL-6 content, and frequency of elevated cytokine values in chorioamnionitis.

PATIENTS AND METHODS

The study examined a cohort of 111 singleton pregnant women admitted for delivery at the University Hospital Sisters of Mercy during the period of October 2002 to June 2003. Clinical chorioamnionitis was diagnosed in 40 patients in the presence of maternal temperature higher than 38.0 °C, premature rupture of membranes and premature birth (1), plus two or more of the following criteria: fetal tachycardia (>160 beats/min), maternal tachycardia, uterine tenderness, foul-smelling amniotic fluid, leucocytosis (>15 \times 10⁹ leukocyte/L, non-segmented leukocytes >15 %) or elevated C-reactive protein (2, 17). Chorioamnionitis patients with gestational age of 32–38 weeks were included. Seventy-one consecutive pa-

tients without signs of genital or extra genital infection, spontaneous contractions at term, normal labor duration and absence of major malformations were included. We collected chorioamnion and placental tissues and neonatal umbilical cord blood (111) after delivery.

The Regional Committee for Ethics in Medical Research approved the study. We obtained informed consent from all the participating women.

A pathologist blinded to the clinical conditions of mothers and infants detected histological chorioamnionitis using the described criteria (11). All placentas were examined within 24 h of collection. Placental tissues, with attached fetal membranes, were immersed in 4% formaldehyde immediately after delivery. After fixation, eight tissue samples were processed. Two full-thickness sections of the central placenta were taken within 5 cm from the insertion of the umbilical cord. Another two full-thickness sections of the periphery of the placenta were prepared. Three transverse sections of the umbilical cord taken at 5, 10 and 15 cm from the insertion and embedded into one block, and one standard membrane roll including the lining against the placenta were prepared. One 5 μ m section from each block was stained with hematoxylin, erythrosin and saffron and examined microscopically. The presence of polymorphonuclear leukocytes was separately assessed in the free membranes (amnion and chorion-decidua), in the chorionic plate, and in the umbilical cord. Ten or more polymorphonuclear leukocytes per high-power field (18) in any tissue qualified as positive for chorioamnionitis (3).

Patients were stratified according to clinical and histological findings into groups: clinical without histological chorioamnionitis, histological without clinical chorioamnionitis, associated clinical with histological chorio-

TABLE 2

Umbilical serum concentrations of TNF- α and IL-6 in chorioamnionitis.

	A Control (n=53)	B Histological* Chorioamnionitis, (n=18)	C Clinical Chorioamnionitis, (n=21)	D Clinical+Histological Chorioamnionitis, (n=19)	P
TNF α (pg/mL)	8	61	8	51	AvsB<0.001
Median	3-168	3-1001	3-27	3-915	CvsD<0.001
5-95% range					
IL-6 (pg/mL)	4	6	5	169	AvsB<0.048
Median	4-13	4-90	4-45	4-5413	CvsD<0.001
5-95% range	TNF- α : IL-6				

*As defined in Methods

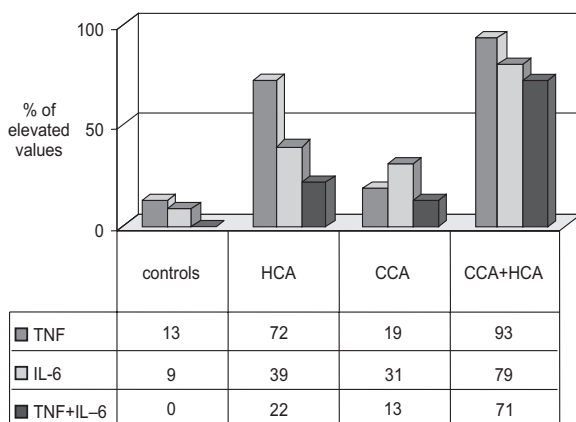


Figure 1. Percent of elevated cytokine values (cut offs: ≥ 15 pg/mL for TNF- α , and > 11 pg/mL for IL-6) in histological (HCA), clinical (CCA) and associated clinical and histological (CCA+HCA) chorioamnionitis.

TNF- α	IL-6	TNF- α + IL-6
A vs B<0.01	A vs B<0.01	A vs B<0.01
A vs C NS	A vs C<0.01	A vs C<0.01
A vs D<0.01	A vs D<0.01	A vs D<0.01
B vs C<0.01	B vs C NS	B vs C NS
B vs D<0.01	B vs D<0.01	B vs D<0.01
C vs D<0.01	C vs D<0.01	C vs D<0.01

amnionitis and neither clinical nor histological chorioamnionitis (controls). Cut-off plasma concentrations to define the fetal inflammatory response had previously been defined as > 15 pg/mL (19) for TNF- α , and > 11 pg/mL for IL-6 (12, 17).

Umbilical serum samples (111), prepared from 2 mL of cord blood collected at birth, were run immediately by an automated chemiluminescence assay (EURO/DPC-Diagnostic Immulite Products Corporation, Gwynedd LL55 4EL, United Kingdom). Analytical sensitivity was 1.7 pg/mL for TNF- α and 2.0 pg/mL for IL-6.

STATISTICAL ANALYSIS

We expressed results as the median and a 5-95 % percentile range. Statistical differences among groups were determined using the Kruskal-Wallis test, and the Mann-Whitney U tests to detect pair differences. Proportions were compared by the chi-square test. Computation was performed using Medcalc statistical software 7.3.0.0. for Windows (Medcalc Inc., Mariakerke, Belgium).

RESULTS

We presented characteristics of the population studied in Table 1 and median umbilical serum TNF- α and IL-6 concentrations in Table 2. In clinical chorioamnionitis, TNF- α and IL-6 concentrations were elevated only if histological inflammation was present (all $P < 0.001$). In histological chorioamnionitis without clinical signs, TNF- α and IL-6 concentrations were also elevated ($P < 0.001$, < 0.048). Frequency of elevated cytokine values in chorioamnionitis patients was calculated and presented in Fig 1. In infants not previously exposed to histological or clinical chorioamnionitis, the percent of elevated TNF- α or IL-6 values was low. In chorioamnionitis patients, the percent of elevated TNF- α or IL-6 was higher and cytokine pattern was different compared to controls. In chorioamnionitis patients, besides elevated TNF- α or IL-6 values, concurrently elevated both cytokines were present. Frequency of concurrently elevated TNF- α and IL-6 was higher in chorioamnionitis with histological inflammation, e.g. in associated clinical and histological chorioamnionitis and in histological chorioamnionitis compared to clinical chorioamnionitis.

DISCUSSION

Median umbilical serum cytokine content was high in chorioamnionitis with placental inflammation, e.g. in associated clinical and histological chorioamnionitis and in histological chorioamnionitis without clinical signs.

In the presence of placental inflammation, cytokines were elevated in significant percent of chorioamnionitis patients. Cytokine patterns were different in chorioamnionitis patients and controls. Gestational age additionally elevated umbilical serum IL-6 content. Preterm histological chorioamnionitis patients had higher IL-6 content than term patients did.

Similar umbilical serum TNF- α and IL-6 concentrations in histological chorioamnionitis patients were shown before (7). Different patterns of TNF- α and IL-6, described here for term and preterm histological chorioamnionitis, are comparable to a recent experimental study (20). After perfusion of term and preterm placental tissue with endotoxin, different concentrations of TNF- α and IL-6 were detected. While term and preterm placental tissue produced similar amounts of TNF- α , preterm tissue produced more IL-6 compared to term tissue. Cytokine patterns noted in perfusates and in umbilical serums of histological chorioamnionitis patients were similar. These results suggested placental origin of umbilical serum cytokines in histological chorioamnionitis, thus supporting some earlier idea (7, 11, 14). The study of cytokine transfer across placenta reinforced this approach. Cytokines are transferred across inflamed, but not across non-uninflamed placentas (20, 21). Concurrently elevated TNF- α and IL-6, shown here in umbilical sera of chorioamnionitis patients, were described earlier for septic infants (22). The combination of elevated values of TNF- α and IL-6 was a good predictor of neonatal sepsis. Possible clinical value of concurrently elevated TNF- α and IL-6 in chorioamnionitis patients requires some further investigation. Cytokine quantification by immunoassays is rapid, sensitive, specific and easy to perform.

The absence of TNF- α in histological chorioamnionitis (9) and in clinical chorioamnionitis (16) where placental tissue inflammation is present in about two thirds of patients (1, 4) is difficult to explain. Inflammatory cytokines IL-1 and TNF- α act at the beginning of inflammatory cascade to initiate and propagate the process (23, 24). We could speculate that some environmental factors or type of pathogen (25) could interfere with cytokine mechanisms leading to substitution of TNF- α with IL-1 in some cytokine networks.

Previous study of clinical and histological chorioamnionitis in terms of inflammatory cytokines showed significant variability (8-16). We demonstrated that clinical chorioamnionitis with/without histological inflammation and histological chorioamnionitis exert distinct effects on cytokine content and therefore could contribute to variability of cytokine results.

Cytokines are produced in inflammation, but as well during parturition, maternal and fetal immune response and hypoxic-ischemic injury (6). This explains the presence of elevated umbilical cytokines in infants not previously exposed to chorioamnionitis. If inflammatory cytokines, produced abundantly at the inflammation sites, spill over from a particular tissue to blood they will cause fever, leukopenia, intravascular coagulation and shock

(26). Elevated concentrations of inflammatory cytokines, if not properly down-regulated, can damage fetal/infant vital organs such as brain, lungs, and intestine (6). The link between inflammatory response and adverse infant outcome is now documented (6).

Our study details effects of clinical and histological inflammation on umbilical serum inflammatory cytokine content. We confirmed significant enhancing effect of histological inflammation on umbilical serum cytokine content known before, but also noted that even in the presence of histological chorioamnionitis some infants had low (normal) umbilical serum inflammatory cytokine content. These results suggest that placental inflammation does not always spread to the fetus. We expect that low umbilical serum cytokine content in chorioamnionitis patients will be associated with normal fetal development during and after chorioamnionitis, while the candidates with high risk for adverse outcome are among patients with high umbilical serum cytokines.

Conclusion: Associated clinical and histological chorioamnionitis and histological chorioamnionitis enhanced inflammatory cytokine concentrations and percent of elevated cytokine values. The effect of clinical chorioamnionitis without placental inflammation on umbilical serum cytokine content was minor.

Acknowledgment: The study was financially supported by Croatian Ministry of Science, Grant No 0134011.

REFERENCES

1. REDLINE R W, WILSON-COSTELLO D, BORAWSKI E, FARNAROFF A A, HACK M 2000 The relationship between placental and other perinatal risk factors for neurologic impairment in very low birth weight children. *Pediatr Res* 47: 721-726
2. GIBBS R S, BLANCO J D, ST CLAIR P J, CASTANEDAY S 1982 Quantitative bacteriology of amniotic fluid from women with clinical intraamniotic infection at term. *J Infect Dis* 145: 1-8
3. ELIMIAN A, VERMA U, BENECK D, CIPRIANO R, VISINTAINER P, TEJANI N 2000 Histologic chorioamnionitis, antenatal steroids, and perinatal outcomes. *Obstet Gynecol* 96: 333-336
4. SMULIAN J C, SHEN-SCHWARZ S, VINTZILEOS A M, LAKE M F, ANANTH C V 1999 Clinical chorioamnionitis and histologic placental inflammation. *Obstet Gynecol* 94: 1000-1005
5. VAN HOEVEN K H, ANYAEBUNAMA A, HOCHSTER H, WHITTY J E, DISTANT J, CRAWFORD C, FACTOR S M 1996 Clinical significance of increasing histologic severity of acute inflammation in the fetal membranes and umbilical cord. *Pediatr Pathol Lab Med* 16: 731-744
6. CORNETTE L 2004 Fetal and neonatal inflammatory response and adverse outcome. *Semin Fetal Neonatal Med* 9: 459-470
7. DØLLNER H, VATTEN L, HALGUNSET J, RAHIMPOOR S, AUSTGULEN R 2002 Histologic chorioamnionitis and umbilical serum levels of pro-inflammatory cytokines and cytokine inhibitors. *BJOG: Int J Obstet Gynecol* 109: 534-539
8. KAZZI S N J, JACQUES S M, QURESHI F, QUASNEY M W, KIM U O, BUHIMSCHI I A 2004 Tumor necrosis factor- α allele lymphotoxin- α +250 is associated with the presence and severity of placental inflammation among preterm births. *Pediatr Res* 56: 94-98
9. KASHLAN F, SMULIAN J, SHEN-SCHWARTZ S, ANWAR M, HIATT M, HEGY T 2000 Umbilical vein interleukin 6 and tumor necrosis factor alpha plasma concentrations in the very preterm infant. *Pediatr Infect Dis J* 19: 238-243
10. YOON B H, ROMERO R, PARK J S, KIM M, OH S Y, KIM C J, JUN J K 2000 The relationship among inflammatory lesions of the umbilical cord (funisitis), umbilical cord plasma interleukin 6 con-

centration, amniotic fluid infection, and neonatal sepsis. *Am J Obstet Gynecol* 183: 1124–1129

11. SALAFIA C M, SHERER D M, SPONG C Y, LENCKI S, EGLINTON G S, PARKASH V, MARLEY E, LAGE J M 1997 Fetal but not maternal serum cytokine levels correlate with histologic acute placental inflammation. *Am J Perinatol* 14: 419–422
12. PACORA P, CHAIWORAPONGSA T, MAYMON E, KIM Y M, GOMEZ R, YOON B H, GHEZZI F, BERRY S M, QURESHI F, JACQUES S M, KIM J C, KADAR N, ROMERO R 2002 Funisitis and chorionic vasculitis: the histological counterpart of the fetal inflammatory response syndrome. *J Matern Fetal Neonatal Med* 11: 18–25
13. CHAIWORAPONGSA T, ROMERO R, KIM J C, KIM Y M, BLACKWELL S C, YOON B H, GOMEZ R 2002 Evidence for fetal involvement in the pathologic process of clinical chorioamnionitis. *Am J Obstet Gynecol* 186: 1178–1182
14. SINGH B, MERCHANT P, WALKER C R, KRYWORUCHKO M, DIAZ-MITOMA F 1996 Interleukin-6 expression in cord blood of patients with clinical chorioamnionitis. *Pediatr Res* 39: 976–979
15. LENCKI S G, MACIULLA M B, EGLINTON G S 1994 Maternal and umbilical cord serum interleukin levels in preterm labor with clinical chorioamnionitis. *Am J Obstet Gynecol* 170: 1345–1351
16. SHALAK L F, LAPTOOK A R, VAFRI H S, RAMILO O, PERLMAN J M 2002 Clinical chorioamnionitis, elevated cytokines, and brain injury in term infants. *Pediatrics* 110: 832–833
17. ROMERO R, YOON B H, MAZOR M, GOMEZ R, DIAMOND M P, KENNEY J S, RAMIREZ M, FIDEL P L, SOROKIN Y, COTTON D, PRAVINKUMAR S 1993 The diagnostic and prognostic value of amniotic fluid white blood cell count, glucose, interleukin-6, and Gram stain in patients with preterm labor and intact membranes. *Am J Obstet Gynecol* 169: 805–816
18. BENIRSCHKE K, KAUFMANN P 2000 Pathology of the Human Placenta. Springer-Verlag, New York, p 268–318
19. GIRARDIN E P, BERNER M E, GRAU G E, SUTER S, LA-COURT G, PAUNIER L 1990 Serum tumor necrosis factor in newborns at risk for infections. *Eur J Pediatr* 149: 645–647
20. HOLCBERG G, AMASH A, SAPIR O, SHEINER E, LEVY S, HULEIHEL M 2007 Perfusion with lipopolysaccharide differently affects the secretion of tumor necrosis factor-alpha and interleukin-6 by term and preterm placenta. *J Reprod Immunol* 74: 15–23
21. AALTONEN R, HEIKKINEN T, HAKALA K, LAINE K, ALANEN A 2005 Transfer of proinflammatory cytokines across term placenta. *Obstet Gynecol* 106: 802–807
22. DE BONT E S, MARTENS A, VAN RAAN J, SAMSON G, FETTER W P, OKKEN A, DE LEIJ L H, KIMPEN J L 1994 Diagnostic value of plasma levels of tumor necrosis factor alpha (TNF alpha) and interleukin-6 (IL-6) in newborns with sepsis. *Acta Paediatr* 83: 696–699
23. MANTOVANIA 1997 The interplay between primary and secondary cytokines. *Drugs* 54: 15–23
24. DINARELLO C A 2000 Proinflammatory cytokines. *Chest* 118: 503–508
25. BASHIRI A, BURSTEIN E, MAZOR M 2006 Cerebral palsy and fetal inflammatory response syndrome: a review. *J Perinat Med* 34: 5–12
26. WHITESIDE T L 1994 Cytokine measurements and interpretation of cytokine assays in human disease. *J Clin Immunol* 14: 327–339