

INTRAVENTRICULAR LOCATION OF METASTATIC BREAST CARCINOMA: A CASE REPORT

Tomislav Sajko¹, Krešimir Rotim¹, Nenad Kudelić¹, Hrvoje Krpina¹ and Leandra Miletić²

¹University Department of Neurosurgery, Sestre milosrdnice University Hospital, Zagreb; ²School of Medicine, University of Rijeka, Rijeka, Croatia

SUMMARY – Intraventricular neoplasms are uncommon central nervous system lesions that account for only 10% of all neoplasms and are unusual location of metastatic breast cancer. A 73-year-old woman with a medical history of breast carcinoma without any signs of metastatic lesions in the liver, lungs or bones and with an intraventricular tumorous lesion found on multislice computed tomography of the brain is presented. Surgery was indicated in order to confirm the diagnosis histologically and to gain local control of the metastasis. The patient was operated on using the neuronavigation guided transcortical approach. The tumor was removed using the Cavitron ultrasonic aspirator. Histopathologic examination revealed a metastatic breast carcinoma. Postoperative irradiation of the whole brain was performed.

Key words: *Cerebellar neoplasms – pathology; Cerebellar neoplasms – surgery; Cerebellar neoplasms – therapy; Glioblastoma – etiology; Glioblastoma – surgery; Glioblastoma – therapy; Case report*

Introduction

Metastasis to the brain is diagnosed in patients with breast cancer at a rate of 10%-20%, making breast cancer the second most common source of brain metastases¹⁻³. Patients with breast cancer rarely present with manifestations of brain metastasis before detection of the primary breast cancer⁴. Brain metastasis is usually associated with aggressive tumor behavior, negative hormone-receptor status, relatively young age, and presence of lung and liver metastasis^{5,6}.

Case Report

A 73-year-old woman was admitted to our Department of Neurosurgery on July 2007 for an intraventricular tumorous lesion found on multislice computed tomography (MSCT) of the brain (Fig. 1). Medical history revealed right breast carcinoma operated on two years

before. The patient was conscious, complaining of headache and vomiting. Except for truncal ataxia, the rest of

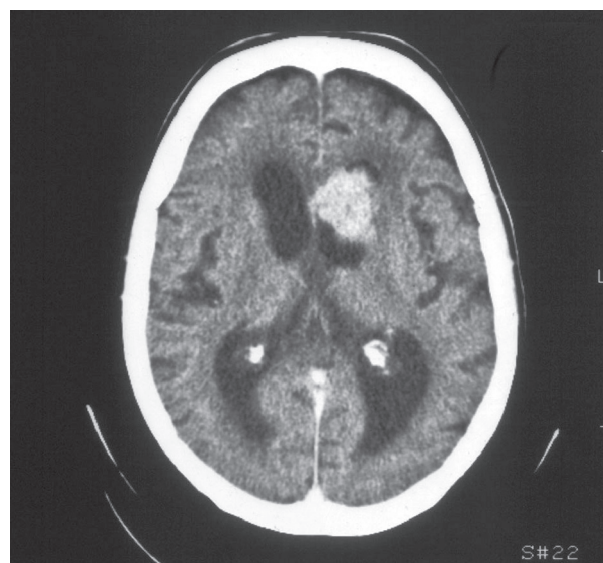


Fig. 1. Preoperative computed tomography of the brain with contrast agent showing a homogeneously enhanced intraventricular lesion in the frontal horn of the left lateral ventricle with subsequent unilateral hydrocephalus.

Correspondence to: *Tomislav Sajko, MD*, University Department of Neurosurgery, Sestre milosrdnice University Hospital, Vinogradska c. 29, HR-10000 Zagreb, Croatia

E-mail: *t_sajko@net.hr*

Received January 8, 2009, accepted February 27, 2009

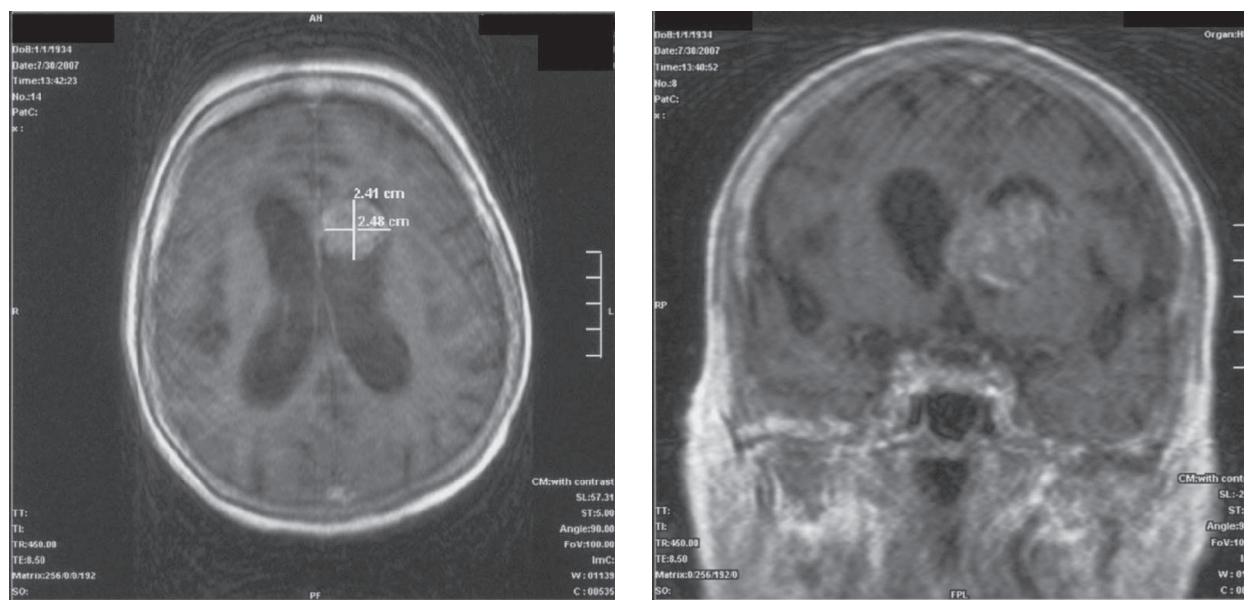


Fig. 2. Preoperative magnetic resonance of the brain. Axial and coronal T1 weighted images showing a tumorous lesion filling the frontal horn of the left lateral ventricle.

her neurologic examination was normal. There were no signs of metastatic lesions of the liver, lungs or bones. The carcinoembryonic antigen (CEA) and CA15-3 levels were normal (CEA=1.2 ng/mL; CA15-3=14.8 U/mL). Magnetic resonance (MR) of the brain showed a tumorous lesion, 24x25 mm in size, located in the frontal horn of the left lateral ventricle with subsequent unilateral hydrocephalus (Fig. 2). Homogenous enhancement of the lesion was observed upon contrast agent (gadolinium) administration. An ependymoma or intraventricular meningioma was suspected.

Left frontal craniotomy was made at the projection of Kocher's point. Upon opening the dura, frontal corticotomy was done and the frontal horn of the left lateral ventricle was entered using the Medtronic Stealth® neuronavigation device (Fig. 3). The surgery was continued in the microneurosurgical manner. The tumorous lesion was attached to the lateral wall of the frontal horn of the left lateral ventricle. The lesion was removed using the Cavitron ultrasonic aspirator (CUSA). Upon completing exact hemostasis, choroid plexus, left thalamostriate vein and foramen of Monroe were found intact using a rigid endoscope. The dura was closed in the watertight fashion. Postoperative recovery was uneventful. Histopathologic examination revealed a metastatic carcinoma composed of pseudopapillary and cribriform atypical epithelial cells with a high mitotic index. The pa-

tient underwent whole brain radiation therapy (WBRT) applying 30 Gy in 10 fractions. On three-month postoperative follow-up, MSCT was performed to reveal normal postoperative finding (Fig. 4). Six months after the surgery, the patient's condition aggravated due to the development of lung and liver metastases. The patient is currently receiving chemotherapy.

Discussion

Brain metastases are the most common intracranial tumours in adults, occurring in 10-40% of cancer patients⁷.

Intraventricular neoplasms are uncommon central nervous system lesions that account for only 10% of all neoplasms⁷. In a study of 47 cases of intraventricular neoplasms of the brain, Jelinek *et al.* report on three cases of metastases in patients older than 30 years⁸. A landmark randomized trial published by Patchell *et al.* demonstrated that patients with resectable single brain metastasis randomized to undergo resection and WBRT survived longer than those that received biopsies and WBRT alone⁹. After the confirmatory trial was published, surgery and postoperative irradiation have been established as the standard approach¹⁰.

Intraventricular localization of metastatic lesions is rare. We report on a case of an adult female patient with

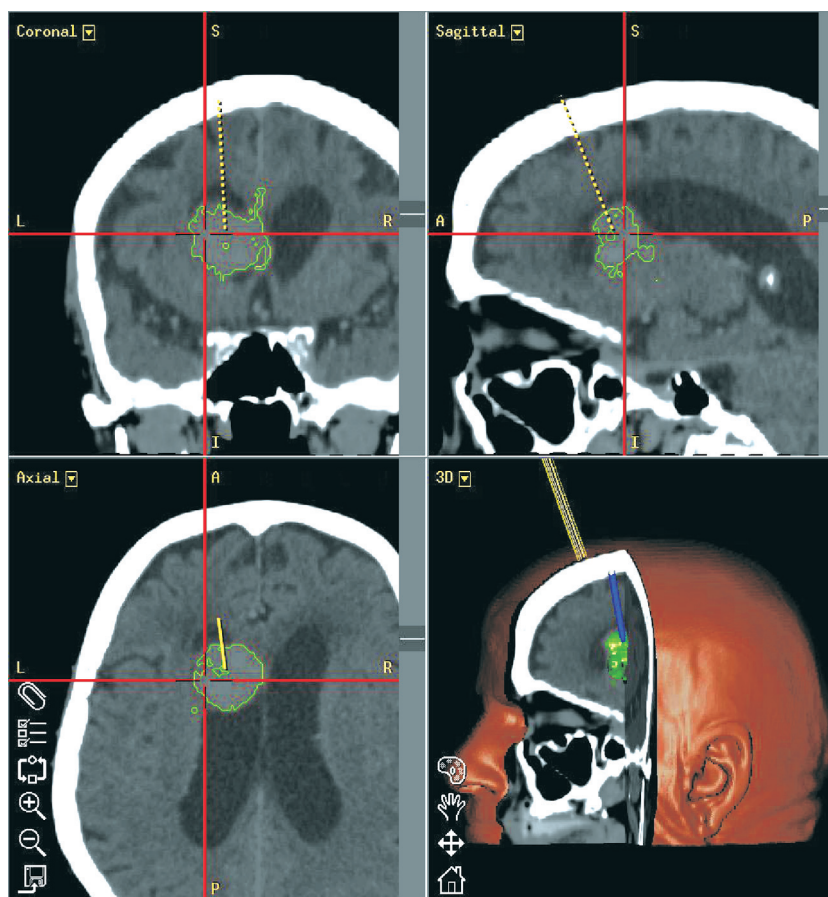


Fig. 3. Preoperative surgical planning indicating the trajectory of the transcortical frontal approach to the intraventricular tumorous lesion.

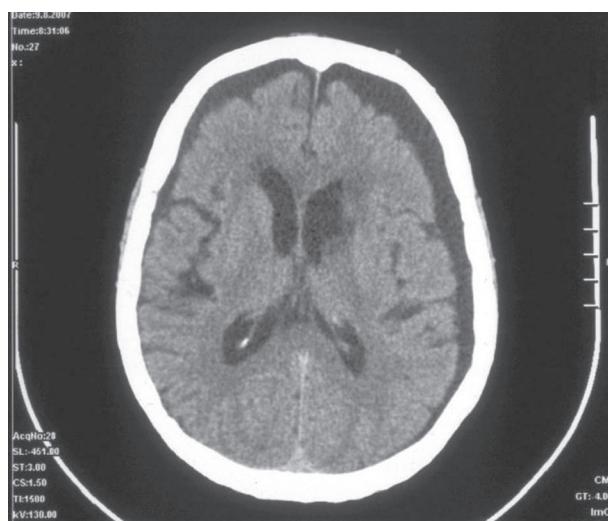


Fig. 4. Postoperative computed tomography of the brain showing no residual tumorous lesion. Bilateral postoperative subdural hygromas are shown.

no systemic signs of breast carcinoma metastases and with normal carcinoma antigen findings. Surgery was performed in order to confirm the diagnosis histologically and to gain local control of the tumor as proposed by other authors^{4,11}. We did not use stereotactic biopsy due to the noted false-positive rate of 11%⁹.

Surgery continues to be the major treatment option in patients with brain metastases, especially as advances in therapy increase the number of patients who present as candidates for craniotomy¹³.

References

1. DISTEFANO A, YONG YAP Y, HORTOBAGYI GN, *et al.* The natural history of breast cancer patients with brain metastases. *Cancer* 1979;44:1913-8.
2. LEE YE. Breast carcinoma: pattern of metastasis at autopsy. *J Surg Oncol* 1983; 23:175-80.
3. POSNER JB. Back pain and epidural spinal cord compression. *Med Clin North Am* 1987;71:185-205.

4. WEN PY, LOEFFLER JS. Management of brain metastases. *Oncology (Huntingt)* 1999;12:941-54, 957-61; discussion 961-2, 969.
5. SPARROW GE, RUBENS RD. Brain metastases from breast cancer: clinical course, prognosis and influence of treatment. *Clin Oncol* 1981;7:291-301.
6. STEWART JF, KING RJ, SEXTON SA, *et al.* Oestrogen receptors, sites of metastatic disease and survival in recurrent breast cancer. *Eur J Cancer* 1981;17:449-53.
7. SOFFIETTI R, RUDA R, TREVISAN E. Brain metastases: current management and new developments. *Current Opinion in Oncology* 2008, 20:676-684.
8. LANG FF, SAWAYA R. Surgical management of cerebral metastases. *Neurosurg Clin N Am* 1996; 7:459-484
9. JELINEK J, SMIRNIOTOPOULOS JG, PARISI JE, KANZER M. Lateral ventricular neoplasms of the brain: differential diagnosis based on clinical, CT, and MR findings. *AJR Am J Roentgenol* 1990;155:365-72.
10. PATCHELL RA, TIBBS PA, WALSH JW, *et al.* A randomized trial of surgery in the treatment of single metastases to the brain. *N Engl J Med* 1990;322:494-500.
11. NOORDIJK EM, VECHE CJ, HAAXMA-REICHE H, *et al.* The choice of treatment of single brain metastasis should be based on extracranial tumor activity and age. *Int J Radiat Oncol Biol Phys* 1994;29:711-7.
12. WEN PY, SHAFMAN TD. Site-specific therapy of metastatic breast cancer. In: HARRIS JR, ed. *Disease of the breast*. Philadelphia: Lippincott, Williams & Wilkins, 2000:841-53.
13. SILLS A. Current Treatment Approaches to Surgery for Brain Metastases. *Neurosurgery* 2005; 57(5 Suppl):S24-32; discussion S1-4.

Sažetak

INTRAVENTRIKULARNA LOKALIZACIJA METASTATSKOG KARCINOMA DOJKE: PRIKAZ SLUČAJA

T. Sajko, K. Rotim, N. Kudelić, H. Krpina i L. Milić

Intraventricularni tumori predstavljaju svega 10% svih tumora središnjega živčanog sustava. Još je rjeđa intraventricularna lokalizacija metastatskog karcinoma dojke. Prikazujemo slučaj 73-godišnje bolesnice s karcinomom dojke bez znakova metastatskih promjena u jetri, plućima ili kostima. Neuroradiološka obrada (MSCT, višeslojna kompjutorizirana tomografija) je pokazala intraventricularnu tumorsku tvorbu. Radi potvrde histološke dijagnoze te lokalne kontrole rasta tumora indicirano je operacijsko liječenje. Bolesnica je operirana transkortikalnim pristupom uz pomoć neuronavigacijskog sustava. Tumor je uklonjen uz primjenu kavitronskog ultrazvučnog aspiratora. Patohistološka analiza je pokazala metastatski karcinom dojke. Poslijeoperacijski je provedeno ozračivanje cijelog mozga.

Ključne riječi: Novotvorine cerebeluma – patologija; Novotvorine cerebeluma – kirurgija; Novotvorine cerebeluma – liječenje; Glioblastom – etiologija; Glioblastom – kirurgija; Glioblastom – liječenje; Prikaz slučaja