

## LAMOTRIGINE THERAPY FOR RESISTANT PAIN IN RADICULAR LESIONS OF CERVICAL SEGMENTS C4-C5 AND C5-C6: A CASE REPORT

Marina Titlić<sup>1</sup>, Ivana Jukić<sup>2</sup>, Ante Tonkić<sup>2</sup>, Ante Buča<sup>3</sup> and Anka Aleksić-Shihabi<sup>4</sup>

<sup>1</sup>University Department of Neurology, <sup>2</sup>Department of Gastroenterology and Hepatology, University Department of Medicine, <sup>3</sup>Department of of Neuroradiology, University Department of Radiology, Split University Hospital Center, Split; <sup>4</sup>Department of Neurology, Šibenik General Hospital, Šibenik, Croatia

**SUMMARY** – Radicular pain syndromes caused by disk herniation are often accompanied by incomplete central cord syndrome. Intensive pain is difficult to control with standard analgesics. Antiepileptics of new generation have shown significant efficacy in treating pain syndromes, trigeminal neuralgia, diabetic neuropathy, migraines, etc. The treatment of radicular pain with lamotrigine, a new generation antiepileptic, turned out to be effective in lumbar disk radicular conflicts, justifying its application for resistant pain in cervical segment. In our patient, pain intensity was significantly reduced with gradual titration of lamotrigine to a dose of 200 mg/day. Pain intensity measured by the visual analog scale significantly decreased from 100 to 20 mm during eight weeks of titration. The blood concentration of the drug measured by the method of high performance liquid chromatography was 13.65  $\mu\text{mol/L}$ . The patient's quality of life improved greatly. It is necessary to further evaluate the efficacy of lamotrigine in the treatment of resistant radicular damage.

**Key words:** *Spinal cord diseases – therapy; Neuralgia – physiopathology; Neuralgia – drug therapy; Anticonvulsants – pharmacology; Pain – drug therapy*

### Introduction

In permanent pain syndromes, pain does not offer any biological or adaptive advantage. It only presents permanent suffering and stress for the affected person. Such pain is the result of the nervous system lesion, such as damage to the peripheral nervous system, dorsal roots of the spinal cord, or the central nervous system itself, and in neurology it is usually classified as neuropathic pain. The pain is usually flashing, followed by unpleasant paresthesia and electric shock-like sensations. Another characteristic is allodynia, a type of hyperpathia characterized by severe pain irrespective of the type and intensity of stimulus. Pain radiation be-

yond the stimulated area is also typical, and so is basic pain intensifying upon recurring stimulations of any quality. Pressure upon nerve roots due to herniated disk results in intensive pain, which is relatively successfully controlled with classic analgesics, opiates, etc. Pain is sometimes resistant, making it necessary to use other available drugs as well<sup>1,2</sup>. The efficacy of antiepileptic drugs of the new generation in the treatment of neuropathic pain has been proved by clinical studies<sup>3-5</sup>. Lamotrigine is indicated in the management of central pain, resistant trigeminal neuralgia, but it also has a significant effect in diabetic neuropathy, HIV-associated neuropathy, and neuropathic pain of mixed etiology<sup>6-9</sup>.

Lamotrigine is a new generation antiepileptic with dual action, i.e. stabilizing neural membrane by inactivating the voltage-sensitive ionic channels and inhibiting presynaptic release of glutamates<sup>10</sup>. It should be noted that lamotrigine has a mood stabilizing activity and can be used in bipolar disorder. The treatment of

Correspondence to: *Marina Titlić, MD, PhD*, University Department of Neurology, Split University Hospital Center, Spinčićeva 1, HR-21000 Split, Croatia

E-mail: [marina.titlic@gmail.com](mailto:marina.titlic@gmail.com)

Received July 2, 2007, accepted in revised form January 12, 2009

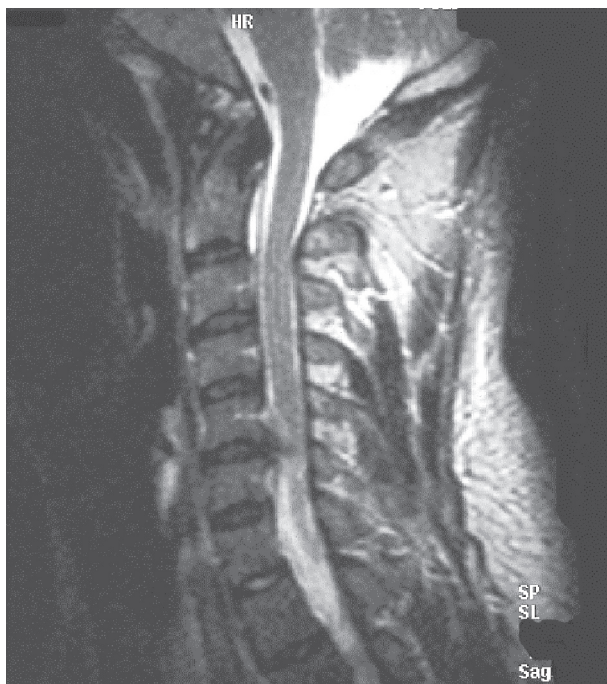chronic pain should also include antidepressant therapy.

The possible efficacy of lamotrigine in treating pain in disk-radicular lesions has been investigated, especially in cases when the pain cannot be controlled with classic analgesics. Eisenberg *et al.* suggest that lamotrigine is potentially effective and safe for the treatment of painful lumbar radiculopathy when other analgesics and procedures fail to show adequate efficacy<sup>11</sup>.

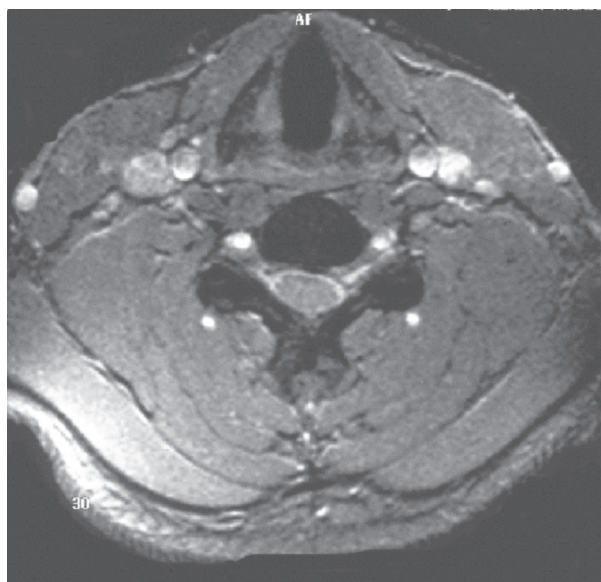
Herniation of intervertebral disk in cervical segment can very often cause severe pain syndromes with incomplete central cord syndrome. In this report we describe a patient with herniation of cervical disk, whose severe pain could not be reduced with standard treatment (non-steroidal analgesics and opioids), therefore it was attempted by gradual titration of lamotrigine.

### Case Report

A 43-year-old woman reported pressure and subsequent pain experienced for the last two years with growing intensity in the neck and along both arms, more pronounced on the left side. Rough motor strength of the



*Fig. 1. Magnetic resonance image of the spine-dorsal protrusion at C4-C5 level, with compression of the frontal arachnoid area and spinal medulla, and slight reduction of the frontal arachnoid area at C5-C6 level.*



*Fig. 2. Magnetic resonance image of the spine: dorsal protrusion at C5-C6 level (transverse cross section).*

left arm gradually decreased, as well as the strength of flexor III, IV and V of the left hand fingers. Hypoesthesia ranging broadly from C4 to C8 was also reported. The patient reported occasional dropping objects from her hands.

Paravertebral muscles were tense. Radicular lesion at C6, C7 was determined by electromyography. Neuro-radiologically, computerized tomography (CT) and magnetic resonance imaging (MRI) of the cervical spine showed intervertebral disk protrusion at C4-C5 and C5-C6 level. MRI of the cervical vertebrae clearly showed degenerative changes of the disk at C4-C5 level, with dorsal protrusion, accompanied by compression of the frontal arachnoid area and spinal medulla. Degenerative disk changes at C5-C6 level were pronounced, along with slight reduction of the frontal arachnoid area. Spinal medulla did not show signs of myelopathic changes (Figs. 1 and 2).

Neurosurgeon indicated surgery, but the patient refused it temporarily. The patient was administered analgesics (diclofenac sodium 150 mg/day in ampoules and diazepam 10 mg i.m.) and myorelaxants (chlorzoxasone 3 g/day orally) as well as corticosteroids. Physical therapy was also prescribed. Pain intensity was increasing and hardly bearable, significantly reducing the patient's quality of life.

Pain intensity increased to become very strong over the past two months. Measured by the visual analog scale

(VAS), it reached 100 mm. Since pain could not be alleviated by any of the nonsteroidal antirheumatics or opioids, we decided to administer antiepileptics. We tried to choose an antiepileptic with the least possible side effects and the best possible therapeutic effects, and decided to apply lamotrigine. Lamotrigine was introduced with gradual titration of 25, 50, 100 and 200 mg/day. Therapeutic efficacy was assessed by 100-mm VAS every two weeks throughout the 8-week period.

At the beginning of treatment, VAS scale showed 100 mm according to the patient's report, and two weeks later while taking 50 mg/day lamotrigine it showed 75-80 mm. Since there were no side effects, the drug dose was increased to 100 mg/day, administered as 50 mg twice a day. Two more weeks later, during follow up examination, VAS scale showed 35 mm, the patient felt much better, having successfully performed her daily activities, avoiding lifting heavy objects. The drug dosage was increased to 150 mg/day administered in two half doses *per day*. The next follow up visit in two weeks, i.e. six weeks of the drug introduction, while taking 150 mg/day lamotrigine, pain intensity decreased and the patient assessed it as 30 mm VAS. It is noteworthy to mention that the patient was more cautious about her daily activities. The daily drug dose was increased to 200 mg/day, divided into two daily doses. Two weeks later, i.e. in week 8 of gradual drug administration at a dose of 200 mg/day, the patient's subjective pain assessment was 20 mm VAS. Pain intensity was reduced by gradual increase in daily drug dose, as measured with VAS scale. The blood concentration of the drug measured by the method of high performance liquid chromatography (HPLC) during eighth week on a dose of 200 mg/day was 13.65  $\mu\text{mol/L}$  (reference range, 3.9-19  $\mu\text{mol/L}$ ). The patient continued taking the medicine for the next six months. On VAS scale, pain intensity was 20 to 25 mm. The patient's quality of life markedly improved. Follow up examinations showed no changes of either neurologic status or electromyography results.

## Discussion

Radicular lesion of the cervical segment with herniation of intervertebral disk and the resulting incomplete central cord syndrome causes radicular pain which cannot be successfully treated with standard analgesics. In our patient, resistant acute radicular pain of the cervical segment was treated with lamotrigine, a neuron membrane stabilizer, by blocking the voltage-sensitive chan-

nels and inhibiting the presynaptic glutamate release. Efficient drug dose for resistant radicular pain of the cervical segment was determined by gradual drug titration to the dose of 200 mg/day, pain measurement with VAS scale, and measurement of the blood concentration of the drug by HPLC. Control of painful syndromes with lamotrigine has proved efficient in trigeminal neuralgia, SUNCT syndrome, diabetic neuropathy, etc.<sup>6,7,12</sup>. Lamotrigine is potentially efficient in the management of painful lumbar radiculopathy<sup>11</sup>. It was the reason for us to try lamotrigine in the treatment of resistant pain of cervical segment by gradual drug titration, which proved to significantly reduce pain intensity.

HPLC is used for quantitative determination of lamotrigine in plasma<sup>13,14</sup>. The level of lamotrigine in blood during week 8 of treatment, while taking a dose of 200 mg/day, was 13.65  $\mu\text{mol/L}$  as measured by the HPLC method (reference range, 3.9-19  $\mu\text{mol/L}$ ). Hence, this stabilizer of neuron membrane showed significant efficacy in the control of pain with adequate drug concentration in the blood.

In conclusion, the treatment of pain that is resistant to nonsteroidal analgesics requires the use of antiepileptics. Priority is given to medicines with best effects and least side effects. Lamotrigine has good effects, its serum concentration can be established, and side effects are rare. Therefore, we prefer it in the management of painful radiculopathies.

Lamotrigine has proved efficient for neurologic or EMG deficits. Sporadic successes in treating painful radiculopathy indicate the need of extensive research of lamotrigine effects in such cases. Only a large study could show the effects of lamotrigine in radicular pain when it is used as first-line, second-line, third-line or fourth-line treatment for moderate to severe pain.

## References

1. GOEBERT HW, JALLO SJ, GARDNER WJ, *et al.* Painful radiculopathy treated with epidural injections of procaine and hydrocortisone acetate: results in 113 patients. *Anesth Analg* 1961;40:130-4.
2. GOUPILLE P, JAYSON MIV, VALT JP, FREEMONT AJ. The role of inflammation in disc herniation associated radiculopathy. *Semin Arthritis Rheum* 1998;28:60-71.
3. EISENBERG E, RIVER Y, SHIFRIN A, KRIVROY N. Antiepileptic drugs in the treatment of neuropathic pain. *Drugs* 2007;67:1265-89.
4. FOX A, GENTRY C, PATEL S, KESINGLAND A, BEVAN S. Comparative activity of the anticonvulsants oxcarbazepine,

- lamotrigine and gabapentin in a model of neuropathic pain in the rat and guinea-pig. *Pain* 2003;105:355-62.
5. SPINA E, PERUGI G. Antiepileptic drugs: indications other than epilepsy. *Epileptic Disord* 2004;6:57-75.
  6. CANAVERO S, BONICALZI V. Drug therapy of trigeminal neuralgia. *Expert Rev Neurother* 2006;6:429-40.
  7. VINIKA. Clinical review: use of antiepileptic drugs in the treatment of chronic painful diabetic neuropathy. *J Clin Endocrinol Metab* 2005;90:4936-45.
  8. SIMPSON DM, McARTHUR JC, OLNEY R, CLIFFORD D, SO Y, ROSS D, BAIRD BJ, BARRETT P, HAMMER AE; Lamotrigine HIV Neuropathy Study Team. *Neurology* 2003;60:1508-14.
  9. EISENBERG E, SHIFRIN A, KRIVOY N. Lamotrigine for neuropathic pain. *Expert Rev Neurother* 2005;5:729-35.
  10. CHEUNG H, KAMP D, HARRIS E. An *in vitro* investigation of the action of lamotrigine on neural voltage-activated sodium channels. *Epilepsy Res* 1992;13:107-12.
  11. EISENBERG E, DAMUNNI G, HOFFER E, BAUM Y, KRIVOY N. Lamotrigine for intractable sciatica: correlation between dose, plasma concentration and analgesia. *Eur J Pain* 2003;3:485-91.
  12. ALORE PL, JAY WM, MACKEN MP. SUNCT syndrome: Short-lasting Unilateral Neuralgiform headache with Conjunctival injection and Tearing. *Semin Ophthalmol* 2006;21:9-13.
  13. MORRIS RG. High-performance liquid chromatography quantitation of plasma lamotrigine concentrations: application measuring through concentrations in patients with epilepsy. *Ther Drug Monit* 1997;19:688-93.
  14. RAMACHANDRAN S, UNDERHILL S, JONES SR. Measurement of lamotrigine under conditions measuring phenobarbitone, phenytoin, and carbamazepine using reversed-phase high-performance liquid chromatography at dual wavelengths. *Ther Drug Monit* 1994;16:75-82.

#### Sažetak

### LAMOTRIGIN U LIJEČENJU REZISTENTNE AKUTNE BOLI PRI RADIKULARNOM OŠTEĆENJU VRATNOG SEGMENTA: PRIKAZ SLUČAJA

M. Titlić, I. Jukić, A. Tonkić, A. Buča i A. Aleksić-Shihabi

Radikalarni bolni sindromi uzrokovani hernijacijom diska obično su udruženi s nepotpunim sindromom kralježnične moždine. Intenzivna bol se teško kontrolira standardnim analgeticima. Antiepileptici nove generacije pokazuju značajan učinak u liječenju bolnih sindroma, neuralgije trigeminusa, dijabetične neuropatije, migrene itd. Liječenje radikularne boli lamotriginom, antiepileptikom nove generacije, pokazalo se učinkovitim u lumbarnom disk-radikularnom konfliktu pa smo ga pokušali primijeniti i u rezistentnoj boli vratnoga segmenta. Postupnom titracijom lamotrigina do doze od 200 mg/dan intenzitet boli značajno se smanjio. Intenzitet boli mjereno ljestvicom VAS smanjio se sa 100 na 20 mm kroz razdoblje od osam tjedana titracije lijeka. Razina lijeka u krvi određena pomoću metode HPLC bila je 13,65 µmol/L. Kvaliteta života naše bolesnice značajno se poboljšala. Potrebno je procijeniti učinkovitost lamotrigina u liječenju rezistentne radikularne boli.

**Ključne riječi:** *Bolesti kralježnične moždine – terapija; Neuralgija – patofiziologija; Neuralgija – terapija lijekovima; Antikonvulzansi – farmakologija; Bol – terapija lijekovima*