

PEDUNCULATED MYOLIPOMA INCIDENTALLY FOUND IN HERNIAL SAC: A CASE REPORT

Petra Šulentić, Slaven Abdović, Jakša Filipović and Davor Tomas

Ljudevit Jurak University Department of Pathology, Sestre milosrdnice University Hospital, Zagreb, Croatia

SUMMARY – A case of a very rare adipocytic tumor found during corrective surgery for incisional abdominal hernia is presented. Because of uterine leiomyomas the patient underwent total abdominal hysterectomy 14 years before. During surgery of incisional hernia, a part of small intestine along with a pedunculated tumor was found in hernial sac. The tumor was attached to the medial intra-abdominal peritoneum. On examination, the tumor presented as a totally encapsulated dimorphic benign neoplasm composed of mature adipocytes and well-differentiated smooth muscle cells. Lipoblasts, floret-like giant cells, nuclear atypia, mitosis or proliferation of medium-sized arteries with thick muscular walls were not observed. Tumor cells were negative for HMB45, estrogen and progesterone. The diagnosis of myolipoma was established. This tumor commonly presents as a large quiescent mass in retroperitoneum in adult females and to our knowledge this is the first report of myolipoma in hernial sac. Characteristic findings, differential diagnosis, prognosis and the possible origin of such a neoplasm are discussed.

Key words: *Leiomyoma – complications; Leiomyoma – pathology; Retroperitoneal neoplasms – pathology; Retroperitoneal neoplasms – surgery; Myolipoma – diagnosis; Hernia, abdominal; Liposarcoma – diagnosis*

Introduction

Myolipoma is a very rare adipocytic tumor, composed of mature adipocytes and well-differentiated smooth muscle cells¹. Most often, it is found as a large quiescent mass in retroperitoneum in adult females, although other various locations have also been reported^{1,2}. Besides its incidental finding during operative procedures, it can present itself as a clinically palpable mass. Myolipoma is often misdiagnosed radiologically as liposarcoma, especially if the tumor is located in retroperitoneum, because the great majority of large retroperitoneal tumors containing fat are liposarcomas².

We report a case of pedunculated myolipoma incidentally found in hernial sac during surgical procedure.

Case Report

A 54-year-old woman was admitted to the hospital for correction of incisional abdominal hernia. Fourteen years before she had undergone total abdominal hysterectomy because of uterine leiomyomas. During the past few years she had suffered severe coughs leading to the development of abdominal hernia. Intermittent pain and discomfort had appeared and the hernia enlarged in the last few months before corrective surgery. Physical examination revealed a large abdominal hernia. Manual reposition of hernia was not successful. The patient underwent surgery and during corrective procedure a part of small intestine along with a pedunculated tumor was found in hernial sac. The tumor was attached to medial intra-abdominal peritoneum. After tumor resection, the sac was returned to peritoneal cavity and the margins were sutured.

Pathologic findings

On gross examination, the tumor was round, well demarcated, entirely encapsulated by a thin capsule and

Correspondence to: *Petra Šulentić, MD*, Ljudevit Jurak University Department of Pathology, Sestre milosrdnice University Hospital, Vinogradska c. 29, HR-10000 Zagreb, Croatia
E-mail: petra.sulentic@gmail.com
Received February 5, 2009, accepted April 15, 2009

measured 6 cm in maximum diameter. At the cut section, the tumor was soft, yellowish and lobular with whitish septa (Fig. 1A).

Microscopically, the tumor was composed of benign looking smooth muscle cells with spindle shaped nuclei and eosinophilic cytoplasm and mature adipose tissue (Fig. 1B). The smooth muscle component predominated, with a muscle to fat ratio of approximately 2:1. Smooth muscle was evenly distributed and arranged in short fascicles or individual distinct cells. The adipose cells were entirely mature, and lipoblasts or floret-like giant cells were not observed. Nuclear atypia, mitosis and proliferation of medium-sized arteries with thick muscular walls were not evident in either component. Immunohistochemically, tumor cells with smooth mus-

cle morphology were immunoreactive for vimentin, smooth muscle actin (Fig. 1C) and desmin (Fig. 1D). CD34 immunostains only highlighted the vascular network of the neoplasm. Tumor cells were negative for HMB45, estrogen and progesterone. The tumor was encapsulated with a tiny fibrous capsule and totally excised. According to gross appearance, histological and immunohistochemical presentation, the diagnosis of myolipoma was established.

Discussion

Myolipoma is an uncommon benign neoplasm, occurring most frequently in adults in the deep soft tissue of the abdomen or abdominal cavity²⁻⁵. In the past six

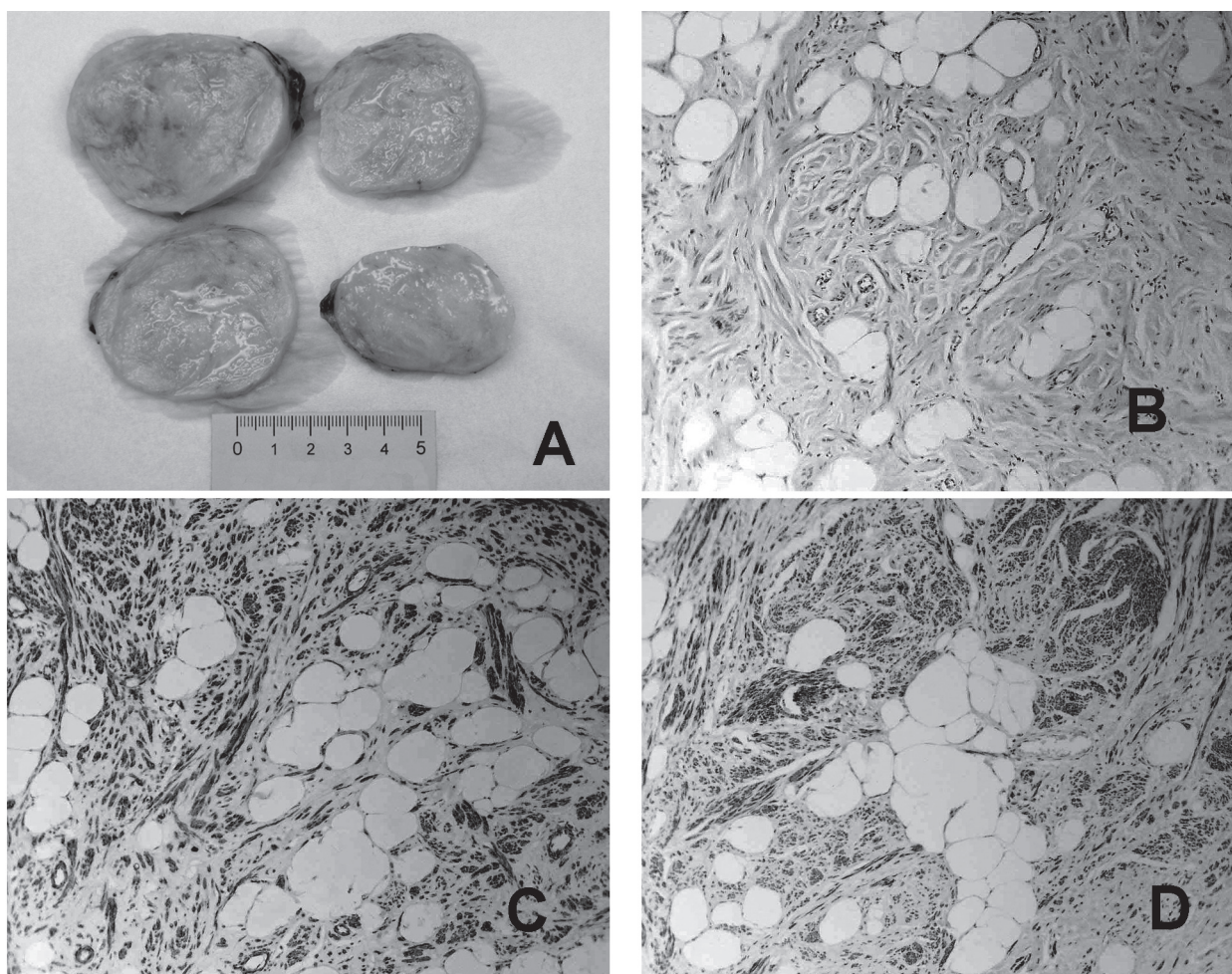


Fig. 1. (A) Gross features of the tumor found in hernial sac; (B) the tumor was composed of uniform smooth muscle cells with spindle-shaped nuclei and mature adipose cells (HE; original magnification X100); (C) smooth muscle cells staining positive for smooth muscle actin (original magnification X100); and (D) tumor cells staining positive for desmin in spindle cells (original magnification X100).

years, three new origins of myolipoma have been reported: breast⁶, orbit⁷ and tethered cord⁸. Retroperitoneum remains the most common site of origin, found in 37% of all cases of myolipoma reported^{4,5}.

This dimorphic tumor is composed of a uniformly and harmoniously distributed variable amount of benign smooth muscle and mature adipose tissue. A distinctive feature of the two main components in this tumor is that lipoblasts, floret-like giant cells, zones of atypia or mitosis, and proliferation of medium-sized arteries with thick muscular wall are not to be found³. Thus, efficient differentiation from other fat-containing masses, such as liposarcoma, lipoleiomyosarcoma, angiomyolipoma, spindle cell lipoma, or leiomyoma with fatty degeneration is possible³⁻⁵.

Retroperitoneal myolipoma is most often misdiagnosed as liposarcoma because the latter neoplasm is the most common soft tissue sarcoma in adults and is most likely to arise from deep-seated, well-vascularized structures such as deep soft tissue of the retroperitoneum⁹. Gross and histological examinations of such a mass unequivocally differentiate these two tumors. Encapsulation and mature adipose tissue without lipoblasts or enlarged eosinophilic cells with atypical nuclei (floret-like cells) are characteristic of myolipoma. However, well-differentiated liposarcoma such as lipoma-like liposarcoma usually contains a predominance of mature adipose cells with relatively few, widely scattered lipoblasts. Here, misinterpretation can result from inadequate sampling^{2,3}.

Immunohistochemical staining using antibodies against vimentin, desmin, alpha-smooth muscle actin, and melanoma is helpful to distinguish tumors². In myolipoma tissue, tumor cells with smooth muscle morphology are diffusely positive for vimentin, desmin, and alpha-smooth muscle actin. Melanoma marker (HMB-45) positivity is typical for tumor cells in angiomyolipoma, a neoplasm frequently associated with tuberous sclerosis, containing conspicuous vessels showing thick muscular walls³.

Myolipoma has been for the first time introduced as a new entity in the World Health Organization (WHO) classification scheme as part of adipocytic tumors, a group in which liposarcomas were placed and categorized. After a major conceptual shift in this tumor group in the 2002 WHO Classification of Tumors of Soft Tissue and Bone, the term well-differentiated liposarcoma has been exclusively applied to those lesions arising in

the retroperitoneum and other surgically unapproachable locations⁴. The latter are poorly circumscribed and, in the overwhelming majority, are ultimately associated with uncontrolled local recurrence, especially after incomplete excision, with the possibility of evolution to higher-grade sarcoma with more aggressive behavior after repeated local recurrences^{4,5,9}. None of the previously reported myolipomas manifested recurrence or metastasis³⁻⁵.

The first article that described myolipoma as a separate entity was the only one that found this neoplasm in abdominal cavity, attached to the abdominal wall¹. To our knowledge, there have been no reports of myolipoma in hernial sac, probably intra-abdominal tumor protruding through weakened sites in the abdominal wall causing irreducible incisional hernia. The mass was pedunculated and totally resected, thus a benign course and good prognosis are expected.

References

1. MEIS JM, ENZINGER FM. Myolipoma of soft tissue. *Am J Surg Pathol* 1991;15:121-5.
2. TAKAHASHI Y, IMAMURA T, IRIE H, *et al.* Myolipoma of the retroperitoneum. *Pathol Int* 2004;54:460-3.
3. BEHRANWALA KA, CHETTIAR K, EI-BAHRAWY M, STAMP G, KAKKAR AK. Retroperitoneal myolipoma. *World J Surg Oncol* 2005;3:72.
4. FLETCHER CDM, UNNI KK, MERTENS F, eds. World Health Organization classification of tumours. Pathology and genetics of tumours of soft tissue and bone. Lyon: IARC Press, 2002:29-30.
5. WEISS SW, GOLDBLUM JR. Enzinger and Weiss's soft tissue tumors, 4th edition. St. Louis: Mosby, 2001:586-8.
6. MCGREGOR DK, WHITMAN GJ, MIDDLETON LP. Myolipoma of the breast: mammographic, sonographic, and pathologic correlation. *Breast J* 2004;10:259-60.
7. NAGAYAMA A, MIYAMURA N, LU Z, *et al.* Light and electron microscopic findings in a patient with orbital myolipoma. *Graefes Arch Clin Exp Ophthalmol* 2003;241:773-6.
8. BROWN PG, SHAVER EG. Myolipoma in a tethered cord. Case report and review of the literature. *J Neurosurg* 2000;92(Suppl): 214-6.
9. INOUE K, HIGAKI Y, YOSHIDA H. Giant retroperitoneal liposarcoma. *Int J Urol* 2005;12:220-2.

Sažetak

SLUČAJNO OTKRIVENI MIOLIPOM UČVRŠĆEN PEDUNKLOM U HERNIJSKOJ VREĆI: PRIKAZ SLUČAJA

P. Šulentić, S. Abdović, J. Filipović i D. Tomas

Prikazuje se slučaj vrlo rijetkog adipocitnog tumora koji je otkriven tijekom korektivne operacije incizijske trbušne hernije. Bolesnica je zbog leiomioma maternice 14 godina ranije podvrgnuta potpunoj abdominalnoj histerektomiji. Tijekom sadašnje operacije zbog incizijske hernije u hernijskoj vreći je otkriven dio tankog crijeva i tumor s peteljkom. Tumor je bio učvršćen za medijalni intraabdominalni peritoneum. Za vrijeme pregleda tumor se prikazao kao potpuno enkapsulirana dimorfna dobroćudna novotvorina sastavljena od zrelih adipocita i dobro diferenciranih glatkomišićnih stanica. Nisu nađeni lipoblasti, divovske stanice nalik cvjetiću, kao ni jezgrena atipija, mitozna ili proliferacija srednje velikih arterija sa zadebljanim mišićnim stijenkama. Stanice tumora bile su negativne na HMB45, estrogen i progesteron. Postavljena je dijagnoza miolipoma. Ovaj tumor se obično pojavljuje kao velika mirujuća masa u retroperitoneumu u odraslih žena i, prema našem saznanju, ovo je prvi prikaz slučaja miolipoma u hernijskoj vreći. Raspravlja se o znakovitim nalazima, diferencijalnoj dijagnostici, prognozi te mogućem podrijetlu ovakve novotvorine.

Ključne riječi: *Leiomiom – komplikacije; Leiomiom – patologija; Novotvorine retroperitoneuma – patologija; Novotvorine retroperitoneuma – kirurgija; Miolipom – dijagnostika; Hernija, abdominalna; Liposarkom – dijagnostika*