

Localization of Mental and Mandibular Foramens on the Conventional and Digital Panoramic Images

Ilkay Peker¹, Kahraman Gungor¹, Mustafa Semiz² and Ibrahim Tekdemir³

¹ Department of Oral Diagnosis and Radiology, Gazi University, School of Dental Medicine, Ankara, Turkey

² Department of Statistics, Faculty of Art and Sciences, Selcuk University, Konya, Turkey

³ Department of Anatomy, School of Medicine, Ankara University, Ankara, Turkey

ABSTRACT

The purpose of this study was to compare the efficiency of conventional and digital panoramic images for localization of mental and mandibular foramens. Six dry edentulous human mandibles were used in the study. Conventional and digital panoramic images were obtained and the vertical and horizontal measurements were performed for localization of mental and mandibular foramens on the images. The correlations between radiographic (conventional and digital) and direct measurements were compared. A measurement error between the radiographic and direct measurements was determined at the level of 1 mm. The measurement errors were generally less in conventional panoramic radiography than digital one. There was statistically strong positive correlation between direct and radiographic measurements. Statistically significant difference was found between radiographic and direct measurements for bone height of mandible in ramus region. According to the results of this study, diagnostic performance of conventional and digital panoramic images seems to be equal for the localization of mental and mandibular foramens. The vertical radiographic measurements are generally reliable and correlated with direct measurements in mandible for conventional and digital panoramic radiography, but the evaluation of bone height in ramus region may not be sufficiently reliable.

Key words: mental foramen, mandibular foramen, panoramic radiography, digipan, anatomic landmarks

Introduction

Mental and mandibular foramens are important anatomic landmarks for many surgical procedures. Also, the mandible and the teeth are typically the best preserved of the skeleton in archeological contexts¹.

The course of the inferior alveolar canal is frequently apparent between the mandibular foramen and the mental foramen. The mental foramen is usually the anterior limit of the inferior alveolar canal which is obvious on radiographs. Its image is quite variable, and may be identified only about half the time, because the opening of the mental canal is directed superiorly and posteriorly².

The mandibular foramen is the proximal opening of the mandibular canal and is usually located on the lingual surface, near the center, of the mandibular ramus. Although the appearance will be altered if the slightly radiopaque lingula is projected over the shadow of the foramen, its image is usually described as radiolucent and

funnel shaped. Due to its position in the ramus, this foramen is seldom seen on periapical films, but it may often be identified on panoramic and lateral oblique films, in which its outline varies from triangular to oval to funnel shaped and its definition varies from faint to prominent³.

Inferior alveolar anesthesia is administered routinely in dental practice and unfortunately it is not always successful. The common cause of failure in this anesthetic procedure is improper placement of the hypodermic needle because of improper evaluation of anatomic landmarks⁴. Accurate localization of the mental and mandibular foramen is extremely important in order to avoid such failures. Restoration of or improvement in form and function without violating important anatomic structures are the most basic goal in the surgical management of any patient⁵. Accurate localization of the mental and mandibular foramens is important to avoid complica-

tions during periapical and orthognathic surgical procedures of the neurovascular structures which pass through the foramens^{6,7}. Radiography is the only available non-invasive method for diagnosis and treatment planning of major surgical procedures of the mandible. Panoramic radiographs are commonly used for screening, diagnosis, and for selecting the best surgical approach^{8,9}.

Digital imaging was first introduced in dentistry for intraoral radiography, but is now widely available or panoramic radiography based on either a CCD or storage phosphor receptor¹⁰. The advantages of digital techniques compared with film techniques are fast communication of images, the small storage space needed and lower contamination of the environment¹¹.

Adobe Photoshop program (Adobe Systems, USA) is an excellent image-editing software program for editing and annotating radiological images intended for presentation and publication according to Adobe Photoshop 7.0 user guide. This program can be used on either MS-Windows (Microsoft, Redmond, WA) or Macintosh (Apple Computers, Cupertino, CA) platforms. There is insufficient publication about use of this program in digital panoramic radiography.

The aim of this study was to compare the measurements of which are performed with Adobe Photoshop (7.0 version) in digital panoramic images and conventional panoramic images for localization of mental and mandibular foramens.

Materials and Methods

Six dry edentulous adult human mandibles were selected from Ankara University (Ankara, Turkey), School of Medicine, Department of Anatomy. The sex and age of these samples were unknown. A total of eight distances four for mental foramen and four for mandibular foramens were chosen in each mandible.

D₁, D₂, D₃ and D₄ distances were measured for localization of the mental foramen.

D₁: Distance from the inferior border of the mental foramen to the inferior border of the mandible^{12,13}.

D₂: Distance from the superior border of the mental foramen to the crest of the alveolar process¹².

D₃: Distance from the anterior border of the mental foramen to symphysis mentalis^{14,15}.

D₄: Distance from the posterior border of the mental foramen to the posterior border of mandibular ramus¹⁵.

The reference points for the location of the mandibular foramens were determined initially¹⁶.

Point A: Posterior limit of the mandibular foramen.

Point B: Posterior edge of the mandibular ramus.

Point C: Anterior edge of the mandibular ramus.

Point D: Superior limit of the mandibular foramen.

Point E: Incisura mandibula in coronoid notch.

Point F: Mandibular inferior border in mandibular ramus

After defining the points in all ramii, measurements of the following distances were made for the localization of the mandibular foramen.

D₅: Distance from point A to point B (posterior vertical ramus width).

D₆: Distance from point B to point C (vertical ramus total width).

D₇: Distance from point D to point E (vertical ramus superior height).

D₈: Distance from point E to point F (vertical ramus total height).

Distances related to mental and mandibular foramens are illustrated in Figure 1.

All images were obtained at Gazi University (Ankara, Turkey), School of Dental Medicine, Department of Radiology. Conventional and digital panoramic images were taken with OP100 (Instrumentarium, Tuusula, Finland) panoramic unit equipment at 57 kV and 2 mA and an exposure time of 17.6 seconds.

Conventional panoramic radiographs were obtained by using 15x30 cm Kodak screen cassette and Kodak T Mat G film (Eastman Kodak Company, Rochester, NY) and digital images were obtained with Digipan receptor. Radiographs were developed in automatic film processor (Velopex, Extra-X, Medivance Instruments Ltd, London, UK and NW107A). One panoramic image is shown Figure 2.

All measurements were made by an oral radiologist of approximately 12 years of experience. Measurements of conventional panoramic radiographs were made by using a digital sliding caliper (Digimatic caliper, Mitutoyo, Andover, UK) and a 2x magnification X-viewer (Luminosa, CSN Industrie, Italy) in a quiet room with subdued ambient lighting. The magnification ratio of the conventional panoramic unit was 1:1.30. Images from the digital system were displayed on a 17 inch monitor in the same ambient lighting. The original image had a 16-bit resolution; the images were assessed on the monitor with 8-bit resolution. Digital panoramic images were imported to a computer software (Adobe Photoshop version 7.0, Adobe Systems, USA) and the measurements were carried out

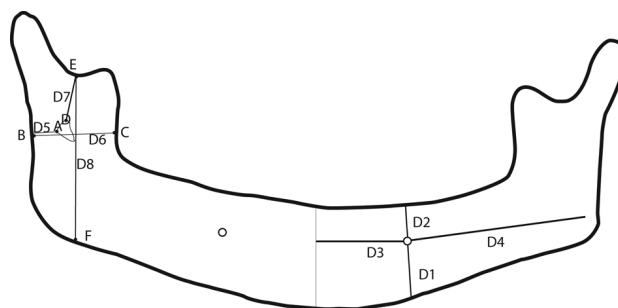


Fig. 1. Distances for localization of mental and mandibular foramens.

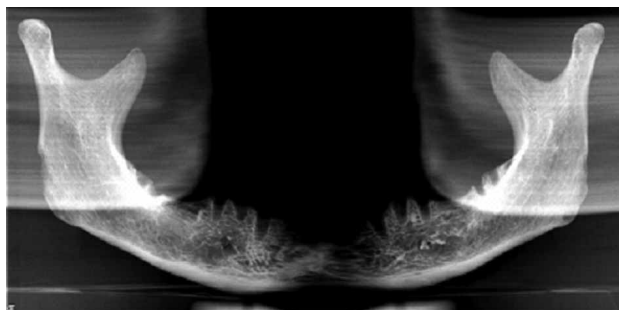


Fig. 2. An example of panoramic image.

by using image enhancement features including adjustment of brightness, contrast, gamma curve and magnification where indicated^{17,18}. The magnification ratio of the digital panoramic unit was 1:1.40.

To simulate a clinical situation, any radiopaque marker was not used as suggested by Kositbowornchai et al.¹⁹. Finally, dry mandibles were measured directly by using the digital sliding caliper. The radiographic measurements which had been made on conventional and digital panoramic images were compared with direct measurements.

Data analysis

Obtained data were statistically analyzed with descriptive analyses, Pearson correlation coefficient, t-test using SPSS software-version 11.5 (SPSS Inc, IL) for Windows. Pearson correlation coefficient was calculated to detect the correlations and the mean differences were calculated by using t-test between radiographic (conventional and digital) and direct measurements. Iota coefficient was calculated for the agreement between radiographic and direct measurements with multivariate measurements²⁰. The interpretation of iota coefficient is similar to the kappa coefficient because iota coefficient is the multivariate version of the kappa coefficient²¹.

Results

Twelve panoramic images were assessed and totally 288, 48 measurements for each mandible were performed in this study. A measurement error between the radiographic and direct measurements was determined at the level of 1 mm (Table 1). The measurement errors between conventional radiography measurements and direct measurements were greater for D₃ and D₈. The measurement errors between digital radiography measurements and direct measurements were greater for D₂ and D₃. The measurement errors in conventional radiography were greater than digital radiography for D₃ and D₈. For D₁, D₂, D₄, D₅, D₆ and D₇, the measurement errors in conventional radiography were less than digital radiography (Table 1).

There was statistically strong positive correlation between direct and radiographic measurements according to Pearson correlation coefficient (Table 2). Statistically significant difference ($p < 0.05$) was found between direct and radiographic measurements for D₇ and D₈ according to t-test (Table 2).

Agreement between direct measurements and radiographic measurements was found to be quite good according to iota coefficient (Table 3).

Discussion

The localization of the mental and mandibular foramens were widely investigated especially in the dental literature^{22,23}. Since panoramic radiography is a radiographic technique for producing a single image of the facial structures that includes both maxillary and mandibular arches and their supporting structures². The efficiencies of conventional and digital panoramic images were investigated using dry mandibles for the localization of the mental and mandibular foramens.

The mental foramen is an important anatomic landmark in dental implant planning. The violation of the mental foramen by an implant may lead to permanent injury to the mental nerve and permanent paresthesia or anesthesia of the lower lip¹³. The measurement error

TABLE 1
THE MEASUREMENT ERRORS BETWEEN RADIOGRAPHIC AND DIRECT MEASUREMENTS

Distances	Conventional panoramic and direct measurements		Digital panoramic and direct measurements	
	Less than or equal 1 mm	Greater than 1 mm	Less than or equal 1 mm	Greater than 1 mm
D ₁	100%	–	83.4%	16.6%
D ₂	100%	–	75.0%	25.0%
D ₃	50.0%	50.0%	75.0%	25.0%
D ₄	92.0%	8.0%	83.4%	16.6%
D ₅	100%	–	100%	–
D ₆	100%	–	83.4%	16.6%
D ₇	100%	–	100%	–
D ₈	50.0%	50.0%	83.4%	16.6%

TABLE 2
THE CORRELATIONS AND THE MEAN DIFFERENCES BETWEEN RADIOGRAPHIC AND DIRECT MEASUREMENTS

Distances	Conventional panoramic and direct measurements				Digital panoramic and direct measurements			
	Correlation coefficient	Comparisons of means			Correlation coefficient	Comparisons of means		
	r	Difference	t-value	p-value	r	Difference	t-value	p-value
D ₁	0.993	-0.0308	-0.375	0.715	0.964	0.0283	0.151	0.883
D ₂	0.999	0.0108	0.146	0.887	0.993	-0.0942	-0.420	0.683
D ₃	0.907	0.4342	1.337	0.208	0.914	0.3292	1.052	0.315
D ₄	0.984	-0.2350	-1.110	0.291	0.987	-0.1492	-0.740	0.475
D ₅	0.979	-0.0600	-0.476	0.644	0.992	0.1633	1.792	0.101
D ₆	0.988	-0.1450	-1.009	0.334	0.978	0.3433	1.630	0.131
D ₇	0.975	-0.3075	-2.332	0.040*	0.989	-0.2033	-2.402	0.035*
D ₈	0.989	-0.7942	3.045	0.011*	0.995	0.4658	2.826	0.016*

* Indicates a statistical difference between two population means at the level of 0.05.

should be less than 1 mm on images made for implant treatment²⁴. Vertical measurements can be performed on panoramic radiographs and the measurement error is smallest in the lower premolar region where the mental foramen is located¹². In this study, the measurement error between the radiographic and direct measurements was calculated at the level of 1 mm and the measurement errors were generally less than 1 mm for all images. Vertical radiographic measurements related with mental foramen were found to be quietly consistent with direct measurements.

Previous studies reported that vertical measurements not requiring high accuracy can be made on conventional panoramic images as long as the patient is positioned properly and the manufacturer's magnification values are considered^{25–31}. However, some studies reported that panoramic radiography is not reliable for evaluation of bone height of mandible^{26,29,30}. The radiographic measurements related with condyle and ramus heights were found to be poorly correlated to direct values in dry mandibles as reported by Turp et al.³¹. Kositbowornchai et al. performed the measurements for localization of lingula in dry mandibles and they found high positive correlations between panoramic and dry skull measurements¹⁹. Additionally, it was reported that vertical and angular measurements are generally reliable and reproducible but horizontal measurements were unreliable in panoramic radiography^{32–34}. The occurrence of magnification and distortion in anterior region was an important disadvantage of panoramic radiography³⁵. In this study, four vertical and four horizontal distance measurements were performed. To simulate a clinical situation, any radiopaque markers were not used as suggested by Kositbowornchai et al.¹⁹. The correlations between radiographic and direct measurements were strongly positive but the lowest correlation was found for horizontal distance measurement in anterior region (D₃). This result may be explained by magnification and distortion in anterior region being greater than posterior region for panoramic radi-

ography. There was statistically significant difference between the means of radiographic and direct measurements for vertical distance measurement in posterior region (Superior and total ramus height = D₇ and D₈) although the correlation was strongly positive. This result is in accordance with previous studies^{26,29,30}. The differences between the studies may be related with several factors such as plane of measurement, experience of examiners and the evaluation criteria.

Adobe Photoshop program can provide reasonably good results when manipulating an image, but there is insufficient publication about use of this program in digital panoramic radiography. Once radiological images are on the Photoshop program, they can be cropped, resized, cut, and pasted to fit side-by-side. Brightness, contrast, and saturation can be adjusted³⁶. It was reported that this program is useful in understanding of normal anatomy and pathologies for panoramic images³⁷. On the other hand, Al-Amad et al.³⁸ reported that Adobe Photoshop program may be difficulties as well as benefits for specific features of its. Contrast, brightness and measurement features of Adobe Photoshop 7.0 using frequently and easily were used for evaluation and manipulation of images in this study.

The majority of studies comparing digital and conventional panoramic radiographs have focused on subjective

TABLE 3
THE AGREEMENT BETWEEN RADIOGRAPHIC AND DIRECT MEASUREMENTS ACCORDING TO IOTA COEFFICIENT

Distances	Agreement level between conventional panoramic and direct measurements	Agreement level between digital panoramic and direct measurements
D ₁ , D ₂ , D ₃ , D ₄	0.9826	0.9783
D ₅ and D ₆ distances	0.9687	0.9835
D ₇ and D ₈ distances	0.9804	0.9867

image quality, but there is insufficient publication which evaluated the localization of mental and mandibular foramens by comparing conventional and digital panoramic images in dental literature. Some studies^{39,40} have found no differences between digital and conventional panoramic radiographs, whereas one study⁴¹ found that digital images from the CCD-based Orthophos Plus unit were inferior to film-based radiographs made with two common panoramic units. It was reported that the accuracy of vertical measurements on digital panoramic images was less than the accuracy of measurements on conventional panoramic images^{30,33,42}. The correlation between digital radiographic and direct measurements was found to be strongly positive for total height of the mandible⁴². Additionally, horizontal and oblique measurements in conventional panoramic radiography were less accurate than vertical measurements³³. In this study, digital panoramic images were found to be slightly inferior to conventional panoramic images for localization of the mental foramen, conventional panoramic images were found to be slightly inferior to digital panoramic images for localization of the mandibular foramen. The correlations between radiographic and direct measurements were strongly positive and very similar as described above for horizontal and vertical distance measurements. In comparison with conventional panoramic images, the percentages of measurement errors which

were greater than 1 mm were found to be higher in digital panoramic images. Only in D₃ and D₈, the measurement error was less in digital radiography than conventional one. These results may be related with the usage of image enhancement features in Adobe Photoshop program and this program may be useful in clinical practice.

In conclusion, the efficiencies of digital and panoramic images seem to be equal for the localization of the mental and mandibular foramens. The vertical radiographic measurements are generally reliable and correlated with direct measurements in mandible for conventional and digital panoramic radiography, but the evaluation of bone height in ramus region may not be sufficiently reliable. The horizontal measurements in mandibular anterior region may be more reliable in digital panoramic radiography than in conventional one. Additionally, Adobe Photoshop program may be useful for enhancement of images in clinical practice. The efficiencies of conventional and digital panoramic images for the localization of several anatomic landmarks should be investigated by comparing other radiographic techniques in preoperative assessment. Also, there is need to numerous studies about the usefulness of Adobe Photoshop program in digital panoramic radiography.

It is essential to accurate positions of the anatomical landmarks are located for both clinicians and anthropologists.

REFERENCES

1. DJURIC M, RAKO CEVIC Z, Coll Antropol, 31 (2007) 379. — 2. GOAZ PW, WHITE SC, Oral Radiology Principles and Interpretation 3rd ed. (Mosby-Year Book, St. Louis, Missouri, 1994). — 3. WOOD NK, GOAZ PW, Differential diagnosis of oral and maxillofacial lesions 5th ed. (Mosby-Year Book, 1997). — 4. HETSON G, SHARE J, FROMMER J, KRONMAN JH, Oral Surg Oral Med Oral Pathol, 65 (1988) 32. — 5. SHANKLAND WE, J Oral Implantol, 20 (1994) 118. — 6. KAFFE I, ARDEIKAN L, GELERENTER I, TAICHER S, Oral Surg Oral Med Oral Pathol, 78 (1994) 662. — 7. CUTRIGHT B, QUILLOPA N, SCHUBERT W, J Oral Maxillofac Surg, 61 (2003) 354. — 8. WOLFORD LW, HENRY CH, Radiol Clin North Am, 31 (1993) 221. — 9. PROFIT WR, WHITE RP: Surgical orthodontic treatment. (Mosby, Toronto 1991). — 10. FARMAN AG, FARMAN TT, Dent Clin North Am, 44 (2000) 257. — 11. MOLANDER B, GRÖNDAHL H-G, EKESTUBBE A, Dentomaxillofac Radiol, 33 (2004) 32. — 12. SOIKKONEN K, WOLF J, AINAMO A, QIUFEI X, J Oral Rehabil, 22 (1995) 831. — 13. CAVALCANTI MGP, YANG J, RUPRECHT A, VANNIER MW, Dentomaxillofac Radiol, 27 (1998) 329. — 14. WANG TM, SHIH C, LIU JC, Acta Anat, 126 (1986) 29. — 15. ERDIL H, GUMUSBURUN E, ADIGUZEL E, OZTURK M, J Anatolian Medicine, 36 (2000) 39. — 16. FONTOURA RA, VASCONCELLOS HA, CAMPOS AE, J Oral Maxillofac Surg, 60 (2002) 660. — 17. BENEDIKTSDOTTIR IS, HINTZE H, PETERSEN JK, WENZEL A, Dentomaxillofac Radiol, 32 (2003) 109. — 18. BENEDIKTSDOTTIR IS, HINTZE H, PETERSEN JK, WENZEL A, Dentomaxillofac Radiol, 32 (2003) 39. — 19. KOSITBOWORNCHAI S, SIRITAPETAWEI M, DAMRONGRUNRUANG T, KHONGKANKONG W, CHATRCHAIWIWATANA S, KHAMANARONG K, CHANTHAOOPLEE T, Surg Radiol Anat, 29 (2007) 689. — 20. JANSON H., & OLSSON U, Educ Psycho Measure, 64 (2004) 62. — 21. JANSON H, OLSSON U, Educ Psycho Measure, 61 (2001) 289. — 22. HETSON G, SHARE J, FROMMER J, KRONMAN J, Oral Surg Oral Med Oral Pathol, 65 (1988) 32. — 23. OGUZ O, BOZKIR MG, West Indian Med J, 51 (2002) 14. — 24. WYATT CCL, PHOROAH MJ, Int J Prosthodont, 11 (1998) 442. — 25. HABETS LL, BEZUR JN, VAN OOLJ CP, HANSSON TL, J Oral Rehabil, 14 (1987) 475. — 26. BATENBURG RH, STELLINGSMA K, RAGHOEBAR GM, VISSINK A, Oral Surg Oral Med Oral Pathol, 84 (1997) 430. — 27. KJELLBERG H, EKESTUBBE A, KILLARIDIS S, THILANDER B, Acta Odontol Scand, 52 (1994) 43. — 28. XIE Q, SOIKKONEN K, WOLF J, MATTILA K, GONG M, AINAMO A, Dentomaxillofac Radiol, 25 (1996) 61. — 29. CATIC A, CELEBIC A, VALENTIC-PERUZOVIC M, CATOVIC A, KUNA T, Coll Antropol, 22 (Suppl) (1998) 139. — 30. CATIC A, CELEBIC A, VALENTIC-PERUZOVIC M, CATOVIC A, JEROLIMOV V, MURETIC I, Oral Surg Oral Med Oral Pathol, 86 (1998) 242. — 31. TURP JC, VACH W, HARBICH K, ALT KW, STRUB JR, J Oral Rehabil, 23 (1996) 395. — 32. LARHEIM TA, SVANAES DB, Am J Otrhod Dentofacial Otrhop, 90 (1986) 45. — 33. LASTER WS, LUDLOW JB, BAILEY LJ, HERSHEY HG, Dentomaxillofac Radiol, 34 (2005) 343. — 34. VAN ELSLANDE DC, RUSSETT SJ, MAJOR PW, FLORES-MIR C, Am J Otrhod Dentofacial Otrhop, 134 (2008) 183. — 35. WYATT CCL, PHOROAH MJ, Int J Prosthodont, 11 (1998) 442. — 36. CHALAZONITIS AN, KOUARIANOS D, TZOVARA J, CHRONOPULOS P, J. Digit Imag, 16 (2003) 216. — 37. WANG X, YANG C, GODDARD G, QIU W, Cranio, 21 (2003) 196. — 38. AL-AMAD S, MCCULLOUGH M, GRAHAM J, CLEMENT J, HILL A, J Forensic Odontostomatol, 24 (2006) 47. — 39. FARMAN TT, FARMAN AG, J Digit Imag, 11 (1998) 169. — 40. KAEPLER G, AXMANN-KRCMAR D, REUTER I, MEYLE J, GOMEZ-ROMAN G, Dentomaxillofac Radiol, 30 (2001) 308. — 41. GJJBELS F, DE MEYER AM, BOU SERHAL C, VAN DEN BOSSCHE C, DECLERCK J, PERSOONS M, JACOBS R, Clin Oral Investig, 4 (2000) 162. — 42. KAMBYLAFKAS P, MURDOCK E, GILDA E, TALLENTS RH, KYRKANIDES S, Angle Orthod, 76 (2006) 388.

K. Gungor

Department of Oral Diagnosis, Oral Medicine and Radiology, School of Dental Medicine, University of Gazi, Ankara, Turkey

e-mail: kahraman@gazi.edu.tr

LOKALIZACIJA MENTALNOG I MANDIBULARNOG FORAMENA NA KONVENCIONALNIM I DIGITALNIM PANORAMSKIM SLIKAMA

S A Ž E T A K

Svrha je ove studije usporediti efikasnost konvencionalnih i digitalnih panoramskih snimki u lokalizaciji mentalnih i mandibularnih foramena. Šest ljudskih mandibula je upotrebjeno u studiji. Snimljene su konvencionalne i digitalne panoramske snimke te su obavljena vertikalna i horizontalna mjerenja za lokalizaciju mandibularnih i mentalnih foramena na slikama. Uspoređene su korelacije između radiografskih (konvencionalnih i digitalnih) te izravnih mjerenja. Određena je pogreška u mjerenju s točnošću od 1 mm. Pogreške u mjerenju bile su općenito manje kod konvencionalne panoramske radiografije nego u digitalne. Postoji statistički jaka pozitivna korelacija između izravnih i radiografskih mjerenja. Statistički značajna razlika nađena je između radiografskih i izravnih mjerenja visine kostiju mandibule u regiji ramusa. Prema rezultatima studije dijagnostička vrijednost konvencionalnih i digitalnih panoramskih slika čini se jednakom za lokalizaciju mentalnih i mandibularnih foramena. Vertikalna radiografska mjerenja su općenito pouzdanija te su odgovarala izravnim mjerenjima mandibule kod konvencionalne i digitalne panoramske radiografije, no evaluacija visine kostiju u regiji ramusa nije dovoljno pouzdana.