

Vertebroplasty for Vertebral Compression Fracture

Saša Rapan¹, Savo Jovanović¹ and Gordan Gulan²

¹ Department of Orthopaedics, University Hospital Osijek, Osijek, Croatia

² Clinic for Orthopaedic Surgery »Lovran«, Lovran, Croatia

ABSTRACT

*The patients with intensive pain caused by the vertebra body fracture were treated by application of bone cement under local or general anesthesia, by means of diascopy through unilateral transpedicular approach. The intensity of pain was followed-up on the VAS scale before surgery, 24 hours after surgery and three months after surgery. The cement was applied in 55 patients (43 women, 12 men). The average age of the tests was 68.43 years (38 to 82 years). Fifty five procedures were implemented on 85 vertebrae, i.e. 32 metastatic fractures and 23 osteoporotic fractures. The procedures were applied on 28 thoracic and 57 lumbar vertebrae. The average VAS before surgery was 8.36 and 2.23 ($p < 0.005$) 24 hours after surgery, and it remained almost unchanged three months later. There were 1 serious complication, a paraparesis caused by the leakage of cement into the spinal canal, which was partially recovered after decompression and rehabilitation treatment, and 2 superficial infections with *S. epidermidis* which were cured by means of antibiotics. By means of Wilcoxon paired test a significant difference was found between the preoperative VAS and the value 24 hours after surgery ($n=55$, $Z=6.451$, $p < 0.00001$) and 3 months after surgery ($Z=6.45$, $p < 0.00001$), while there was a compliance between two VAS measurements after surgery ($Z=1.308$, $p=0.191$) which indicates that the fast pain reduction remained stable during the 3 month follow-up. The vertebroplasty is a safe and efficient surgical method in treatment of compressive vertebrae fractures which do not react to the conventional method of treatment. The achieved analgesic effect 24 hours after surgery is a good predictor of pain intensity 3 months after surgery.*

Key words: vertebroplasty, VAS pain scale, complications

Introduction

Compressive vertebral fracture is a frequent complication caused by osteoporosis and expansion of malignant tumors into the skeleton. Frequency of these fractures increases with age, and they include compression, collapse and wedging of the body causing kyphoscoliosis.

These fractures lead to the significant rate of morbidity and mortality, nourishment disorders, lungs function troubles, lack of self-reliance, increased pains and psychic disorder caused by pains and drugs.

Traditional method of treating vertebrae fractures include the use of narcotics, analgesics, NSA, resting, and the use of orthosis, and in the case of malignancies – hormonal, radiotherapy and chemotherapy. In most patients, the pain is reduced within 2–3 months, while the pain persists in smaller number of cases, so that they make a group where surgery is indicated as well.

Surgery option in the case of compressive vertebral body fractures implies the application of osteosynthetic material and fusion, which is in aged patients accompa-

nied with numerous complications, both due to anesthesia and to the gravity of surgery and quality of bones, and in malignancies, with frequently bad general condition of the patients.

Vertebroplasty is a stabilization surgery achieving its effect by applying PMMA through a needle into the broken vertebral body by means of diascopy^{1–6}.

A number of papers and studies describe vertebroplasty as a safe and efficient method in treatments of pathological fractured vertebrae^{1–10}.

Patients and Methods

In the period from April 2005 to December 2007, 55 patients were treated with a method of vertebroplasty at the Orthopedic Department of the Clinical Hospital Osijek.

The research covered patients with pains in the back caused by osteoporotic vertebral fractures, which did not

react positively to the conservative method of treatment, or caused by a malignant process with or without previously performed hormonal, radio or chemotherapy.

For the purpose of the method efficiency evaluation, all patients filled in the VAS questionnaire with a scale from 1 to 10 before surgery, 24 hours and 3 months after surgery.

Surgery: The patients underwent surgery under local or general anesthesia, if they could not tolerate the local one. Surgery is carried out in a prone position, the fractured vertebra is located by means of diascopy, the operation area is washed and covered, and the skin and subcutaneous tissue are anesthetized with 2% lidocaine when applying local anesthesia.

Through a small skin incision, an 11-gauge needle for bone biopsy is placed in the center of pedicle and then, it is followed-up on diascope and inserted, unilaterally, in LL direction to the first third of the vertebral body. Once we are satisfied with the needle position, PMMA of relevant viscosity is applied in the vertebral body (Figure 1).

After ten minutes, when the surgery is completed, the patient remains in bed for minimum one hour, and 24 hours after surgery the patient is discharged from the hospital, after having filled-in the VAS questionnaire.

Results

In total, 55 patients (43 women and 12 men, aged from 38 to 82) have been tested to pain with VAS, 24 hours and 3 months after surgery. Thus, 55 surgeries were carried out on 85 vertebrae, 32 for malignancy and 23 for osteoporosis. The surgery was performed on 28 thoracic and 57 lumbar vertebrae.

Local anesthesia was applied in 23 and general anesthesia in 32 surgeries.

The average surgery time was 55 (30–80) minutes, and average stay in hospital was about 2 (1–4) days.

The bone cement volume (PMMA) amounted to 3 (1.5–5) mL per vertebra on average.

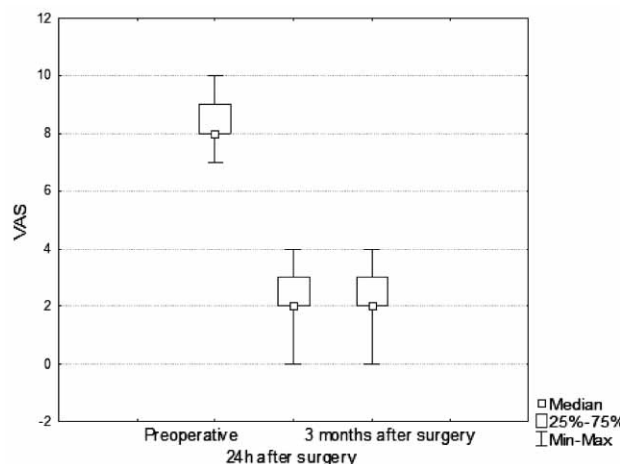


Fig. 2. VAS pain scale before, 24 hours later, and 3 months after the vertebroplasty.

The average pain suffering period prior to surgery was 44 (2–124) days.

Pain reduction was significant, per VAS score from 8.36 ± 0.85 before surgery to 2.23 ± 0.85 (-72.63%) 24 hours later, and 2.072 ± 0.81 , three months after surgery.

The Wilcoxon paired test demonstrated a significant difference between preoperative VAS score and the value measured 24 hours after surgery ($n=55$, $Z=6.451$, $p<0.00001$) and 3 months after surgery ($Z=6.45$, $p<0.00001$), while there is a compliance between two VAS measurements after surgery ($Z=1.308$, $p=0.191$) which indicates that the fast achieved pain reduction remained stable during the 3 month follow-up (Figure 2).

There was 1 serious complication, leakage of PMMA into the spinal canal followed by paraparesis. After urgent decompression and rehabilitation treatment, the female patient was partially recovered. In 2 patients superficial infections with *Staphylococcus epidermidis* occurred, which were cured by peroral administration of antibiotics and lesion toilet.

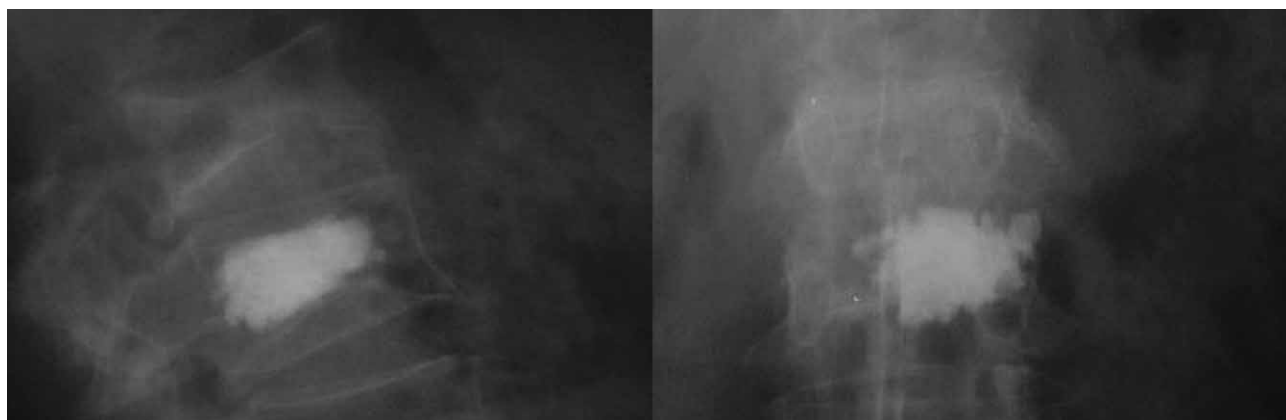


Fig. 1. X-ray taken after the cement application.

Discussion

In the case of pathologically changed bone, a vertebral fracture may result in constant pains despite analgesic and antirheumatic treatment, resting or immobilization. As osteoporotic fractures are connected with older age, and metastatic with poor general condition, beside the pains, the condition is worsened due to the reduced mobility, urinary disorders, depression or neurological disorders. Similarly, because of bad quality of bones, conventional surgery methods of stabilization, osteosynthesis and lumbar fusion had no success. Vertebroplasty is a surgical method for achieving stabilization of fracture in a pathologically changed vertebral body, when due to osteoporosis, tumor or malignancy, the conventional methods of treatment fail.

By this method, stabilization is achieved about 10 minutes after application of cement in the vertebral body, and analgesic effect is either a result of preventing micro-movements or of destruction of nerve ends by thermal reaction during the polymerization of cement. The success of this method of treatment in pain reduction by 75–90% is described by many authors^{1–14}, and our result of pain reduction by approx. 72.63% is in the line with this statement.

This method also causes numerous complications, general and local ones. Frequency of complications is much higher in treatment of malignancy (up to 10%) than in osteoporosis 1 to 3%⁶.

Cotten¹⁵ and Barragan-Campos¹¹, state that cement is frequently leaking into the spinal canal (52%), into the neuroforamen 27.6%, and into the intervertebral discus about 27.6%. The risk of PMMA leakage into the spinal canal correlates with bone destruction, so that the surgery is contra-indicated in more serious destructions of vertebral body¹¹. There is a direct dependence between cement leakage into the spinal canal and the quantity of

cement applied during the surgery on the fractured vertebral body¹⁶. Cement leakage into the inter-vertebral discus increases the risk of new fracture of adjacent vertebral body¹⁷.

In spite of high percentage of cement leakage (0.5–65.6%)¹⁸, only about 7.5% of the cases were symptomatic¹¹ and they respond to conservative treatment with antirheumatics and the use of corticosteroids. Neurological disturbance asking for decompression of spinal canal and cement removal make only 1% of complications^{19–23}.

In our case, there was cement leakage in 23 out of total 85 treated vertebrae (27%); in one case (1.8%) cement leakage into the spinal canal resulted in paraparesis, and then in decompression of spinal canal. Somewhat higher percentage of this complication can be explained by a small series of cases, and that the complication occurred at the mere beginning of surgery, so that it makes a part of the learning curve.

Adequate cement viscosity, exact spinal tap needle position and diascopy during the whole procedure and especially during the application of cement are crucial and they significantly reduce the possibility of having this serious complication.

It can be concluded that, although our group of operated patients was relatively small, and the follow-up period was short, vertebroplasty proved to be a safe, efficient and minimum invasive method for stabilization of fractured vertebra and pain reduction caused by osteoporosis or malignant process. The risk of cement leakage into the spinal canal, as a serious complication, can be reduced by using an advanced operation technique (reduced cement viscosity), more precise procedure indication (better selection of cases) and reduced volume of injected cement.

REFERENCES

1. ANSELMETTI GC, CORGNIER A, DEBERNADI F, REGE D, Radiol Med, 110 (2005) 262. — 2. CHEUNG G, CHOW E, HOLDEN L, VIDMAR M, DANJOUX C, YEE AJ, CONNOLLY R, FINKLSTEIN J, Can Assoc Radiol J, 57 (2006) 13. — 3. VOORMOLEN MH, LOHLE PN, FRNSEN H, JUTTMANN, DE WAAL MALEFIJT J, LAMPMAN LE, Ned Tijdschr Geneesk, 147 (2003) 1549. — 4. FESSL R, ROEMER FW, BOHN-DORF K, Rofo, 177 (2005) 884. — 5. HOCHMUTH K, PROSCHEK D, SCHWARZ W, MACK W, KURTH AA, VOGL TJ, Eur Radiol, 16 (2006) 998. — 6. AFZAL S, DHAR S, VASAVADA NB, AKBAR S, Pain Physician, 10 (2007) 559. — 7. GILL JB, KUPER M, CHIN PC, ZHANG Y, SCHUTT RJR, Pain Physician, 10 (2007) 583. — 8. MC GRAW JK, LIPPERT JA, MINKUS KD, RAMI PM, DAVIS TM, BUDZIK RF, J Vasc Interv Radiol, 13 (2002) 883. — 9. EWANS AJ, JENSEN ME, KIP KE, DE NARDO AJ, LAWLER GJ, NEGIN GA, REMLEY KB, BOUTIN SM, DUNNAGAN SA, Radiology, 226 (2003) 366. — 10. PONGSOIPETCH B, J Med Assoc Thai, 90 (2007) 479. — 11. BARRAGAN-CAMPOS HM, VALLEE JN, LO D, CORMIER E, JEAN B, ROSE M, ASTAGNEAN P, CHIRAS J, Radiology, 238 (2006) 354. — 12. CALMELS V, VALEE JN, ROSE M, CHIRAS J, AJNR Am J Neurorad, 28 (2007) 570. — 13. RYSKA P, REHAK S, ODRAKA K, MAISNAR V, RAMPACH J, MALK V, RENC O, KALTOFEN K, Cas Lek Cesk, 145 (2006) 804. — 14. FOURNEY DR, SCHOMER DE, NADAR R, CHLAN-FOURNEY J, SUKI D, AHRAR K, RHINES LD, GOKASLAN ZL, J Neurosurg, 98 (2003) 21. — 15. COTTON A, DEWATRE F, CORTEZ B, Radiology, 200 (1996) 525. — 16. RYU KS, PARK CK, KIM MC, KANG JK, J Neurosurg, 96 (2002) 56. — 17. LIN EP, EKHOLM S, HIWATASHI A, WESTESSON PL, AJNR Am J Neuroradiol, 25 (2004) 175. — 18. SHAPIRO S, ABEL T, PURVINIS S, J Neurosurg, 98 (2003) 90. — 19. WUU CC, LIN MH, YANG SH, CHEN PQ, SHIH TT, Eur Spine J, 16 (2007) 326. — 20. CHEN YJ, TIN TS, CHEN WH, CHEN CC, LEE TS, Spine, 31 (2006) 379. — 21. TSAI TT, CHEN WJ, LAI PL, CHEN LH, NIU CC, FU TS, WONG CB, Spine, 28 (2003) 457. — 22. CHEN JK, LEE HM, SHIH JT, HUNG ST, Spine, 32 (2007) 358. — 23. LE BJ, LEE SR, YOO TY, Spine, 27 (2002) 419.

S. Rapan

Department of Orthopaedics, University Hospital »Osijek«, J. Huttlera 4, 31000 Osijek, Croatia
e-mail: sasa.rapan@gmail.com

VERTEBROPLASTIKA

SAŽETAK

Ispitanici s jakom boli uslijed loma trupa kralješka liječeni su aplikacijom koštanog cementa, u lokalnoj ili općoj anesteziji, uz pomoć dijaskopije kroz unilateralni transpedikularni pristup. Intenzitet bolova pratili smo VAS skalom prije operacijskog zahvata, nakon 24 sata i tri mjeseca nakon procedure. Aplikacija cementa je učinjena u 55 pacijenata (43 žene, 12 muškaraca). Prosječna životna dob ispitanika bila je 68,43 godina (38 do 82 godine). 55 procedura je izvedeno na 85 kralježaka, 32 zbog malignog oboljenja, a na 23 zbog osteoporoze. Zahvat je učinjen na 28 torakalnih i 57 lumbalnih kralježaka. VAS prijeoperacije iznosio je prosječno 8,36, a nakon 24 sata 2,23 ($p < 0,005$) i ostao je gotovo nepromjenjen nakon 3 mjeseca. Imali smo 1 ozbiljniju komplikaciju, paraparezu uslijed istjecanja cementa u spinalni kanal koja se djelomično oporavila nakon dekompresije i rehabilitacijskog liječenja, te 2 površne infekcije *Staphylococcus Epidermidis* koje su izliječene uporabom antibiotika. Wilcoxonovim testom vezanih parova utvrđena je izrazito značajna razlika između prijeoperacijskog VAS-a i vrijednosti 24 h nakon operacije ($n=55$, $Z=6,451$, $p < 0,00001$) odnosno 3 mjeseca nakon operacije ($Z=6,45$, $p < 0,00001$), dok postoji suglasje u dva mjerenja VAS nakon operacije ($Z=1,308$, $p=0,191$) što upućuje da je brzo postignuto poboljšanje bolova ostalo stabilno tijekom 3 mjeseca praćenja. Vertebroplastika je sigurna, djelotvorna operacijska metoda u liječenju kompresivih prijeloma kralježaka koji ne reagiraju na konvencionalan način liječenja. Postignuti analgetski učinak nakon 24 sata od zahvata dobar je prediktor intenziteta bolova nakon 3 mjeseca od zahvata.