

Concurrent bilateral inguinal and umbilical hernias in a bitch - a case report

Alireza Raayat Jahromi^{1*}, Seifollah Dehghani Nazhvani¹,
Musa Javdani Gandmani¹, and Samira Mehrshad²

¹Department of Surgery, School of Veterinary Medicine, Shiraz University, Shiraz, Iran

²Student of Veterinary Medicine, School of Veterinary Medicine, Shiraz University, Shiraz, Iran

JAHROMI, A. R., S. D. NAZHVANI, M. J. GANDMANI, S. MEHRSHAD:
Concurrent bilateral inguinal and umbilical hernias in a bitch. Vet. arhiv 79, 517-522, 2009.

ABSTRACT

A 3 year old Schianlu bitch with a bilateral swelling in the inguinal region and a small umbilical swelling was referred to the Veterinary teaching hospital, School of Veterinary Medicine, Shiraz University. She had had dystocia with her 3 puppies 7 months earlier. Soft, painless and reducible swellings were palpated in all 3 sites on physical examination. Under general anesthesia all 3 sites were repaired surgically. The left inguinal hernia sac contained the entire uterus along with the broad ligaments and in the right, the omentum was found in the hernia sac. The hernia rings were sutured by simple interrupted suture pattern using Vicryl no. 1. The umbilical hernia sac contained some omental fat with a small ring. The hernial sac was removed and the margin of the abdominal ring was trimmed and the ring was sutured in a similar suture pattern. Fluid and antibiotics were administered immediately after surgery but antibiotics were continued until 5 days post operative. The follow up study for four months revealed no complications.

Key words: bilateral inguinal hernia, umbilical hernia, bitch

Introduction

Hernia is an abnormal protrusion of an organ or tissue through a normal body opening. An inguinal ring defect allows the abdominal contents to enter the subcutaneous space. Its exact etiopathogenesis in small animals is unknown (BOJRAB et al., 1998; PARKS, 1981). The Pekinese appears to be the best model to determine the method of genetic transmission for both defects in the same animal, the Basenji dog for excessive occurrence of both umbilical and inguinal hernia, the Airedale Terrier for excessive occurrence of

*Corresponding author:

Dr. Alireza Raayat Jahromi. Department of Surgery, School of Veterinary Medicine, Shiraz University, Shiraz, P.O. Box 71345-1731, Fars Province, Iran, Phone: +987112286950; Fax: +987112286940; E-mail: Raayat@shirazu.ac.ir

umbilical hernia, the West Highland White Terrier for excessive occurrence of inguinal hernia, and mixed breed dogs for negligible inguinal hernia occurrence (HAYES, 1974). The Pekingese also exhibits a greater incidence of concurrent umbilical hernia (HAYES, 1974). Inguinal hernia in dogs has been classified as congenital or acquired (BOJRAB et al., 1998). Clinical signs often reflect the size of the hernia and the hernia contents and range from a painless inguinal mass to signs related to incarcerated or nonviable small intestine. Diagnosis of inguinal hernia might be accomplished by radiography demonstrating a gas loop filled with intestine or the appearance of an ossifying fetal skeleton after 43 to 45 days of gestation (BOJRAB et al., 1998). An umbilical hernia is generally not a serious hernia as it mainly consists of fatty tissue, which protrudes. Both male as well as female dogs can have an umbilical hernia (PARKS, 1981). Pekingese, Airedale, and Basenji commonly have umbilical hernias (HAYES, 1974). Although herniorrhaphy techniques have been described, data from dogs with inguinal hernia that have undergone surgical repair are limited to case reports and a very small series of dogs with limited follow-up. This report describes a concurrent bilateral inguinal and umbilical hernia in a Schianlu bitch.

Case description

A three year old Schianlu bitch with a bilateral swelling in the inguinal region (prominent in left side) (Fig. 1) and a small swelling in the umbilical region was referred to the Veterinary teaching hospital of the School of Veterinary Medicine of the Shiraz University. She had had dystocia with her 3 puppies 7 months earlier. Clinical examination revealed: normal heart rate, respiratory rate and rectal temperature. General condition, appetite, CRT (capillary refill time) and hydration status were also normal. A soft, non painful and reducible swelling was palpated in all 3 sites on physical examination. The dog was premedicated by Acepromazine (0.05 mg/kg). The anesthesia was induced by Ketamine (5 mg/kg) and diazepam (0.05 mg/kg), then it was intubated and the anesthesia maintained by halothane in oxygen. After preparation of the surgical sites, an incision was made over each inguinal canal separately to allow exposure of the hernial sac. In left side, the whole uterus along with the broad ligaments (Fig. 3) and in the right, omentum was contained in the hernial sac (Fig. 4). Some adhesion between the uterus and the sac was dissected free. All contents were returned to the abdominal cavity by twisting the redundant sac. The sac was transligated and trimmed at the margin of the abdominal ring. The hernial ring was sutured by a simple interrupted suture pattern using No. 0 Vicryl. Enough room was left for crossing the external pudendal vessels and genitofemoral nerve. The subcutaneous tissue was sutured in a simple continuous pattern using No. 0 Vicryl to eliminate dead space. Finally, the skin was closed by No. 0 silk in a subcuticular pattern. A stent suture was placed on each site immediately after the procedure. The umbilical swelling contained some omental fat with a small ring (Fig. 2). The omentum was returned back and the ring was trimmed off from the abdominal wall, then it was sutured by polyglycolic suture no.1 using a simple interrupted pattern. The fascia and the

skin were apposed routinely. Fluid (5% dextrose) was administered during surgery until one hour after the operation. Penicillin (30,000 IU/kg) and streptomycin (10 mg/kg) were administered for 5 days postoperative. The follow up study for four months revealed a sound recovery with no complications.

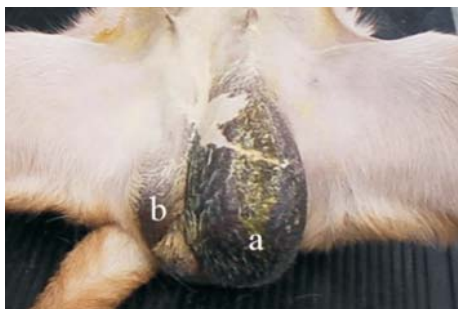


Fig. 1. Bilateral inguinal hernia, larger left (a) and smaller right (b) sacs.

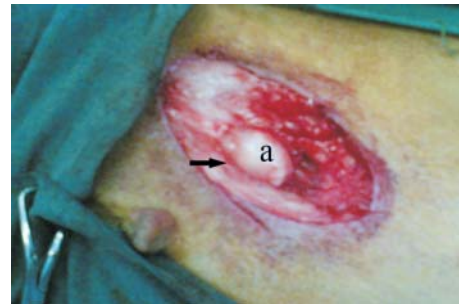

Fig. 2. Umbilical hernia, umbilical hernial ring (arrow), and omental fat (a).

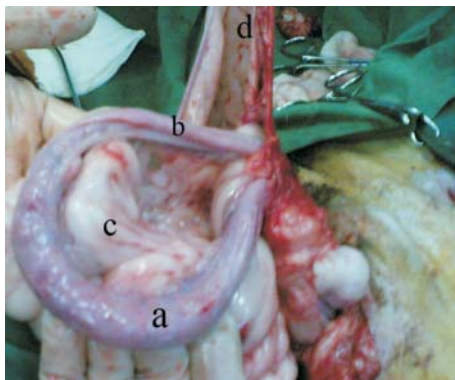


Fig. 3. Contents of the left inguinal sac; uterine body (a), left horn (b), broad ligament (c) and inguinal hernial sac (d).

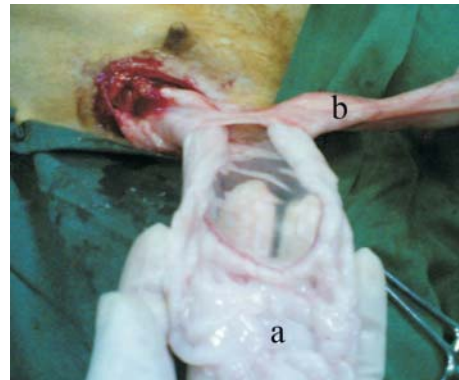


Fig. 4. Right inguinal hernial sac; omentum (a) and inguinal hernial ring (b).

Discussion

Data from dogs with inguinal hernia that have undergone herniorrhaphy are limited (WATERS et al., 1993). Concurrent bilateral inguinal and umbilical hernias have not been reported in dogs. Inguinal hernia has been classified as congenital and acquired. These

hernias are often chronic and do not cause clinical signs until pregnancy or pyometra develops (FOSSUM et al., 2002). WATERS et al. (1993) have identified two groups of dogs with inguinal hernia: dogs with inguinal hernia surgically repaired when they are younger than 4 months of age and those diagnosed when they are older than 4 months of age (WATERS et al., 1993). It is likely that hernias in the first group are congenital. However it is plausible that dogs in the second group include some dogs with congenital hernias that were not identified earlier (WATERS et al., 1993). The dog in our report was 3 years old, and the history of a dystocia with 3 puppies 7 months earlier suggests an acquired cause of her hernias. It seems that the protrusion of the whole uterus, along with the broad ligaments in left inguinal canal, concurrent with adhesions to the sac may be explained by the distinct role of the pregnancy and parturition pressures worsening the hernias and development of clinical signs too. The risk for nonviable small intestine in dogs with longstanding inguinal hernia is relatively low (less than 5%). This may mean that small hernias go unnoticed until pain or vomiting caused by mechanical or vascular obstruction of the intestine occur. Longstanding hernias are more likely to be large and unnoticed; large hernias are less likely to become incarcerated than small hernias. A role for estrogens in the etiology of inguinal hernia has been postulated because spayed females with acquired inguinal hernia have not been reported (HAYES, 1974). Experimental evidence suggests that sex hormones may influence the development of inguinal hernia in mice. The role of trauma in the development of inguinal hernia remains unclear. The contribution of other factors, such as tensmus, vigorous physical activity, or obesity, has not been investigated. Inguinal hernias are reportedly rare in male dogs. Congenital inguinal hernia in dogs is more common in males than females (WATERS et al., 1993). The prevalence of perineal hernia in male dogs with inguinal hernia has not been reported at a high rate which suggests that dogs with inguinal hernia are at increased risk for hernias in other locations (FOX, 1963; FOSSUM et al., 2002; HAYES, 1974; SMEAK, 1985). Due to the absence of incarceration and intestinal perforation or leakage in this reported case, the prognosis was evaluated to be good.

Unilateral hernias are much more common than bilateral hernias. Bilateral hernias seem to occur more frequently in young dogs. Despite the low prevalence of bilateral hernias, careful palpation of the contra lateral inguinal region for occult hernias is recommended. Surgical management of inguinal hernia consists of identification of the hernia sac, assessment of the viability of the hernia contents, surgical resection of nonviable tissue, herniorrhaphy, and, in some instances, neutering. The surgical approach in this case was through the inguinal region, although a midline approach in female dogs is common, since it facilitates examination of both inguinal rings (WATERS et al., 1993). Intraoperative pneumoperitoneography has been used as an alternative to surgical exploration in the detection of occult contralateral hernias in children (HARRISON et al., 1990). This technique has not yet been described in Veterinary literature. Herniorrhaphy by simple interrupted or

mattress sutures has been reported as effective. Use of multifilament sutures increased the incidence of infection after inguinal herniorrhaphy in humans (PARKS, 1981). Omentum is reportedly the most common organ present in canine inguinal hernia (BOJRAB et al., 1998; FOSSUM et al., 2002; GRIER et al., 1971; WATERS et al., 1993); the omentum was also the main content of the right inguinal sac in this case too. The presence of the omentum may account for the asymptomatic nature and benign course of inguinal hernia in many dogs. However, the omentum may occasionally become incarcerated, resulting in clinical signs that include pain and depression (WATERS et al., 1993). The uterus within a hernia may limit the movement of the small intestine into the hernia; such a hernia is likely to be relatively large, and large hernias are associated with less risk for incarceration. The whole uterus, along with the broad ligaments, was present in the left inguinal sac in this case, without any signs of incarceration although there was some adhesion to the sac. Small intestine viability is an important factor in determining whether herniorrhaphy is an elective or an emergency procedure. Complications in dogs treated surgically for inguinal hernia are incisional infection, wound dehiscence, hematoma, seroma, excessive postoperative swelling, hernia recurrence, sepsis or peritonitis and death. The reported case did not show any form of complications having been monitored for four months.

References

- BOJRAB, M. J., G. W. ELLISON, B. SLOCUM (1998): Current Techniques in Small Animal Surgery. 4th ed. Williams & Wilkins. pp. 552-554.
- FOX, M. W. (1963): Inherited inguinal hernia and midline defects in the dog. J. Am. Vet. Med. Assoc. 143, 602-604.
- FOSSUM, T. W., S. H. CHOYL, A. H. DOLAND, L. J. ANN, B. S. HOWARD, D. W. MICHAEL (2002): Small Animal Surgery. 2nd Ed., Mosby Inc Missouri. pp. 261-267.
- GRIER, R. L., J. D. HOSKINS, J. D. WAHLSTROM (1971): Inguinal hernia and Richter's hernia in a dog. J. Am. Vet. Med. Assoc. 159, 181-183.
- HARRISON, C. B., G. W. KAPLAN, H. C. SCHERZ, M. G. PACKER (1990): Diagnostic pneumoperitoneum for the detection of the clinically occult contralateral hernia in children. J. Urol. 144, 510-511.
- HAYES, H. M. Jr. (1974): Congenital umbilical and inguinal hernias in cattle, horse, swine, dogs, and cats: risk by breed and sex among hospital patients. Am. J. Vet. Res. 35, 839-842.
- PARKS, J. (1981): Herniation. In: Pathophysiology in Small Animal Surgery. (Bojrab MJ, ed.). Philadelphia: Lea & Febiger. pp. 420-424.
- SMEAK, D. D. (1985): Caudal Abdominal Hernias. In: Textbook of Small Animal Surgery. (Slatter DS, ed.). Philadelphia: WB Saunders. pp. 862-869.
- WATERS, D. J., R. G. ROY, E. A. STONE (1993): Retrospective study of inguinal hernia in 35 dogs. Vet. Surgery 22, 44-49.

JAHROMI, A. R., S. D. NAZHVANI, M. J. GANDMANI, S. MEHRSHAD: Istodobna bilateralna ingvinalna i pupčana kila u kuje. Vet. arhiv 79, 517-522, 2009.

SAŽETAK

Kuja pasmine Schianlu u dobi od tri godine s bilateralnom oteklinom u ingvinalnom području i slabom oteklinom u pupčanom području dovedena je na pregled na kliniku Veterinarske škole Sveučilišta Shiraz u Iranu. Sedam mjeseci ranije s poteškoćama je oštenila tri šteneta. Blaga, bezbolna i reponibilna oteklina palpirla se na sva tri spomenuta područja. Sva tri područja podvrgnuta su operativnom zahvatu pod općom anestezijom. U lijevoj ingvinalnoj hernijalnoj vreći nalazila se cijela maternica zajedno sa širokim ligamentima, a u desnoj omentum. Hernijalni prsteni bili su sašiveni jednostavnim prekinutim šavom uporabom vikrila br. 1. Pupčana hernijalna vreća sadržavala je nešto masti omentuma, a imala je mali prsten. Hernijalna vreća bila je uklonjena, a rubovi trbušnog prstena resecirani i sašiveni jednostavnim šavom. Tekućina i antibiotici bili su primijenjeni netom nakon kirurške obradbe s tim da su antibiotici bili davani tijekom pet dana nakon operacije. U kuje nisu bile ustanovljene komplikacije tijekom šest mjeseci postoperativnog promatranja.

Ključne riječi: obostrana ingvinalna kila, pupčana kila, kuja
