

# Human osseal remains from a medieval cemetery near Königsberg Cathedral (Kaliningrad, Russia)

• Zinoviev AV •

Zoology Division, Tver State University, Tver, Russia

**Address for correspondence:**

Andrei V. Zinoviev,  
Tver State University,  
Faculty of Biology,  
Zoology Division,  
Chaikovskogo pr. 70a  
170002 Tver, Russia.  
E-mail: [m000258@tversu.ru](mailto:m000258@tversu.ru)

**Bull Int Assoc Paleodont. 2009; 3(2):14-27.**

---

**Abstract**

This paper describes the osseal remains of fourteen human individuals discovered near Königsberg Cathedral (Kaliningrad, Russia). Data on age at death, stature, diseases and trauma is provided. The possible close kinship of several buried is hypothesised.

**Keywords:** Archaeoanthropology; Kaliningrad; Königsberg, Medieval Cemetery, Cathedral; Kinship

---

**Introduction**

The Königsberg Cathedral, a brick Gothic period building, was built on the Kniephof Island of the former capital of eastern Prussia between 1333 and 1380 (Figure 1). It soon became final resting place to Albert, Duke of Prussia, and some of his relatives, as well as other dignitaries. At the time there was custom to bury individuals of lower rank outside the cathedrals themselves (1). No such graves have been preserved until recent times, aside from the grave of the famous German philosopher Immanuel Kant, whose remains were removed from the Cathedral in 1880. In 2008 during the course of reconstruction work a small area of the medieval cemetery was exposed, north-west of the Cathedral (Figure 1). Preliminarily dated to the 15th century, it contained the skeletal fragments of fourteen individuals buried according to Christian tradition with the heads pointed to the West. Marshy soil, on which the Cathedral was once built, preserved the bones in relatively good condition (Figure 2). Since research into the biological anthropology of the medieval population of Königsberg is scarce if present at all, this report could be considered one of the first steps in this direction.




Figure 1 Königsberg Cathedral from the west. White arrow points to the place of excavations.



Figure 2 Part of the excavations pit with the skeleton, protruding from the wall (white arrow).

### Materials and methods

The subjects of this research were fourteen relatively well preserved human skeletons of varying completeness (Figure 3). The fragmentation of some of the skeletons due to the restricted size of the excavation pit made the stature determination less precise. This, however, did not affect sex determination as the pelvic bones were relatively well preserved in most cases (2, 3). The sex of the 4-to-6-month-old child was not determined due to the lack of reliable methods. A number of approaches were employed in determining the age each individual. Apart from basic methods provided by Alekseev (4), some additional techniques were also used (5-15). The most precise data on the age of those buried was obtained for individuals with available skulls (16-22). Premature skulls gave even further precision in age determination due to the ongoing processes of tooth eruption (23-25). Stature estimation was based on a number of methods, provided in the work of Alekseev (4) and later authors (26-37). An original computer program "Stature of Buried" (2007), developed at the Physics-Technical Faculty of Tver State University, has been used to find an optimal value for the stature of buried individuals.

The skeletons in Figure 3 have been vectorized by the author in Corel Draw 10. Forms for vectorization have been generously provided by Thierry Vette (France).

### Results and Discussion

Data on the humans buried near Königsberg Cathedral is summarized in Table 1. Along with initial numbers given to burials during the excavations (column "Initial Number") we introduced additional ones (column "No") to count heavily disturbed burials. The red and blue fonts in Table 1 indicate possible kinship between corresponding buried.

Figure 4 shows the distribution of buried individuals according to their age at death. Although it is not possible to generalise due to the small sample size, this data can add to our knowledge of population demographics in the medieval capital of Eastern Prussia. The buried remains of men outnumber those of women – a situation common for medieval and more recent cemeteries studied elsewhere (for overview, see 38-40). The situation can locally be related to the proximity of the cathedral where clergymen were primarily buried. This can increase the average age at death since it was not unusual for clergymen to live longer than for other members of contemporaneous society (41). The height estimates (average for men - 168 cm; for women – 157 cm) along with descriptions provided below can be used in broader scale anthropological research.

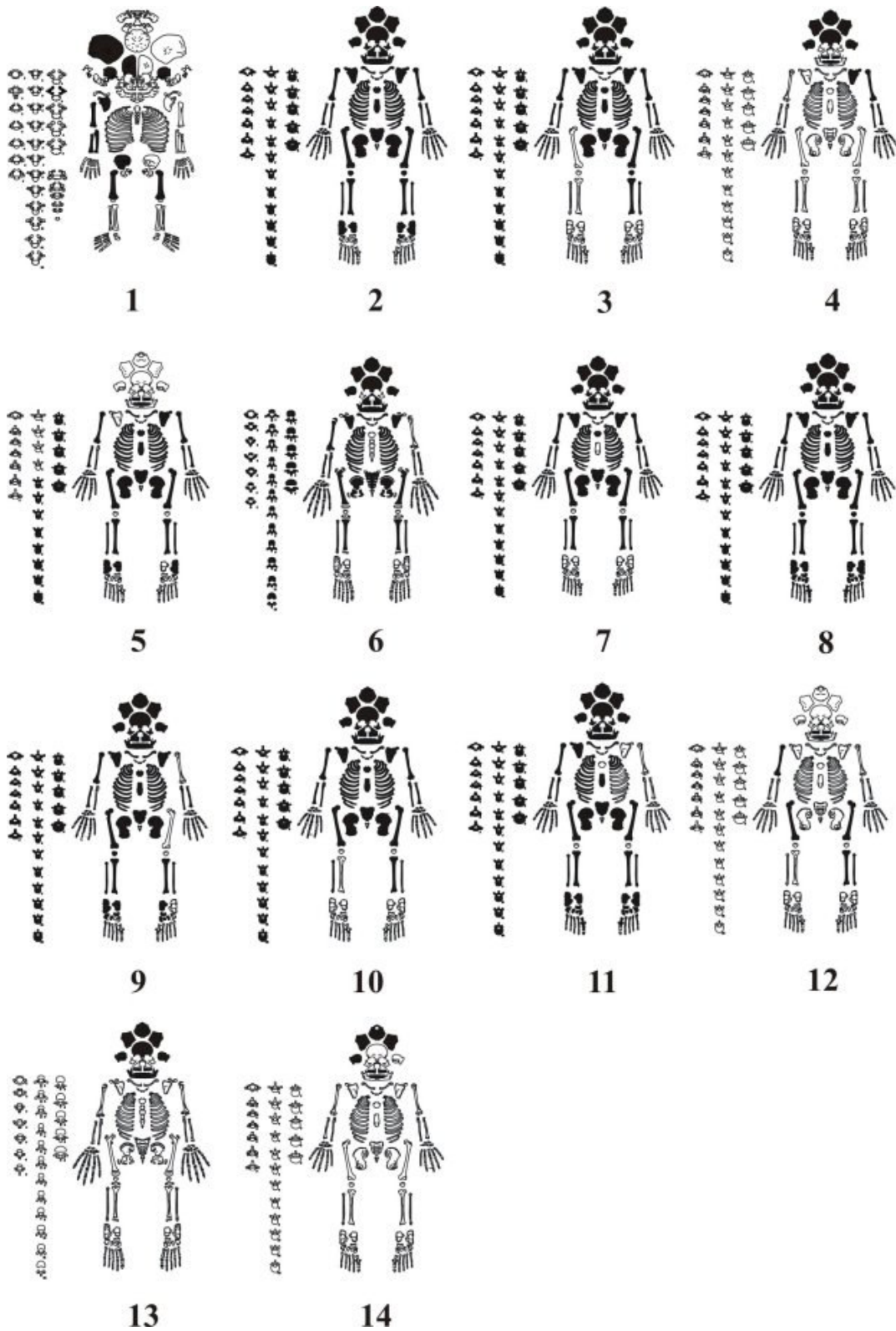


Figure 3 Scheme, showing the completeness of skeletons  
(bones available for the study are filled in with black).

Burial 1. Skeletal fragments of the four-to-six-month-old child. Extremely fragmentary, the skeleton did not allow for even a rough estimate of sex.

Burial 2. Skeleton of a man aged 35-40 years. The dental system is in relatively good condition with only M1sin fallen out during the man's lifetime (Figure 4A). The presence of dental calculus, especially strongly developed on lingual surfaces of mandibular incisors and molars points to insufficient oral hygiene. The death of the individual could have resulted from prolonged sepsis in the central part of the right ulna (Figure 4B). This sepsis caused by fracture of the mentioned bone prevented it from knitting and healing (Figure 4C).

Burial 3. Skeleton of a man aged 35-40 years. In contrast to the previously described individual's remains, the dental system of this man was in far worse condition. Under a similar degree development and distribution of dental calculus, this man had lost I1sin and M3sin during the course of his life. P2dex was almost completely destroyed by caries. The inflammation caused by this caries led to the resorption of the maxillary alveolar bone in the region of the anterior root of M1dex (Figure 5).

Burial 4. Neurocranium and bones of left arm belonging to 23-to-25-year-old man. The occipital bone has pronounced asymmetry, with its left part best developed (Figure 6A).

Burial 5. Fragmentary skeleton of a man aged 40-45 years. This is the tallest individual in the sample.

Burial 6. Skeleton of a child aged 7-8 years. The length of the clavicle shows that it was most probably a boy. Initial caries was discovered on the buccal surfaces of both mandibular permanent first molars (Figure 7).

Burial 7. Skeleton of a woman aged 60-70 years. She had lost all the molars during her life, except one, M1dex (Figure 8). Her skull has a shallow impression going along the sagittal suture (Figure 9A). There are almost no traces of profound osteochondrosis, which is quite rare for an individual of this age.

Burial 8. Unusually robust skeleton of a 28-to-32-year-old woman. The crowns of M1dex et sin and P2sin were destroyed by caries.

Burial 9. Skeleton of 50-55 years old man. Although all the teeth were present, the high degree of tartar development and alveolar bone changes due to periodontitis indicates insufficient dental hygiene. The first sacral vertebra of the individual is unusually tilted backwards. His tibiae bear traces of osteogranulomatosis, best developed on the left tibia (Figure 11). This disease might have been the cause of death.

Burial 10. Skeleton of an old woman aged 60-65 years. Normally lacking wisdom teeth, which is not unusual for women (42), during her life she lost M1dex et sin and (M1P2) dex. There is a shallow impression going along the sagittal fissure similar to that found in woman from the Burial 7 (Figure 9B). Besides the moderately developed osteophytes in lumbar region of the vertebral column, she had osseal abnormalities in the region of the femoral head of the right femur (Figure 12A). This impaired movement of the right leg.

Burial 11. Skeleton of a man aged 35-40 years. The full set of teeth is present, although dental calculus and periodontitis (Figure 13) betray insufficient dental hygiene, as in previously described cases. The occipital bone of the individual has similar asymmetry to that observed in the individual

from Burial 4 (Figure 6B). The tenth and twelfth vertebrae of the thoracic region bare pronounced osteophytes. The degree of their development is most probably related to trauma, which caused the compression of the body of the last thoracic vertebra (Figure 12B).

Burial 12. Some limb bones of the 30-35 year-old man.

Burial 13. Fragment of skull of the 7-19 year-old girl.

Burial 14. Fragment of skull of the 55-65 year-old man (?).

Table 1 Data on individuals buried near Königsberg Cathedral.

No	Initial Number	Sex	Age (years)	Age Group	Height (cm)
1	1	-	0,3-0,2	Infantilis I	-
2	2	♂	35-40	Maturus	164±1
3	3	♂	35-40	Maturus	172±1
4	4	♂	23-25	Adultus	164±1
5	5	♂	40-45	Maturus	178±1
6	6	♂	7-8	Infantilis II	-
7	7	♀	60-70	Senilis	158±1
8	8	♀	28-32	Adultus	158±1
9	9	♂	50-55	Maturus	166±1
10	10	♀	60-65	Senilis	157±1
11	11	♂	35-40	Maturus	163±1
12	disturbed	♂	30-35	Adultus	170±1
13	disturbed	♀	17-19	Juvenis	-
14	disturbed	♂?	55-65	Senilis	-

Red and blue fonts in the table designate possible kinship between corresponding buried.

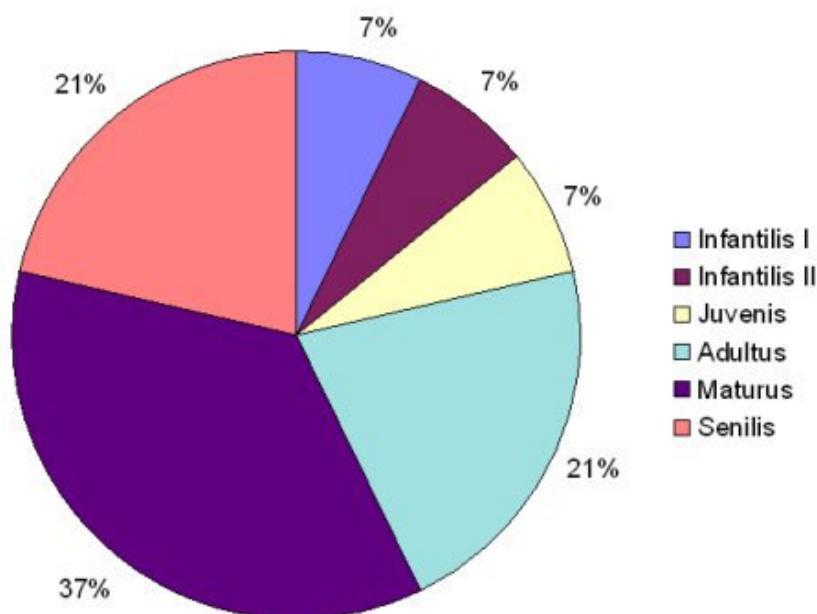


Figure 4 Distribution of buried according to age categories.

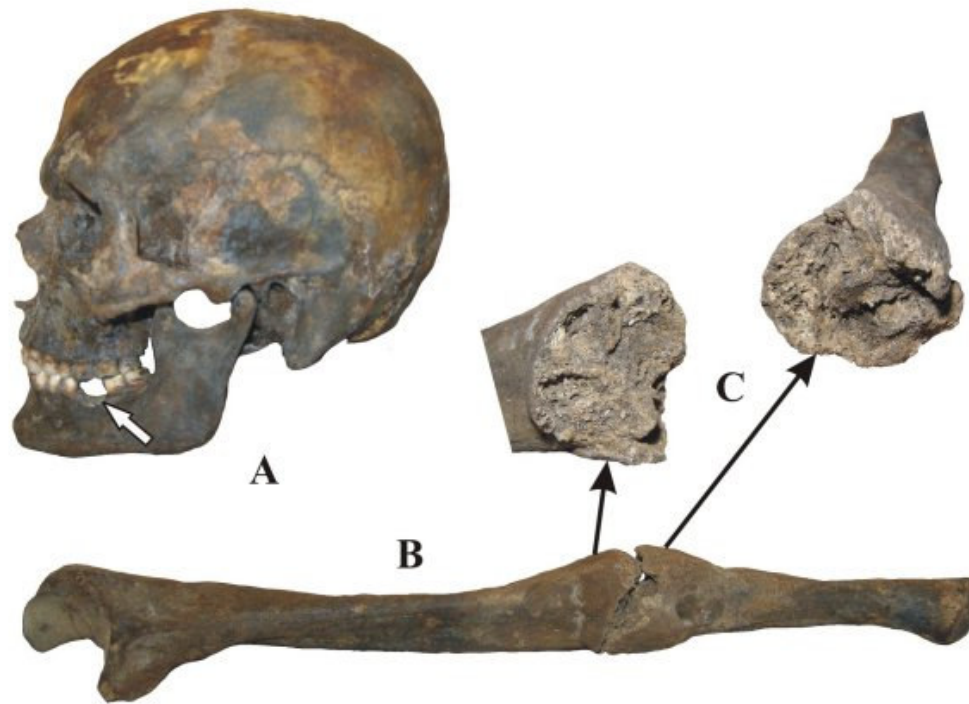


Figure 5 Skull (A) and right ulna (B, C) of the man aged 35-40 years from Burial 2. Note the absence of M1sin (white arrow) and the sepsis occurring upon fracture of the ulna, which prevented parts of this bone from knitting.

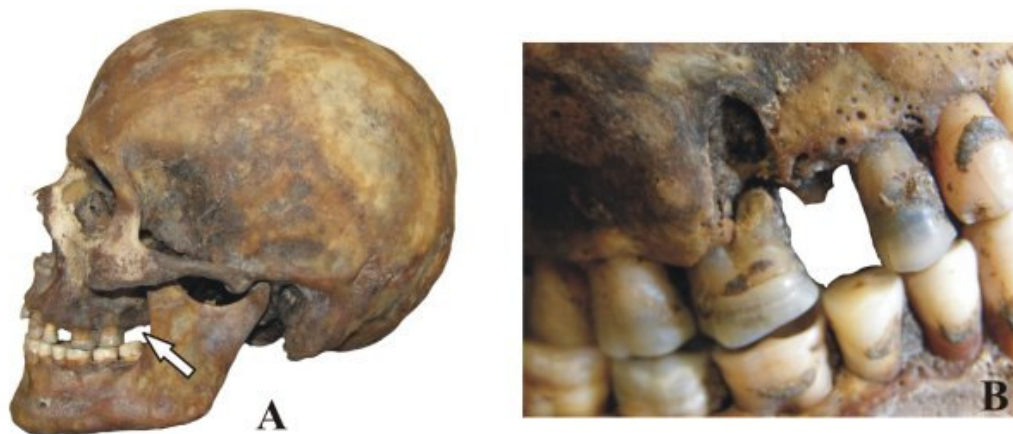

Figure 6 Skull of the man aged 35-40 years from Burial 3. Note M3sin had fallen out during this man's lifetime (A: white arrow) and P2dex crown of which had been destroyed by caries (B).

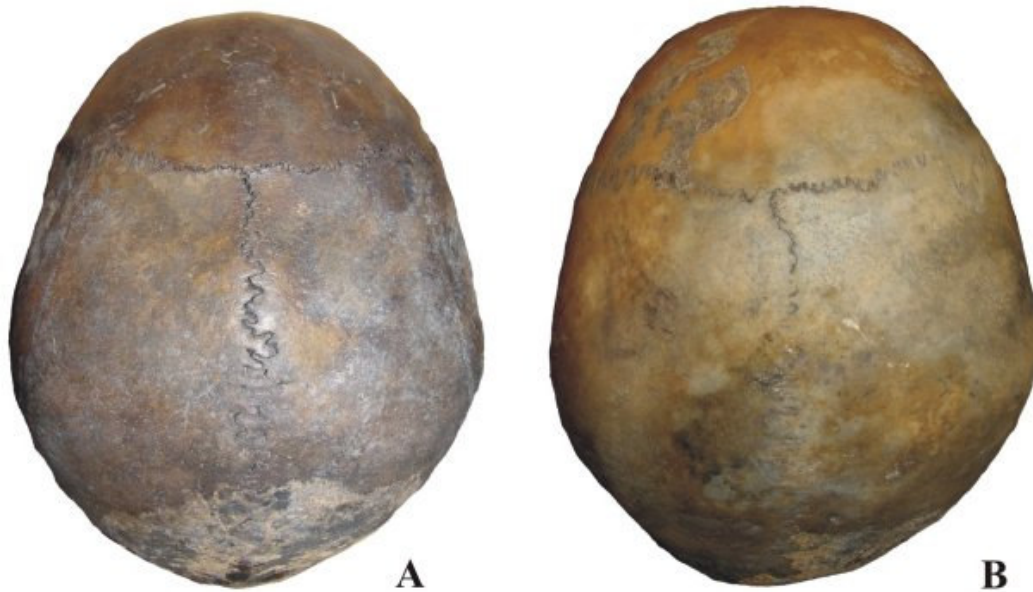


Figure 7 Similar neurocranial asymmetry suggests kinship between the man aged 23-25 years from Burial 4 (A) and the man aged 35-40 years from Burial 11 (B).

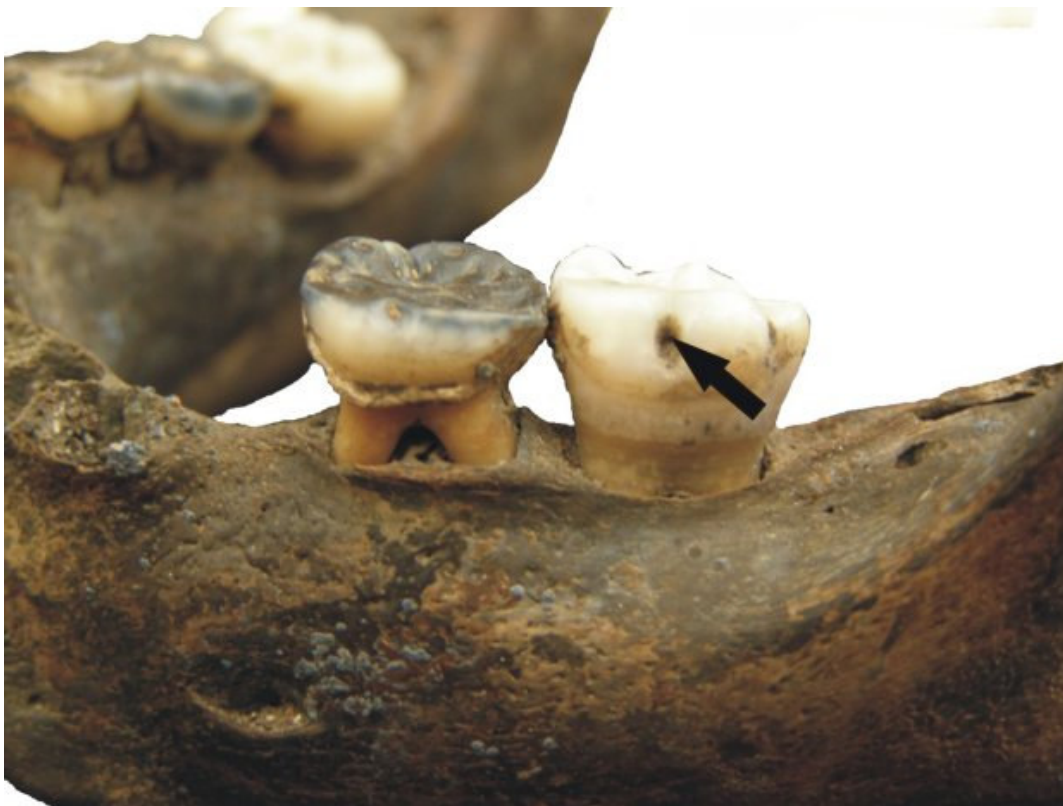

Figure 8 Caries on the buccal surface of the first left permanent molar of a boy aged 7-8 years.



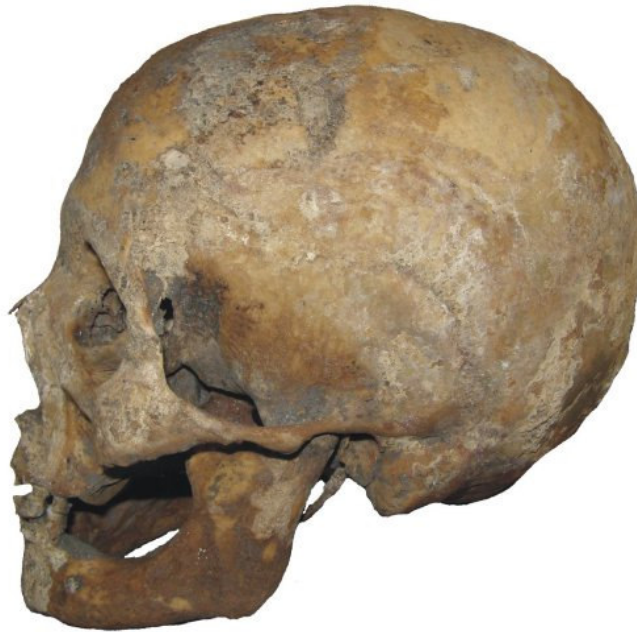

Figure 9 Skull of a 60-70-year-old woman. Note the absence of molars and resorption of the corresponding alveolar bone.

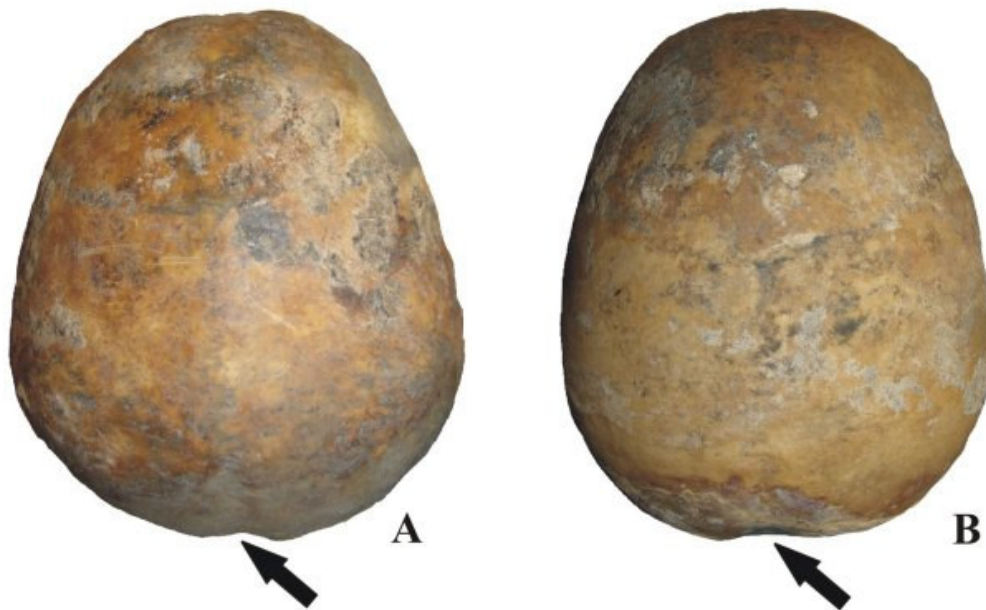


Figure 10 Neurocrania of two women from Burial 7 (A) and Burial 10 (B) showing similar impressions along the sagittal fissure (black arrows), suggesting the kinship between the buried.



Figure 11 Tibiae and fibulae of a man aged 50-55 years with traces of osteogranulomatosis.

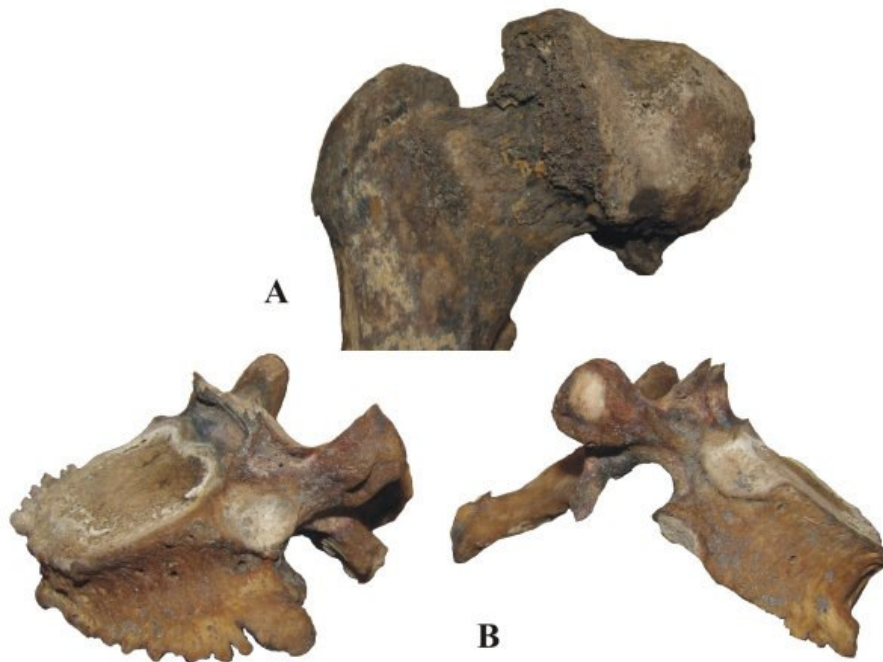
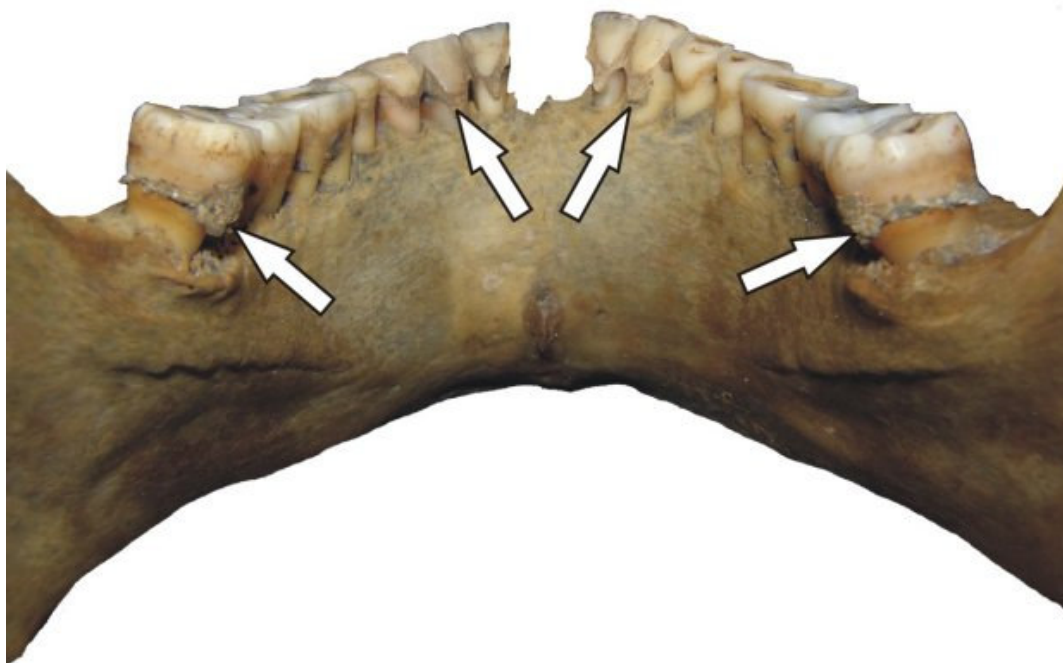


Figure 12 Osteophytes on the caput femoris of the right femur belonging to a woman aged 60-65 years (A) and the thoracic vertebrae of a man aged 35-45 years (B) (the body of the left vertebra is compressed due to trauma).



*Figure 13 Dental calculus and periodontitis on the lower jaw of the man from Burial 11.*

### **Conclusion**

Despite the very small size of the sample, it still shows that:

1. Despite the development of dental calculus which increased with the age, caries was not quite common among those buried near the Cathedral (in comparison with data in 43). This points to the presence of certain dental hygiene, although insufficient.
2. The presence of similar morphological cranial traits in some individuals might reveal their close kinship.
3. The obtained data should be extrapolated with care, keeping in mind possible peculiarities related to the social status of buried near the Cathedral.

### **Acknowledgements**

I am grateful to the Head of the Sambian Archaeological Team of the Russian Academy of Sciences - Alexander Khokhlov (Tver Archaeological Research and Restoration Centre) and to Boris Meleshko (Institute of Archaeology of the Russian Academy of Sciences, Moscow) for providing the material. I also thank Konstantin Skvortsov (Head of Archaeology Division, Kaliningrad Museum of History and Art) for his helpful participation in this study.

**References**

1. Gordon B, Marshall P. The place of the dead. Death remembrance in late medieval and early modern Europe. Cambridge: Cambridge Univ. Press; 2000.
2. Kelley MA. Phenice's visual sexing technique for the os pubis: A critique. *Am J Phys Anthropol* 1978; 48(1):121-2.
3. Phenice TW. A newly developed visual method of sexing the os pubis. *Am J Phys Anthropol* 1969; 30(2):297-301.
4. Alekseev VP. [Osteometry]. Moscow: Nauka; 1966.
5. Todd T. Age changes in the pubic bones, I: the white man pubis. *Am. J. Phys. Anthropol.* 1920; 3(3):285-334.
6. Brooks ST. Skeletal age at death: The reliability of cranial and pubic age indicators. *Am J Phys Anthropol* 1955; 13(4):567-97.
7. Bass WM. Human osteology: A laboratory and field manual. Columbia: Missouri Archaeological Society; 1995.
8. Brooks S, Suchey J. Skeletal age determination based on the os pubis: a comparison of the Acsadi-Nemesken and Suchey-Brooks methods. *Human Evol* 1990; 5:227-38.
9. Buikstra J, Ubelaker DH. Standards for data collection from human skeletal remains. *Proc Seminar Field Mus Nat Hist*; 1994; Fayetteville. Arkansas: Arkansas Arch. Surv. Res. Ser.; 1994.
10. Haglund WD, Galloway A, Simmons T. Practical forensic anthropology of human skeletal remains recovery analysis & resolution. Crc Press; 2002.
11. Mays S. The archaeology of human bones. London: Routledge, an imprint of Taylor & Francis Books; 1998.
12. Schmitt A. Age-at-death assessment using the os pubis and the auricular surface of the ilium: a test on an identified Asian sample. *Int J Osteoarch* 2004; 14(1):1-6.
13. Lovejoy CO, Meindl RS, Pryzbeck TR, Mensforth RP. Chronological metamorphosis of the auricular surface of the ilium: a new method for the determination of adult skeletal age at death. *Am. J. Phys. Anthropol.* 1985; 68(1):15-28.
14. Kurki H. Use of the first rib for adult age estimation: a test of one method. *Int J Osteoarch* 2005; 15(5):342-50.
15. Rissech C, Estabrook GF, Cunha E, Malgosa A. Using the acetabulum to estimate age at death of adult mans. *J. Forensic Sci.* 2006; 51(2):213-29.
16. Alekseev VP, Debets GF. [Cranioemetry. Methods of Anthropological Research]. Moscow: Nauka; 1964.
17. Zvyagin VN. [Age morphology of human cranial sutures (to the methods of age forensic age determination)]. PhD thesis. Moscow: 1971.
18. Johanson G. Age determination from human teeth. *Odontol Rev* 1971; 22(Suppl. 21):1-126.
19. Tschernyavskaya ZP. [Teeth wear age determination in forensic medicine]. PhD thesis. Leningrad: 1983.
20. Walker PL, Dean G, Shapiro P. Estimating age from tooth wear in archaeological populations.

- Kelley M, Larsen CS, editors. *Advances in Dental Anthropology*. New York: Alan R. Liss; 1991. p. 169-78.
21. Solheim T. A new method for dental age estimation in adults. *Forensic Sci. Int.* 1993; 59(2):137-47.
22. Lampe, Rötzscher. Age determination from adult human teeth. *Med Law* 1994; 13(7-8):623-8.
23. Schour I, Massler M. *Development of the Human Dentition*. Chicago: American Dental Assoc.; 1944.
24. Mamonova NN, Romanova GP, Kharitonov VM. [Preliminary processing and determination of anthropological material in the field. *Methods of field archaeological research*]. Moscow: Nauka; 1989.
25. DeVito C, Saunders SR. A discriminant function analysis of deciduous teeth to determine sex. *J. Forensic Sci.* 1990; 35(4):845-58.
26. de Mendonca MC. Estimation of height from the length of long bones in a Portuguese adult population. *Am J Phys Anthropol* 2000; 112(1):39-48.
27. Duyar I, Pelin C. Body height estimation based of tibia length in different stature groups. *Am J Phys Anthropol* 2003; 122(1):23-7.
28. Duyar I, Pelin C, Zagyapan R. A new method of stature estimation for forensic anthropological application. *Anthrop Sci* 2006; 114(1):23-7.
29. Jantz RL1. Modification of the Trotter and Gleser woman stature estimation formula. *J Forensic Sci* 1992; 37:1230-5.
30. Lundy JK. The mathematical versus anatomical methods of stature estimate from long bones. *Am J Forensic Med Path* 1985; 6:73-6.
31. Mall G, Hubig M, Buttner A, Kuznik J, Penning R, Craw M. Sex determination and estimation of stature from the long bones of the arm. *Forensic Sci Int* 2001; 117(1-2):23-30.
32. Oezaslan A, Iscan MY, Oezaslan I, Tugcu H, Koc S. Estimation of stature from body parts. *Forensic Sci Int* 2003; 132(1):40-5.
33. Pelin C, Duyar I. Estimating stature from tibia length: a comparison of methods. *J Forensic Sci* 2003; 48:708-12.
34. Rösing FW. Körperhöhenrekonstruktion aus Skelettmassen. Knussmann R, editor. *Anthropologie: Handbuch der Vergleichenden Biologie des Menschen*. Stuttgart: Gustav Fischer; 1988. S. 586-600.
35. Sjøvold T. Estimation of stature from long bones utilizing the line of organic correlation. *Human Evol* 1990; 5(5):431-47.
36. Sjøvold T. Stature estimation from the skeleton. Siegel JA, Saukko PJ, Knupfer GC, editors. *Encyclopedia of Forensic Sciences*. Vol. 1. London: Academic Press; 2000. p. 276-83.
37. Formicola V. Stature reconstruction from long bones in ancient population samples: An approach to the problem of its reliability. *Am. J. Phys. Anthropol.* 1993; 90(3):351-8.
38. Zinoviev AV. [Some results of studying of anthropological material from late medieval necropoles of Tver. In: *Tver, Tver Region and Adjacent Territories during Middle Ages*]. Vol. 3. Тверь: 1999. p. 245-8.
39. Zinoviev AV. [To the characteristics of the anthropological collection from an excavations of Spas Vysoky Monastery from middle suburban settlement of the city of Tver. *City of Tver, Tver Region and*

Adjacent Territories during Middle Ages]. Tver: TNEER; 2003. p. 106-8.

40. Zinoviev AV. A study of human osseal remains from archaeological excavations in Saint-Assumption Trinity Monastery (Staritsa, Tver District, Russia). *Bull. Int. Assoc. Paleodont.* 2008; 2(1):4-18.

41. Carrieri MP, Serraino D. Longevity of popes and artists between the 13th and the 19th century. *Int. J. Epidemiol.* 2005; 34(6):1435-6.

42. Thompson GW, Popovich F, Anderson DL. Third molar agenesis in the Burlington Growth Centre in Toronto. *Comm. Dent. Oral Epid.* 1974; 2(4):187-192.

43. Vodanovic M, Brkic H, Slaus M, Demo Z. The frequency and distribution of caries in the mediaeval population of Bijelo Brdo in Croatia (10th-11th centuries). *Arch. Oral Biol.* 2005; 50(7):669-80.