

Epitheloid Hemangioendothelioma in Patient with Liver Transplantation

Tajana Filipec Kanižaj^{1,4}, Vesna Čolić Cvrlje^{1,4}, Anna Mrzljak^{1,4}, Ika Kardum-Skelin^{1,4}, Dunja Šušterčić¹, Dinko Šegro¹, Denis Guštin² and Branislav Kocman³

¹ Department of Medicine, University Hospital »Merkur«, Zagreb, Croatia

² Department of Anaesthesiology and Intensive Care, University Hospital »Merkur«, Zagreb, Croatia

³ Department of Surgery, University Hospital »Merkur«, Zagreb, Croatia

⁴ University of Zagreb, School of Medicine, Zagreb, Croatia

ABSTRACT

Malignant hepatic epitheloid hemangioendothelioma (HEH) is a rare malignant tumor of vascular origin with unknown aetiology and a variable natural course. At the time of diagnosis, most patients present with multifocal tumours lesions that involve both liver lobes. From the therapeutic aspect, liver resection (LRx), liver transplantation (LTx), chemotherapy, radiotherapy, and/or immunotherapy have been used in the treatment of patients with HEH. However, because of the rarity of this tumor and its unpredictable natural history, it is impossible to assess the effectiveness of these respective therapies. In this report, our objective was to present clinical aspects, diagnostic options, therapeutic modalities, and the clinical outcome of single patient with LTx because of this rare tumor.

Key words: hepatic epitheloid hemangioendothelioma, liver transplantation, fine needle aspiration cytology

Introduction

Malignant hepatic epitheloid hemangioendothelioma (HEH) is a rare malignant tumor of vascular origin with unknown aetiology and a variable natural course. The term epitheloid hemangioendothelioma was defined as a distinct entity first by Weiss and Enzinger in 1982 as a soft tissue vascular tumor of endothelial origin with a clinical course between benign haemangioma and angiosarcoma¹. HEH most commonly affects adult females. At the time of diagnosis, most patients present with multifocal tumours lesions that involve both liver lobes. Most common sites of extra hepatic involvement are lungs, peritoneum, lymph nodes, and bones¹.

Based on current knowledge, no definitive etiology has been confirmed as a causative factor for HEH. Some possible risk factors of HEH include oral contraceptives, vinyl chloride, asbestos, major trauma to the liver, viral hepatitis, primary biliary cirrhosis, gold compounds and alcohol consumption². HEH, in contrast to many other types of primary liver tumor, does not typically arise in

a background of chronic liver disease, as described previously².

Clinical manifestations of HEH are uncommon and non-specific. Makhoul et al. reported findings in a series of 137 patients with this tumor³. At the time of diagnosis, 25% of reported patients were asymptomatic. Among symptomatic patients, the most common clinical manifestations were right upper quadrant pain (48.6%), hepatomegaly (20.4%), and weight loss (15.6%). Weakness, anorexia, epigastric mass, ascites, nausea/emesis, jaundice, and fatigue were the next most common presenting manifestations. Eighty-seven percent of patients presented with a multifocal tumor that involved both liver lobes, whereas only 13% of the patients had a unifocal tumor. The right lobe was affected more than the left lobe in both multifocal and unifocal presentations. Extra hepatic involvement at the time of diagnosis was observed only in 36.6% of patients. Out of other reported sites spleen is involved in 3.2% of cases. Eighty percent of pa-

tients had abnormal laboratory findings. Most tumor markers (e.g., alpha-fetoprotein, carcinoembryonic antigen, and CA 19-9) were in the normal range and, in the current context, were suitable only for ruling out other primary or metastatic liver tumors.

On ultrasonography, most frequently (66%), the lesions are hypoechoic relative to the adjacent hepatic parenchyma⁴. The other patterns of echogenicity include heterogeneous (22.5%), hyperechoic (6.2%), and isoechoic with hypoechoic rim (5%) appearance. On computed tomography (CT) scans most often low-density abnormal pattern is reported (98% of patients). Normal CT scans are reported in 1.4% of patients. HEH usually is hypointense on T1-weighted images and hyperintense on T2-weighted images by magnetic resonance images. The target appearance of the lesions may be caused by the presence of a central sclerotic zone and a peripheral region of cellular proliferation. Central low-signal areas may correspond to haemorrhage, coagulation necrosis, and calcification; whereas peripheral high signal intensity corresponds to oedematous connective tissue and viable tumor. Angiographic examination of the liver is performed only in selected patients and reveals only moderate vascularization. In literature review findings were completely heterogeneous, ranging from hypo- to hyperperfusion².

Generally, in the nodular form, a specific diagnosis is impossible without performing a fine needle aspiration cytology or biopsy because the radiology findings are similar to those in some hepatic metastases. Tumor is characterized by an epithelioid or histiocytoid morphology and a growth pattern with evidence of endothelial histogenesis⁵. Cells show prominent mucin negative cytoplasmic vacuoles. Red blood cells may be present within some of these vacuoles (reminiscent of primitive vascular channels). Its vascular nature is confirmed by positive staining for factor VIII-related antigen and/or other endothelial cell markers (CD31, CD34) in addition to the ultrastructural characteristics of well developed basal lamina, pinocytotic vesicles, and, more specifically, Weibel-Palade bodies. Some cases show positivity to smooth muscle actin, vimentin and cytokeratin. Epithelial membrane antigen (EMA) and S-100 staining patterns are negative. Immunohistochemical identification of factor VIII related antigen is helpful in differentiating between metastatic carcinoma and primary epithelial liver tumors⁵. Generally there is low mitotic activity and mild to moderate pleomorphism. Cases with tumor cells displaying cytological atypia, increased mitotic activity and necrosis and high cellularity could be related with worsen outcome. But clinical course of this tumor is quite variable and cytological analysis could not be used to predict disease outcome.

Clinical course of HEH is variable, ranging from a favourable disease with prolonged survival, even without therapy, to a rapidly progressive disease with a grave outcome. Liver resection therapy (LRx) is the treatment of choice in patients with resectable HEH. However, in patients with multifocal liver tumor the most common management procedure is liver transplantation (LTx). In

addition, LTx is an acceptable option for patients who have HEH with extrahepatic manifestation. The 1-year and 5-year patient survival rates are 96% and 54.5%, respectively, after LTx; 39.3% and 4.5%, respectively, after no treatment, 73.3% and 30%, respectively, after chemotherapy or radiotherapy; and 100% and 75%, respectively, after (LRx)².

Case Report

60 year old female patient with psoriatic arthritis was treated for six years with metotrexate (cumulative dose 460 mg) and gold compounds. Eight years before definite diagnosis patient presented with signs of liver damage (pathological aminotransferases) and multiple hypoechogenic lesions on liver ultrasound. All psoriatic arthritis therapy thereafter was stopped. Laboratory oncogenic markers (AFP, CEA, CA 19-9, CA 125, CA 15-3) were all in normal ranges. By repeated biopsies malignant alteration was not confirmed and diagnosis of tumor lesions was undefined. For years ago patient developed signs of ascites. Bioptic samples of tumor uninvolved liver tissue revealed cirrhosis. Because tests to all other etiological factors were negative (alcohol consumption, viral serology, immunological tests, and copper in bioptic sample) etiology was related with postnecrotic changes. Since that time liver ultrasound and multislice CT displayed slow progression in size of confluent hypoechogenic/hypodense tumor lesions in both liver lobes (3 cm maximal diameter) and appearance of one new lesion (4 cm in diameter) in spleen. Some tumors displayed signs of central necrosis. Angiography revealed no signs of pathological arterial vascularisation.

In our centre patient appeared one year ago with symptoms of upper quadrant pain, nausea, weight loss, weakness, ascites, and jaundice. Laboratory findings revealed elevated level of aminotransferases, alkaline phosphatase and gamma-glutamyltransferase (within twice of upper normal level), hyperbilirubinaemia (5 fold higher than upper normal limit), low prothrombin time (64%), normocytic normochromic anemia (Hgb 90 MCV 96.4 MCHC 340), and signs of renal failure (creatinin klirens 33 mL/min). Ultrasound examination confirmed multiple tumor lesions in both liver lobes and one lesion in spleen. Ultrasound guided fine needle aspiration of tumor mass in left liver lobe and spleen was performed. Cytological examination was suggestive of malignant epithelioid hemangioendothelioma (Figure 1). Tumor cells were staining positive to anti CD31 (Figure 2), anti CD 34 (Figure 3), vimentin and factor VIII related antigen.

Multiple tumor lesions in cirrhotic liver were considered nonresectable. Since multiphocal malignant hemangioendothelioma is considered in literature for liver transplantation it was proposed to patient. According to rules of Eurotransplant organization patient was reconsidered as non standard exception in indication for liver transplantation.

Standard orthotopic liver transplantation with total splenectomy was performed in December 2008. Explan-

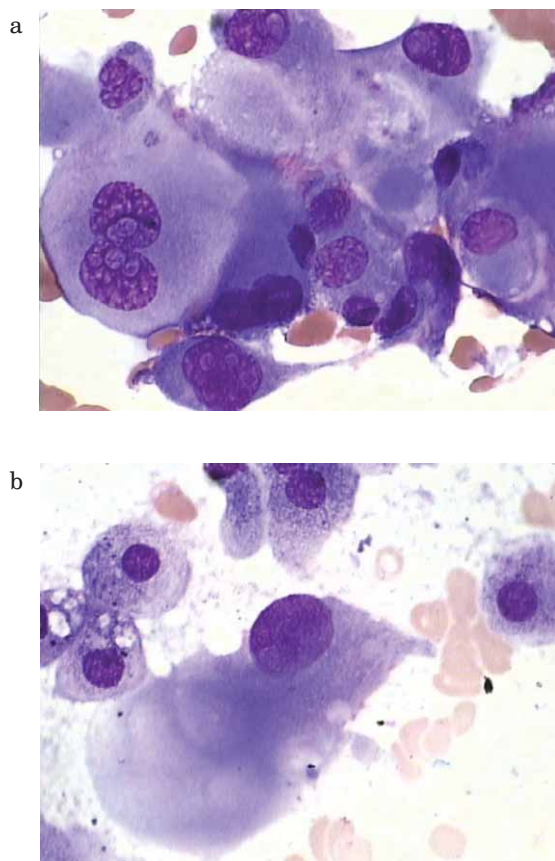


Fig. 1. Hepatic epitheloid hemangioendothelioma cells, fine needle aspiration cytology smears (May-Grunwald-Giemsa staining).

ted liver represented multiple tumor lesions involving almost entire liver with spleen metastasis. Patient is treated with regular immunosuppressive therapy consisted of combination with tacrolimus and mycophenolic acid. First month postoperative treatment was complicated with *E. coli* sepsis and progression of renal insufficiency. Both were successfully treated with standard procedures including antibiotics and correction of tacrolimus dose. Forth month after transplantation patient developed acute diarrhoea with signs of toxic megacolon and again with progression of renal insufficiency. No signs of bacterial or viral pathogens were detected in stool and possible explanation for toxic megacolon was related with toxic levels of calcineurin inhibitor (tacrolimus). Total colectomy was performed and tacrolimus stopped in therapy. After therapy correction patient went better and was released from hospital.

So far (8 months after LTx) patient has been treated with combination of mycophenolic acid and corticosteroid immunosuppressant and there is no sign of recurrence of primary disease.

Discussion and Conclusion

HHE is rare vascular tumor of liver. Positive imaging findings in addition to certain features, such as occur-

rence in younger adults, the presence of numerous intrahepatic tumors with a good clinical condition, slow course of the disease, and the presence of intratumoral calcifications, are suggestive for HEH^{6,7}. But the definitive diagnosis of this rare liver tumor requires a cytological or histopathologic analysis. The diagnosis mostly is confirmed by immunohistochemical evidence of endothelial differentiation, as demonstrated by the presence of factor VIII-related antigen (in nearly all patients), the presence of CD34 (94%), and CD31 (86%). Often, a laparoscopic wedge or core biopsy is sufficient to encompass the architectural features of HEH, such as the intravascular characteristics. In presented case definite diagnosis was confirmed by fine needle aspiration cytology.

Variable patterns of the tumor may mimic other lesions⁵. As in this case, in the literature review, approximately 60% to 80% of patients with HEH initially were misdiagnosed². The most common misdiagnoses are cholangiocarcinoma, angiosarcoma, hepatocellular carcinoma, metastatic carcinoma, and sclerosing hemangioma. Mixed hamartoma, spindle cell neoplasm, inflammatory pseudotumors, bile duct adenoma, cirrhosis, carcinoma with chondromyxoid change, venoocclusive disease, fibrolamellar carcinoma, postnecrotic fibrosis, and Budd-Chiari syndrome were less common misdiagnoses.

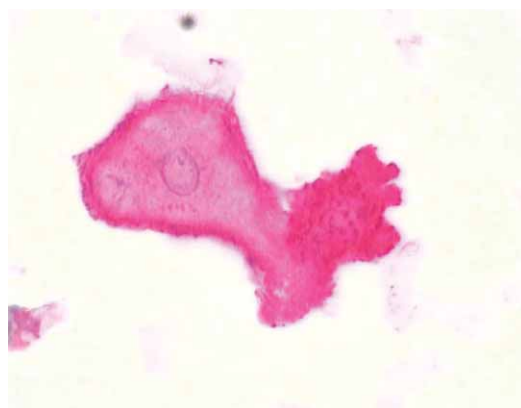


Fig. 2. Hepatic epitheloid hemangioendothelioma cells – positive immunostaining to CD31 (LSAB).

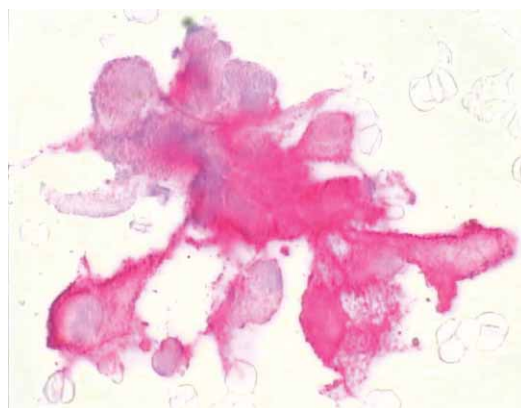

Fig. 3. Hepatic epitheloid hemangioendothelioma cells – positive immunostaining to CD34 (LSAB).

The management options for patients with HHE are numerous. Theoretically, LRx is the first choice for curative treatment of HEH. Like in this case, in majority of other patients, total resection is impossible because of the multicentricity of the lesions or anatomic difficulties: LTx is generally the most common treatment modality (44.8)⁸. Improved clinical outcomes after LTx in the last decade have provided further support in favour of undergoing LTx as curative treatment for HEH⁹. Significance of chemotherapy and/or radiotherapy is difficult to assess, mainly because of the lack of uniform treatment modalities and prospectively collected data.

According to earlier experience tumor can spread to other organs and presence of tumor cells displaying cytological atypia are not necessarily related with bad prognosis. In this regard, the unpredictable natural course and prognosis of HEH make it difficult to determine a correlation between morphologic grading or clinical stag-

ing and outcome. The life expectancy of patients with HEH potentially is good. Limited extrahepatic disease should not be considered an absolute contraindication to LTx¹⁰. Some authors have advocated LTx in the presence of extrahepatic involvement based on the reports of a 5-year survival rate between 48% and 71% in patients with HEH who had extrahepatic manifestations and underwent LTx^{2,11}. Most recurrences occurred beyond 2 years after transplantation¹².

This case report represents first case of successfully liver transplanted adult patient with multifocal HEH with extrahepatic spleen involvement in Croatia. In accordance with earlier experience, despite multifocal appearance of disease before LTx eight months after procedure there are no signs of disease recurrence. In patients with multifocal HHE and resectable extrahepatic disease LTx seems rational option.

REFERENCES

1. WEISS SW, ENZINGER FM, *Cancer*, 50 (1982) 970. — 2. MEHRABI A, KASHFI A, FONOUNI H, SCHEMMER P, SCHMIED BM, HALLSCHEIDT P, SCHIRMACHER P, WEITZ J, FRIESS H, BUCHLER MW, SCHMIDT J, *Cancer*, 107 (2006) 2108. — 3. MAKHLOUF HR, ISHAK KG, GOODMAN ZD, *Cancer*, 85 (1999) 562. — 4. LYBURN ID, TORREGGIANI WC, HARRIS AC, ZWIREWICH CV, BUCKLEY AR, DAVIS JE, CHUNG SW, SCUDAMORE CH, HO SG, *AJR Am J Roentgenol*, 180 (2003) 1359. — 5. LAUFFER JM, ZIMMERMANN A, KRAHENBUHL L, TRILLER J, BAER HU, *Cancer*, 78 (1996) 2318. — 6. D'ANNIBALE M, PIOVANELLO P, CARLINI P, DEL NONNO F, SCIARRETTA F, ROSSI M, BERLOCO P, IAPPELLI M, LONARDO MT, PERRONE R, DONNORSO R, *Transplant Proc*, 34 (2002) 1248. — 7. VAN BEERS B, ROCHE A,

MATHIEU D, MENU Y, DELOS M, OTTE JB, LALONDE L, PRINGOT J, *J Comput Assist Tomogr*, 16 (1992) 420. — 8. SOTIROPOULOS GC, KAISER GM, FRÜHAUF NR, KÜHL H, METZ KA, OLDHAFFER KJ, BROELSCH CE, *Hepatology*, 51 (2004) 436. — 9. MEHRABI A, KASHFI A, SCHEMMER P, SAUER P, ENCKE J, FONOUNI H, FRIESS H, WEITZ J, SCHMIDT J, BÜCHLER MW, KRAUS TW, *Transplantation*, 80 (2005) 109. — 10. LERUT JP, ORLANDO G, SEMPOUX C, CICCARELLI O, VAN BEERS BE, DANSE E, HORSMANS Y, RAHIER J, ROGGEN F, *Transpl Int*, 17 (2004) 202. — 11. YOKOYAMA I, TODO S, IWATSUKI S, STARZL TE, *Hepatology*, 37 (1990) 188. — 12. PENN I, *Surgery*, 110 (1991) 726.

T. Filipec Kanižaj

*Department of Internal medicine, University Hospital »Mercur«, Zajčeva 19, 10000 Zagreb
e-mail: tajana_filipec@yahoo.com*

EPITELOIDNI HAEMAGIOTELIOM U BOLESNIKA S TRANSPLANTACIJOM JETRE

SAŽETAK

Maligni epiteloidni hemangioendoteliom jetre je rijetki maligni tumor porijeklom od stanica krvnih žila s nepoznatom etiologijom i varijabilnim prirodnim tijekom. U vrijeme postavljanja dijagnoze većina bolesnika prezentira se s multifokalnim tumorskim promjenama koje zahvaćaju oba režnja jetre. U terapiji provode se postupci resekcije dijela jetre, transplantacije jetre, kemoterapije, zračenja i/ili imunomodulatorne terapije. Obzirom na rijetkost navedenog tumora i nepredvidiv prirodni tijek bolesti nemoguće je generalno procijeniti efektivnost navedenih terapija. U ovom prikazu cilj je prikazati kliničke aspekte, dijagnostičke mogućnosti, terapijske modalitete i tijek bolesti kod bolesnice s transplantiranom jetrom uslijed navedenog rijetkog tumora.