

Hypophosphatasia: Phenotypic Variability and Possible Croatian Origin of the c.1402G>A Mutation of TNSALP Gene

Danijela Petković Ramadža¹, Feodora Stipoljev², Vladimir Sarnavka¹, Davor Begović^{1,3}, Kristina Potočki^{4,5}, Ksenija Fumić⁶, Etienne Mornet⁷ and Ivo Barić^{1,3}

¹ Department of Pediatrics, University Hospital Center Zagreb, Zagreb, Croatia

² Cytogenetics Laboratory, General Hospital »Sveti Duh«, Zagreb, Croatia

³ Department of Pediatrics, School of Medicine, University of Zagreb, Zagreb, Croatia

⁴ Department of Radiology, University Hospital Center Zagreb, Zagreb, Croatia

⁵ Department of Radiology, School of Medicine, University of Zagreb, Zagreb, Croatia

⁶ Clinical Institute of Laboratory Diagnosis, University Hospital Center Zagreb, Zagreb, Croatia

⁷ Laboratoire SESEP, Batiment Fermat, University of Versailles Saint Quentin, Versailles, France

ABSTRACT

Hypophosphatasia is a metabolic bone disease characterized by bone and teeth hypomineralization due to defective function of tissue-nonspecific alkaline phosphatase (TNSALP). The disorder is caused by various mutations in the TNSALP gene localized on short arm of chromosome 1. Infantile hypophosphatasia is a severe form of the disease inherited as an autosomal recessive trait which presents before age of six months and often has fatal outcome. We report a patient with typical clinical course for infantile hypophosphatasia who was homozygous for the c.1402G>A mutation. The same mutation has been previously associated with a more severe perinatal form also in a Croatian family what indicates a possible common ancestral origin and phenotypic variability potential of c.1402G>A mutation of TNSALP gene.

Key words: hypophosphatasia, alkaline phosphatase, phenotypic variability, infantile form, gene mutations

Introduction

Hypophosphatasia (OMIM 146300, 241500, 241510) is a rare inherited metabolic bone disease characterized by bone hypomineralization and deficiency of tissue-nonspecific alkaline phosphatase¹. According to severity and age of onset five different forms of hypophosphatasia can be distinguished: perinatal, infantile, childhood, adult and odontohypophosphatasia¹. In some reports perinatal benign hypophosphatasia is classified as the sixth clinical form². The gene encoding TNSALP (ALPL gene) is located in chromosome band 1p36.1-34, and consists of 12 exons comprising about 50kb³. So far, at least 209 distinctive mutations have been reported⁴. About 80% of these mutations are missense mutations. Numerous rare compound heterozygous genotypes make it difficult to establish genotype-phenotype correlations. Severe forms of the disease are perinatal and infantile hypophosphatasia, which are both associated with mutations mostly lo-

calized in regions coding crucial domains of the protein⁵. Infantile hypophosphatasia usually presents before the sixth month of life after a normal neonatal period with failure to thrive, clinical manifestations of rickets, bone ossification abnormalities, functional craniosynostosis, hypercalcemia and hypercalcuria. Mortality is over 50% in the first year of life and is mostly due to respiratory failure and pneumonia which are pulmonary complications of their skeletal disease. However, prognosis improves in individuals who survive infancy¹.

Case Report

This girl was born as the second child of healthy and unrelated parents. Her older brother is healthy.

The infant was delivered at 36 weeks of gestation by cesarean section due to premature rupture of fetal membranes followed by weak labor. Birth weight was 2190 g (between 3rd and 10th percentile), length was 44.5 cm (10th percentile) and head circumference was 31.5 cm (between 10th and 50th percentile). The infant had myoclonic convulsions in the fourth and twelfth hour of life which were treated with intravenous administration of phenobarbiton. Seizures recurred on the third and fourth day of life and again respond well to therapeutic doses of barbiturates. Diagnostic procedures revealed no abnormalities apart from old periventricular intracranial hemorrhage showed by brain ultrasound. The child was discharged from the hospital with oral phenobarbiton therapy on the 17th day of life. During the following months she was unremarkable and without seizures until the fourth month of life when she started to lose weight. At the age of five months she presented with features of infantile hypophosphatasia including failure to thrive, mild psychomotor delay, hypotonia, wide cranial sutures, large fontanel, micrognathia, asymmetric hypoplastic thorax and widened wrists.

Laboratory results revealed severely decreased alkaline phosphatase (4 U/L; reference range for infants 150–420 U/L) and hypercalcemia (3.28 mmol/L; reference range for infants. 2.3–2.8 mmol/L). Phosphate was normal (1.73 mmol/L; reference range for infants 1.42–2.16 mmol/L) and PTH was suppressed (<0.2 pmol/L; reference range for adults 1–6 pmol/L) as expected. Increased amount of phosphoethanolamine was found in serum (127 µmol/L; reference range 0–40 µmol/L) and urine (660 mmol/mol creatinine; reference range 0–25 mmol/mol creatine). Bone turnover markers indicated increased bone remodeling with high serum osteocalcin levels (>62

µg/L, normal values for infants 19.4 – 56.8 µg/L) but normal β-CrossLaps in urine (1089 µg/mmol creatinine, normal values for children <18 yrs 4089±2456 µg/mmol creatinine). X-rays (Figure 1) and bone densitometry showed severe bone hypomineralization (BMD in lumbar region 0.119 g/cm², Z-score –6.57 SD). All these findings led to the clinical diagnosis of infantile hypophosphatasia. Mutation analysis by sequencing of the ALPL gene⁶ showed the homozygous missense mutation: c.1402G>A (A451T).

Therapeutic efforts were aimed at normalizing blood calcium and slowing down bone demineralization. A low calcium diet decreased serum calcium and normocalcemia was established with calcitonine and chlorothiazide therapy which was previously described to be successful⁷. Subsequent radiographs showed some improvement in bone mineralization but this could not be more thoroughly evaluated because the child died at the age of eight months due to extensive bilateral pneumonia and respiratory failure while waiting for bone marrow transplantation.

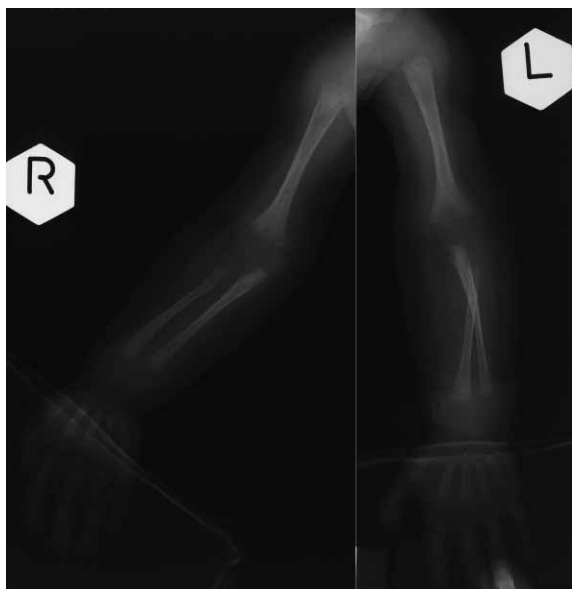

Fig. 1. Roentgenograms of the arms at the age of five months show osteopenic bones with thinned cortices and irregular metaphyses. Ossification nuclei of carpal bones are undeveloped.

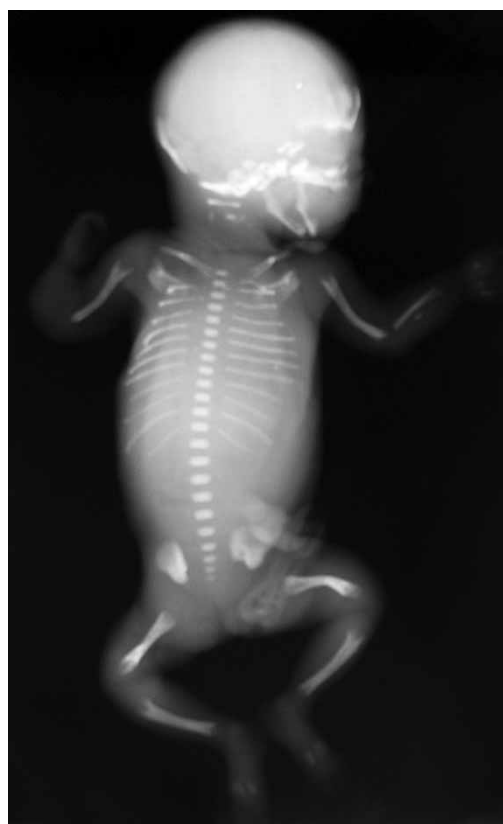


Fig. 2. Roentgenogram of the fetus with perinatal hypophosphatasia shows findings typical for hypophosphatasia. The overall shape is much more preserved than the ossification. The upper limbs show defective ossification of the left ulna and right radius and ulna. The spine shows skipped ossification of the cervical vertebrae and no ossification on the pedicles. The femurs are slightly bowed, while the tibiae are straight and of normal length. The femurs, tibiae and humeri show V-shaped metaphyseal defects very typical of hypophosphatasia.

Discussion

We report a patient with classic infantile hypophosphatasia caused by a homozygous A451T mutation in the TNSALP gene. This mutation was previously tested in at least 50 unrelated normal individuals to ensure that the base change was not a frequent polymorphism⁸. The residue is close to the homodimer interface^{8,9}. This is consistent with previous reports showing that most mutations associated with a severe phenotype affect residues localized in crucial domains such as the catalytic site, ligand-binding site and homodimer interface⁵. Alkaline phosphatases in *Escherichia coli* and humans show 25–30% homology, with conserved residues at the active site and the metal-binding domains⁹ which demonstrate the evolutionary importance of these domains in TNSALP. The substitution of alanine at position 451 to threonine residue would have a great impact on catalytic activity. Alanin is nonpolar amino-acid with hydrocarbon side chain and hydrophobic features, while threonine consists a hydroxyl group in the side chain, which interacts strongly with the water by forming of hydrogen bonds. Conversion of alanin to threonine, could influence directly on homodimer interactions or structural conformational conditions. This mutation was for the first time described, also in the homozygous form, in a severely deformed fetus at the 24 weeks of gestation⁸. Alkaline phosphatase in fetal blood obtained by chordocentesis was low (12 IU/L). Postmortem examination showed a poorly mineralized skull and vertebrae and slightly bowed femurs (Figure 2). First child in that family was born as a stillborn with hydrocephalus and tetraphocomelia at 36 weeks of gestation, but there was no evidence that it had hypophosphatasia. The parents originated from the same region of Croatia as our patient's family. To the best of our knowledge this mutation was not described before in non-Croats, what indicates a possible common ancestral origin of the A451T mutation in Croatian population. Both cases implicate the importance of this protein domain for function of TNSALP. Allosteric features are determined, among other factors, with a molecular structure of the

dimer interface. Because this enzyme is only active in dimeric form, any mutation found in and around homodimer interface is expected to severely compromise the function of the TNSALP protein. Additionally, these two different phenotypes in patients homozygous for the same mutation confirm that modifying genetic or possibly epigenetic factors could play an important role in clinical expression¹⁰. Serum alkaline phosphatase activity in our patient was very low (4 IU/L), which is more often seen in perinatal than in infantile form. Zurutuza et al. also described two families with same homozygous mutation R433C in exon 12, but different forms of lethal hypophosphatasia (infantile and perinatal) as in our case⁵. The mutation is located in the long insertion loop. Identification of causative mutation has an important implication for prenatal diagnosis in eventual next pregnancies.

Like our patient, all other reported patients with infantile hypophosphatasia and neonatal seizures had fatal outcomes¹¹, what confirms the thesis that seizures indicate bad prognosis in patients with hypophosphatasia. Another interesting fact about A451T mutation, that further indicates its phenotypic potential and requires additional research of modifying factors, is its possible dominant negative effect¹². In the family we report, both parents and the brother of our patient are heterozygous for A451T mutation. They all had reduced TNSALP serum activity and no other clinical signs or symptoms of the disease, which is more concordant with observation that heterozygous carriers of severe forms are clinically unaffected¹². However, it is known that parents of patients carrying mutations with *in vitro* dominant negative effect may express only very mild symptoms (mostly premature loss of teeth) or even may be completely unaffected^{13,14}.

Acknowledgements

This work is supported by Ministry of Science, Education and Sport, Republic of Croatia Grant No 108-1081870-1885.

REFERENCES

1. WHYTE MP, *Endocr Rev*, 15 (1994) 439. — 2. PAULI RM, MO-DAFF P, SIPES SL, WHYTE MP, *Am J Med Genet*, 86 (1999) 434. — 3. GREENBERG CR, EVANS JA, MCKENDRY-SMITH S, REDEKOPP S, HAWORTH JC, MULVOR R, CHODIRKER BN, *Am J Hum Genet*, 46 (1990) 286. — 4. TNSALP gene mutations database, Available from: URL: <http://www.sesep.uvsq.fr/Database.html> — 5. ZURUTUZA L, MULLER F, GIBRAT JF, TAILLANDIER A, SIMON-BOUY B, SERRE JL, MORNET E, *Hum Mol Genet*, 8 (1999) 1039. — 6. MORNET E, TAILLANDIER A, PEYRAMAURE S, KAPER F, MULLER F, BRENNER R, BUSSIÈRE P, FREISINGER P, GODARD J, LE MERRER M, OURY JF, PLAUCHU H, PUDDU R, RIVAL JM, SUPERTI-FURGA A, TOURAINE RL, SERRE JL, SIMON-BOUY B, *Eur J Hum Genet*, 6 (1998) 308. — 7. BARCIA JP, STREIFE CF, LANGMAN CB, *J Pediatr*, 130 (1997) 825. — 8. SPENTCHIAN M, MERRIEN Y, HERASSE M, DOBBIE Z, GLASER D, HOLDER SE, IVARSSON SA, KOSTINER D, MANSOUR S, NORMAN A, ROTH J, STIPOLJEV F, TAILLEMITE JL, VAN DER SMAGT JJ, SERRE JL, SIMON-BOUY B, TAILLANDIER A, MORNET E, *Hum Mutat*, 22 (2003) 105. — 9. MORNET E, STURA E, LIA-BALDINI AS, STIGBRAND T, MÉNEZ A, LE DU MH, *J Biol Chem*, 276 (2001) 31171. — 10. BRUN-HEATH I, LIA-BALDINI AS, MAILLARD S, TAILLANDIER A, UTSCH B, NUNES ME, SERRE JL, MORNET E, *Eur J Med Genet*, 50 (2007) 367. — 11. BAUMGARTNER-SIGL S, HABERLANDT E, MUMM S, SCHOLL-BÜRGI S, SERGI C, RYAN L, ERICSON KL, WHYTE MP, HÖGLER W, *Bone*, 40 (2007) 1655. — 12. MORNET E, *Orphanet J Rare Dis*, 2 (2007) 40. — 13. LIA-BALDINI AS, MULLER F, TAILLANDIER A, GIBRAT JF, MOUCHARD M, ROBIN B, SIMON-BOUY B, SERRE JL, AYLSWORTH AS, BIETH E, DELANOTE S, FREISINGER P, HU JC, KROHN HP, NUNES ME, MORNET E, *Hum Genet*, 109 (2001) 99. — 14. HERASSE M, SPENTCHIAN M, TAILLANDIER A, KEPPLER-NOREUIL K, FLIORITO AN, BERGOFFEN J, WALLERSTEIN R, MUTI C, SIMON-BOUY B, MORNET E, *J Med Genet*, 40 (2003) 605.

D. Petković Ramadža

*Department of Pediatrics, Division of Genetics and Metabolism, University Hospital Center Zagreb, Kišpatićeva 12,
10 000 Zagreb, Croatia
e-mail: dramadza@gmail.com*

HIPOFOSFATAZIJA: FENOTIPSKA VARIJABILNOST I MOGUĆE HRVATSKO PODRIJETLO c.1402G>A MUTACIJE TNSALP GENA

S A Ž E T A K

Hipofosfatazija je nasljedna metabolička bolest kostiju koja nastaje zbog nedostatne funkcije tkivno nespecifične alkaline fosfataze (TNSALP), a očituje se smanjenom mineralizacijom kostiju i zubi. Bolest nastaje zbog mutacija TNSALP gena koji se nalazi na kratkom kraku 1. kromosoma. Infantilni oblik hipofosfatazije se nasljeđuje autosomno recesivno, a klinički se bolest očituje unutar prvih šest mjeseci života i nerijetko ima fatalan ishod. Prikazujemo žensko dojenče oboljelo od infantilne hipofosfatazije s kliničkom slikom karakterističnom za ovaj oblik bolesti, koje je bilo homozigot za c.1402G>A mutaciju TNSALP gena. Ista mutacija je ranije opisana u fetusa koji je također bio hrvatskog porijekla, ali je imao teži, perinatalni oblik bolesti. U članku se raspravlja o mogućem zajedničkom porijeklu i fenotipskoj varijabilnosti mutacije c.1402G>A gena TNSALP.