

The Influence of Medical and Nonmedical Factors to the Progression of Renal Osteodystrophy

Mirna Šubat-Dežulović¹, Gordana Pelčić^{2,3}, Sanja Flajšman-Raspor¹, Goran Pelčić⁴ and Iva Sorta Bilajac³

¹ Department of Pediatrics Nephrology and Dialysis, School of Medicine, University of Rijeka, Rijeka, Croatia

² Health Centre of Primorsko-Goranska County, Rijeka, Croatia

³ Departments of Social Sciences, School of Medicine, University of Rijeka, Rijeka, Croatia

⁴ Departments of Ophthalmology, School of Medicine, University of Rijeka, Rijeka, Croatia

ABSTRACT

We report a 13-year-old boy hospitalized for the first time at the age of 17 months with clinical and laboratory signs of chronic kidney disease (CKD) and renal osteodystrophy caused by severe obstructive uropathy of the single kidney. Prevention and treatment of renal osteodystrophy has been target for aggressive therapy and the great challenge for pediatric nephrologists. The outcome of the therapy of renal osteodystrophy is influenced by medical and non – medical factors. It was concluded that the place of living (in our example a small village distant from primary care physicians, far from the social care professionals and far from the hospital), inferior social and economical status with inadequate nutrition present negative factors that contributed to the outcome and development of CKD and its complications as is renal osteodystrophy. The coordination of medical and non – medical professionals is necessary on the primary and secondary level to achieve positive results of therapy in patients with CKD.

Key words: renal osteodystrophy, social factors, inadequate nutrition

Introduction

In childhood, chronic kidney disease (CKD) causes disordered regulation of mineral and bone metabolism, with subsequent alterations in bone strength and growth failure. Renal osteodystrophy is the specific term used to describe the bone pathology that is manifested by either one or a combination of abnormalities of calcium, phosphorus, parathyroid hormone (PTH), or vitamin D metabolism¹. Beside biomarkers, prevention and treatment of renal osteodystrophy depend on abnormalities in bone turnover, mineralization, and bone growth with bone deformities common in infants and other children with long-standing CKD². However, the final outcome of the therapy of renal osteodystrophy is often influenced by medical and non – medical factors, such as place of living, culture, economical and social status and family education. The coordination of medical and non – medical professionals is necessary on the primary and secondary

level to achieve positive results of therapy in patients with renal osteodystrophy.

Case Report

We present a 13-year-old boy who was hospitalized for the first time at the age of 17 months with clinical and laboratory parameters indicative of chronic kidney disease (CKD) stage 3. He presented with clinical signs of urosepsis and severe obstructive uropathy of the single kidney due to pyeloureteral junction stenosis and consecutive hydronephrosis grade IV. His previous medical history was indicative for several febrile episodes and feeding problems since birth, and walking difficulties observed by his parents just prior to admission. Initial clinical evaluation showed decreased glomerular filtration rate

(GFR 30 mL/min/1.73 m², Schwartz formula), metabolic acidosis (serum bicarbonate 16 mmol/L) and anemia (Hb 90 g/dl) in addition to poor growth below the third percentile and clinical and X-ray signs of overt rickets (swollen ankles, genu valgum). Left hand and wrist X-ray showed bone age corresponding to 6 month old child with metaphyseal widening typical for rickets. The biochemical parameters of plasma calcium (2.2 mmol/L), phosphate (1.92 mmol/L), alkaline phosphatase (336 U/L, normal <300 U/L) and intact parathyroid hormone (PTH 28.2 pmol/L, normal <7.6 pmol/L) were indicative of vitamin-D-deficient rickets, indicating therapy with cholecalciferol (2000 units/day/3 months). Following the initial therapy with antibiotics, correction of metabolic acidosis, anemia, treatment of rickets and adequate diet, he stayed in hospital for 3 months, until the indicated surgical procedure for hydronephrosis was undertaken (sec. Anderson-Hynes). In the meantime, his clinical condition significantly improved and he could walk without any difficulties. In addition to improved radiological signs of rickets, control biomarkers showed normalization of alkaline phosphatase (143 U/L) but low plasma 1,25-(OH) vitamin D3 (21 pmol/L, normal 48–182 pmol/L for age) indicating renal osteodystrophy. He was discharged with prescribed therapy including low phosphate diet (reduction of dairy products) and protein intake of 1.2 g/kg/day, calcium-containing phosphate binders (CaCO₃ 500 mg/day) and calcitriol (Rocaltrol 0.25 µg/day) plus cholecalciferol (400 units/day). From that time on, however, living in a mountain village far from the hospital and far from his primary care physician, he was followed-up infrequently, no more than 2–3 times a year, often without any control for several months. Despite healed rickets and initial catch-up growth, his renal function progressively deteriorated and within next 5 years CKD reached stage 4. As he started school, he was even more irregularly seen by nephrologists, the compliance with prescribed diet and anticipated therapy was poor and often interrupted for prolonged periods. By the age of 10 years, after he was without any control for al-

most 2 years, he eventually presented with severe complications of renal osteodystrophy, i.e. deformed both legs (genu valgum) with crossed knees (intermaleolar distance of 20 cm) causing pain and severe walking difficulties. At that time, beside retarded growth, left hand and wrist X-ray corresponded to 6 year-old boy (Figure 1). Radiological signs of renal bone disease of hand, knees and predominantly lower extremities (periosteal resorption zones and metaphyseal changes) were in correlation with elevated PTH (max. 274 pmol/L), high calcium phosphorus product (5.4 mmol/L) and decreased 1,25-(OH) vitamin D3 (28 pmol/L) and 25-(OH) vitamin D3 (24 nmol/L). Osteodensitometry (DXA) of lumbar spine (BMD 0.644 g/cm², T score -4.1, Z-score -0.4) and left hip (T score -2.3) confirmed low bone mineral density indicating osteoporosis. Bone biopsy was not undertaken, but according to histological analysis of intraoperative bone resection, a few months later, clinically presumed diagnosis of osteomalacia, was confirmed. Consultant orthopedic surgeon, due to severe skeletal deformities indicated surgical correction of bone deformities. Prior to the first scheduled operation, prescribed therapy for renal osteodystrophy was intensified (CaCO₃ 2500 mg/day, calcitriol 0.75 µg/day, cholecalciferol 1000 units/day orally) with improvement of serum calcium, phosphorus and PTH. In the meantime, by the age of 12 years, just before the surgical correction was undertaken, our patient reached end stage renal disease and started haemodialysis 3 times a week. Histological analysis of resected bone confirmed pure osteomalacia with accumulation of osteoid without mineralization within thin bone trabecule excluding osteitis fibrosa cystica and adynamic renal osteodystrophy. Final result of both orthopedic corrections was rather satisfactory. We retrospectively analyzed our patient's biomarkers of renal bone disease through the whole period of observation including plasma calcium, phosphorus and the level of PTH. The aim of this retrospective study was to evaluate if such severe complications of renal osteodystrophy causing deformities of lower extremities could have been prevented. As shown,

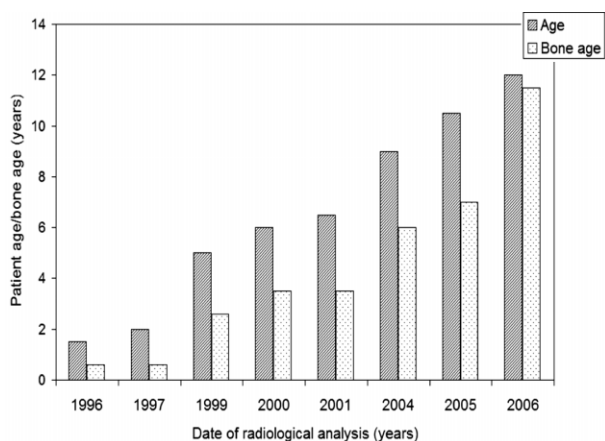


Fig. 1. Patient's age and delayed bone age based on radiological analysis (left hand) during follow-up in the patient with chronic kidney disease.

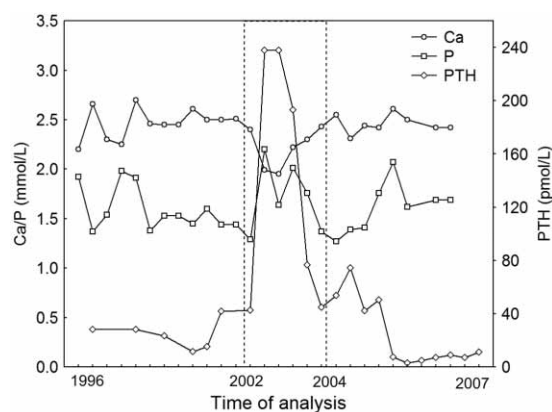


Fig. 2. The plasma values of calcium, phosphorus and parathyroid hormone during follow-up period of the patient with chronic kidney disease. Period between 2002 and 2004 without the control show the aggravations of laboratory parameters).

main aggravations of clinical and biomarkers of renal bone disease were in periods when he was without control, particularly during prolonged stay at home (as between 2002 and 2004) indicating poor compliance with prescribed diet and probably without any therapy for renal osteodystrophy (Figure 2). Contrary, during the 6-month stay at the hospital while awaiting between the two operations, taking prescribed medications regularly, control biomarkers of renal bone disease, including the level of PTH, calcium, phosphorous and active vitamin D metabolites, significantly improved. Control osteodensitometry undertaken after second surgical correction and 12-month regular therapy showed improvement (BMD 0.776g/m², T-2.9, Z-0.1). At that point, with pain reduction, better ability to walk even with, and afterwards, without crutches, he was able to return to school and ready to start evaluation for renal transplantation.

Discussion

The bone growth in childhood is under direct influence of a variety of hormones and growth factors including growth hormone, thyroid hormone, estrogen, testosterone, parathyroid hormone, vitamin D and insulin-like growth factor. A wide range of skeletal abnormalities are described in patient with CKD, but some of them are specific and the unique consequence of renal osteodystrophy on the growing skeleton¹⁻³. According to some authors both PTH assay (»intact« and »whole« PTH assay) seem to provide similar information in regard to bone turnover in patients with CKD⁴. The study by Sheth and Goldstein suggested that management of renal osteodystrophy based on correlation between iPTH levels and bone biopsy findings should not be extrapolated using the newer 1–84 PTH assay⁵. The patient presented here had the proportion of severe bone disease corresponding to renal osteodystrophy from the time he presented. Compared to K/DOQI's (National Kidney Foundation Kidney Disease Outcomes Quality Initiative) clinical signs and symptoms of bone disease in children with CKD¹, this patient had metabolic (hyperphosphatemia, elevated alkaline phosphatase), hormonal (altered vitamin D metabolism and elevated PTH), and radiographic abnormalities (delayed skeletal maturation and skeletal changes resembling vitamin-D-deficient rickets) at presentation. Proximal myopathy, extra skeletal calcifications and ocular disease were not found. Radiographic studies can diagnose bone complications such as rickets, skeletal deformities and delayed bone age. Radiological investigations play an important role in early diagnosis and therapy of renal bone disease, but are insufficient without biochemical markers. More sophisticated diagnostic methods have been introduced such as computer tomography (CT), magnetic resonance imaging (MRI) and bone biopsy, but plain film radiography still represents most widely used examination⁶. The bone biopsy provides definitive evaluation of renal osteodystrophy, but it is not routinely performed in clinical setting³. The bone changes in our patient developed over the years

parallel with the progression of the pathological levels of PTH concentration, mostly because of non-compliant therapy and irregular control. Bakr in his study detected that 61.9% of children in predialysis stage of CKD had osteopenia (measured by bone mineral density of lumbal spine) that occurs early and irrespective of duration or severity of CKD⁷. Osteodensitometry of lumbal spine in our patient detected osteoporosis in the predialysis period, corresponding to osteomalacia diagnosed during orthopedics surgery. As it is recommended, an entire panel of tests including radiological examination, densitometry tests, biochemical tests and bone biopsy should be performed for the comprehensive evaluation of the skeleton in patients with CKD.

The National Kidney Foundation has published 13 evidence based clinical practice guidelines (CPGs) to improve the outcome of patients in all stages of CKD, reduce disparities in care and reduce complications associated with kidney disease. In 2000, CPG was developed for nutrition in CKD and in 2003, for bone metabolism that requires dietary phosphorus restriction⁹. Parathyroid hormone is a better marker than serum phosphorus to start with this restriction. Dietary phosphate restriction with high dose phosphates binder in children with CKD plays a major role in suppression of secondary hyperparathyroidism either directly or through sustained elevation of circulating active D vitamin¹⁰. Despite of several clinical practice guidelines which were formulated by The National Kidney Foundation only a small number of patients achieved K/DOQI targets¹¹. In our patient, despite the recommendations, the adequate nutrition with reduced phosphate intake was not achieved considering the elevated concentrations of phosphorus and PTH through the periods when he stayed at home.

The patient lives on the small farm in the mountain area of our country. His family is occupied with farming and raising the cattle, heteroanamnestic data suggests that the main provision was milk and milks' products. The other problem considered in our patient was not compliant with prescribed therapy according to the K/DOQI and European guidelines^{1,2} during the periods when he was staying at home. Living in an isolated village without continuous supervision of the primary care physician and social workers, with low socio-economical status, were all the additional obstacles to successful outcome of the therapy.

O. Lenz et al.¹¹ identified the difficulties of successful care in chronic kidney disease detecting secondary hyperparathyroidism as a serious problem, just like in our patient. Detected the crucial facts for the improvement of CKD were raising awareness of CKD and K/DOQI goals among primary care physicians, early referral to a nephrologists, timely initiation of renal replacement therapy, exploration of socioeconomic barriers and cultural differences, continuous patient and physicians' education¹¹. Christensen and Ehlers emphasized that future clinical research should clarify the role of social support influencing patients' mortality in end-stage renal disease¹². The Patient Advocacy Committee of the Interna-

tional Federation of Kidney Foundation developed a set of rights for individuals with end stage renal failure. Patients possess those rights regardless of where they live or what may be their economic, social, ethnic or political status. Among 20 rights there is a right to prevent renal osteodystrophy¹³. This right and the right for different choice of treatment (peritoneal dialysis was suggested to patient's mother) could not be accomplished in our patient due to patients' economic and social status correlating with the place of his living.

Secondary hyperparathyroidism aggravated during the progression of CKD associated with renal osteodystrophy and extremity deformities requiring osteotomy. It was associated with frequent hospitalizations but irregular appointments by nephrologists and most importantly, non-

-compliance with prescribed therapy and the lack of multidisciplinary approach in primary care (primary care physicians, social workers, home nursing visits) support his illness¹⁴. It was concluded that socioeconomic factors and undertaken role of primary care professionals (physicians, social workers, school staff and home nursing staff) had negative influence on the outcome of renal osteodystrophy complicated by severe bone deformities that requires surgical correction.

Acknowledgements

We are grateful to dr. Kristina Pilipovic for her help in creating figures and prof. Anamarija Gjuranc-Coha for her help in lecturing this paper.

REFERENCES

1. ANONYMOUS, K/DOQI Clinical Practice Guidelines for Bone Metabolism and Disease in Children With Chronic Kidney Disease, National Kidney Foundation, accessed 2005. Available from: URL: http://www.kidney.org/PROFESSIONALS/kdoqi/guidelines_pedbone/index.htm — 2. KLAUS G, WATSON A, EDEFONTI A, FISCHBACH M, RONNHOLM K, SCHAEFER F, SIMKOVA E, STEFANIDIS CJ, STRAZDINS V, VANDE WALLE J, SCHRODER C, ZUROWSKA A, EKIM M, *Pediatr Nephrol*, 21 (2006) 151. — 3. WESSELING K, BAKKALOGLU S, SALUSKY I, *Pediatr Nephrol*, 23 (2008) 195. — 4. GAL-MOSCOVICI A, POPOVTZER MM, *Clin Nephrol*, 63 (2005) 284. — 5. SHETH RD, GOLDSTEIN SL, *Pediatr Nephrol*, 20 (2005) 977. — 6. JEVIĆ V, *Eur J Radiol*, 46 (2003) 85. — 7. BAKR AM, *Pediatr Nephrol*, 19 (2004) 1390. — 8. ZIÓLKOWSKA H, PAŃCZYK-TOMASZEWSKA M, MAJKOWSKA Z, RAJKOWSKA

T, DEBIŃSKI A, PRZEDLACKI J, SAWICKI A, OSTROWSKI K, MARCINIŃSKI A, ROSZKOWSKA-BLAIM M, *Med Sci Monit*, 7 (2001) 1034. — 9. BURROWES JD, *Nutr Today*, 41 (2006) 22. — 10. TURNER C, COMPTON J, MAK RH, VEDI S, MELLISH RW, HAYCOCK GB, CHANTLER C, *Kidney Int*, 33 (1988) 989. — 11. LENZ O, MEKELAA DP, PATEL DV, FORNONI A, METZ D, ROTH D, Barriers to successful care for chronic kidney disease, *BMC Nephrol*, Accessed: 2005. Available from: URL: <http://www.biomedcentral.com/1471-2369/6/11>. — 12. CHRISTENSEN AJ, EHLERS SL, *J Consult Clin Psychol*, 70 (2002) 712. — 13. ANDREUCCI VE, KERR DNS, KOPPLE JD, *Nephrol Dial Transplant*, 19 (2004) 30. — 14. JOY MS, KARAGIANNIS PC, PEYERL FW, *J Manag Care Pharm*, 13 (2007) 397.

G. Pečić

Department of Social Sciences, School of Medicine, University of Rijeka, Braće Branchetta 20, Rijeka 51000, Croatia
e-mail: gordanap17@yahoo.com

UTJECAJ MEDICINSKIH I NEMEDICINSKIH ČIMBENIKA NA PROGRESIJU RENALNE OSTEODISTROFIJE

SAŽETAK

Prezentiran je slučaj 13-godišnjeg dječaka koji je hospitaliziran prvi put u dobi od 17 mjeseci s kliničkim i laboratorijskim znakovima kronične bubrežne bolesti i renalne osteodistrofije uzrokovane opstruktivnom uropatijom jedinog bubrega. Prevencija i liječenje renalne osteodistrofije je cilj agresivne terapije i veliki izazov za pedijatrijske nefrologe. Ishod terapije renalne osteodistrofije je pod utjecajem medicinskih i ne-medicinskih čimbenika. Zaključeno je da mjesto stanovanja (u našem primjeru malo selo udaljeno od primarne zdravstvene skrbi, socijalne skrbi i bolnice), niži socijalni i ekonomski status obitelji te neadekvatna prehrana predstavljaju negativne čimbenike koji doprinose razvoju komplikacija kronične bubrežne bolesti kao što je renalna osteodistrofija. Koordinacija medicinskih i nemedicinskih stručnjaka je neophodna na primarnoj i sekundarnoj razini kako bi se postigli pozitivni rezultati terapije u pacijenata s kroničnom bubrežnom bolešću.