

# Bone Morphogenetic Protein-7 Expression in Human Pyelonephritis

Josip Španjol<sup>1</sup>, Gordana Djordjevic<sup>3</sup>, Dean Markić<sup>1</sup>, Dora Fučkar<sup>3</sup>, Kristian Krpina<sup>1</sup> and Dragica Bobinac<sup>2</sup>

<sup>1</sup> Department of Urology, University Hospital of Rijeka, Rijeka, Croatia

<sup>2</sup> Department of Anatomy, Faculty of Medicine, University of Rijeka, Rijeka, Croatia

<sup>3</sup> Department of Pathology, Faculty of Medicine, University of Rijeka, Rijeka, Croatia

## ABSTRACT

*Bone morphogenetic protein 7 (BMP-7) is a member of the transforming growth factor (TGF) beta superfamily and is involved in regeneration, repair, and development of specific tissues, for example kidney and skeleton<sup>1–5</sup>. The experimental studies have shown its protective role against fibrotic processes. Tubulointerstitial changes are present in the pyelonephritic kidney which progresses to fibrosis<sup>4–6</sup>. Renal fibrosis may lead to the loss of renal function. The aim of this study was to investigate BMP-7 expression in acute and chronic pyelonephritis in humans. Seven patients with acute pyelonephritis and 7 with chronic pyelonephritis were treated in Department of Nephrology Clinical Hospital, Rijeka. Tissue biopsy was taken and renal tissue was studied histopathologically by use of hematoxylin and eosin and scored for diagnosis of pyelonephritis. BMP-7 expression was studied by immunohistochemical staining. BMP-7 expression was observed in the tubular area of the pyelonephritic kidneys. The expression of BMP-7 was stronger in the acute pyelonephritic group and less in the chronic pyelonephritic group of patients. The results imply that BMP-7 has a role in chronic pyelonephritis. Tubular BMP-7 expression had a negative correlation with fibrosis and tubular atrophy. Our results are suggesting that BMP-7 plays an important protective role in renal inflammatory diseases preventing greater damage and fibrosis.*

**Key words:** bone morphogenetic proteins, kidney, inflammatory diseases

## Introduction

Pyelonephritis is one of the most common serious infections in children and early adulthood in many countries<sup>1</sup>. Progression of acute pyelonephritis into renal scarring (chronic pyelonephritis) is around 10–40% and postinfectious renal damage is still one of the major causes of chronic renal failure<sup>1–3</sup>.

Bone morphogenetic proteins (BMPs) are members of transforming growth factor-b (TGF-b) superfamily and control multiple organogenetic processes: morphogenesis, cell proliferation and differentiation, apoptosis and patterning of various organs on all three developmental envelopes<sup>4–8</sup>. Only BMP-7 is absolutely required for proper formation of the kidney<sup>6</sup>. The kidney has been identified as a major site of BMP-7 synthesis during embryonic and postnatal development<sup>5–7</sup>. In postnatal life, many developmental features are recapitulated during renal

injury, and BMPs are important in both preservation of kidney function and resistance to injury<sup>9–11</sup>. In animal models BMP-7 inhibits tubular epithelial cell de-differentiation, mesenchyme transformation and apoptosis stimulated by various renal injuries, has an anti-inflammatory effect in both models of acute and chronic renal failure, inhibits inflammatory cytokines IL-1 and TNF- $\alpha$ <sup>1,4,5,7,9–11</sup>. In diabetic rats loss of BMP-7 expression is associated with profibrotic activity<sup>12,13</sup>. In vitro studies have demonstrated that BMP-7 inhibits TGF-b mediated effects on renal cells and his production<sup>5</sup>. Exogenous administration of rhBMP-7 reduces renal fibrogenesis and apoptosis, also a reversal of renal fibrosis was observed starting BMP-7 therapy several weeks after initial damage<sup>7,14,15</sup>. BMP-7 in ischemic acute renal failure prevents neutrophil-mediated tissue damage, maintains the renal

tubular epithelia in a mature and functional state by preventing TGF- $\beta$ 1-mediated disruption of tubular epithelial polarity and inhibits TGF- $\beta$  mediated extracellular matrix accumulation and collagen synthesis<sup>4</sup>. BMP-7 in kidney is produced mostly by tubular epithelial cells and glomerular podocytes<sup>4</sup>.

The aim of this study was to investigate BMP-7 expression in acute and chronic pyelonephritis in humans.

## Material and Methods

Seven patients with acute pyelonephritis and 7 with chronic pyelonephritis were treated at the Department of Nephrology Clinical Medical Center of Rijeka, Rijeka, Croatia. All patients have signed the informed consent. True cut ultrasound guided tissue biopsy was taken for clinical evaluation. Tissue specimens were fixed in 10% buffered formalin and embedded in paraffin wax. Serial sections at 3  $\mu$ m thickness were made, mounted on glass slides and kept at room temperature until use. The first 3 sequential sections from each specimen were stained with hematoxylin and eosin (H&E) and with Masson's trichrome. To determine morphological data the corticomedullary part of the kidney including a minimum of 20 glomeruli was analyzed. The diagnosis of acute or chronic pyelonephritis was made by an experienced pathologist. Extensive fibrosis in chronic pyelonephritis was proved with Masson's trichrome staining. Semiquantitative scoring was performed as 0 (Masson's trichrome staining not present), 1 (in <25% of tissue sample), 2 (in 25–50%) and 3 (in >50%)<sup>16</sup>. Scoring was performed by three independent observers (S.Z., I.M. and J.S.) that were blinded to patient outcome. Staining score of counted cells revealed a significant interobserver concordance.

## Immunohistochemistry

Tissue slices were mounted on glass slides coated with 3-aminopropyltriethoxy silane (APES, Sigma, St. Louis, MO, USA), air-dried, and stored at 4 °C until processing for indirect immunoperoxidase staining. Briefly, tissue slices were deparaffinized in xylene and rehydrated in ethanol. Endogenous peroxidase and nonspecific binding were blocked by incubation in 0.3% H<sub>2</sub>O<sub>2</sub> in methanol and 10% non-immune serum. The sections were incubated with primary antibody for 60 minutes at room temperature. Anti-BMP-7 were goat polyclonal antibodies purchased from Santa Cruz Biotechnology (Santa Cruz, CA, USA). After the incubation with a primary antibody, secondary biotinylated antibody was applied according to the manufacturer's protocol (DAKO, LSAB $\beta$ + Kit Peroxidase, Carpinteria, CA, USA). Peroxidase conjugated streptavidin was added and the site of antigen binding was visualized using AEC + Substrate Chromogen (DakoCytomation). Sections were counterstained with hematoxylin. Slides used as negative control were processed either with PBS buffer or the secondary antibody alone.

## Assessment of Immunohistochemistry

Semiquantitative scoring was performed as 0 (BMP-7 staining not present), 1 (in <25% of tissue sample), 2 (in 25–50%) and 3 (in >50%)<sup>16</sup>. Scoring was performed by three independent observers (S.Z., I.M. and J.S.) that were blinded to patient outcome. Staining score of counted cells revealed a significant interobserver concordance.

## Statistical Analysis

The data was elaborated and analyzed using Statistica 6.1 software package (StatSoft.Inc., Tulsa, OK, USA). For comparison one-way ANOVA was used and post hoc Bonferroni correction was applied. A value of  $p < 0.01$  was required for significance.

## Results

Histopathologically acute pyelonephritis was characterized by polymorphonuclear leukocytes (PNL) infiltration of the interstitial tissue, interstitial oedema, PNL in tubular lumen and the presence of tubulitis. Chronic pyelonephritis was characterized by dominant mononuclear cell infiltration, tubular atrophy, colloid casts in dilated tubules, fibrosis and vascular changes. Fibrosis was significantly stronger in chronic ( $1.9 \pm 0.6$ ) compared to acute ( $0.9 \pm 0.2$ ) pyelonephritis. BMP-7 expression was observed mostly in the tubulointerstitial area of the pyelonephritic kidneys. The expression of BMP-7 (Figure 1, 2) was significantly ( $p < 0.01$ ) stronger in the acute

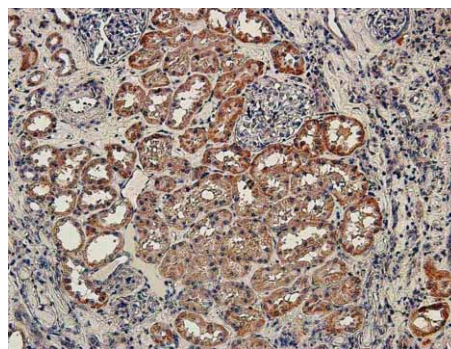


Fig. 1. Bone morphogenetic protein 7 expression in acute pyelonephritis.

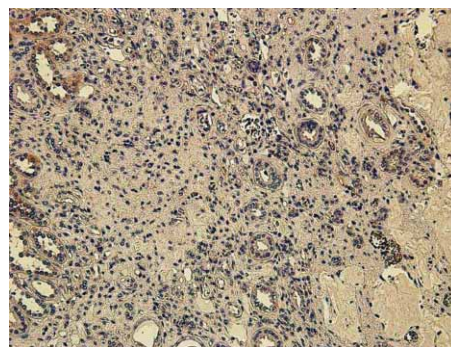


Fig. 2. Bone morphogenetic protein 7 expression in chronic pyelonephritis.

pyelonephritis group ( $2.1 \pm 0.9$ ) compared to chronic pyelonephritis group ( $0.9 \pm 0.2$ ). Tubulointerstitial BMP-7 expression had a negative correlation ( $p < 0.01$ ) with fibrosis.

## Discussion and Conclusions

Our results have demonstrated lower expression of BMP-7 in the chronic human pyelonephritis. Also the predominantly tubulointerstitial expression of BMP-7 is negatively correlated with fibrosis and tubular atrophy. Increased expression of BMP-7 in acute pyelonephritis is available to inhibit further changes that characterize chronic disease such as fibrosis.

Our findings on human material are consistent with animal and in vitro studies. In animal models BMP-7 inhibits tubular epithelial cell de-differentiation, mesenchyme transformation and apoptosis, has an anti-inflammatory effect in both models of acute and chronic renal failure, inhibits inflammatory cytokines IL-1 and TNF- $\alpha$ <sup>1,4,5,7,9–11</sup>. Histopathologically in our study acute pyelonephritis was characterized by polymorphonuclear leukocytes (PNL) infiltration of the interstitial tissue, in-

terstitial oedema, PNL in tubular lumen and the presence of tubulitis. Chronic pyelonephritis was characterized by dominant mononuclear cell infiltration, tubular atrophy, colloid casts in dilated tubules, fibrosis and vascular changes<sup>10–20</sup>. With lower expression in chronic pyelonephritis the protective, antiinflammatory role of BMP-7 is minimalised. In diabetic rats loss of BMP-7 expression is associated with profibrotic activity<sup>12,13</sup>. In vitro studies have demonstrated that BMP-7 inhibits TGF- $\beta$  mediated effects on renal cells and his production<sup>5</sup>. Our results also associate stronger fibrosis with lower BMP-expression. In animal model exogenous administration of rhBMP-7 reduces renal fibrogenesis and apoptosis, also a reversal of renal fibrosis was observed starting BMP-7 therapy several weeks after initial damage<sup>7,14,15</sup>. According to our results a possible therapeutic effect of BMP-7 implementation is to be considered in human patients.

In conclusion BMP-7 plays an important protective role in renal inflammatory diseases preventing greater damage and fibrosis. BMP-7 is mostly expressed in the tubulointerstitial area of the kidney. Submission of rh-BMP-7 in human patients with chronic pyelonephritis may be an efficient therapeutic approach for preventing further renal damage and advanced kidney failure.

## REFERENCES

1. BIYIKI NK, TUGTEPE H, CAKALAGAOGLU F, ILIKI A, ALPAY H, *Pediatr Nephrol*, 20 (2005) 1230. — 2. COOPER CS, *Nature Reviews Urology*, 6(9) (2009) 481. — 3. MONTINI G, HEWITT I, *Pediatr Nephrol*, 24 (2009) 1605. — 4. ZHANG Q, ZHANG Y, *Biochemical and Biophysical Research Communications*, 383 (2009) 1. — 5. TRI NGUYEN Q, GOLDSCHMEDING R, *Pharmaceutical Research*, 25(10) (2008) 2416. — 6. VUKIČEVIĆ S, BAŠIĆ D, ROGIĆ N, BAŠIĆ N, SHIN MS, SHEPARD A, JIN D, DATATREYAMURTY B, JONES W, DORAI H, RYAN S, GRIFITHS D, MALIAKAL J, JELIĆ M, PASTORČIĆ M, STAVLJENIĆ A, SAMPATH TK, *J Clin Invest*, 102 (1998) 202. — 7. MITU G, HIRSCHBERG R, *Frontiers in Bioscience*, 13 (2008) 4726. — 8. BOBINAC D, MARIĆ I, ZORIČIĆ S, ŠPANJOL J, DJORDJEVIĆ G, FUČKAR Z, *Croat Med J*, 46(3) (2004) 389. — 9. CHAN WL, LEUNG JCK, CHAN LYY, TAM KY, TANG SCW, LAI KN, *Kidney International*, 74 (2008) 1026. — 10. YEH CH, CHANG CK, CHENG MF, LIN HJ, CHENG JT, *Hormone et Metabolic Research*, 41(8) (2009) 605. — 11. TURK T, LEUWIS JW, GRAY J, TORTI SV, LYONS KM, NGUYEN TQ, GOLDSCHMEDING R, *Journal of Histochemistry and Cytochemistry*, 57(7) (2009), 623. — 12. MICHOS O, GONCALVES A, LOPEZ RIOS J, TIECKE E, NAILLAT F, BEIER K, GALLI A, VAINIO S, ZELLER R, *Development*, 134 (2007) 2397. — 13. MORRISSEY J, HRUSKA K, GUO G, WANG S, CHEN Q, KLAHR S, *J Am Soc Nephrol*, 13(Suppl.1) (2002) S14. — 14. ZEISBERG M, SHAH A, KALLURI R, *J Biol Chem*, 280 (2005) 8094. — 15. ZEISBERG M, HANAI J, SUGIMOTO H, MAMMOTO T, CHARYTAN D, STRUTZ F, KALLURI R, *Nat Med*, 9 (2003) 964. — 16. SIMON M, MARESH JG, HARRIS SE, HERNANDEZ JD, ARAR M, OLSON MS, ABOUD HE, *Am J Physiol*, 276 (1999) F382. — 17. BOBINAC D, ŠPANJOL J, MARINOVIĆ M, CVEK SZ, MARIĆ I, CICVARIĆ T, FUČKAR D, MARKIĆ D, VOJNIKOVIĆ B, *Coll Antropol*, 32(Suppl 2) (2008) 83. — 18. BIOČIĆ M, SARAGA M, KUZMIĆ AC, BAHTIJAREVIĆ Z, BUDIMIR D, TODORIĆ J, UJEVIĆ RM, *Coll Antropol*, 27(2) (2003) 745. — 19. GALEŠIĆ K, SABLJAR-MATOVINOVIĆ M, TOMIĆ M, BRKLJAČIĆ B, *Coll Antropol*, 28(2) (2004) 667. — 20. SMOKVINA A, GRBAC-IVANKOVIĆ S, GIROTTO N, DEZU-LOVIĆ MS, SAINA G, BARKOVIĆ MM, *Coll Antropol*, 29(2) (2005) 649.

J. Španjol

Department of Urology, University Hospital of Rijeka, T. Strišića 3, 51000 Rijeka, Croatia  
e-mail: jspanjol@vip.hr

## IZRAŽAJ KOŠTANOG MORFOGENETSKOG PROTEINA 7 U PIJELONEFRITISU LJUDI

### S A Ž E T A K

Koštani morfoogenetski protein 7 (BMP-7) član je superobitelji transformirajućeg čimbenika rasta (TGF) beta i uključen je u: regeneraciju, popravak i razvoj specifičnih tkiva, npr. bubrega i skeleta<sup>1–5</sup>. Eksperimentalne studije pokazale su zaštitnu ulogu od procesa fibroze. Tubulointersticijske promjene izražene su u pijelonefritisu te postupno progrediraju u fibrozu<sup>4–6</sup>. Bubrežna fibroza može dovesti do gubitka funkcije. Cilj ove studije bio je istražiti izražaj BMP-7 u

pielonefritisu ljudi. Sedam bolesnika s akutnim i 7 s kroničnim pielonefritisom, liječeni su na Zavodu za nefrologiju i dijalizu u Rijeci. U bolesnika je učinjena biopsija bubrega, a uzorci su obrađeni patohistološki te je postavljena dijagnoza pielonefritisa. Izražaj BMP-7 proučavan je imunohistokemijski. Izražaj BMP-7 zamijećen je tubulima bubrega zahvaćenih pielonefritisom. Izražaj BMP-7 bila je jača u akutnom pielonefritisu nego li u kroničnom. Rezultati upućuju na zaključak kako BMP-7 ima ulogu u razvoju kroničnog pielonefritisa. Tubularni izražaj BMP-7 imao je negativnu korelaciju s fibrozom i tubularnom atrofijom. Naši rezultati sugeriraju kako BMP-7 ima potencijalno zaštitnu ulogu u progresiji fibroze i tubularne atrofije u kroničnom pielonefritisu.