

Role of Bone Morphogenetic Proteins in Human Prostate Cancer Pathogenesis and Development of Bone Metastases: Immunohistochemical Study

Josip Španjol¹, Gordana Djordjević³, Dean Markić¹, Marko Klarić², Dora Fučkar³
and Dragica Bobinac²

¹ Department of Urology, University Hospital of Rijeka, Rijeka, Croatia

² Department of Anatomy, Faculty of Medicine, University of Rijeka, Rijeka, Croatia

³ Department of Pathology, Faculty of Medicine, University of Rijeka, Rijeka, Croatia

ABSTRACT

Bone morphogenetic proteins (BMP) have the ability to induce ectopic bone formation^{1–10}. The findings of their expression in prostate cancers have been linked with specifically tumor progression to bone and development of osteosclerotic metastases^{7–15}. We investigated the expression pattern of BMP-2/4, -6 and -7 and the receptors BMPR-IA, -IB and -II in normal human prostate, organ-localized and metastatic prostate cancers. The expression we also examined in skeletal metastases caused by prostate cancer. In localized prostate cancers we found increased expression of BMP-6 and decreased expression of BMP-2/4 and -7. In metastatic prostate cancers the expression of examined BMPs decreased. The expression of BMPRs showed the tendency to be lower with progression of prostate cancer but the expression of BMPR-II was completely absent in metastatic prostate cancers. In bone metastases caused by prostate cancer we found high expression of BMP-2/4, -6 and -7. Decreased expression of BMPs and loss of BMPR-II expression, could suggest that the influence of BMPs on prostate cancer cells is inhibited and plays an important role in prostate cancer pathogenesis. High expression of osteogenic BMPs in prostate cancer bone metastases could explain their osteosclerotic properties.

Key words: bone morphogenetic proteins, etiology, neoplasm metastasis, prostatic neoplasm

Introduction

Prostate cancer is the most common cause of cancer death in male population in Western countries^{1–3}. Advanced prostate cancer is commonly associated with the development of skeletal metastases. More than 90% of skeletal metastases caused by prostate cancer are osteoblastic bone lesions^{3–9}. In contrary, skeletal metastases from other malignancies are most frequently osteolytic bone lesions¹⁰. The linkage between prostate cancer and bone as well as predominantly presence of osteoblastic activity in the metastatic bone lesions remains still poorly understood^{11–13}.

Human prostate cells produce bone morphogenetic proteins (BMPs), the members of the transforming growth factor beta (TGF- β) superfamily. BMPs were originally identified as factors that were able to induce ectopic bone and cartilage formation in vivo and were in-

involved as multifunctional regulator factors in cellular differentiation, cellular proliferation, apoptosis and organogenesis^{14–18}. The expression of BMPs in malignant prostate cells and prostate cancer cell lines brings a new insight on relationship between prostate cancer and bone microenvironment. Several BMPs were detected in human normal and malignant prostate cells. Mostly the expression of BMP-2, -3, -4, -5 and -6 was examined^{19–23}. Masuda et al investigated the expression of BMP-7, one of the members of BMPs family with strong osteoinductive capacity²⁴. BMP-6 expression has been predominantly found in human prostate cancers with established skeletal metastases comparing with non-metastatic prostate cancer^{20,21}. Several studies have shown a correlation between elevated BMP-6 expression and cancer severity and it was suggested that the effect of the BMP-6 in the

surrounding bone environment may be related to the osteoblastic nature of the metastatic lesions^{24–26}. Additionally, bone metastases could be osteoblastic or osteolytic bone lesions and thinking about the expression of BMPs it is indicated to differentiate the type of bone activity. *In vitro* studies have shown that BMP -2, -4, -6 and -7 have no direct effect on prostate cancer cell growth, but BMP -2, -4 and -6 increase the *in vitro* invasive ability of prostate cancer cells^{27,28}. Feeley et al have found that BMP-7 inhibits PC-3 cell proliferation and BMP-6 inhibits the proliferation of human renal cell cancer (RCC) cell line²⁸. BMP-6 and BMP-7 expression has been even detected in metastatic bone lesions caused by prostate cancer^{24,29}.

BMPs act over binding to membrane receptors known as BMP receptors (BMPRs). BMPRs are heteromeric complex that consists of two types I receptors named type -IA and -IB and one type -II receptor. It has been shown that all members of BMPs bind to BMPR-II in combination with BMPR-IA or BMPR-IB. BMP binding results in crossphosphorylation of one of type I receptors by BMPR-II³⁰. The effect of BMP-2, -4 and -7 is mediated by binding on BMPR-IB³¹. Followed by the expression of all three BMPRs in normal prostate cancer cells, decreased expression of BMP receptors type -IA, -IB and -II has been found in prostate cancer cells^{27,30,31,33}. It has been assumed that defective BMP signaling may lead to an enhanced tumorigenic potential of prostate cancer cells and consequently contribute to tumor progression^{30,31}. RCC cell lines with the lack of BMPR-II were resistant to the growth-inhibitory effect of BMP-6³¹.

The aim of the present study was, using immunohistochemistry on same tissue samples, to examine the expression of BMP-2/4, -6 and -7, and BMPR-IA, -IB and -II in human normal prostate tissue, organ-localized prostate cancer and metastatic prostate cancer with established osteosclerotic bone metastases and to clarify the potential role of BMPs in prostate cancer pathogenesis. The expression of BMP-2/4, -6 and -7 and BMPRs in non-matched samples of bone metastases caused by prostate cancer was examined, too.

Materials and Methods

We analyzed tissue samples of prostate cancer obtained from the patients treated at the Department of Urology, University Hospital of Rijeka, Croatia in the period from 2002 to 2007. All the patients involved in this study were informed about the aims of the study and signed informed consent letter. The patients with diagnosed prostate cancer were divided in two groups. The first was a group of the patients with primary prostate cancer without any clinical signs of tumor progression and without bone metastases. For that group we selected twenty one patients and they all underwent to radical prostatectomy. The second group consisted of the patients with metastatic prostate cancer, with proved bone metastases. In that group we selected twenty one patients, too. The patients with metastatic prostate cancer

who already received hormonal therapy were not included into the study. The age of patients ranged from 55 to 81 years (mean±SD, 69.5±6.2). From the archival tissue samples stored at the Department of Pathology, Faculty of Medicine, University of Rijeka, following the approval of the local ethic committee, we obtained 21 specimens of nonmetastatic prostate cancer and 21 specimens of metastatic prostate cancer tissue. Tissue samples of nonmetastatic prostate cancer were taken after transrectal prostate needle biopsy and patohistological finding were confirmed after radical prostatectomy. Tissue samples of metastatic prostate cancer were also taken after transrectal prostate needle biopsy. Normal prostate tissue was obtained from aged matched individuals (10 specimens). Tissue samples were pathohistologically analyzed. Prostate tissue that was pathohistologically confirmed as prostate cancer, was graded using Gleason scoring system according to the World Health Organization (WHO) classification criteria³⁵. For determining the stage of prostate cancer regarding to its affinity to metastasis to the bone and produce bone lesions, isotope bone scanning of the whole body, and radiography of the vertebral column with pelvis and thoracic region were done. After detection of bone metastases by both plain radiography and bone scyntigraphy, the characteristics of bone metastasis were determined. All bone metastases were distinguished as predominantly osteosclerotic bone lesions. Other clinical data we obtained from patient's medical records.

From patient's charts we obtained data about serum prostate specific antigen (PSA) values and serum alkaline phosphatase (AP) values. Serum PSA was measured using IMx assay (Abbott Laboratories, Abbot Park, IL, USA) and the reference for this assay ranged from 0 to 4.0 ng/mL. Serum total alkaline phosphates (AP) activity was determined using a kinetic color test on Olympus analyzer using p-nitrophenylphosphate substrate at pH 10.4, normal range for adults 30–120 U/L.

The next group consisted of the patients who suffered pathological bone fracture but afterwards was determined that the cause of bone fracture was prostate cancer metastatic lesion. After bone surgery procedures the bone tissue samples were sent for patohistological examination. For five patients bone lesions were detected as bone metastases of prostate cancer. So we included these five patients in the research. Patohistologically those bone metastatic lesions were described as osteoblastic.

Tissue samples preparation

Prostate tissue specimens were fixed in 10% buffered formalin and embedded in paraffin wax. Serial sections at 3 μm thickness were made, mounted on glass slides and kept at room temperature until use. The first of sequential sections from each specimen was stained with hematoxylin and eosin (H&E). Tissue samples of bone metastases passed prior sectioning additional procedures of tissue preparations. Bone tissue samples were fixed in solution composed of concentrated formaldehyde (50%), methanol (46%) and PBS (4%). Following this fixation,

the tissue was transferred in 70% ethanol and decalcified in Osteodec (Bioptica, Milano, Italy).

Immunohistochemistry

Tissue slices were mounted on glass slides coated with 3-aminopropyltriethoxy silane (APES, Sigma, St. Louis, MO, USA), air-dried, and stored at 4 °C until processing for indirect immunoperoxidase staining. Briefly, tissue slices were deparaffinized in xylene and rehydrated in ethanol. Endogenous peroxidase and nonspecific binding were blocked by incubation in 0.3% H₂O₂ in methanol and 10% non-immune serum. The sections were incubated with primary antibody for 60 minutes at room temperature. Anti-BMP-2/4, -6, -7, anti-BMPR-IA, -IB and -II were goat polyclonal antibodies purchased from Santa Cruz Biotechnology (Santa Cruz, CA, USA). After the incubation with a primary antibody, secondary biotinylated antibody was applied according to the manufacturer's protocol (DAKO, LSAB⁺ Kit Peroxidase, Carpinteria, CA, USA). Peroxidase conjugated streptavidin was added and the site of antigen binding was visualized using AEC + Substrate Chromogen (DakoCytomation). Sections were counterstained with hematoxylin. Slides used as negative control were processed either with PBS buffer or the secondary antibody alone.

Assessment of Immunohistochemistry

Assessment of immunohistochemistry was performed by three independent observers (M.K., D.M. and J.S.) that were blinded to patient outcome. Cytoplasmic expression was assessed as absent or present. The cells with positive reaction were counted and scored as a percentage of the total number of malignant cells present in 15 high powerfield (400x magnifications). Cell counting was done by using an image analyzer system equipped with a software package (Issa, VAMS, Zagreb, Croatia). Before starting the assessment the tissue sample was looked through by pathologists and was signed the area of clear prostate cancer. In the signed area 15 neighboring powerfields were analyzed. Conventional sections of normal prostate were scored using the same method with assessment of 15 randomly selected powerfields of each section. Staining score of counted cells revealed a significant interobserver concordance. The sample with more than 10% of positively stained cells was declared as positive sample.

Statistical Analysis

The data was elaborated and analyzed using Statistica 6.1 software package (StatSoft Inc., Tulsa, OK, USA). The observations were described by their mean± standard deviations, or with medians with 10th to 90th percentile range, where suitable. Normality check was performed with Shapiro-Wilks test. Following, the groups were compared using non parametric tests: Kruskal-Wallis ANOVA for comparison of multiple groups or Mann-Whitney U test for comparison of two groups. A value of p<0.05 was required for significance. Because of the small number of metastatic bone samples involved, only descriptive analyses could be performed.

Results

By immunohistochemistry we investigated the expression of BMP-2/4, -6 and -7, and BMPR IA,-IB and II in epithelial glandular tissue of normal human prostate and in prostate cancer cells of organ-localized prostate cancer and metastatic prostate cancer with proved bone metastases. Furthermore we analyzed metastatic bone lesions from prostate cancer. Acquired data were statistically analyzed and in the most cases the distribution of data was not normal but the distributions had similar shapes.

The expression of BMP-2/4,-6 and -7 was found in epithelial glandular cells from all samples of normal prostate and the percentage of positive cells was different for each BMP (Figure 1a,d,g). According to the percentage of positive cells the predominant expression of BMP-2/4 and BMP-7 was found in normal prostate tissue (Table 1).

TABLE 2
VALUES OF GLEASON SCORE, SERUM CONCENTRATION OF PROSTATE SPECIFIC ANTIGEN (PSA) AND SERUM TOTAL ALKALINE PHOSPHATASE IN PATIENTS WITH LOCALIZED AND METASTATIC PROSTATE CANCER (PC) (MEAN±SD)

	Localized PC	Metastatic PC
Gleason score	4±1	6±2 ¹
PSA	10.5±2.8 ng/mL	105.1±147.1 ng/mL*
Alkaline phosphatase	63.5±24.3 U/L	526.9±342.6 ^b U/L*

* p<0.05, metastatic PC vs. localized PC

TABLE 1
EXPRESSION OF BONE MORPHOGENETIC PROTEINS (BMPs) IN NORMAL PROSTATE (NP) AND PROSTATE CANCER (PC) (MEAN±SD)

	BMPs NP		Localized PC		Metastatic PC	
	% positive cells	no. of cases	% positive cells	no. of cases	% positive cells	no. of cases
BMP-2/4	87.77±11.4	10/10	71.71±24.40	21/21	62.88±16.03	20/21 (95%)
BMP-6	64.51±12.95	10/10	88.63±13.27*	21/21	40.98±15.74**	6/21 (29%)**
BMP-7	94.63±0.89	10/10	80.37±22.10	21/21	46.23±11.58**	7/21 (33%)**

* p<0.05 localized PC vs. NP, ** p<0.05 metastatic PC vs. localized PC

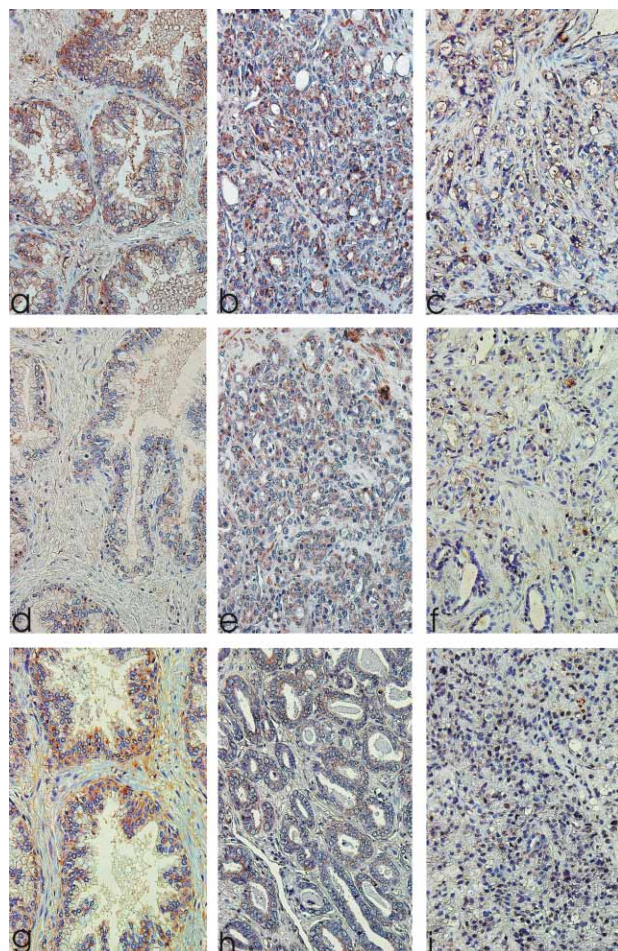


Fig. 1. The expression of bone morphogenetic protein (BMP) -2/4 in normal prostate (a), in localized prostate cancer (b), in metastatic prostate cancer (c); the expression of BMP-6 in normal prostate (d), in localized prostate cancer (e), in metastatic prostate cancer (f); the expression of BMP-7 in normal prostate (g), in localized prostate cancer (h), in metastatic prostate cancer (i).

The patients with organ-localized prostate cancer had significantly lower Gleason score, lower PSA serum concentration and lower serum alkaline phosphatase compared to the patients with metastatic prostate cancer and proven bone metastases. (Table 2).

BMP-2/4 was strongly expressed in organ-localized prostate cancer while in metastatic prostate cancer the expression decreased. In all tissue samples of organ-localized tumor and metastatic prostate tumor we found positive expression (Figure 1b,c, Table 1).

BMP-7 expression slightly decreased in organ-localized prostate cancers compared to the normal prostate. In metastatic prostate cancers the percentage of BMP-7 positive cells even more significantly decreased ($P < 0.001$) (Figure 1h,i). The expression was found in almost all tissue samples of organ-localized prostate cancer while in metastatic prostate cancers the expression was found only in 7 out of 21 samples what additionally indicated BMP-7 expression significant reduction (Table 1).

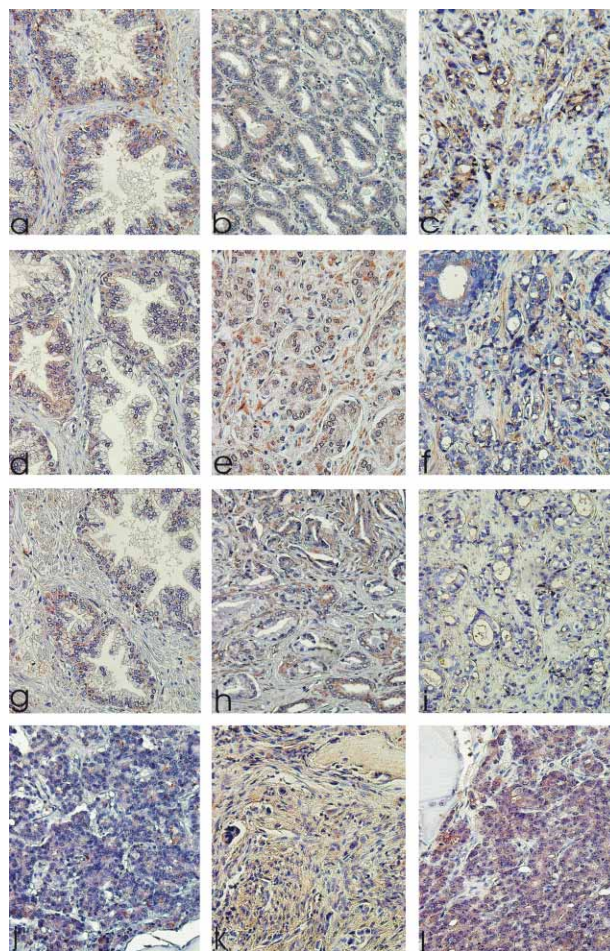


Fig. 2. The expression of bone morphogenetic protein receptor (BMPR) -IA in normal prostate (a), in localized prostate cancer (b), in metastatic prostate cancer (c); the expression of BMPR-IB in normal prostate (d), in localized prostate cancer (e), in metastatic prostate cancer (f); the expression of BMPR-II in normal prostate (g); in localized prostate cancer (h); in metastatic prostate cancer (i); the expression of bone morphogenetic protein (BMP) -2/4 in metastatic bone lesion (j); the expression of BMP-6 in metastatic bone lesion (k); the expression of BMP-7 in metastatic bone lesions (l).

The percentage of BMP-6 positive cells was higher in organ-localized prostate cancer tissue than in normal prostate tissue but the difference was not statistically significant. In metastatic prostate cancer tissue the expression of BMP-6 was significantly lower in comparison to the localized prostate cancer ($P < 0,01$) (Figure 1e,f). Even more, we found only 6 out of 21 tissue samples of metastatic prostate cancer with positive expression (Table 1).

BMPR-IA, BMPR-IB and BMPR-II were expressed by the cells of normal prostate (Table 3). The expression was localized in the epithelial glandular cells and in some cases in stromal cells (Figure 2a,d,g).

The expression of BMPR-IA, BMPR-IB and BMPR-II in organ-localized prostate cancer was not distinct to the expression in normal prostate (Table 3). However, in

TABLE 3
EXPRESSION OF BONE MORPHOGENETIC PROTEIN RECEPTORS (BMPRs) IN NORMAL PROSTATE (NP) AND PROSTATE CANCER (PC) (MEAN±SD)

BMPRs	Normal prostate		Localized PC		Metastatic PC	
	% positive cells	no. of cases	% positive cells	no. of cases	% positive cells	no. of cases
BMPR-IA	80.52±18.3	10/10	67.25±30.71	21/21	42.73±13.09*	5/21 (24%)*
BMPR-IB	62.28±12.4	10/10	58.43±22.67	21/21	55.47±32.9 3	9/21 (43%)*
BMPR-II	41.80±11.3	10/10	45.96±32.22	21/21	negative	none

* p<0.05, metastatic PC vs. localized PC

TABLE 4
EXPRESSION OF BONE MORPHOGENETIC PROTEINS (BMPs) IN PROSTATE CANCER SKELETAL METASTASES TISSUE

BMPs	Skeletal metastases	
	positive staining	no. of cases
BMP-2/4	100±0	5/5
BMP-6	80.22±15.31	4/5
BMP-7	100±0	5/5

metastatic prostate cancer cells we found significantly decreased expression of receptors type IA and IB, and loss of expression for BMPR-II (Figure 2b,e,h). The lower expression for BMPR-IA and -IB was also manifested by significantly reduced number of positive samples of metastatic prostate cancer. (Table 3, Figure 1c,f,i).

BMP-2/4, -6 and -7 were strongly expressed by metastatic prostate cancer cells in skeletal metastases (Table 4, Figure 2j,k,l).

Analysis of prostate cancer bone metastases showed also a decreased expression of BMPRs. The expression of BMPR-II was absent.

Discussion

In our study BMP-2/4, -6 and -7 expression was downregulated in metastatic prostate cancer with established bone metastases. Decreased expression of bone morphogenetic protein receptors type IA and IB, and lack of receptor type II were found in metastatic prostate cancer, too. Metastatic cancer cells from bone lesions caused by prostate cancer strongly expressed BMP-2/4, 6 and -7.

We have confirmed previous results that BMP-2/4, -6 and -7 and receptors BMPR-IA, -IB and -II were expressed by epithelial cells of human normal prostate tissue^{19,24,33,34}. We found the highest expression for BMP-2/4 and BMP-7. Harris et al examined for BMP-2, BMP-3, BMP-4 and BMP-6 mRNA expression in human normal prostate and prostate cancer cell lines¹⁹. They found that normal human prostate predominantly expressed BMP-4.

Over membrane receptor complex BMPs initiate cell signal transduction. Since BMPRs are expressed in nor-

mal prostate, BMPs could be important factors in maintaining of normal prostate tissue physiology and cell growth control by acting as autocrine or paracrine growth regulatory factors¹⁹.

In our study BMP-2/4 and -7 expression appeared to be downregulated whereas BMP-6 expression increased in localized prostate cancers compared with normal prostate. On the other hand, we found decreased expression of all examined BMPs in metastatic prostate cancers. Evaluating BMPs expression through the number of samples that showed positive immunohistochemical staining we found that all samples of normal prostate and with localized prostate cancer conferred a positive reaction. The number of metastatic prostate cancer samples with BMP-6 and -7 positive immunohistochemical reactions was significantly reduced. Our study revealed that in metastatic prostate cancers with established bone metastases and consequently higher Gleason score, the expression of BMP-6 and -7 was strongly downregulated. This finding suggests that BMPs may have an inhibitory effect on prostate cancer tumorigenesis.

Several studies have examined the expression of BMP-2, -4, -6 and -7 in human normal and malignant prostate tissues. In PCR-based analysis, Bentley et al found that several BMPs were expressed in both benign and malignant human prostate tissue³. BMP-6 expression was detected in the prostate tissue of over 50% of patients with clinically defined metastatic prostate cancer, but was not detected in nonmetastatic or benign prostate samples. These results were consistent with a later study by Hamdy et al., who reported that BMP-6 mRNA expression was detected exclusively in malignant epithelial cells in 20 out of 21 patients with metastases, in 2 out of 11 patients with localized prostate cancer, and undetectable in 8 benign samples²¹. In the study of Harris et al, they examined BMP-2, -3, -4 and -6 mRNA expression in normal rat prostate and rat PAIII prostate adenocarcinoma¹⁹. Their experiments revealed that normal rat prostate produces BMP-2, -3, -4 and -6 mRNA. BMP-2 and -6 mRNA expression in normal prostate tissue was considerably elevated compared with PAIII cells and prostate tumor. This same trend they reported for BMP-2 and BMP-6 expression in normal human prostate compared with PC-3 and LNCaP cells. In another study focused on BMP-6 mRNA and protein expression, Barnes et al. observed that BMP-6 was produced by normal and neoplastic human prostate²¹. Furthermore, they found no signif-

icant increase in BMP-6 protein expression with tumor grade or metastatic potential in the rat prostate adenocarcinoma model. Horvath et al examined BMP-2 expression in normal prostate and localized prostate cancer; they demonstrated decreased BMP-2 expression in localized prostate cancer in correlation with benign prostate hyperplasia or hyperplasia adjacent to prostate cancer²³. Expression of BMP-7 in normal and neoplastic human prostate was examined by Masuda et al²⁴. They found that the level of BMP-7 expression was highest in the normal prostate glandular tissue in comparison to the prostate cancer. In newly diagnosed prostate cancer tissues they found lower BMP-7 expression and they concluded that the expression of BMP-7 tended to be lower during the development and progression of prostate cancer.

In accordance with previous results we have found decreased expression of BMP-2 and -7 in organ-localized prostate cancers compared to the normal prostate tissue. For the first time we showed the differences in the expression of BMP-7 between localized and metastatic prostate cancers. In prostate cancers with confirmed skeletal metastases and higher Gleason score the expression of BMP-7 significantly decreased and in 2/3 of tissue samples was completely lost. Since systemic administration of BMP-7 inhibited prostate cancer growth in the bone marrow we assumed that decreased BMP-7 expression is related to progression to a more aggressive form of prostate cancer²⁶. Horvat et al have also suggested that decreased BMP-2 expression was related to progression of prostate cancer since inhibitory effect was absent²¹. Ide et al demonstrated that recombinant BMP-2 treatment in the presence of androgen inhibits cellular proliferation of androgen-responsive LNCaP cells³⁴. Another report demonstrated that recombinant BMP-2 had anti-proliferative effects *in vitro* on multiple tumors including breast and lung cancers³⁶. Feeley et al showed that BMP-2 in dose dependent fashion effected small decrease in cell proliferation while there was no effect on cell proliferation with BMP-4 and BMP-7 at any concentration³⁸. BMP-7 was found positive in metastatic breast cancer⁴. The results of BMP-6 expression were more controversial. Several reports revealed elevated BMP-6 expression in metastatic prostate cancers^{19–21}, while Barnes et al has not found increased expression of BMP-6 in higher grade tumors²². Contrary, we found significantly decreased expression of BMP-6 in metastatic prostate cancers. BMP-6 inhibited cell proliferation although the antiproliferative response of prostate cancer cells to BMP-6 seems contrary to the established correlation between aggressive cancer and elevated BMP-6 expression³⁹.

BMPR-IA, BMPR-IB and BMPR-II were expressed by epithelial and in some cases by stromal cells in all samples of normal human prostate what is in correlation with previous results^{30,31,34}. There were no significant differences in BMPRs expression between normal and localized prostate cancers. However, in metastatic prostate cancers we found lower expression of all three BMPRs

compared with normal or localized prostate cancers. BMPR-IA expression was significantly decreased in metastatic prostate cancers. Furthermore, BMPR-II expression was completely lost because less than 10% of positive cells were found in only 3 out of 21 metastatic prostate cancer samples. Kim et al have previously demonstrated loss of expression of the three BMP receptors in higher grade prostate cancers, but only loss of BMPR-II correlated with 5-year survival rate^{30,31}. Loss of BMPR-II expression will disrupt the function of heteromeric complex of membrane receptors as BMPR-II is necessary part for receptor activation. This was confirmed with *in vitro* experiment in which BMP-6 inhibits PC3M cellular proliferation but in the cases when prostate cancer cell lines was transfected by dominant-negative BMPR-II, strong inhibitory effect of BMP-6 on cell growth and proliferation was absent²³. They have suggested that the neutralization of BMP signaling led to an increased tumorigenic potential of the PC3M prostate cancer cell line³¹. Ide et al have reported that BMPR-IB is androgen dependent and they have found significantly lower amount of BMPR-IB mRNA in all the prostate cancer tissues after androgen withdrawal³³. In our cases the tissue samples of prostate cancers were collected from the patients with newly diagnosed prostate cancer and still with normal androgen function. That can be an explanation of rather similar expression of BMPR-IB that we found between normal prostate tissue and prostate cancers.

We examined tissue samples of skeletal metastases caused by prostate cancer. BMP-2/4, -6 and -7 were expressed by metastatic cancer cells. Previous results have shown that osteoblastic bone lesions caused by prostate cancer expressed BMP-6 and -7^{25,29}. Additionally, BMP-7 expression was not detected in normal bone tissue, unlike BMP-6 expression that was identified in normal osteoblasts in skeletal tissue^{25,29}. The expression of highly osteogenic BMPs in bone microenvironment in metastatic cells possibly leads and facilitates the formation of osteoblastic bone lesions. The expression of BMPRs in prostate cancer metastatic cells is probably low to prevent the possible inhibitory effect of BMPs on cancer cells growth.

In conclusion for the first time in our study we have examined the expression of BMPs and BMPRs in the same tissue samples of normal prostate, metastatic and nonmetastatic prostate cancer. We have proved the significant decrease of BMPs and BMPRs expression with the progression of prostate cancer suggesting BMPs important inhibitory role. Since, the expression of BMPs and BMPRs is similar in normal prostate and nonmetastatic prostate cancer we can conclude that BMPs have insignificant or no influence on the onset of malignant disease but can control the malignant disease progression especially bone metastasing. Also for the first time we showed high expression of osteogenic BMPs in osteoblastic prostate cancer bone metastases as a possible explanation of their osteosclerotic characteristics.

REFERENCES

1. JACOBSEN SJ, KATUSIC SK, BERGSTRALH EJ, JAMA, 274(18) (1995) 1445. — 2. LU-YAO GL, GREENBERG RC, Lancet, 343 (1994) 251. — 3. KELLER ET, BROWN J, J Cell Bioch, 91(4) (2004) 718. — 4. BOBINAC D, MARIĆ I, ZORIČIĆ S, ŠPANJOL J, DJORDJEVIĆ G, FUČKAR Z, Croat Med J, 46(3) (2004) 389. — 5. SPANJOL J, MARICIC A, CICVARIĆ T, VALENČIĆ M, OGUIĆ R, TADIN T, FUČKAR D, BOBINAC M, Coll Antropol, 31(1) (2007) 235. — 6. ŠPANJOL J, MARIČIĆ A, VALENČIĆ M, OGUIĆ R, KRPINA K, PROTIĆ A, IVANČIĆ A, BOBINAC M, FUČKAR D, VOJNIKOVIC B, Coll Antropol, 32(Suppl 2) (2008) 79. — 7. BERNAT MM, PASINI J, MAREKOVIĆ Z, Coll Antropol, 29(2) (2005) 589. — 8. VODOPIJA N, ZUPANČIĆ M, KORŠIĆ L, KRAMER F, PARAČ I, Coll Antropol, 28(1) (2004) 429. — 9. ŠTIMAC G, DIMANOVSKI J, TRNSKI D, KATUŠIĆ J, RUŽIĆ B, SPAJLIĆ B, RELJIĆ A, PADOVAN M, KRAUS O, Coll Antropol, 31(4) (2007) 1055. — 10. CHOONG PF, Clin Orth Rel Res, 415 (2003) 19. — 11. LEE Y, SCHWARZ E, DAVIES M ET AL, J Orthop Res, 21 (2003) 62. — 12. KOENEMAN KS, YEUNG F, CHUNG LW, Prostate, 39 (1999) 246. — 13. COOPER CR, CHAY CH, GENDERNALIK JD, Cancer, 97 (2003) 739. — 14. URIST MR, Science, 150 (1965) 893. — 15. WOZNEY JM, ROSEN V, CELESTE AJ, Science, 242 (1988) 1528. — 16. SAMPATH TK, MALIAKAL JC, HAUSCHKA PV, J Biol Chem, 267 (1992) 20352. — 17. WOZNEY JM, Spine, 27 (2002) S2. — 18. CHENG H, JIANG W, PHILLIPS FM, J Bone Joint Surg Am, 85-A (2003) 1544. — 19. HARRIS SE, HARRIS MA, MAHY P, Prostate, 24(4) (1994) 204. — 20. BENTLEY H, HAMDY FC, HART KA, Br J Cancer, 66 (1992) 1159. — 21. HAMDY FC, AUTZEN P, ROBINSON MC, Cancer Res, 57 (1997) 4427. — 22. BARNES J, ANTHONY CT, WALL N, STEINER MS, World J Urol, 13 (1995) 337. — 23. HORVATH LG, HENSHALL SM, KENCH JG, Prostate, 59 (2004) 234. — 24. MASUDA H, FUKABORI Y, NAKANO K, SHIMIZU N, YAMANAKA H, Prostate 59(1) (2004) 101. — 25. AUTZEN P, ROBSON CN, BJARTELL A, Brit J of Cancer, 78 (1998) 1219. — 26. THOMAS BG, HAMDY FC, Prostate Cancer Prostatic Dis, 3 (2000) 283. — 27. DAI J, KELLER J, ZHANG J, Cancer Res, 65(18) (2005) 8274. — 28. FEELEY BT, GAMRADT SC, HSU WK, J Bone Mineral Res, 20(12) (2005) 2189. — 29. MASUDA H, FUKABORI Y, NAKANO K, Prostate, 54 (2003) 268. — 30. KIM IY, LEE DH, AHN HJ, Cancer Res, 60 (2000) 2840. — 31. KIM IY, LEE DH, LEE DK, Oncogene, 23 (2004) 7651. — 32. TEN DIJKE P, YAMASHITA H, SAMPATH TK, J Biol Chem, 269 (1994) 16985. — 33. KIM IY, LEE DH, LEE DK, Clin Cancer Res, 9 (2003) 6046. — 34. IDE H, KATOH M, SASAKI H, Oncogene, 14 (1997) 1377. — 35. EBLE JN, SAUTER J, EPSTEIN JI, SESTERHENN IA, World Health Organisation classification of tumors. Tumors of the urinary system and male genital organs (IARC Press, Lyon, 2004). — 36. SIMIC P, VUKICEVIC S, Cytokine Growth Factor Rev, 16 (2005) 299. — 37. SODA H, RAYMOND E, SHARMA S, Anti-cancer Drugs, 9 (1998) 327. — 38. FEELEY BT, KRENEK L, LIU N, HSU WVK, GAMRADT SC, Bone, 38 (2006) 154. — 39. HAUDENSCHILD DR, PALMER SM, MOSELEY TA, YOU Z, REDDI AH, Cancer Res, 64 (2004) 8276.

J. Španjol

*Department of Urology, University Hospital of Rijeka, T. Stržičica 3, 51000 Rijeka, Croatia
e-mail: jspanjol@vip.hr*

ULOGA KOŠTANIH MORFOGENETSKIH PROTEINA U PATOGENEZI HUMANOG KARCINOMA PROSTATE I RAZVOJU KOŠTANIH METASTAZA: IMUNOHISTOKEMIJSKA STUDIJA

SAŽETAK

Koštani morfogogenetski protein (BMP) imaju sposobnost indukcije ektopičnog stvaranja kosti¹⁻⁹. Njihova ekspresija u stanicama karcinoma prostate povezana je s tumorskom progresijom u kosti i razvojem osteosklerotičnih metastaza¹⁰⁻¹⁵. U ovoj studiji istražili smo obrasce ekspresije BMP-2/4, -6 i 7 te receptora BMPR-IA, IB i II u normalnoj humanojoj prostati, organ ograničenom karcinomu prostate i metastatskom karcinomu prostate. Ekspresiju smo istražili i u samim koštanim metastazama. U lokaliziranom karcinomu prostate uočili smo pojačanu ekspresiju BMP-6, a smanjenu BMP-2/4 i 7. U metastatskom karcinomu ekspresija BMP-a je smanjena. Ekspresija BMPR-a se smanjivala s progresijom karcinoma prostate, a ekspresija BMPR-II je potpuno odsutna u metastatskom karcinomu prostate. U koštanim metastazama karcinoma prostate pronašli smo ekspresiju BMP-2/4, -6 i -7. Smanjena ekspresija BMP-a i gubitak ekspresije BMPR-II može upućivati na inhibitornu ulogu BMP-a na stanice karcinoma prostate te na njihovu važnu ulogu u patogenezi karcinoma prostate. Izražena ekspresija osteogenih BMP-a u koštanim metastazama karcinoma prostate može objasniti njihovu osteosklerotičnu prirodu.