

# Amaurosis Fugax is in the First Place, During Attack, Medical Emergency for Ophthalmologist's Practice

Božo Vojniković<sup>1</sup>, Ines Strenja-Linić<sup>2</sup>, Aldo Ivančić<sup>3</sup>, Svatopluk Synek<sup>4</sup>, Vladimir Mićović<sup>5</sup> and Goran Bajek<sup>6</sup>

<sup>1</sup> Daily Eye Clinic »Dr. Božo Vojniković«, Rijeka, Croatia

<sup>2</sup> Department of Neurology, Rijeka University Hospital, Rijeka, Croatia

<sup>3</sup> Department of Thoracic and Vascular Surgery, Rijeka University Hospital, Rijeka, Croatia

<sup>4</sup> Department of Ophthalmology and Optometry, Saint Anne Hospital, Medical Faculty Masaryk University, Brno, Czech Republic

<sup>5</sup> Teaching Institute of Public Health of Primorsko-Goranska County, Rijeka, Croatia

<sup>6</sup> Department of Neurosurgery, Rijeka University Hospital, Rijeka, Croatia

## ABSTRACT

*This paper is focused on disease Amaurosis Fugax (AF), indicating the necessary urgent therapy in attack of illnesses. In attack, the patient represents ophthalmic case, because of vision lost, but primary process and cause exists even earlier and very often is of chronic character. Authors emphasize sequencing in therapy of AF and accentuate that in 24 hours the cause of the disease may be defined. AF is a syndrome with very different etiopathogenesis, including also big complexity in diagnosis and therapy.*

**Key words:** amaurosis fugax, etiology, ophthalmic medical treatment

## Introduction

Etiology and pathophysiology of amaurosis fugax (AF) is very complex. It is usually defined like quickly developed, monocular blindness with short duration, named: transient monocular blindness (TMB)<sup>1</sup>. In classification we differentiate four types: angiospasm, retinal and cortical visual center hypoperfusion, embolic-thrombosis causes and migraine as idiopathic<sup>2-4</sup>. Clinically we can speak about: carotid stenosis and carotid emboli, retinal and retinocortical vasospasm, atherosclerosis with hypertension, blood hyper viscosity and coagulation disorders, especially by diabetics, as well as migraine. These are circulation disorders, but also they can be results of ocular reasons as: angle closure glaucoma<sup>5-8</sup> (intermittent), retinal and vitreous detachment, vitreoretinal hemorrhage, intracranial tumor and papilledema, optic neuritis. Typical neurological causes may include: multiple sclerosis, psychogenic, intracranial tumors and migraine<sup>3,4</sup>. But there is also transient bilateral blindness, like: bilateral microvascular disorders of the optic nerve

in diabetics, migraine, and vertebro-basilar loss blood supply. The basic question is what we can do? Generally, this kind of patients does many examinations, including sometimes vascular surgeon. First of all, patient is coming to ophthalmologist because of blindness. After the examination, patient has to go to neurologist (Doppler of arterial carotis communis, etc.) and then to vascular surgeon. Figure 1 shows the possible examinations and then usually the patient is going to surgery. During this diagnostic proceeding, the problem of vision is on the second place. But Amaurosis fugax is a typical process treatment – »best medical management«<sup>2,3</sup>. Simultaneously, it has to be done: ophthalmic emergency treatment with parabolbar capillary protectors agents, with pharmacological effects of: inhibits platelet aggregation induced by ADP<sup>9,10</sup>, reduced whole-blood and plasma hyperviscosity, erythrocyte flexibility improved and platelet hyperaggregation decreased<sup>11-14</sup> (Figures 2 and 3). Ophthalmologist has to react very quickly: vision and visual field ana-

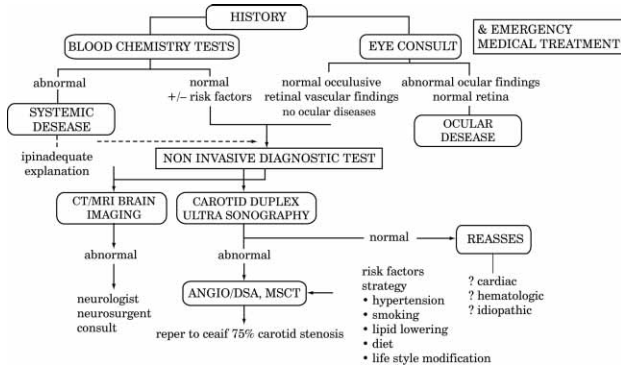


Fig. 1. Diagnostic workup of patients with amaurosis fugax.

lyse, intraocular pressure, fundus, and anamnesis. This is emergency because the patients have blindness but etiological causes exist for a long time earlier and very often are chronic characters. Our appearance is focused on AF, and then is including other examinations to find the cause.

**Patients and Methods**

Our 30-years clinical experience includes 87 cases of AF. In majority (57%) the cause was stenosis of carotids. In that time the possible examinations were poor and patients were in ophthalmic treatment predominant, because vision rehabilitation. In all cases in therapy was retrobulbar injection of Priscol. In 15% the visus were complete recovered, but the injection has to be given in 1 hour after the attack. In 50% recovery was stop on visus 0.6 and 35% of others visus were under 0.1, mostly caused because of late coming to ophthalmologist or some other chronic diseases.

**Case Report**

The specificity of this case what we will represent is medical treatment, as well as, specificity in rehabilitation of damaged vision with AF.

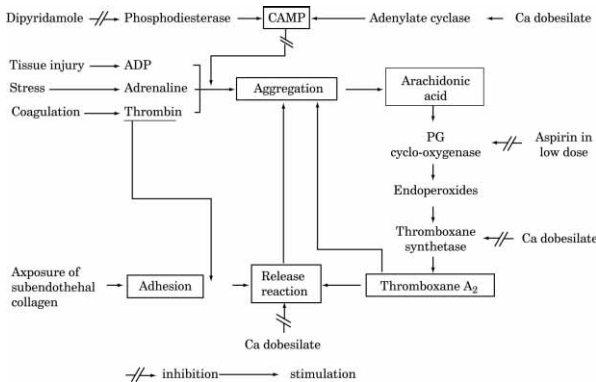


Fig. 2. Scheme representing the site of actions of: Aspirin, Dipyridamole and Calcium Dobesilate (Doxium) on the mechanisms controlling platelet function.

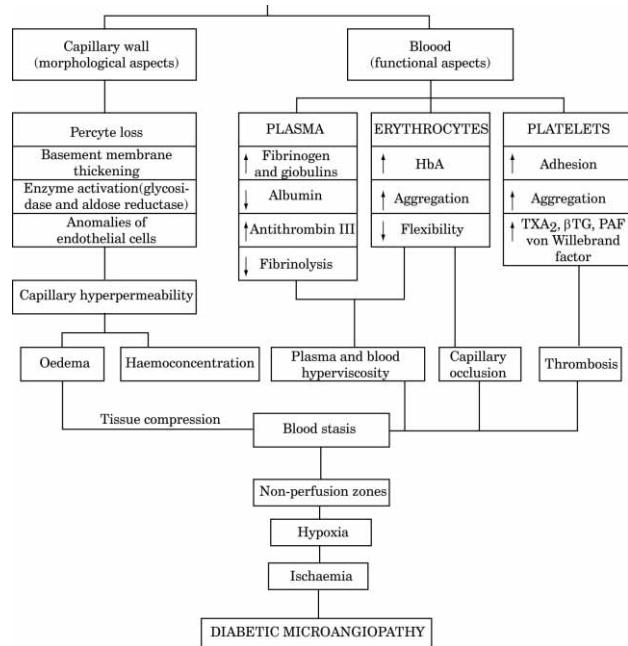


Fig. 3. Hemorrhheological disorders in diabetics (A. de Courten and B. Vojniković).

The patient was woman, 71 years old, with migraines during last 20 years. Patient also suffered from hypertension and diabetes mellitus type II. November the 29th 2009 patient came to hospital as an urgent case of AF of left eye. The complete diagnosis was: opticoretinopathy, lesion of optic nerve-praechiasmatic, macular edema, swelling of optic disc and Age-Related Macular Degeneration (AMD). The patient was ordered to make visual field after 45 days and in meantime came Doppler finding which was normal. After 20 days the patient went to our institution on consultation with our team experts (ophthalmologist, neurologist, neurosurgeon, vascular surgeon and epidemiologist), because the visus was 0.5/60. After our ophthalmic analyses, the findings were: bilateral macular edema, l>d, the picture of left fundus (Figure 4) has shown the presence of: Hollenhorst plaque (a) in nasal inferior branch of retinal artery<sup>7</sup>, and microangiopathy of macular region with Guist's mark (b). Visual field analysis (Figure 5) of right eye has shown defect of peripheral and central isopters, while on the left eye it was impossible to define because of an existing amaurosis. Ophthalmodynamometric finding has indicated very low perfusion of the central retinal artery, left 7 mmHg in comparison with 35 mmHg in right artery. Color Duplex Dopler (Figures 6a and b) revealed: normal finding of ACC, ACI, ACE and Ophthalmic artery. The patient received parabolbar therapy (depo 1 mL of 30 mg Pentoxifyllinum, 2 mL of 250 mg Dicynone (Etamsylate)) and 3x2 tablets of Doxium (Ca-Dobesilate) daily permanently for four days. After five days the vision of left eye was 0.8 and the vision of right eye on 0.9. Visual fields have shown bilateral almost normal findings. Perfusion

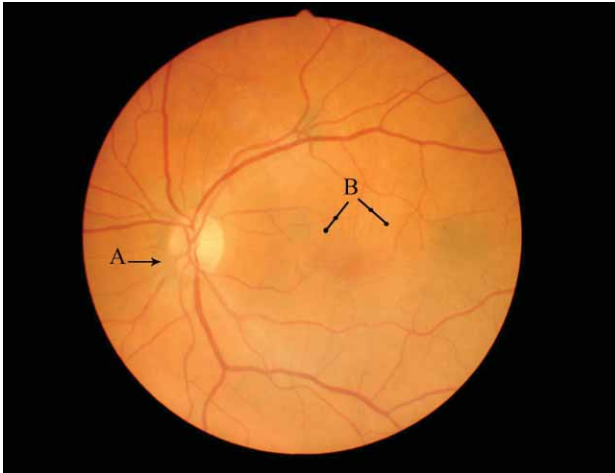


Fig. 4. Fundus picture with visible Hollenhorst and Guist sign.

of left central retinal arteria was 45 mmHg and right was 65 mmHg. Figure 7 shows visual field after parabolbar therapy procedure: on the left eye is practically normal finding, with both isopters, and on the right eye is also improved visual field.

### Results and Discussion

Our earlier experience, particularly this case of AF, has shown very clear that clinical features of this disease

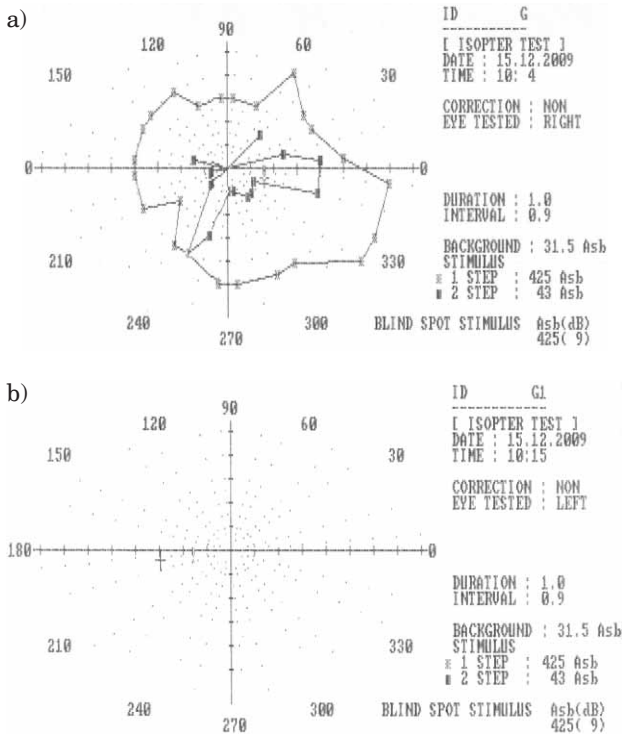
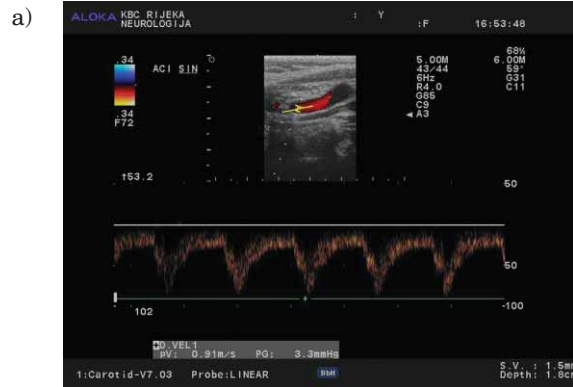


Fig. 5. Visual field analysis a) Right eye – showing constriction of inner and outer isopters, b) Left eye – without perception (amaurosis).



Depth [mm] 64	Max: 66.0/20.3	
Sample Volume [mm] 12	Mean 34.0/12.1	
Gain [%] 38	Min 11.3/4.7	
Power [ISPTA] 100	PI 1.0/1.3	
Scale [Hz] 4525	RI 0.8/0.8	
Label: A.OFT SIN	S/D 5.8/4.4	
	CCP 0.0/0.0	
Depth [mm] 67	Max: 73.0/22.3	
Sample Volume [mm] 12	Mean 42.7/12.7	
Gain [%] 38	Min 20.3/0.0	
Power [ISPTA] 100	PI 1.2/2.6	
Scale [Hz] 5525	RI 0.7/1.0	
Label: A.OFT DEX	S/D 3.6/0.0	
	CCP 0.0/0.0	

Fig. 6. a) Transcranial Doppler sonography of aa.ophtalmic – physiological flow through both aa.ophtalmicae b) Doppler sonography of normal internal carotid artery.

are very different and lost of vision may be very long time, but its rehabilitation is possible. It is difficult to un-

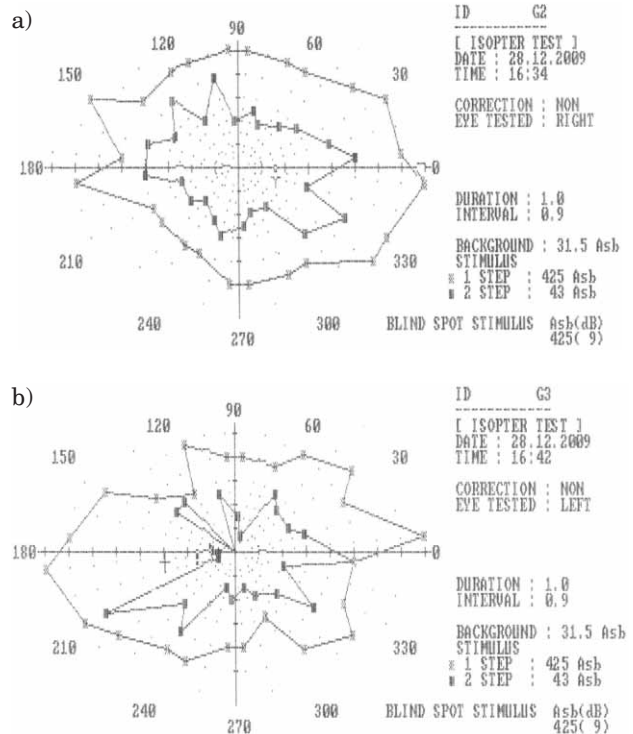


Fig. 7. Visual field analysis a) left eye after treatment showing almost normal finding, b) right eye also showing visual field improvement.

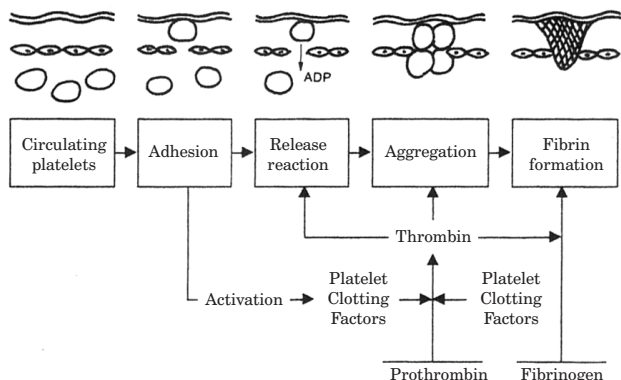


Fig. 8. Evolution of a platelet-fibrin thrombus following the disruption of the epithelium. (A. de Courten and B. Vojniković).

derstand the principle of improvement after parabolbar therapy even on right eye. Normal Doppler finding has indicated that functionally the circulation in ACI and ophthalmic artery was not compromised. Migraine represents etiologically the idiopathic form of AF. Nevertheless, etiological factor was also diabetes, which may be accompanied with many hematological disorders (Figures 2 and 3). Figures 8 and 9 show the effects of

Ca-Dobesilate on some hematological factors: flexibility of erythrocytes, blood viscosity, cholesterol level, reduces fibrinogen concentration, inhibits blood platelets aggregation, etc, which may reduce the risk of thrombosis and capillary occlusion. Pentoxifyllinum influence on the flexibility of erythrocytes and coagulation of trombocytes. Because of that, the patient had interruption in circulation of central retinal artery, central and periphery, mostly in left eye, but particularly also in right eye. Diameter of ophthalmic artery is too large, that come the stop of retinal supply, and consequently the Doppler was normal.

### Conclusion

Based on this case, we can conclude that AF represents the ophthalmic urgent case, which has to be accompanied with best medical management<sup>7</sup>, especially immediately after attack. Only one hour is needed for complete ophthalmic care and then patient has to go to neurologist and maybe to neurosurgeon or vascular surgeon (Figure 1). Lost of vision represents the acute symptom of disease, but primary etiology is chronic character and exists earlier. AF is an syndrome because of it's complexity of symptoms and unique clinic manifestations.

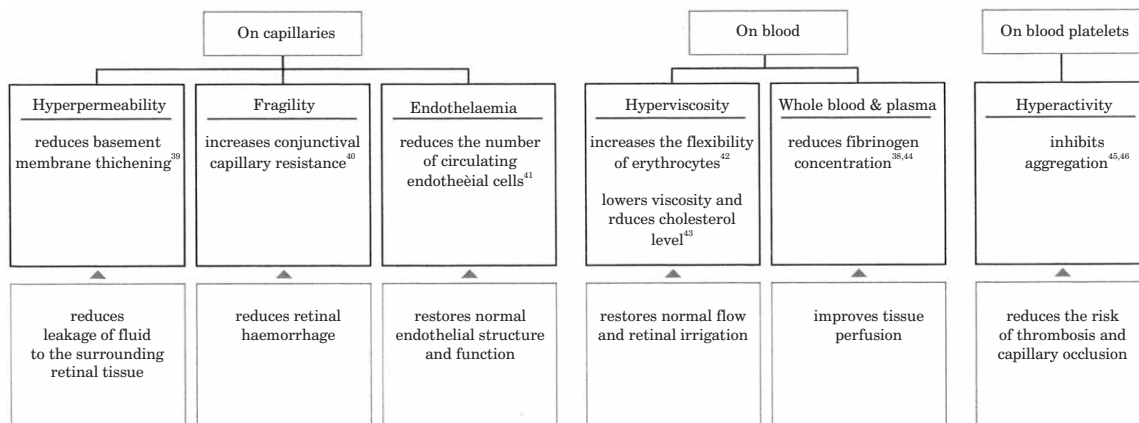


Fig. 9. Calcium Dobesilate (Doxium-500): pharmacological effects (A. de Courten and B. Vojniković).

### REFERENCES

1. WRAY S, J Neurol Neurosurg Psychiatr, 56 (1993) 234. — 2. PARKIN P, KENDALL B, MARSHALL J, McDONALD W, J Neurol Neurosurg Psychiatry, 45 (1982) 45. — 3. TIPPIN J, CORBETT J, KERBER R, SCHROEDER E, THOMPSON H, Ann Neurol, 26 (1989) 69. — 4. WJMAN C, GOMES J, KOLEINI B, MATJUCHA I, Stroke, 35 (2004) 100. — 5. GREENBERG MS, Handbook of Neurosurgery (Thieme, Stuttgart, 2006). — 6. DAVIDESCU I, NICA S, Romanian Journal of Neurology, 3 (2007) 118. — 7. BRAUNWALD E, Braunwald's Heart Disease: A Textbook of Cardiovascular Medicine (Saunders, Philadelphia, 2007). — 8.

VOJNIKOVIC B, Primarni glaukomi (Manualia Societatis »Chirurgia Ophthalmo-Cranio-Orofacialis Croatica«, Rijeka, 2000). — 9. SALAMA BENARROCH I, Acta Therapeutica, 13 (1987) 256. — 10. DE COURTEN A, Review of Clinical Pharmacology and Pharmacokinetics, 1 (1984) 270. — 11. VOJNIKOVIC B, Ophthalmologica 167 (1973) 15. — 12. VOJNIKOVIC B, Ophthalmic Res, 16 (1984) 150. — 13. VOJNIKOVIC B, Ophthalmic Res, 23 (1991) 12. — 14. VINAZZER H, HACHEN H, J Vasa, 16 (1987) 190.

*Daily Eye Clinic »Dr. Božo Vojniković«, A. Barca 3b, 51000 Rijeka, Croatia  
e-mail: decv@decv.com*

## **AMAUROSIS FUGAX JE PRVENSTVENO OFTALMOLOŠKA HITNOST POČETKOM ATAKE**

### **S A Ž E T A K**

Autori etiološki obrađuju oboljenje Amaurosis Fugax (AF), naglašavajući hitnost tretmana u ataci. Naglašava se da u toku atake, bolesnik je prvenstveno oftalmološki kazu, jer treba hitno spašavati vid koji je akutno ugrožen, dok je primaran proces i uzrok AF postojao mnogo ranije, često kroničnog karaktera. Autori se zalažu za striktno određeni redoslijed obrade bolesnika sa AF, te se praktički unutar 24 sata može definitivno dijagnosticirati uzrok. Smatra se da je AF u biti sindromno oboljenje, premda vrlo različite etiologije, pa je stoga i takav bolesnik u biti vrlo kompleksan u dijagnostičkom i terapijskom smislu.