

Pyostomatitis Vegetans Associated with Inflammatory Bowel Disease – Report of Two Cases

Brankica Mijandrušić-Sinčić¹, Vanja Licul¹, Lari Gorup², Nada Brnčić², Irena Glazar³ and Ksenija Lučin⁴

¹ Division of Gastroenterology, Department of Internal Medicine, University Hospital Center Rijeka, Rijeka, Croatia

² Department of Infectious Diseases, University Hospital Center Rijeka, Rijeka, Croatia

³ Department of Oral Medicine and Periodontology, School of Dental Medicine, University of Rijeka, Rijeka, Croatia

⁴ Department of Pathology, School of Medicine, University of Rijeka, Rijeka, Croatia

ABSTRACT

Pyostomatitis vegetans (PV) is a rare, chronic mucocutaneous disorder associated with inflammatory bowel disease (IBD). Oral lesions of PV are distinct and present as multiple white or yellow pustules with an erythematous base that coalesce and undergo necrosis to form a typical »snail tracks« appearance. Two cases of PV associated with IBD – one with Crohn's disease (CD) and the other with ulcerative colitis (UC) are reported. In the first case, adalimumab therapy brought the oral and gastrointestinal manifestations to complete remission. In the second case, the remission was achieved with systemic steroid therapy, but the disease relapsed after therapy discontinuation. Azathioprine was added leading to sustained remission of PV. Because of persistent active intestinal manifestation of UC, in spite of immunosuppressive therapy, infliximab was introduced. With the therapy remission of intestinal manifestation of UC was achieved as well. Our cases confirm previously reported good experience with immunomodulators and biologics in the treatment of PV. But, before using them we have to exclude an infectious etiology of oral lesions.

Key words: pyostomatitis vegetans, inflammatory bowel disease, corticosteroids, azathioprine, adalimumab, infliximab

Introduction

Extraintestinal manifestations of inflammatory bowel disease (IBD) can involve any organ system¹. Pyostomatitis vegetans (PV) is a rare chronic mucocutaneous disorder associated with IBD^{1–3}. PV represents an oral equivalent of pyodermitis vegetans on skin^{4,5}. Oral lesions of PV are distinct and appear as multiple white or yellow pustules with an erythematous base that coalesce and undergo necrosis to form a typical »snail tracks« appearance^{6,7}. PV is an oral mucosal indicator of possible IBD existence^{3,4}.

We report two cases of PV associated with IBD – one with Crohn's disease (CD) and the other with ulcerative colitis (UC).

Cases Report

Case 1. A 23-year-old woman with history of luminal, corticosteroid dependent CD involving terminal ileum and colon experienced an episode of acute pancreatitis

caused by azathioprine. During pretreatment screening for biological therapy she presented with yellow, linear pustules and multiple ulceration on erythematous labial and buccal mucosa. Deep fissures were present on the ventral side of tongue (Figure 1). Histological examination of a biopsy specimen removed from the buccal mucosa showed subepithelial and intraepithelial inflammatory infiltrate containing numerous eosinophils consistent with the diagnosis of PV (Figure 2). Culture showed normal oral flora. Adalimumab therapy was started and the patient achieved remission of intestinal and oral pathology (Figure 3).

Case 2. A 32-year-old woman with history of UC presented with yellowish, slightly elevated, pustules on the erythematous soft palatal mucosa and mucosa of the dorsal side of tongue (Figure 4) which occurred after stopping corticosteroid therapy. The patient complained of severe pain, which interfered with food ingestion. Histological examination of a biopsy specimen removed from the dorsal side of tongue showed intraepithelial and subepithelial exudates containing numerous granulocytes

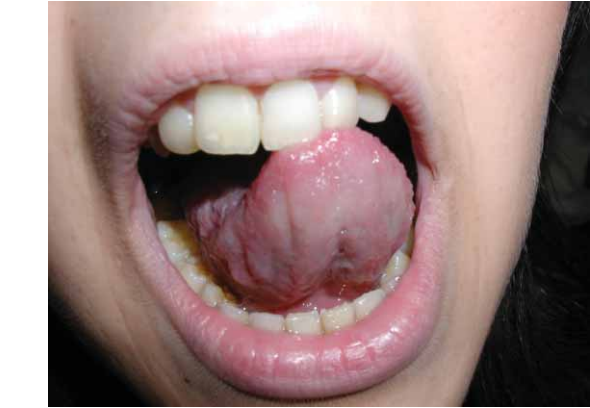

Fig. 3. Complete remission of lesions on the ventral side of tongue in patient with pyostomatitis vegetans after adalimumab therapy was started (compare with Fig. 1.).

tes including eosinophils (Figure 5). In subepithelial stromal tissue, a mixed inflammatory infiltrate containing granulocytes, lymphocytes and plasma cells was found. Based on these findings the diagnosis of PV was established. Culture showed normal oral flora. As steroid treatment with azathioprine was restarted oral pathology disappeared. Because of persistent active UC, in spite of immunosuppressive therapy, infliximab was introduced. Complete remission of intestinal and extraintestinal manifestation (PV) was achieved.

Discussion and Conclusion

Pyostomatitis vegetans (PV) is a rare chronic mucocutaneous disorder¹⁻³. PV was first reported by Hal-

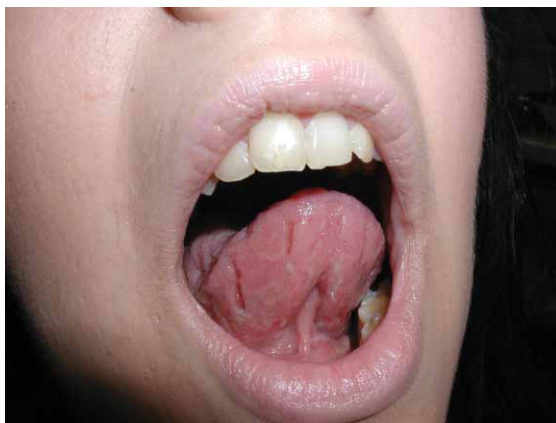

Fig. 1. Oral findings in patient with pyostomatitis vegetans and Crohn's disease – deep fissures on the ventral side of tongue.

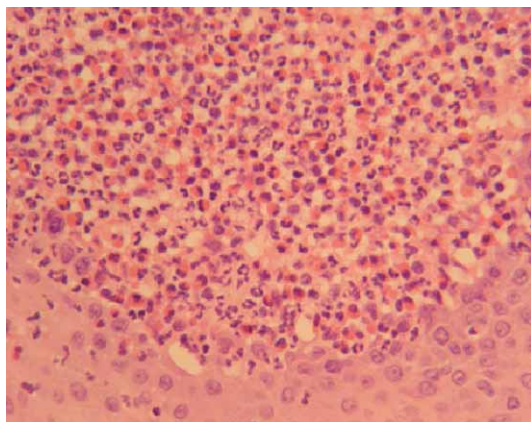


Fig. 2. Histological examination (HE staining, magnification 40x) of a biopsy specimen removed from the buccal mucosa of the patient with pyostomatitis vegetans showing subepithelial and intraepithelial inflammatory infiltrate containing numerous eosinophils.

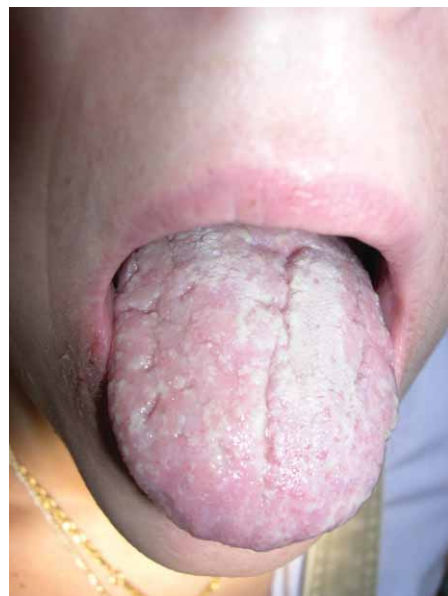

Fig. 4. Oral findings in patient with pyostomatitis vegetans and ulcerative colitis – pustules and fissures on the dorsal side of tongue.

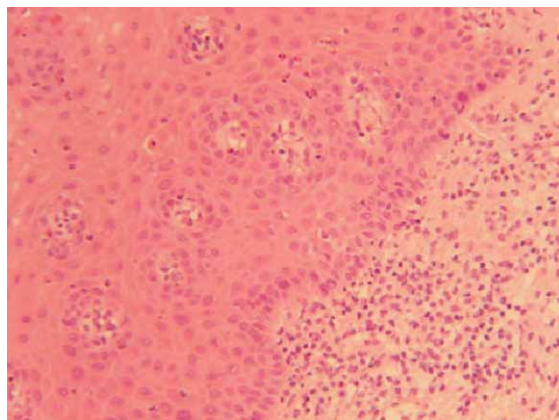


Fig. 5. Histological examination (HE staining, magnification 20x) of a biopsy specimen removed from the dorsal side of tongue showing intraepithelial and subepithelial exudate containing numerous granulocytes including eosinophils.

peau in 1898, who described five cases with vegetating pustular dermatosis called »pyodermite vegetante«⁶, two of which had oral localization. In 1949 McCarthy introduced the name »pyostomatitis vegetans« after observing this lesion isolated to the oral cavity⁶. Since then not more than 50 cases have been reported in the literature^{2,8}.

PV affects patients at any age, but the prevalence is highest between 20–59 years^{3,6}. The disease is predominantly found in males^{3,6}.

Oral lesions of PV are distinct and appear as multiple white or yellow pustules with an erythematous base^{6,7}. Granular morphology of oral mucosa – resulting in a vegetating appearance – undergo degeneration leading to erosions and ulcer formation and subsequently to typical »snail tracks« appearance^{6,7}. Associated oral discomfort or pain is variable and it seems that is not in correlation with extension of oral lesions^{2,6}. PV represents the oral equivalent of pyodermitis vegetans on skin, but possibly PV and pyodermitis vegetans is the same entity^{4,5}.

The etiology of PV is unknown. Despite the name suggests possible infectious origin, cultures repeatedly yielded negative results for pathogenic bacteria, viruses and

fungi^{5,6,9}. There is strong association of PV with IBD^{3,4}, in most reported cases with UC. The bowel disease usually precedes oral manifestations³. In asymptomatic patients or those with minimal gastrointestinal disturbance, which can be overlooked, the finding of PV should be a reason to refer the patient for gastrointestinal evaluation^{3,4,10}.

The diagnosis of PV is based on clinical findings, association with IBD, peripheral eosinophilia, negative culture results and histological examination⁵. Microscopic examination reveals intraepithelial and/or subepithelial microabscesses containing eosinophils and neutrophils⁴. Differential diagnosis includes Neumann type of pemphigus vegetans, a variant of pemphigus vulgaris which in majority of cases manifests in the oral cavity^{7,11,12}.

Management of PV is often aimed at treating underlying IBD⁵. Topical corticosteroid therapy administration alone was successful only in few cases³, therefore systemic steroids are usually necessary^{2,8}. Resistance to corticosteroids and recurrence of PV after therapy discontinuation have been described⁸. Azathioprine, sulfamethoxypyridazine and dapsone have been also used⁵. In the case reported in 2003, infliximab followed by maintenance therapy with methotrexate were used leading to complete remission of both the PV and the CD⁸.

In our two cases, patients (23 and 32-year-old) were in typical age range in which the prevalence of PV is highest, but both were females, which is contrary to male predominance described in the literature. Clinical findings in the oral cavity, association with IBD (one with CD and the other with UC) and histological examination in both our patients were typical for PV. IBD preceded the appearance of PV as it was described in most reported cases^{2,8}. In the first case, adalimumab therapy brought the oral and gastrointestinal manifestations to complete remission. In the second case, the remission of oral findings was achieved with azathioprine, while the remission of UC was achieved with infliximab.

In conclusion, our cases confirm previously reported satisfactory effects of immunomodulators and biologics in the treatment of PV. But, before using them we have to exclude an infectious etiology of oral lesions.

REFERENCES

1. JOSE FA, HEYMAN MB, *J Pediatr Gastroenterol Nutr*, 46 (2008) 124. — 2. RUIZ-ROCA JA, BERINI-AYTES L, GAY-ESCODA C, *Oral Surg Oral Med Oral Pathol Oral Radiol Endod*, 99 (2005) 447. — 3. CHAUDHRY SI, PHILPOT NS, ODELL EW, CHALLACOMBE SJ, SHIRLAW PJ, *Oral Surg Oral Med Oral Pathol Oral Radiol Endod*, 87 (1999) 327. — 4. STORWICK GS, PRIHODA MB, FULTON RJ, WOOD WS, *J Am Acad Dermatol*, 31 (1994) 336. — 5. FEMIANO F, LANZA A, BUONAIUTO C, PERILLO L, DELL'ZERMO A, CIRILLO N, *Med Oral Patol Oral Cir Bucal*, 14 (2009) E114. — 6. BALLO FS, CAMISA C, MIEN CM, *J Am Acad Dermatol*, 21 (1989) 381. — 7. SORIANO ML, MARTINEZ N, GRILLI R, FARINA MC, MARTIN L, REQUENA L, *Oral Surg Oral Med*

- Oral Pathol Oral Radiol Endod*, 87 (1999) 322. — 8. BENS G, LAHARIE D, BEYLOT-BARRY M, VERGIER B, NOBLESSE I, BEYLOT C, AMOURETTI M, *Br J Dermatol*, 149 (2003) 181. — 9. GIBSON J, WRAY D, BAGG J, *Oral Surg Oral Med Oral Pathol Oral Radiol Endod*, 89 (2000) 171. — 10. MERGULHAO P, MAGRO F, PEREIRA P, CORREIA R, LOPES JM, MAGALHAES J, DIAS JM, CARNEIRO F, TAVARELA-VELOSO F, *Dig Dis Sci*, 50 (2005) 1946. — 11. BRINKMEIER T, FROSCHE PJ, *Acta Derm Venereol*, 81 (2001) 134. — 12. MEHRAVARAN M, KEMENY L, HUSZ S, KOROM I, KISS M, DOBOZY A, *Br J Dermatol*, 137 (1997) 266.

B. Mijandrušić-Sinčić

Division of Gastroenterology, Department of Internal Medicine, University Hospital Center Rijeka, Krešimirova 42, 51000 Rijeka, Croatia

e-mail: brankica.sincic@medri.hr

PYOSTOMATITIS VEGETANS POVEZAN S UPALNOM BOLEŠĆU CRIJEVA – PRIKAZ DVA SLUČAJA

S A Ž E T A K

Pyostomatitis vegetans (PV) rijedak je kronični mukokutani poremećaj povezan s upalnom bolešću crijeva. Promjene u usnoj šupljini tipične za PV su višestruke bijelo-žute pustule s eritematoznom bazom koje konfluiraju i podliježu nekrozi oblikujući na taj način karakterističnu sliku poput »traga puža«. Prikazana su dva slučaja PV-a povezana s upalnom bolešću crijeva – prvi s Crohnovom bolešću, a drugi s ulceroznim kolitisom. U prvom slučaju liječenje adalimumabom rezultiralo je potpunom remisijom kako crijevnih tegoba tako i onih u ustima. U drugom je slučaju kortikosteroidna terapija rezultirala remisijom, no relaps PV-a uslijedio je prekidom liječenja. U terapiju je uveden azatioprin koji je doveo do remisije PV-a. Radi perzistentno aktivne crijevne simptomatologije uvedena je terapija infliksimabom čime je postignuta remisija crijevne manifestacije bolesti. Tijek liječenja naših bolesnika potvrđuje ranije opisanu učinkovitost imunosupresivne i biološke terapije u PV. Prije uvođenja terapije potrebno je isključiti infekciju kao uzrok lezija u usnoj šupljini.