

# Prevalence of Odontogenic Keratocysts Associated with Impacted Third Molars

Davor Planinić<sup>1</sup>, Ivana Bočina<sup>2</sup> and Berislav Perić<sup>3</sup>

<sup>1</sup> Dental practitioner, Međugorje, Bosnia and Herzegovina

<sup>2</sup> Department of Biology, Faculty of Science, Split, Croatia

<sup>3</sup> Department of Oral Surgery, University Hospital Dubrava, Zagreb, Croatia

## ABSTRACT

*In this study we analyzed the prevalence of the odontogenic keratocyst (OKC) associated with impacted third molars and evaluated OKC reactivity with the antibodies against cytokeratins (CK), particularly for CK10. Tissue samples were obtained from the proximity of the impacted molar. Differences between genders, age groups and localization of cysts were assessed using the  $\chi^2$ -test and relative risk (RR), and associated confidence interval. Cysts were found in 75 cases, and the radicular ones prevailed (63%), followed by follicular and OKC (13% and 12% respectively). The RR for the upper jaw cysts was almost twice greater than for the mandible. For the OKC exclusively, the upper-lower jaw RR was 1:2. The RR for all cysts increases with age, while decreases for the OKCs. The risk for the OKC occurrence decreased with age, with no significant differences between age groups. Finally, based on the results from this study we cannot suggest that the CK10 staining should be considered an useful marker in differential diagnosis of the OKCs.*

**Key words:** occurrence, localization, relative risk, cytokeratin, CK10

## Introduction

An odontogenic keratocyst (OKC) is a benign but locally aggressive developmental odontogenic cyst, firstly described in 1876<sup>1</sup> and named by Phillipson in 1956<sup>2</sup>. It is one of the most aggressive odontogenic cysts of the oral cavity. OKC is known for its rapid growth<sup>3–5</sup> and its tendency to invade the adjacent tissues including bone<sup>1,5–7</sup>. It has a high recurrence rate<sup>5,8,9</sup> and is associated with the basal cell nevus syndrome<sup>10,11</sup>. OKC is generally thought to be derived from either the epithelial remnants of the tooth germ, or the basal cell layer of the surface epithelium<sup>12–16</sup>. The majority of patients are in the age ranges of 20–29 and 40–59<sup>17</sup>, but cases ranging from 5 to 80 years have been reported<sup>18,19</sup>. Gender distribution varies from equality to a male to female ratio of 1.6:1, except in children<sup>18,20–22</sup>. OKC may occur in any part of the upper and lower jaw with the majority occurring in the mandible, most commonly in the angle of the mandible and ramus<sup>17,18,21,23,24</sup>. Radiographically, OKC is presented predominantly as unilocular radiolucency with well-developed sclerotic borders. OKC can be associated, al-

though not in all cases, with a previously impacted third molar<sup>25</sup>. Radiographically, it appears as a unilocular or multilocular lesion with a scalloped contour. These characteristics are suggestive but not considered unequivocal proof for the definitive diagnosis of OKC because other lesions may exhibit similar features<sup>26</sup>. In the literature there is a controversy regarding the treatment of this lesion: some surgeons advocate conservative therapies, whereas others are in favor of an aggressive treatment: endoscopically assisted enucleation and curettage of large mandibular odontogenic keratocyst<sup>27</sup>. Conservative management includes enucleation, curettage, marsupialization, and decompression<sup>28</sup>. Aggressive therapies consist of enucleation with chemical curettage<sup>29</sup> or resection with or without loss of jaw continuity<sup>30</sup>.

Cytokeratins are the main structural proteins in epithelial cells comprising a wide series of polypeptides ranging from 40 to 67 kilodaltons (kD) molecular weight. They belong to acidic (type I or A) and basic (type II or B)

sub-families according to their charges, immunoreactivity and amino acid sequences. Cytokeratin patterns differ in the different types of oral epithelium: the non-keratinized stratified squamous epithelium of normal oral mucosa, from the keratinized epithelium of the gingiva and from that on the dorsum of the tongue. Studies done on cytokeratin expression and other tissue markers in dysplastic and neoplastic oral epithelium led to the conclusion that the presence of true keratinization was not a distinguishing feature of keratocysts and that the more reliable diagnostic features would be the presence of an accentuated basal cell layer, maturation of the cells towards the surface and immunohistochemically, the presence of keratins 8, 18 and 19 in the basal and suprabasal cells, while some studies have found that the CK10 staining have to be considered as useful marker in differential diagnosis of the OKC<sup>31–35</sup>.

The aims of this study were to: (1) determine the prevalence of the OKC associated with impacted third molars, (2) to evaluate OKC reactivity with the antibodies against cytokeratins (CK), particularly for CK10, and to compare it with reactivity of dentigerous cysts (DC).

**Materials and Methods**

We have analyzed all operations performed during the year 2005 at the Clinic for Maxillofacial and Oral Surgery, University Hospital Dubrava Zagreb. The investigation was performed using 10 tissue samples, obtained during the alveotomy of the lower molars. We selected tissue samples obtained from patients where cyst was clearly observable near the impacted molar. Tissue material was divided in two parts. The first part was sent for the usual PHD examination, and the second part of the material was selected for the experiment presented herein. The tissue which was kept for the immunohistochemical investigations was fixated using the 4% paraformaldehyde. Additionally, the data from the medical documentation were examined.

In this study we analyzed OKC reactivity with following antibodies obtained by DAKO, Glostrup, Denmark: Anti-Human Cytokeratin MNF116; Anti-Human Cytokeratin 7; Anti-Human Cytokeratin 8; Anti-Human Cytokeratins LP34, 34βE12, 35βH11; and Anti-Human Cytokeratin 10.

In the first part of the data processing, counts and proportions were calculated. Differences between groups were established using the (1)  $\chi^2$ -test, and (2) relative risk (RR) – the risk of an event (or of developing a disease), and associated confidence interval (CI). The level of the significance of 95% ( $p < 0.05$ ) was applied for all analyses.

**Results and Discussion**

In the year 2005, 997 cases of the operative alveotomies associated with impacted molars were done at the Clinic for Maxillofacial and Oral Surgery, University Hospital Dubrava Zagreb (Table 1). The mandible was significantly more operated than the maxilla in females and males.  $\chi^2$ -test revealed significant differences between genders in the operative treatments. More precisely, female patients were more often involved in the operational procedures we studied herein. The majority of the operated patients were within the age range of 20–30, and the differences between age groups were significant. The cysts were found in 75 cases and their distribution is presented in the Figure 1.

When comparing the cysts associated with impacted molar and its occurrence in upper and lower jaw, the prevalence of the cysts in the upper jaw is almost twice as high as the prevalence of the cysts in the lower jaw (statistically significant). If the comparison is delimited for the OKC occurrence exclusively, the condition is reverted, but not statistically significant, meaning that the occurrence of the OKC in the mandible is twice to that in maxilla, but because of the delimited degrees of freedom

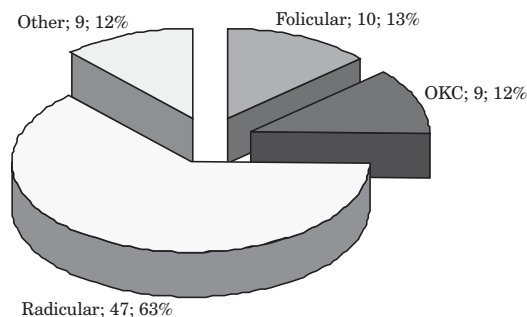


Fig 1. Types of cysts found.

**TABLE 1**  
DISTRIBUTION OF ALL OPERATIONS ASSOCIATED WITH IMPACTED MOLARS ACCORDING TO GENDER AND AGE OF THE PATIENTS;  
 $\chi^2$  SIGNIFICANCE (P – LEVEL OF THE SIGNIFICANCE)

	Gender		$\chi^2$ (p)	Age (years)			
	Males (N)	Females (N)		<20 (N)	20–30 (N)	30–40 (N)	>40 (N)
Upper jaw	72	142	<0.001	119	599	147	112
Lower jaw	265	498	<0.001				
Total	337	640				<0.001	
$\chi^2$ (p)	<0.001	<0.001					

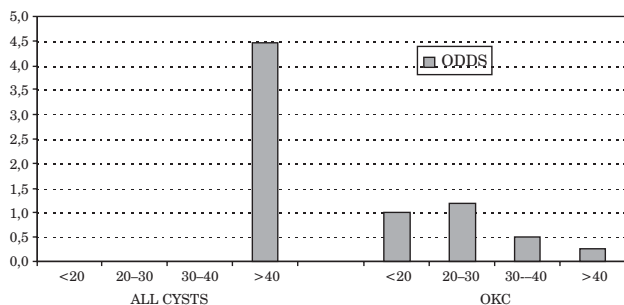


Fig. 2. Odds of the cysts' occurrence in each observed age group.

(e.g. small sample of cases), the numerical difference did not reach the appropriate level of statistical significance (RR=2.24; 95% CI=0.28–17.84;  $p=0.430$ ).

It is already known that OKCs have a tendency to occur in any part of the mandible and maxilla, but the majority, almost 70%, arise in the body of the mandible<sup>18</sup>. This is an area common to many benign but aggressive odontogenic tumors such as ameloblastoma. This is also a common location for dentigerous cysts and other odontogenic cysts. For example Lam et al.<sup>36</sup> reported that of the 43 OKCs identified, 25 developed in the mandible and 18 developed in the maxilla. In their study the majority were associated with a change in either the size or the shape of the follicular space. Similar occurrences (e.g. higher occurrence of the OKCs in mandible) are also reported in other studies<sup>37–39</sup>. Therefore, we can summarize that the data we have found shows consistency with previous investigations.

If observed separately in females and males, the situation is as follows: in males, we have found two times higher risk of cyst occurrence in the upper jaw (RR=1.09; 95% CI=0.12–9.75;  $p=0.940$ ), and no evident differences for the OKC (R=1.09;  $p=0.940$ ). In female patients there is no observable mandible-maxilla difference in the cyst occurrence (R=0.89;  $p=0.510$ ), and for the OKC we have found numerically evident, but not statistically significant risk for the lower jaw (RR=2.57;  $p=0.790$ ).

When comparing the OKC and other kinds of cysts the following can be concluded: there is 3.8 times more frequent OKC occurrence in the mandible than in the maxilla when operating the impacted third molar (R=3.77; 95% CI=0.50–28.42;  $p=0.150$ ) – not significant because of the small sample. We have found almost doubled risk for the incidence of cysts in males (RR=1.89;  $p<0.001$ ), and the risk is somewhat lower for the OKC incidence exclusively (RR=0.16;  $p=0.184$ ). Comparing this data with international reports<sup>21,40</sup> the overall gender distribution is virtually identical.

The risk of the cysts' occurrence increases with age and the majority of cases have been evidenced in the fourth decade of life (Odds ratio: 1 vs. 4.46;  $p<0.001$ ; when compared to age <20 years – see Figure 2). It is interesting that similar findings are reported in the studies

performed by Chen et al. 20 years ago<sup>20</sup> and Woolgar et al.<sup>21</sup>, and recently supported by findings of Oda et al.<sup>41</sup>.

However, for the OKC incidence the situation is reversed, and the risk of OKC occurrence decreases with age with no significant differences between age groups (see Figure 2). The similar findings were reported in previous studies. For example, Oda et al.<sup>41</sup> reported that the greatest frequency of the OKC in both genders occurred in the third life decade (e.g. 20–30 years of age). In the same study<sup>41</sup> authors have found decrease of the OKC occurrence in older patients.

In the second part of the study an immunohistochemical analysis on specimens of 5 DC and 5 OKC was done. Immunohistochemistry was performed by using monoclonal antibodies against CK7, CK8, CK10, and the antibody LP34, 34 $\beta$ E12, 35 $\beta$ H11 that reacts against group of cytokeratins (CK1, 5, 6, 8, 10, 14 and 18). The reactivity with antibody LP34, 34 $\beta$ E12, 35 $\beta$ H11 was positive and equal both with DC and OKC. With antibody against CK10 reactivity of all DC was negative and with OKC it was weak and patchy but only with very high concentrations of antibody. Therefore, it is clear that such diagnosis cannot be considered reliable and relevant method in distinguishing between these types of cysts. In other investigations done with the same objective as we had, authors suggested the possibility of distinguishing the cysts based on the differential reactivity with the CK10 antibody. Briefly, in mentioned studies<sup>42–45</sup> the reaction with the antibody was found for the OKC exclusively. However, our results do not support the observations that the CK10 staining has to be considered as a useful marker in differential diagnosis of the odontogenic cysts.

## Conclusion

In conclusion,

- In 997 cases of the operative alveotomies associated with impacted molars the mandible was significantly more operated than the maxilla.
- Cysts were found in 75 cases, and the radicular ones prevailed (63%), followed by follicular and OKC (13% and 12% respectively).
- The prevalence of the cysts in the upper jaw is almost twice as high as the prevalence of the cysts in the mandible. If the comparison is delimited for the OKC occurrence exclusively the condition is reverted, but – because of the small sample – not statistically significant.
- There is 3.8 times more frequent OKC occurrence in the mandible than in the maxilla.
- The risk of the cysts' occurrence increases with age, and the broad peak has been observed in the fourth life decade. On contrary, the risk of OKC occurrence decreases with age.
- We could not support the previous findings that the CK10 staining has to be considered as a useful marker in differential diagnosis of the odontogenic cysts.

## REFERENCES

1. VOORSMIT RA, The incredible keratocyst. MS Thesis. (The Catholic University of Nijmegen, Nijmegen, The Netherlands, 1984). — 2. PHILIPSEN HP, Tandlaegebladet, 60 (1956) 963. — 3. BROWNE RM, Br Dent J, 131 (1971) 249. — 4. SCHARFFETTER K, BALZ-HERRMANN C, LAGRANGE W, KOBERG W, MITTERMAYER C, J Craniomaxillofac Surg, 17 (1989) 226. — 5. STOELINGA PJ, BRONKHORST FB, J Craniomaxillofac Surg, 16 (1988) 184. — 6. BROWNE RM, Br Dent J, 128 (1970) 225. — 7. LUND VJ, Br J Oral Maxillofac Surg, 23 (1985) 210. — 8. FORSELL K, FORSELL H, KAHNBERG KE, Int J Oral Maxillofac Surg, 17 (1988) 25. — 9. PINDBORG JJ, HANSEN J, Acta Pathol Microbiol Scand, 58 (1963) 283. — 10. BRANNON RB, Oral Surg Oral Med Oral Pathol, 43 (1977) 233. — 11. CROWLEY TE, KAUGARS GE, GUNSOLLEY JC, J Oral Maxillofac Surg, 50 (1992) 22. — 12. HJORTING-HANSEN E, ANDREASEN JO, ROBINSON LH, Br J Oral Surg, 7 (1969) 15. — 13. RUD J, PINDBORG JJ, J Oral Surg, 27 (1969) 323. — 14. PANDERS AK, HADDLERS HN, J Oral Surg, 27 (1969) 931. — 15. LUCAS RB, Pathology of thumors of the oral tissues, (Churchill Livingstone, Edinburgh, 1976). — 16. SHER MR, STOOPACK JC, Oral Surg Oral Med Oral Pathol, 37 (1974) 518. — 17. BRØNDUM N, JENSEN VJ, Oral Surg Oral Med Oral Pathol, 72 (1991) 265. — 18. HARING JI, VAN DIS ML, Oral Surg Oral Med Oral Pathol, 66 (1988) 145. — 19. ANAND VK, ARROWOOD JP JR, KROLLS SO, Laryngoscope, 105 (1995) 14. — 20. CHEN CH, LIN CC, Gaoxiong Yi Xue Ke Xue Za Zhi, 2 (1986) 601. — 21. WOOLGAR JA, RIPPIN JW, BROWNE RM, J Oral Pathol, 16 (1987) 124. — 22. EL-HAJJ G, ANNEROTH G, Int J Oral Maxillofac Surg, 25 (1996) 124. — 23. VEDTOFTE P, PRAETORIUS F, Int J Oral Surg, 8 (1979) 412. — 24. FORSELL K, Proc Finn Dent Soc, 76 (1980) 129. — 25. MAURETTE PE, JORGE J, DE MORAES M, J Oral Maxillofac Surg, 64 (2006) 379. — 26. STOELINGA PJ, Int J Oral Maxillofac Surg, 30 (2001) 14. — 27. SEMBRONIO S, ALBIERO AM, ZERMAN N, COSTA F, POLITI M, Oral Surg Oral Med Oral Pathol Oral Radiol Endod, 107 (2009) 193. — 28. MEISELMAN F, J Oral Maxillofac Surg, 52 (1994) 960. — 29. STOELINGA PJ, J Oral Maxillofac Surg, 63 (2005) 1662. — 30. WILLIAMS TP, CONNOR FA JR, J Oral Maxillofac Surg, 52 (1994) 964. — 31. SHEAR M, Oral Oncol, 38 (2002) 407. — 32. SCULLY C, BURKHARDT A, J Oral Pathol Med, 22 (1993) 246. — 33. PAVIČEVIĆ R, MILIČIĆ J, BUBANOVIĆ G, SUPE S, Coll Antropol, 22 (1998) 629. — 34. MEARA JG, PILCH BZ, SHAH SS, CUNNINGHAM MJ, J Oral Maxillofac Surg, 58 (2000) 862. — 35. OGDEN GR, J Oral Maxillofac Surg, 58 (2000) 866. — 36. LAM EW, LEE L, PERSCHBACHER SE, PHAROAH MJ, Oral Surg Oral Med Oral Pathol Oral Radiol Endod, 105 (2007) 55. — 37. COSTA CARVALHO SILVA G, CARVALHO SILVA E, SANTIAGO GOMEZ R, COUTO VIEIRA T, Oral Oncology Extra, 42 (2006) 231. — 38. CIOFFI GA, TEREZHALMY GT, DEL BALSAMO AM, Oral Surg Oral Med Oral Pathol, 64 (1987) 648. — 39. ABSI EG, SIM RL, Dentomaxillofac Radiol, 23 (1994) 226. — 40. PARTRIDGE M, TOWERS JF, Br J Oral Maxillofac Surg, 25 (1987) 271. — 41. ODA D, RIVERA V, GHANEE N, KENNY EA, DAWSON KH, J Contemp Dent Pract, 15 (2000) 60. — 42. MORGAN PR, SHIRLAW PJ, JOHNSON NW, LEIGH IM, LANE EB, J Oral Pathol, 16 (1987) 212. — 43. MORGAN PR, SELDON S, LANE B, Keratin expression in odontogenic cysts and tumors. In: Proceedings (4th Conf Int Ass-Oral Pathol, 1988). — 44. MATTHEWS JB, BROWNE RM, J Clin Pathol, 43 (1990) 84. — 45. AUGUST M, FAQUIN WC, TROULIS M, KABAN LB, J Oral Maxillofac Surg, 58 (2000) 935.

*D. Planinić*

*Dental practitioner, 88266 Međugorje, Bosnia and Herzegovina  
e-mail: davor.planinic@du.t-com.hr*

## PREVALENCIJA ODONTOGENIH KERATOCISTA S IMPAKTIRANIM TREĆIM MOLAROM

### SAŽETAK

U ovom radu analizirana je prevalencija odontogene keratociste (OKC) povezane s impaktiranim trećim kutnjacima te evaluirana OKC reaktivnost na antitijela protiv citokeratina (CK), posebice CK10. Uzorci tkiva dobiveni su iz blizine impaktiranog kutnjaka. Analizirane su razlike po spolu, dobnim skupinama i lokalizaciji ciste, korištenjem hi-kvadrat testa i izračunavanja relativnog rizika (RR) s intervalima pouzdanosti. Ciste su pronađene u 75 slučajeva, među kojima su prevladavale radikularne (63%), zatim folikularne i OKC (13% i 12%). RR za ciste gornje čeljusti bio je gotovo dvostruko veći nego za donju čeljust. Što se OKC tiče, RR za gornju čeljust bio je 1:2- RR za sve ciste je rastao s porastom dobi pacijenta, dok se smanjivao za OKC. Rizik za nastanak OKC smanjivao se s porastom dobi, no bez statistički značajnih razlika među skupinama. Rezultati ovog istraživanja ne potvrđuju da je CK10 bojanje koristan biljeg u diferencijalnoj dijagnozi OKC.