

Myoepithelial Carcinoma of the Parotid Gland

Mirela Čarapina¹, Mario Jurić², Pero Bubalo¹ and Miro Leventić²

¹ Clinical Institute of Pathology, Cytology and Forensic Medicine, University Hospital Mostar, Mostar, Bosnia and Herzegovina

² Department of Maxillofacial and Oral Surgery, University Hospital Mostar, Mostar, Bosnia and Herzegovina.

ABSTRACT

Rare malignant tumor of the salivary gland, a myoepithelial carcinoma, arose de novo in the right parotid gland. The initial tumor was composed predominantly of myoepithelial cells. Subsequently the tumor recurred three times, with infiltration of the bones of the cranial base. Histological examination showed sarcomatoid neoplasm composed of malignant spindle cells with high mitotic rate and perineural invasion. There was no involvement of cervical lymph nodes. Immunohistochemistry demonstrated myoepithelial differentiation: tumor cells were positively stained with vimentin, alpha smooth muscle actin and S-100 protein antibodies, and focal positively was noticed with cytokeratin (AE1/AE3) antibody. Large number of tumor cells nuclei was reactive with the monoclonal anti-p63 antibody, clone 4A4. Myoepithelial carcinomas exhibit a wide spectrum of morphological heterogeneity and for that reason could be confused with many tumors. Cytoarchitectural patterns and immunohistochemical profile are crucial for identification. These tumors are malignant neoplasms with diverse clinical outcomes, sometimes very aggressive.

Key words: myoepithelial carcinoma, malignant myoepithelioma, parotid gland, immunohistochemistry, p63 protein

Introduction

Myoepithelial carcinoma or malignant myoepithelioma of the salivary glands is a rare tumor and represents the malignant counterpart of benign myoepithelioma¹. The predominant differentiation of the tumor cells is myoepithelial. Cells demonstrate cytological atypia and a potential for aggressive behavior². The sex incidence is approximately equal and the average age of patients at presentation is about 55 years. One-half of cases arise from a pre-existing pleomorphic adenoma or myoepithelioma, particularly in recurrences^{3–5}. In this report we present a morphological and immunohistochemical analysis of a myoepithelial carcinoma which arose de novo in a parotid gland and had a very aggressive behavior.

Case Report

A 66-year old man presented with a two months history of painless swelling in the right preauricular region. On examination, a 3.5 cm diameter firm tumor mass was palpable in the parotid gland. On radiological and ultrasound examination there was no evidence of bone erosion or extension of tumor. A right superficial parotidectomy was performed. Postoperatively the patient made a good

recovery, with full facial nerve function. Two months later a recurrent mass developed in the region of the previous scar. The mass was resected. One month later computed tomography (CT) confirmed the presence of recurrent tumor consisting of one satellite nodule of 1 cm diameter in the deep lobe of the parotid gland posteriorly. Patient underwent a right radical parotidectomy with sacrifice of the facial nerve and elective right neck dissection. Seven months later he complained of a headache and diplopia. Magnetic resonance imaging (MRI) and CT revealed a large tumor in the cavernous sinus extending into the pituitary fossa, the right pterygopalatine fossa and right orbit, with bone erosion. The transmaxillary biopsy confirmed the presence of recurrent tumor. The patient received palliative radiotherapy and he died of disease two months later, just 14 months after first symptoms occurred.

The surgical specimens were fixed in formalin. Sections for histological examination were routinely processed in paraffin wax and stained with haematoxylin and eosin. Immunohistochemical staining was performed using a standard streptavidin-biotin-peroxidase method (Dako, Glostrup, Denmark). The following monoclonal

antibodies were used: cytokeratin AE1/AE3 (Dako), S-100 protein (Dako), alpha smooth muscle actin (Dako), vimentin (Dako), epithelial membrane antigen (EMA, Dako), HMB-45 (Dako), Ki-67 (Dako) and p63, clone 4A4 (Dako).

The initial resection specimen contained a firm, whitish tumor tissue measuring 4 cm in maximum dimension, with a thick irregular border. Histological examination showed cellular tumor composed predominantly of cells with ovoid to spindle shaped nuclei, with a moderate amount of cytoplasm, which was either clear or eosinophilic. There was an abundant myxoid stroma between tumor cells (Figure 1a). Small areas of epithelial elements consisting of ducts and tubules were focally present. In some areas mitotic count was high – there were 10–20 mitoses *per* 10 high power fields. Tumor was not present at the surgical resection margins.

The resection specimen of the first recurrence consisted of a tumor measuring 2 cm in maximum dimension. Histological examination showed that the tumor was composed of the solid areas similar to those seen in the initial specimen, with higher mitotic index. The perineural invasion and areas of necrosis were present. Tumor was present at the surgical resection margin. The second resected recurrence consisted of the skin, residual parotid gland with a tumor measuring 1.5 cm in maximum dimension and cervical lymph nodes. Histological examination showed a sarcomatoid tumor composed almost entirely of spindle cells with myxoid stroma between tumor cells. Surgical resection margins and cervical lymph nodes were free of tumor. The third recurrence

of the tumor was confirmed by transmaxillary biopsy and the histological findings were similar to the previous.

In the first and second resection ducts and tubules of the tumor were immunoreactive for cytokeratin (AE1/AE3), EMA and S-100 but negative with the other antibodies. The spindle-cell tumor areas in the initial specimen and in all recurrences were highly positive for vimentin antibodies and focally positive with S-100 protein and alpha smooth muscle actin. These tumor cells were negative with the antibodies for cytokeratin (AE1/AE3), EMA, HMB-45 and CEA. The tumor cells nuclei were immunoreactive with Ki-67. In the initial specimen the mean proliferation index was 10% and in all recurrences the mean index was 20%.

The tumor cells nuclei in the initial specimen and in all recurrence specimens stained diffusely positive with monoclonal anti-p63 antibody, clone 4A4.

Discussion

The malignant counterpart of benign myoepithelioma – myoepithelial carcinoma or malignant myoepithelioma, is rare neoplasm and is one of several new entities included in the updated classification of salivary gland neoplasms (World Health Organization, 1991²). Most commonly it involves the parotid gland, but other mayor or minor glands and the breast can also be affected^{3,6,7}. Two criteria must be satisfied to establish a diagnosis of myoepithelial carcinoma: the neoplastic cells must show myoepithelial differentiation and the tumor must be malignant⁸. In the present case, myoepithelial differenti-

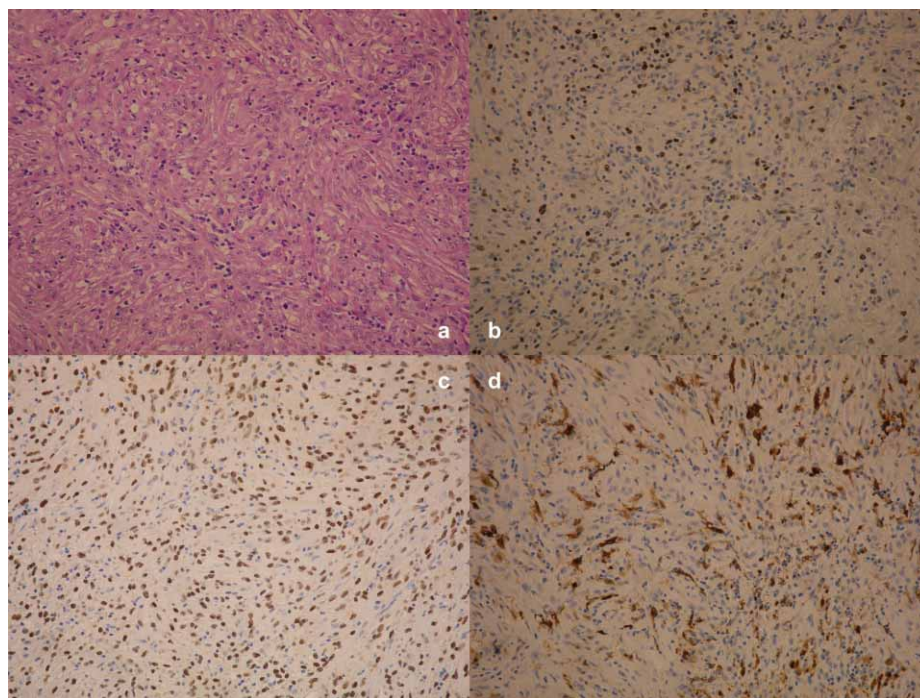


Fig. 1. Myoepithelial carcinoma. a) stained with HE method, objective 20X b) Ki-67 antibody, objective 20X c) p63 antibody, clone 4A4, objective 20X d) S 100 protein antibody, objective 20X.

ation was established by cytoarchitectural patterns and immunohistochemical profile of the tumor cells. The tumor was composed almost entirely of cells with ovoid to spindle shaped nuclei with small foci of epithelial elements consisting of ducts and tubules. Myoepithelial carcinomas exhibit a wide spectrum of morphological heterogeneity and for that reason could be confused with many tumors. Differential diagnoses include myoepithelioma, various sarcomas, interdigitating dendritic cell sarcoma and melanoma⁹.

In the present case, malignant spindle cell pattern initially suggested a sarcoma, but immunohistochemical study showed positive staining for vimentin, S-100 protein (Figure 1d) and alpha smooth muscle actin which indicated a myoepithelial differentiation^{10,11}. Cytokeratin positivity was noticed in the ductal epithelial cells and in the periductular myoepithelial cells, but it was absent from malignant spindle cells. Immunohistochemical staining of tumor cells with antibodies to HMB-45 and CEA was absent.

In the initial specimen and in all recurrence specimens of the present case, large number of tumor cells nuclei was immunoreactive with p63, clone 4A4 (Figure 1c). Benign myoepithelial cells of salivary glands, like those of normal breast and prostate epithelium, express p63¹². In all salivary gland –derived tumor types that differentiate towards luminal and myoepithelial lineages, p63 was expressed in myoepithelial cells, whereas internal luminal cells were always negative¹³. This immunophenotype confirms myoepithelial differentiation.

The combination of nuclear polymorphism and mitotic activity establishes a diagnosis of malignancy. Cellular proliferative activity is assessed by mitotic count and the Ki-67 labelling index (Figure 1b). The tumor cells nu-

clei mean Ki-67 labelling index in the initial specimen was 10% and in all recurrences the mean index was 20%. The Ki-67 labelling index above 10% is said to be diagnostic of malignancy in a myoepithelial neoplasm⁷.

The infiltrative growth pattern with involvement of bones was suggestive of but not in itself indicative of a malignant tumor. There was no histological evidence of a pre-existing adenoma or benign myoepithelioma in our case, despite examination of multiple sections. In initial resection tumor was not present at the surgical resection margin, but unusual histology might indicate that a more aggressive approach was necessary for this patient. Most carcinomas arising de novo in parotid gland are highly aggressive neoplasms, have a higher metastatic potential and have tendency to recur locally following surgical resection⁴. In our case, there was a short time period between resection of the primary tumor and the development of recurrences.

The clinical features of myoepithelial carcinomas are as follows: most frequent involvement of the parotid gland, followed by the submandibular gland; rapidly enlarging mass with extensive invasion of the surrounding tissue in some cases; low rate of cervical lymph node metastasis but high rate of distant metastasis; frequent recurrence after surgical excision; poor prognosis¹⁴.

Conclusion

We report a case of a rare malignant neoplasm of salivary gland, a myoepithelial carcinoma, which arose de novo in a parotid gland, was highly aggressive, characterized by infiltrative growth, with an unusually short time period between resection of the primary tumor and the development of recurrences.

REFERENCES

1. BARNES L, EVESON J W, REICHART P, SIDRANSKY D, Pathology and Genetics of Head and Neck Tumors (IARC Pres, Lyon, 2005).
2. SEIFERT G, SOBIN L H, World Health Organisation international histological classification of tumours (Springer-Verlag, New York, 1991).
3. SAVERA AT, SLOMAN A, HUVOS AG, KLIMSTRA DS, Am J Surg Pathol, 24 (2000) 761.
4. DI PALMA S, GUZZO M, Virchow's Arch A Pathol Anat Histopathol, 423 (1993) 389.
5. NAGAO K, MATSUZAKI O, SAIGA H, Cancer, 48 (1981) 113.
6. ALOS L, CARDESA A, BOMBI JA, MALLOFRE C, CUCHI A, TRASSERA J, Semin Diagn Pathol, 13 (1996) 138.
7. NAGAO T, SUGANO I, ISHIDA Y, TAJIMA Y, MATSUZAKI O, KOONO A, KONDO Y, NAGAO K, Cancer, 83 (1998) 1292.
8. MCCLUGGAGE WG, PRIMROSE WJ, TONER PG, J Clin Pathol, 51 (1998) 552.
9. FLECHER C, Diagnostic Histopathology of Tumours (Churchill Livingstone, Boston, 2007).
10. SINGH R, CAWSON RA, Oral Surg Oral Med Pathol, 66 (1988) 65.
11. TAKEDA Y, Acta Pathol Jpn, 42 (1992) 518.
12. WEBER A, LANGHANKI L, SCHUTZ A, Virchow's Arch, 441 (2002) 428.
13. BILAL H, HANDRA-LUKA A, BERTRAND J C, J Histochem Cytochem, 51 (2003) 133.
14. YU G, MA D, SUN K, Zhonghua Kou Qiang Yi Xue Za Zhi, 32 (1997) 67.

M. Čarapina

Clinical Institute of Pathology, Cytology and Forensic Medicine, University Hospital Mostar, Bijeli Brijeg bb, 88000 Mostar, Bosnia and Herzegovina
e-mail: mirelacarapina@yahoo.com

MIOEPITELNI KARCINOM PODUŠNE ŽLIJEZDE

SAŽETAK

Rijetki maligni tumor žlijezda slinovnica, mioepitelni karcinom, nastao de novo u desnoj podušnoj žlijezdi. Primarni tumor je građen pretežno od polimorfnih malignih mioepitelnih stanica. Kasnije tumor recidivira tri puta a karakterizira ga prodor u kosti baze lubanje. Histološki pregled pokazuje sarkomatozni izgled tumora građenog od malignih vretenastih stanica s brojnim mitozama i perineuralnom invazijom. U limfnim čvorovima vrata ne nalazi se metastaza. Imunohistokemijsko bojenje upućuje na mioepitelnu diferencijaciju: tumorske stanice su pozitivne na monoklonska protutijela za vimentin, alfa glatko-mišićni aktin i S-100 protein, te žarišno pozitivne na citokeratin (AE1/AE3). Brojne jezgre tumorskih stanica su pozitivne na p63 protutijelo, klon 4A4, u svim resektatima. Mioepitelni karcinomi pokazuju širok spektar morfološke raznolikosti, te se mogu zamijeniti s brojnim tumorima. Izgled stanica, način rasta i imunohistokemijski profil je odlučujući za patohistološku dijagnostiku. Ovi tumori su maligne neoplazme sa različitim kliničkim ishodom, ponekad vrlo agresivni.