

# Common Bile Duct Obstruction Caused by the Hydatid Daughter Cysts

Željko Bušić<sup>1</sup>, Enio Amić<sup>2</sup>, Dražen Servis<sup>1</sup>, Mladen Predrijevac<sup>3</sup>,  
Igor Stipančić<sup>1</sup> and Dubravka Bušić<sup>4</sup>

<sup>1</sup> Department of Abdominal Surgery, University Hospital »Dubrava«, Zagreb, Croatia

<sup>2</sup> Department of Traumatology, University Hospital »Dubrava«, Zagreb, Croatia

<sup>3</sup> Hospital for Cardiovascular Surgery and Cardiology »Magdalena«, Krapinske Toplice, Croatia

<sup>4</sup> Department of Dermatology, University Hospital »Dubrava«, Zagreb, Croatia

## ABSTRACT

*Echinococcosis is a human parasitary disease. In 2002, 29 new cases of liver echinococcosis were recorded in Croatia. Liver is the most common site of hydatid cysts. Nine patients with echinococcal liver disease were operated in our department in 2002. Here we present a case where a patient with verified hydatid cyst in the left liver lobe developed high fever, jaundice, nausea, vomiting and pain in the upper abdomen. The symptoms were initially ascribed to the acute cholangitis. After unsuccessful antibiotic treatment, computerized tomography and endoscopic retrograde cholangiopancreatography (ERCP) were performed, demonstrating daughter cysts in the common bile duct. During ERCP, papilotomy was made and daughter cysts were extracted. Hydatid cyst was surgically removed, and a communication between the cyst and left hepatic duct was noted during surgery. Pericystectomy, choledochotomy, removal of remaining daughter cysts from the common bile duct, and sutures of left hepatic duct were performed. The patient recovered fully after the surgery. One of the possible complications of the liver hydatid cysts is the communication between cyst and the biliary tree. Such communications are usually asymptomatic, but symptoms can also mimic acute cholangitis and jaundice, which may lead to the misdiagnosis of the patient's condition.*

**Key words:** *hydatid cysts, echinococcosis, biliary obstruction, case report*

## Introduction

Echinococcosis is a parasitary disease, caused by *Echinococcus granulosus*. It is still present in Croatia, and according to the National Referral Center for Epidemiology in 2002 there were twenty-nine newly registered patients. Adult parasites, approximately 5 mm in length, infest the intestine of dogs. Their eggs are excreted with faeces and represent a source of infection for various animals and humans. When ingested by a man, eggs hatch in the small intestine, develop into larvae that leave the small intestine through blood stream, and form a hydatid cyst in the body, usually in the liver. Hydatid cysts contain several hundreds of protoscolices that have a propensity to develop into the adult parasites after the ingestion by the dog.

Hydatid cysts can grow considerably over time, up to the size of a basketball<sup>1</sup>. The rupture of hydatid cyst following trauma represents a significant danger for the patient, because it leads to dissemination of protoscolices<sup>2</sup>. Also, potentially fatal anaphylactic shock can de-

velop as a reaction to the hydatid fluid<sup>3</sup>. Treatment of hydatid cysts is primarily surgical, usually followed by long-term medication with albendazole<sup>4</sup>. Preferred surgical operation is total pericystectomy, because it results in fewer complications than partial pericystectomy<sup>5</sup>. There are also reports of successful laparoscopic management of uncomplicated liver hydatid cysts<sup>6</sup>.

One of the complications associated with liver hydatid cysts is a communication between the cyst and biliary tree, which may lead to the symptoms resembling those of acute cholangitis.

## Case Report

The 67-years old female patient was admitted to the department of infectology of a municipal hospital, presenting with high fever, jaundice, nausea, vomiting, and pain in the upper abdomen, lasting for two days. During the previous three weeks, patient suffered from intermittent epigastric and right subcostal blunt pain, accompanied with dyspeptic symptoms.

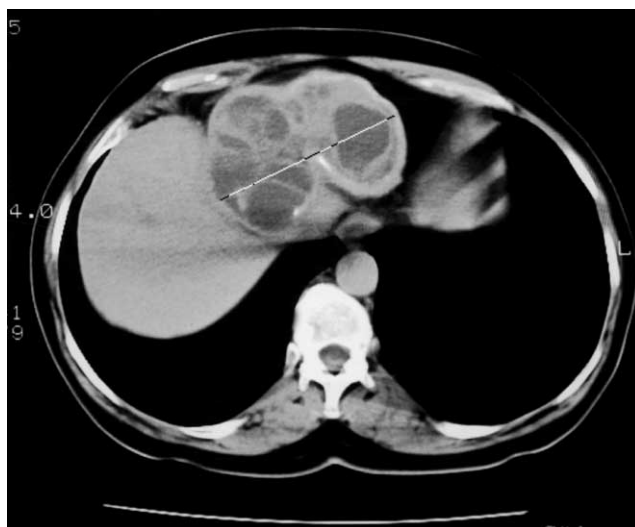


Fig. 1. Abdominal CT demonstrated multilocular septated cyst in the left liver lobe.

Three years ago the hydatid cyst of the left liver lobe was ultrasonographically diagnosed and confirmed by serological tests. At the age of 18 the patient was operated, most likely because of the rupture of liver hydatid cyst following trauma.

Relevant laboratory findings at the time of admission were following: 10,300 WBC/mm<sup>3</sup> with 81% segmented neutrophils, bilirubin 58.6 μmol/L, AST 22 U/L, ALT 78 U/L, GGT 205 U/L and AP 235 U/L.

Abdominal ultrasonography and computerized tomography demonstrated multilocular septated cyst measuring 10 cm in diameter in the left liver lobe, with no signs of bile ducts dilatation (Figure 1). Preliminary diagnosis was acute septic cholangitis, and the patient was treated with cefoperason 2g every 12 hours and metronidazole 500 mg every 8 hours. Fever subsided and the patient's general condition improved, but laboratory findings indicated progression of the disease: 12,500 leukocytes/mm<sup>3</sup> with 58% segmented neutrophils, bilirubin 41.0 μmol/L, AST 294 U/L, ALT 317 U/L, GGT 1,039 U/L and AP 1,521 U/L.

Eleven days after initial hospital admission the patient was referred to Department of gastroenterology in our institution for further work-up. Abdominal ultrasonography was repeated, demonstrating multilocular cyst of the left liver lobe and dilated common bile duct, with intraductal mass 2 cm in diameter that was assumed to be a gallstone.

Endoscopic retrograde cholangiopancreatography (ERCP) with sphincterotomy was next performed (Figure 2). Three lesions were found in the common bile duct, measuring 3 cm, 3.5 cm, and 4 cm in diameter, respectively. They were extracted and sent for histopathology examination, which confirmed the presence of hydatid daughter cysts in the common bile duct.

Since we weren't sure that all the daughter cysts were removed from common bile duct, the patient was transferred to our department for surgical treatment. After preoperative preparation, the hydatid cyst was surgically removed. Intraoperatively, large hydatid cyst was found in left lobe of the liver with gall bladder adhering to it. Cholecystectomy

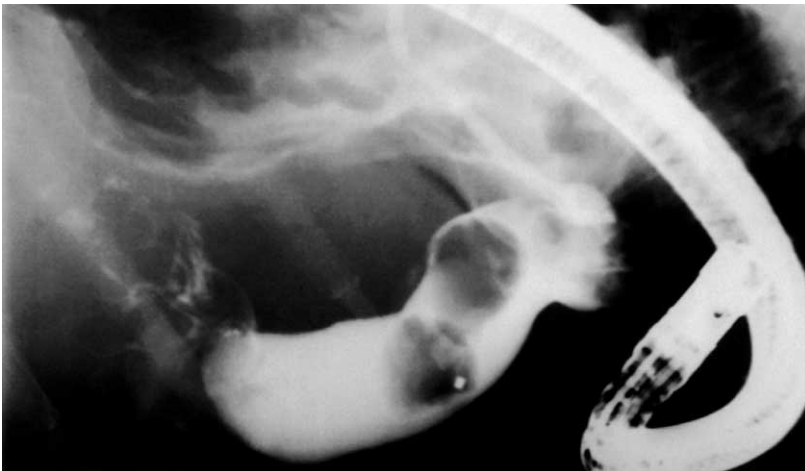


Fig. 2. Endoscopic retrograde cholangiopancreatography (ERCP) with three lesions in the common bile duct.

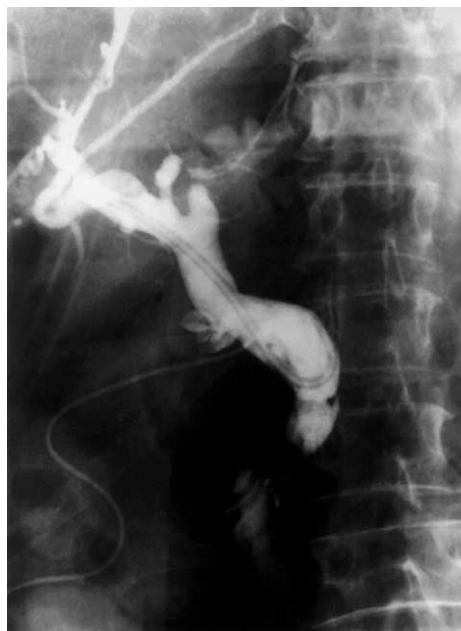

Fig. 3. Intraoperative biligraphy after pericystectomy, choledochotomy et T-tube drainage.

was performed, followed by an exploration of the common bile duct. Remnants of daughter cysts were found approximately 3 cm from Vater's papilla and cleared from the duct. By application of methylene-blue dye the communication between hydatid cyst and left hepatic duct was verified. Pericystectomy was performed and left hepatic duct was closed with sutures. Intraoperative biligraphy was performed, showing no residual abnormalities of the biliary tree (Figure 3).

Subsequent histopathological examination confirmed presence of hydatid

daughter cysts in the common bile duct. No viable protoscolices were found in the part of the cyst resected from the liver. Cholangiogram performed through the T-drain on the 7<sup>th</sup> postoperative day and abdominal ultrasonography on the 11<sup>th</sup> postoperative day were both normal.

## Discussion

Echinococcal disease is still present in our country, and liver is the most common site of hydatid cyst formation. Communication between hydatid cyst and biliary tree is one of possible complications of the disease, reported in several case reports<sup>7–9</sup>. In majority of cases there are no symptoms, but these communications may present with pain in the right subcostal region, jaundice, or signs of acute cholangitis<sup>9</sup>, as in the case we reported. In all patients presenting with the signs of acute cholangitis, and with verified hydatid liver disease, communication between cyst and biliary tree should be included in the differential diagnosis. An effective method for diagnosing such communications is ERCP, unanimously used for the diagnosis of communication between hydatid cyst and biliary tree in reported cases<sup>8–11</sup>. Early diagnosis enables rapid surgical treatment and healing of this condition, contrary to the antibiotic treatment of acute cholangitis, which cannot be effective in case of the cyst-biliary duct communication. In spite of a reported case where a hydatid cyst-biliary tree communication was treated conservatively<sup>9</sup>, surgical treatment remains the golden standard for treating hydatid cysts located in the liver that have ruptured into the biliary tree<sup>8</sup>.

## REFERENCES

1. BULIGESCU, L., L. LUCA, *Med. Interna*, 43 (1991) 93. — 2. SOZUER, E. M., E. OK, M. ARSLAN, *N. Am. J. Trop. Med. Hyg.*, 66 (2002) 575. — 3. HOR-

ZIĆ, M., D. BUNOZA, K. MARIĆ, *Hepatogastroenterology*, 43 (1996) 1601. — 4. KERN, P., *Langenbecks Arch. Surg.*, 388 (2003) 413. — 5. BUŠIĆ, Ž., Z. LO-

VRIĆ, I STIPANČIĆ, D. BUŠIĆ, L. LOVRIĆ, Chirurgia, 16 (2003) 49. — 6. KHOURY, G., F. ABIAD, T. GEAGEA, G. NABOUT, S. JABBOUR, Surg. Endosc., 14 (2000) 243. — 7. DAALI, M., Y. FAKIR, R. HSSAIDA, A. HAJJI, A. HAD, Ann. Chir., 126 (2001) 242. — 8. WARMANN, S., P. N. MEIER, R. KARDORFF, J. FUCHS, Eur. J. Pediatr. Surg., 12 (2002) 134. — 9. PARTHE, S., M. MAIER, B. KOHLER, S. KRESS, J.

F. RIEMANN, Dtsch. Med. Wochenschr., 119 (1994) 624. — 10. DUMAS, R., L. E. P. GALL, P. HASTIER, M. J. BUCKLEY, M. CONIO, J. P. DELMONT, Endoscopy, 31 (1999) 242. — 11. GIOULEME, O., N. NIKOLAIDIS, P. ZEZO, K. BUDAS, P. KATSINELOS, T. VASILIAIDIS, Gastrointest. Endosc., 54 (2001) 508.

Ž. Bušić

Department of Abdominal Surgery, University Hospital »Dubrava«, Zagreb,  
Av. G. Šuška 6, 10000 Zagreb, Croatia  
e-mail: zbusic@kdb.hr

## OPSTRUKCIJA ZAJEDNIČKOG ŽUČOVODA UZROKOVANA EHINOKOKNIM CISTAMA MLADICAMA

### S A Ž E T A K

Ehinokokoza je parazitarna bolest koja pogađa ljude. Prema Državnom zavodu za epidemiologiju, 2002. god. u Hrvatskoj je zabilježeno 29 novih slučajeva. Jetra je najčešća lokalizacija ehinokokne ciste. Devet bolesnika s ehinokoknom bolešću jetre operirano je na našem odjelu tijekom 2002. godine. Prikazan je slučaj bolesnice s verifiriranom ehinokoknom cistom u lijevom režnju jetre uz razvijenu visoku temperaturu, žuticu, mučninu, povraćanje i bol u gornjem trbuhu. Simptomi su inicijalno pripisani akutnom kolangitisu. Nakon bezuspješne antibiotske terapije učinjena je kompjuterizirana tomografija. Ciste mladice dokazane su tek prilikom endoskopske retrogradne kolangiopankreatografije (ERCP), kada je učinjena i papilotomija te ekstrakcija cista mladica iz zajedničkog žučovoda. Ehinokokna cista je kirurški odstranjena a komunikacija između ciste i lijevog hepatičkog voda zamiječena je tijekom kirurškog zahvata. Učinjena je pericistektomija, koledokotomija, odstranjenje preostalih cista mladica iz zajedničkog žučovoda te šavovi lijevog hepatičkog voda. Bolesnica se u potpunosti oporavila nakon kirurškog zahvata. Jedna od mogućih komplikacija ehinokokne bolesti jetre je komunikacija između ciste i bilijarnog stabla. Ovakve komunikacije su obično asimptomatske ali simptomi mogu oponašati akutni kolangitis i žuticu što može dovesti do pogrešne dijagnoze bolesnikovog stanja.