

# Efficiency of Polylactide/ Polyglycolide Copolymers Bone Replacements in Bone Defects Healing Measured by Densitometry

Davor Katanec<sup>1</sup>, Božidar Pavelić<sup>2</sup> and Zoran Ivasović<sup>1</sup>

<sup>1</sup> Department of Oral Surgery, School of Dental Medicine, University of Zagreb, Zagreb, Croatia

<sup>2</sup> Department of Dental Pathology, School of Dental Medicine, University of Zagreb, Zagreb, Croatia

## ABSTRACT

*Healing of bone defects is the most frequent cause of failure in surgical treatments of an odontogenic otitic processes. The aim of this study was to determine successfulness in healing of bone defects after implantation of alloplastic co-polymer-polyglycol bone implant. A group of 45 cases with periradicular otitic processes were examined. The densitometric measurements were taken from radiovisiographic dental x-ray images. Patients were observed throughout a period of one year. The results obtained were analyzed and presented graphically. Thirty-eight patients (84%) were treated successfully, and seven patients (16%) showed unsuccessful healing of the bone defects. The results obtained indicate that polyglycol copolymer bone implants can be successfully used in a treatment of odontogenically caused bone defects. Their fundamental advantage is a slow biodegradation, which ensures a more suitable area for the apposition of a new bone in the defect, simple application in clinical work and the possibility of a mutual combination of all three available forms.*

**Key words:** bone defect, Fisiograft, densitometry

---

## Introduction

Healing of odontogenically caused bone defects is the most frequent reason for failure in surgical treatment of an otitic process. The therapy for smaller bone de-

fects is primarily conservative (root treatment, according to the principles of contemporary endodontic). Larger bone defects (0 > 1 cm) and defects which do

not respond to conservative therapy, require surgical treatment<sup>1</sup>. Apicoectomy is the method most often used for this purpose. Resection of one third of root apex and removal of the pathologically changed tissue from the bone defect enables healing by connective organization of a blood clot and the formation of bone. Incomplete or unsatisfactory healing frequently occurs after surgical treatment of larger bone defects. The need for reconstruction of such bone defects prompted the development of different kinds of bone replacements, which can be autologous, allogenic, xenogenic and alloplastic. The principal task of all these materials is osteoinduction or osteoconduction and mechanical prevention of ingrowing connective tissue in the lumen of bone defect rather than new bone formation<sup>2-4</sup>.

Because they are simple to apply, alloplastic bone implants have become widely used in the treatment of such bone defects. Currently the most frequently used alloplastic implants are resorptive tricalcium phosphate (TCA) and nonresorptive hydroxylapatite (HA). Each of these materials has advantages and disadvantages. Resorptive materials usually have high osteoinductive ability, although the period of their biodegradation is much faster than the possibility of bone apposition in the lumen of the defect<sup>5</sup>. On the other hand nonresorptive bone replacements have low osteoinduction ability, although they remain permanently in the lumen of the defect and create the basis for the formation of new bone<sup>6-8</sup>. The problem is that the ingrowing connective tissue frequently occurs around the nonresorptive HA granules, instead of new bone formation. Thus the majority of studies in this field are connected with the discovery of a material which will have better osteoinductive potential and a slower period of resorption<sup>9,10</sup>. Last year a new generation of resorptive alloplastic bone replacements appeared, based on

synthetic copolymer 1-d polylactic and polyglycolic acid. The material used in this study belongs to this group of materials, and its trade name on the market is Fisiograft (manufacturer Ghimas s.p.a., importer SD Informatika). It has a low molecular weight, which enables biodegradation over a period of 3–8 months, depending on the amount of material needed and reactivity of the organism. The process of absorption and biodegradation evolves via Krebs cycle, which represents a chain of biochemical reactions, resulting in the formation of water and carbon dioxide as the final product of the metabolism of polylactic acid, while polyglycolic acid is biodegraded enzymatically into ethylene glycol<sup>11</sup>.

Fisiograft is a mixture of polyethylene glycol 400 and poly(D,L-lactic-co-glycolic) acid in ratio of 75:25 with polymer degradation period of 6 months. It is manufactured in three different forms: powder, gel and sponge blocks (1×1 cm). It is sterilized by gamma radiation. Depending on the size and shape of the bone defect, all three forms can be mutually combined during application in the bone defect.

The aim of this study was to valorize the successfulness in healing of bone defects that occurred as a result of periapical lesion, after the apicoectomy and implantation of copolymer-polyglycolic alloplastic bone replacements. Based on results achieved by densitometric measurements we shall determine its advantages and disadvantages in clinical application.

## Material and Methods

Forty-five cases with periradicular ositic processes on the frontal teeth in the maxilla, with the size of 1.5 × 1.5 cm approximately, were examined. The cases were classified by random selection into three groups of 15 cases each. The causative teeth of the ositic process were pre-

operatively endodontically treated on the same day.

Resection of the root apex of the causative teeth was then performed, and all of the pathologically changed tissue removed. The alloplastic bone implant was inserted (Figure 1).

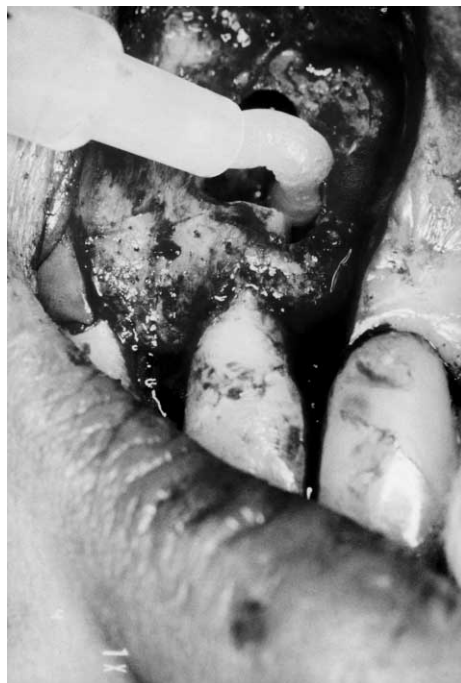

Fig. 1. Apicectomy 11 with Fisiograft gel.

We used a trapezoidal cut during the surgical procedure, which enables an optimal sight of the working field and healing of the wound *per primam*, with complete coverage of the alveolar bone. After surgical treatment, Fisiograft was implanted into the bone defect. In the first group – 15 cases, it was applied in the form of powder. In the second group of 15 cases Fisiograft was implanted in the form of a gel, and in the third group of 15 cases a combination of gel and powder was used, in the proportion 50:50. As a

prophylaxis, patients received an antibiotic *per os* (Klimicin ad 3×150 mg) for ten days, i.e. two days preoperatively and eight days post-operatively, which is a standard procedure<sup>11</sup>.

Patients were observed throughout a period of one year, i.e. a pre-operative X-ray was taken, and then followed by one, six and 12 months after the operation. The X-rays were taken radiovisiographically, on a high-frequency X-ray apparatus »Elitys« (manufacturer Trophy, importer SD informatica), exposure time up to 0.014 sec, so that the dose of radiation was reduced by 90% compared to classical X-ray apparatus. After which, digitalization was performed. Digitalization of the X-ray films was performed with a RVG HDS kit for radiovisiography, which has a CCD sensor with optic fibers

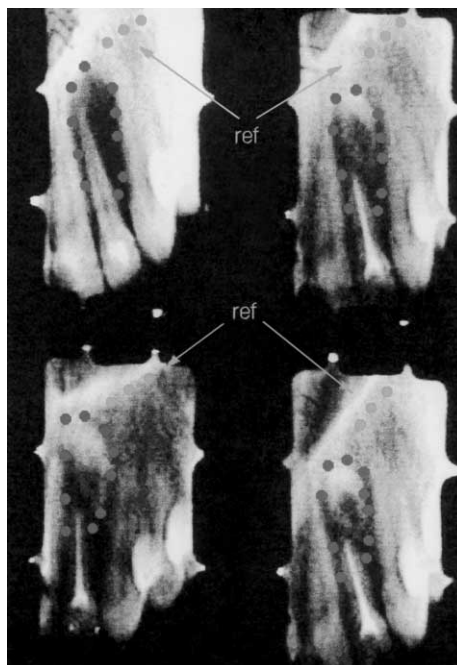


Fig. 2. Schematic presentation of the causative tooth, with ten points marked in which changed density was measured

of penultimate generation. The film was always digitalized with the same spatial resolution of 14 pairs of lines per millimeter. In this way a dynamic range of 256 levels of grey shades was achieved. This resolution is quite adequate for accurate interpretation of the levels of grayness and appropriate densities at any point on the film.

A computerized densitometry program is incorporated in the Trophy system of radiovisigraphy, which enables the determination of the density at certain points, within the plane and defined fields of the radiogram. We measured density at ten points along the edges of the bone defect (Figure 2). This area was chosen for measuring, since density measured in the middle of the bone defect after implantation of Fisiograph due to its translucency, would show increased density<sup>12</sup>.

### Results

In 35 cases *ostitis periapicalis chronica granulomatosis* was diagnosed by means of clinical and X-ray examination on one of teeth within the intracanine region. In the remaining 10 cases, a radicular cyst was diagnosed on one or on two teeth within intra-canine region (Table 1).

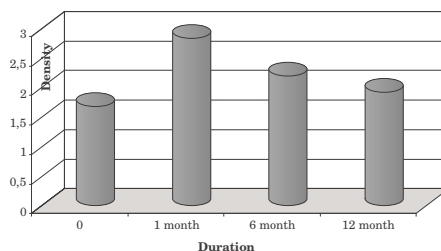
The results of densitometric measurements during the period of one year are shown graphically for each case (Figure 3).

**TABLE 1**  
PRESENTATION OF THE TOTAL NUMBER OF EXAMINED SUBJECTS

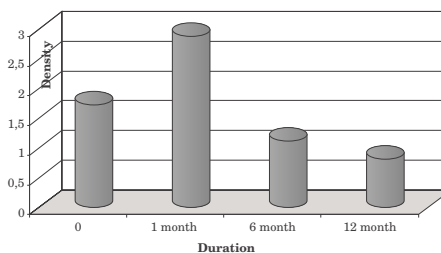
Type of lesion	Female	Male	Total	%
OPC	21	14	35	78
CR	7	3	10	22
Total	28	17	45	100

OPC – Ostitis periapicalis chronica,  
CR – Cysta radicularis

Thirty-eight (84%) successfully treated cases were determined by densitometric measurements. A decrease in density i.e. unsuccessful healing of the bone defect was determined in seven (16%) cases (Table 2).



a) successfully treated bone defect



b) unsuccessfully treated bone defect

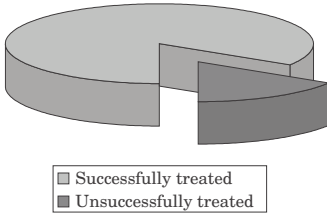
Fig. 3. Presentation of the follow-up of successful and unsuccessful healing of the bone defect by the densitometric measurement.

### Discussion

At the beginning of clinical application of alloplastic bone implants, it was considered that they have an exceptionally high osteoinductive and osteogenetic ability<sup>13</sup>. This was substantiated by the results of basic investigations in vitro, which emphasized the high osteoinductive ability of these materials<sup>14,15</sup>. More recent clinical studies, demonstrated that these materials, when implanted into a bone defect, behave similarly to devitalize autologous or homologous bone transplants. The only difference being that during the

**TABLE 2**  
 GRAFIC AND TABULAR PRESENTATION OF THE TOTAL OBTAINED RESULTS

	Successful		Unsuccessful		Total
	N	%	N	%	
Female	24	85	4	15	28
Male	14	83	3	17	17
Total	38	84	7	16	45



process of new bone formation they do not have an osteoclastic resorptive phase<sup>16,17</sup>. This hypothesis was accelerated by Klein’s study, in which it was reported that all synthetic hydroxylapatites are bioinert and that in 55% of cases in clinical application a fibrous encapsulation occurs around the HA granules instead of new bone formation<sup>18–20</sup>.

We obtained similar results in our studies with these materials, particularly with the introduction of sophisticated and objective methods for following such cases, such as CADIA, which unexpectedly showed a significant high percentage of unsatisfactory healing of bone defects after implantation of HA<sup>1,12,21</sup>.

Because of the need for expensive hardware and software support, computerized densitometry analysis was only applied in some highly specialized institutions. With the development of computer technology in dental medicine, primarily digital technology of RVG HDS kits for radiovisiography, and their wide application in dental practice, the possibilities for computerized densitometry have greatly increased, and it has become an integral

part of the RVG package software. Such programs for densitometric measurements of objects presented on digitalized X-rays, enable an objective and accurate measurements of density, on the basis of which an objective evaluation of post-operative healing of a bone defect can be made.

We used this method in our study to enable objective evaluation of the effectiveness of Fisiograft, as a new alloplastic material for the treatment of odontogenically caused bone defects.

The obtained results, compared with the results of similar studies carried out with resorptive ceramic hydroxylapatite, highlight the advantages of Fisiograft. Although this material showed a decrease in density, in which complete resorption of the material and replacement of new tissue had occurred, yet it was significantly less than in the cases where ceramic HA were implanted<sup>22–24</sup>. Another advantage of this material is the possibility of combining its different forms, such as mixing gel and powder, which provides a very adaptable consistency for application in a bone defect<sup>11</sup>.

Based on the clinical results, it can be concluded that polyglycol copolymer bone replacements can be successfully used in the treatment of odontogenically caused bone defects. The most suitable form of material for application in bone defects is a combination of gel and powder, in a proportion 50%:50%.

## REFERENCES

1. KATANEC, D.: Kompjuterizirana denzitometrijska analiza i standardizacija kliničkih i laboratorijskih kriterija u procjeni terapijske vrijednosti HA koštanih implantata. Ph.D. Thesis. (School of Dental Medicine, University of Zagreb, Zagreb, 1997). — 2. HIDAKA, S., K. ABE, A. LIUSY, Arch. Oral Biol., 36 (1991) 49. — 3. HAN, T., F. A. CARRANZA, B. KENNEY, J. West Soc. Perio., 32 (1984) 88. — 4. KOVAČEVIĆ, D., Z. DELIĆ, A. ČELEBIĆ, Z. KOVAČ, R. GRŽIĆ, I. UHAČ, D. K. ZLATARIĆ, Coll. Antropol., 26 Suppl. (2002) 171. — 5. HARA, K., M. SHIMIZU, J. Oral Implantol., 12 (1985) 68. — 6. BARKHORDAR, R. A., J. R. MEYER, Oral Surg. Oral Med. Oral Pathol., 16 (1986) 201. — 7. LAUC, T., D. KRNIĆ, D. KATANEC, Coll. Antropol., 24 Suppl. (2000) 91. — 8. LOUISE, F., A. BORGHETTI, B. KEREBEL, Int. J. Periodontol. Rest. Dent., 12 (1992) 475. — 9. CORSAIR, A., J. Oral Implantol., 16 (1990) 125. — 10. METSGER, D. S., T. D. DRISKELL, J. R. PAULSRUD, J. Am. Dent. Assoc., 105 (1993) 35. — 11. GATTI, A., E. MONARI, D. TANZA, V. BETTI, Min. Stomatol., 48 (1999) 47. — 12. KATANEC, D., P. KOBLENER, M. ŠLAJ, I. ANIĆ, T. MILOŠAK, Coll. Antropol., 22 Suppl. (1998) 7. — 13. NAGAHARA, K., M. ISOGAI, K. SHIBATA, M. A. MEENAGHA, Int. J. Oral Maxillofac. Impl., 45 (1992) 72. — 14. TATAKIS, D. N., I. TROMBELLI, J. Periodontol., 71 (2000) 299. — 15. SCULEAN, A., N. DONOS, G. C. CHIANTELLA, P. WINDISCH, E. REICH, M. BRECIX, Int. J. Periodont. Rest. Dent., 19 (1999) 501. — 16. AGUIRRE-ZORZANO, L. A., E. ESTEFANIA-CUNDIN, J. GIL-LOZANO, R. MARTINEZ-CONDE, V. NUNEZ-ANTON, J. SANTAMARIA-ZUAZUA, Int. J. Periodont. Rest. Dent., 19 (1999) 363. — 17. BAGAMBISA, F. B., G. JOOS, W. SHILLI, J. Biomed. Mater. Res., 27 (1993) 1047. — 18. CASATI, M. Z., E. A. SALLUM, R. G. CAFFESSE, J. R. NOCITIFH, A. W. SALLUM, S. L. PEREIRA, J. Periodontol., 71 (2000) 238. — 19. RATKA-KRUGER, P., E. NEUKRANZ, P. RAETZKE, J. Clin. Periodontol., 27 (2000) 120. — 20. LAUC, T., P. KOBLENER, Coll. Antropol., 22 Suppl. (1998) 251. — 21. MUSGRAVE, S., P. BOSCH, S. GHIVIZZANI, P. D. EVANSCH, J. HUARD, Bone, 24 (1999) 541. — 22. MACHADO, M. A., C. M. STEFANI, A. W. SALLUM, W. A. TRAMONTINA, F. H. NOCITIJUNIOR, J. Oral Sci., 41 (1999) 181. — 23. MARTIN, C., H. WINET, J. Y. BAO, Biomater., 17 (1996) 2373. — 24. PANDURIĆ, J., D. DODIG, M. KORŠIĆ, T. K. JURKOVIĆ, Coll. Antropol., 20 (1996) 371.

*D. Katanec*

*Department of Oral Surgery, School of Dental Medicine, University of Zagreb, Gundulićeva 5, 10000 Zagreb, Croatia*

## EFIKASNOST POLIGLIKOLNOG KOPOLIMERNOG KOŠTANOG NADOMJESTKA U CIJELJENJU KOŠTANIH DEFEKATA MJERENA DENZITOMETRIJOM

### SAŽETAK

Cijeljenje koštanih defekata je najčešći uzrok neuspjeha kirurškog tretmana odonotogenih koštanih procesa. Svrha ove studije je procjena uspješnosti cijeljenja košanog defekta poslije implantacije aloplastičnog kopolimernog košanog implantata. Grupi od 45 ispitanika s ostitičkim periradikularnim procesom, nakon operativnog zahvata, ugrađen je kopolimerni koštani nadomjestak (Fisiograft, Ghimas s.p.a.). Ispitanici su praćeni na osnovu kliničkog i rtg nalaza u periodu od dvanaest mjeseci. Rezultati su valorizirani na osnovi denzitometrijskog mjerenja na digitaliziranim rtg slikama učinjenim pomoću radiovizigrafije. Dobiveni rezultati su analizirani i prezentirani grafički. Trideset osam pacijenata (84%) uspješno je liječeno, a kod sedam pacijenata (16%) došlo je do neuspješnog cijeljenja košanog defekta. Dobiveni rezultati pokazuju da se poliglikolni kopolimerni koštani implantati mogu uspješno koristiti u tretiranju odonotogenih koštanih defekata. Njihova osnovna prednost je spora biorazgradnja, koja osigurava povoljan prostor za apoziciju nove kosti unutar defekta, jednostavna primjena u kliničkom radu i mogućnost međusobnog kombiniranja sva tri proizvodna oblika.