

Changes in the Tissue Expression of the *C-erbB-2* Oncogen in the Oral Lichen Ruber

Ahmed Pirkić¹, Dolores Biočina-Lukenda², Ana Cekić-Arambašin²,
Dino Buković³, Ljubomir Pavelić⁴ and Šime Šakić⁵

¹ Department of Clinical Pathology »Ljudevit Jurak«, University Hospital »Sestre milosrdnice«, Zagreb, Croatia

² Department of Oral Medicine, School of Dental Medicine, University of Zagreb, Croatia

³ Department of Prosthodontics, School of Dental Medicine, University of Zagreb, Croatia

⁴ University Hospital for Lung Diseases »Jordanovac«, Zagreb, Croatia

⁵ Department of Orthopedic Surgery, University Hospital Center »Zagreb«, Zagreb, Croatia

ABSTRACT

The aim of this study was to determine the expression intensity of c-erbB-2 antigen in oral lichen planus and erosive form of oral lichen in 30 patients, and to compare the obtained results with the inflammation intensity i.e. hyperkeratosis. The examination of expression intensity of c-erbB-2 antigen was conducted through immunohistochemical analysis by APAAP method. Obtained reaction of examined tissue antigen was positive in individual or in group cells of spinous epithelium layer and mosaically expressed. The reaction was negative in basal cell epithelium layer. Strong intensity reaction was observed in intercellular bridges of spinous cells layer. In control group, the reaction was of uniform strong intensity in all epithelium layers. The reaction was not dependent on the inflammation intensity in lesions but it was positively correlated with their degree of hyperkeratosis. Changed expression of c-erbB-2 antigen in OLR lesions reveals the possibility of potential malignant transformation of these lesions.

Key words: *c-erbB-2, oral lichen ruber, hyperkeratosis, malignant transformation*

Introduction

In recent years the results of various studies point to premalignant potential of oral lichen lesions which may cause po-

tential inception of oral squamous carcinoma (OSCC)¹⁻⁴. According to the results of published studies the frequency of ma-

lignant transformation i.e. frequency of oral lichen lesions transformation in OSCC varies, ranging from 0.3–10%^{5–9}. In some clinical forms of oral lichen ruber, like atrophic, erosive and ulcerous lesions, more frequent inception and development of OSCC has been observed^{9–11}.

Proto-oncogene *c-erbB-2* located on chromosome 17 at band q21 encodes the synthesis of phosphoglycoprotein receptor *p185^{erbB2}* (*p185^{HER-2/neu}*), which has tyrosine kinase activity. *c-erbB-2* receptor can be found in many tissue cells^{12,13}.

Excessive expression of *c-erbB-2* oncogene is present in 20%–25% cases of primary lung tumors and ovaries tumors¹⁴, 19%–44% cases of urinary bladder carcinoma¹⁵, certain tumors of salivary glands, like sialocarcinoma, pleomorphic adenoma and mucoepidermoid carcinoma^{16,17}, and in OSCC lesions developed from OLR^{18–20}.

This paper examined the modified tissue expression of *c-erbB-2* antigen in ORL lesions, as important indicator of the prognosis and course of the disease in relation with specific clinical forms of oral lichen ruber, clinical intensity of the inflammation of oral mucosa membrane and clinical intensity of hyperkeratosis of oral mucosa membrane.

Materials and Methods

Subjects

This study included 30 patients with oral lichen ruber (OLR), 15 patients with clinical manifestations of lichen ruber planus (LRP) and 15 patients with clinical manifestations of erosive lichen ruber (LRE). Average age of the patients with oral lichen was 48.1±12.7 years. Control group included 15 patients diagnosed with homogenous oral leukoplakia (OL). Average age of the patients with oral leukoplakia was 44.87±12.77 years.

The investigation was carried out through the clinical diagnosis and deter-

mination of clinical OLR forms and clinical diagnosis of OL^{21,22}.

Clinical status of OLR and OL was evaluated through the clinical parameters of the disease: *inflammation* graded as 0 (no visible inflammatory reaction), grade 1 (barely visible inflammatory reaction with local reddening of mucous membrane and small affected area), grade 2 (inflammatory reaction of medium intensity ranging between grade 1 and grade 3) and grade 3 (distinctly reddish and extended inflammatory reaction of high intensity; affected area of oral mucous membrane is wider than in hyperkeratosis lesion of OLR); *hyperkeratosis* graded as 0 (no visible keratosis), grade 1 (mild, whitish-gray hyperkeratosis barely visible on oral mucous membrane; affected area is less than 5 mm²), grade 2 (the color of hyperkeratosis changes to whitish-gray with affected area between 5–10 mm²) and grade 3 (white hyperkeratosis with affected area bigger than 10 mm²)²³.

The diagnosis of oral lichen ruber and oral leukoplakia determined on a basis of described clinical oral tests and parameters were confirmed in all patients through the pathohistologic diagnosis^{21,24}.

Biopsy samples

Biopsy samples were collected from the pathologically changed oral mucosa membrane, from the border between healthy and diseased tissue, after the administration of 1 ml of local anesthetic solution (3% Mepivastein, ESPE, Germany).

Before the biopsy, sampling the patients with OLR and OL did not go through adequate systemic or local therapy.

Immunohistochemical analysis of biopsy samples

Tissue samples were fixated in buffered 4% paraformaldehyde for 24 h, embedded in paraffin and sectioned with

cryomicrotome to 4 nm thick slices. After deparaffination and rehydration, tissue slices were routinely processed and stained with hematoxylin-eosin and mounted on a slide with Canada balsam.

For the purpose of immunohistochemical analysis antigen demasking was performed by heating tissues sections in a microwave oven (MOULINEX) 3x5' at 800 W in citric acid buffer (pH 6.0). Then the sections were rinsed several times in TRIS buffer (pH 7.6) and processed with APAAP method (Alkaline Phosphatase-Anti-Alkaline Phosphatase Complex) by incubation with BCIP/NBT (Alkaline Phosphatase chromogen kit – DAKO) substrate for 1 hour at the room temperature. Monoclonal mouse antibody anti-human *c-erbB-2* (DAKO) was tested in optimal dilution of 1:50. The final product of the reaction was visualized as dark blue precipitate located on cellular membrane.

The intensity of immunohistochemical reaction of tissue antigen *c-erbB-2* expression in samples was evaluated semi quantitatively and marked as a reaction of negative intensity (–), low positive intensity (+), moderate positive intensity (++) and high positive intensity (+++).

Statistical data processing

The results were statistically analyzed using nonparametric χ^2 test and the Spearman rank correlation method. The results were considered statistically important if the level of importance was 5% or lower ($p < 0.05$). Statistical program STATISTICA for Windows, Release 5.5 H ('99 Edition) was used during the analysis of the results.

Results

Obtained expression intensity values of this antigen, i.e. the share of individual tissue expression intensity of *c-erbB-2*

antigen in biopsy samples of OLR and OL lesions are shown in Figure 1.

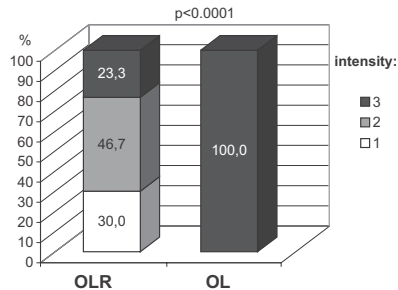


Fig. 1. The proportion of the expression intensity of tissue antigen *c-erbB-2* in oral lichen ruber lesions (OLR; N=30) and oral leukoplakia lesions (OL; N=15).

Statistically important lower intensity of *c-erbB-2* antigen expression was observed when compared with the intensity of its expression in OL samples ($\chi^2 = 23.4611$; $p < 0.0001$).

Immunohistochemical analysis of biopsy samples of OLR lesions showed a polymorph membranous reaction of *c-erbB-2* antigen expression in the epithelial cells, especially expressed in the topography and the intensity of the reaction itself with accentuated mosaic pattern (Figure 2), that was expressed mostly in spinous cells layer but negative in superficial cells layer. The reaction was intensely positive in interepithelial bridges of the spinous cell layer (Figure 3). Opposite to positive reaction in spinous cell layer, the reaction was negative in basal cell layer.

Analysis of biopsy samples of OL showed the membranous-type reaction, exclusively uniform and strong in spinous and basal cell layers (Figure 4).

Expression intensity of that antigen was equal in biopsy samples of various clinical forms of LRE and LRP ($\chi^2 = 0.254$; $p = 0.8807$).

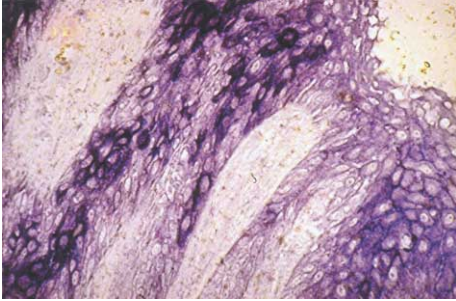


Fig. 2. Oral lichen ruber (OLR). Mosaicism of immunohistochemical reaction expressed in the spinous cell layer (APAAP x200).

The expression intensity of *c-erbB-2* tissue antigen with the intensity of inflammation in OLR and OL lesions is shown in Tables 1 and 2.

Relation between inflammation intensity and the expression intensity of *c-erbB-2* antigen in OLR and OL lesions was not evidenced ($\sigma=-0.266$; $p=0.077$).

The comparison between expression intensity of *c-erbB-2* tissue antigen and the intensity of hyperkeratosis in OLR and OL lesions is shown in Table 3 and 4.

Hyperkeratosis intensity in OLR and OL lesions was positively correlated with the expression intensity of *c-erbB-2* tissue antigen ($\sigma=0.687$; $p<0.0001$).

Discussion

The perception that the excessive expression of *c-erbB-2* antigen exists in malignantly transformed cells revealed the necessity to identify this antigen as a status indicator of malignantly changed lesions. Strong expression of *c-erbB-2* oncogene was observed in many neoplasms where its expression was positively correlated with their invasiveness and their ability to metastasize in other tissues.

The results of this study revealed different expression of *c-erbB-2* than expected.

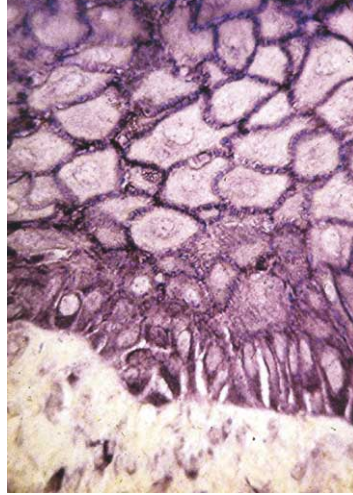


Fig. 3. Oral lichen ruber (OLR). Intensified immunohistochemical reaction expressed in interepithelial bridges of the spinous cell layer (APAAP x400).

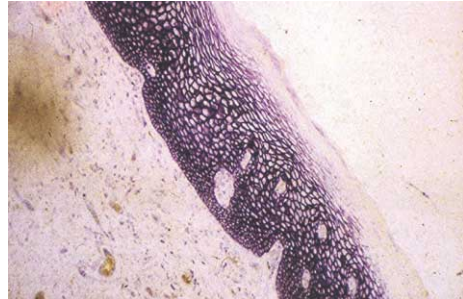


Fig. 4. Oral leukoplakia (OL). Intensified immunohistochemical reaction of equally strong intensity in the basal cell and in spinous cell layers (APAAP x200).

Tissue expression of *c-erbB-2* antigen in OLR lesions showed low reaction intensity compared to the distinctly strong reaction intensity in OL lesions. There was no difference in the *c-erbB-2* antigen expression intensity in erosive and in planus lichen. The relation between the inflammation intensity and the expression intensity of *c-erbB-2* protein in OLR and

TABLE 1
THE PROPORTIONS OF EXPRESSION INTENSITY OF TISSUE ANTIGEN C-ERBB-2 RELATED WITH THE INFLAMMATION GRADE IN ORAL LICHEN RUBER LESIONS (OLR; N=30)

Expression intensity of <i>c-erbB-2</i> antigen	Inflammation grade in OLR lesions % (N)			
	0	1	2	3
+	0	0	26.7 (8)	3.3 (1)
++	0	0	13.3 (4)	33.3 (10)
+++	0	0	0	23.3 (7)

+ = low positive intensity, ++ = moderate positive intensity, +++ = high positive intensity

TABLE 2
THE PROPORTIONS OF EXPRESSION INTENSITY OF TISSUE ANTIGEN C-ERBB-2 RELATED WITH THE INFLAMMATION GRADE IN ORAL LEUKOPLAKIA LESIONS (OL; N=15)

Expression intensity of <i>c-erbB-2</i> antigen	Inflammation grade in OL lesions % (N)			
	0	1	2	3
+ / ++	0	0	0	0
+++	46.7 (7)	26.7 (4)	26.7 (4)	0

+ = low positive intensity, ++ = moderate positive intensity, +++ = high positive intensity

TABLE 3
THE PROPORTIONS OF EXPRESSION INTENSITY OF TISSUE ANTIGEN C-ERBB-2 RELATED WITH THE DEGREE OF HYPERKERATOSIS IN ORAL LICHEN RUBER LESIONS (OLR; N=30)

Expression intensity of <i>c-erbB-2</i> antigen	Hyperkeratosis degree in OLR lesions % (N)			
	0	1	2	3
+	0	13.3 (4)	16.7 (5)	0
++	0	0	36.7 (11)	10.0 (3)
+++	0	0	0	23.3 (7)

+ = low positive intensity, ++ = moderate positive intensity, +++ = high positive intensity

TABLE 4
THE PROPORTIONS OF EXPRESSION INTENSITY OF TISSUE ANTIGEN RELATED WITH THE DEGREE OF HYPERKERATOSIS IN ORAL LEUKOPLAKIA LESIONS (OL; N=15)

Expression intensity of <i>c-erbB-2</i> antigen	Inflammation grade in OL lesions % (N)			
	0	1	2	3
+ / ++	0	0	0	0
+++	0	0	40.0 (6)	60.0 (9)

+ = low positive intensity, ++ = moderate positive intensity, +++ = high positive intensity

OL lesions was not evidenced. On the other hand, positive correlation between expression intensity of *c-erbB-2* protein and the intensity grade of hyperkeratosis in lesions was observed.

Observed lower expression intensity of *c-erbB-2* antigen in OLR lesions is the most interesting result of this study. Similar results were obtained by other authors^{18–20}.

The results of immunohistochemical reaction obtained polymorphy of the membranous *c-erbB-2* antigen reaction according to its intensity and topography, with the accentuated reaction in spinous cells layer but negative in basal cells layer. Membranous reaction of *c-erbB-2* protein could be seen as specific because the antibodies to this antigen recognize its extracellular part. Intense positive reaction in intercellular bridges of the oral epithelium was also observed, making the precedent in literature. The cause for such polymorphism of tissue expression of *c-erbB-2* protein in OLR lesions should be looked for in pathogenetic mechanism of appearance and progression of the disease, including the immunological background and the important role of keratinocytes as immunocompetent cells.

The results of recent published studies reveal that keratinocytes in OLR lesions secrete cytokines IL-6 (interleukin-6) and TNF- α (tumor necrosis factor- α). The very characteristic morphologic lesion of basal cell layer of the oral epithelium in OLR lesions is result of lymphocyte infiltration and mutual interaction of CD8 lymphocytes and keratinocytes¹⁸. Released cytokines may take over the role of autocrine growth factors and induce their proliferation¹⁸.

During the explanation of obtained results, we cannot ignore the fact that *c-erbB-2* protein exists in certain tissues during the embryonic development as well as in the salivary glands epithelium and colonic epithelium of the adults¹². The results of the some studies revealed *c-erbB-2* positive immunohistochemical reaction in healthy oral mucosa^{18–20}.

Comparison between *c-erbB-2* protein expressions in specific oral mucosa lesions revealed its lower expression intensity, e.g. the loss of expression in OLR lesions as well as in lesions of OSCC which

were developed from OLR lesions when compared to the expression in OSCC not followed the oral lichen^{18–20}. Similar results were obtained in this study where lower expression intensity of *c-erbB-2* antigen in oral lichen ruber lesion was observed.

Lower expression intensity of *c-erbB-2* antigen in OLR lesions reveals its changed expression in dysplastic oral epithelia, which was confirmed by other authors^{19,20}. Cellular immunoreactions play a key role in pathogenetic mechanism of OLR development and precede dysplastic changes²⁰. Accumulation of mononuclear infiltrate with keratinocytes interaction induces the release of multitude of cytokines that may affect the *c-erbB-2* transmembranous protein expression. It is a well-known fact that the activity of IFN- γ (interferon-gamma) induces an array of changes in cellular surface that may affect the expression of cellular receptors as well as the oncogene expression^{12,13}.

Conclusion

This study showed changed expression of tissue antigen *c-erbB-2* in OLR lesions, manifested as a membranous-type reaction, which polymorphy varied according to the intensity and topography. Described low expression reaction of tissue antigen *c-erbB-2* in basal and parabasal cell layer in OLR lesions combined with strong intensity reaction in intercellular bridges of spinous cell layer can be an early sign of the tissue transformation. Weakened or negative immunohistochemical reaction in oral lichen lesions, opposite to the stronger reaction in OL lesions, reveals the existence of some internal provoking signal that can induce the malignant transformation of OLR lesions.

REFERENCES

1. SILVERMAN, S. Jr., S. BAHR, Am. J. Dent., 10 (1997) 259. — 2. VAN DER MEIJ, E. H., K. SCHEP-MAN, Oral. Surg. Oral Med. Oral Pathol., 88 (1999) 307. — 3. GARCIA-POLA, M. J., J. M. GARCIA-MARTIN, M. GONZALES, Oral Dis., 5 (1999) 259. — 4. HIETANEN, J., M. R. PASSONEN, M. KUHLFELT, Oral Oncol., 35 (1999) 278. — 5. BERNARD, N. A., C. SCULLY, J. W. EVERSON, S. CUNNINGHAM, S. R. PORTER, J. Oral Pathol. Med., 22 (1993) 421. — 6. BIOČINA-LUKENDA, D., A. CEKIC-ARAMBAŠIN, K. JORGIĆ-SRDJAK, Coll. Antropol., 22 (1998) 83. — 7. EISENBERG, E., D. J. KRUTCHKOFF, Oral Surg. Oral Med. Oral Pathol., 73 (1992) 699. — 8. HOLMSTRUP, P., Oral Surg. Oral Med. Oral Pathol., 73 (1992) 704. — 9. BIOČINA-LUKENDA, D., Acta Stomatol. Croat., 36 (2002) 451. — 10. SILVERMAN, S. Jr., F. LOZADA-NUR, C. MIGLIORETI, Oral. Surg. Oral Med. Oral Pathol., 59 (1995) 360. — 11. SILVERMAN, S. Jr., M. GORSKY, F. LOZADA-NUR, K. GIANNOTTI, Oral Surg. Oral Med. Oral Pathol., 72 (1991) 665. — 12. SCHECHTER, A. L., D. F. STERN, L. VAIDYANATHAN, S. J. DECKER, J. A. DREBIN, M. I. GREENE, R. A. WEINBERG, Nature, 312 (1984) 513. — 13. OCHAREN-RAT, P., P. H. RHYS-EVANS, H. MODJTAHEDI, S. A. ECCLES, Oral Oncol., 38 (2002) 627. — 14. HORIGUCHI, J., Y. ILNO, H. TAKEI, Oncology, 1 (1994) 47. — 15. LIPPONEN, P. K., Pathobiology, 61 (1993) 178. — 16. DARDICK, J. R., L. E. BIREK, J. Oral Medical Pathol., 23 (1994) 226. — 17. KRECECKI, T., M. JELEN, M. ZALESSKA-KRECICKA, Acta Otorolaryngol. (Stockh.), 119 (1999) 392. — 18. KILPI, A., A. RICH, Y. T. KONTTINEN, P. READE, Br. J. Dermatol., 133 (1995) 847. — 19. KILPI, A., A. M. RICH, Y. T. KONTTINEN, P. C. READE, Eur. J. Oral Sci., 104 (1996) 278. — 20. KILPI, A., A. M. RICH, P. C. READE, Y. T. KONTTINEN, Austral. Dental J., 41 (1996) 87. — 21. WHO, Oral Surg. Oral Med. Oral Pathol., 46 (1978) 213. — 22. ANDREASEN, J. O., Oral Surg. Oral Med. Oral Pathol., 25 (1968) 31. — 23. DOBRENIĆ, M., Oralne bolesti: Dijagnostika i terapija. (JUMENA, Zagreb, 1987). — 24. ANDREASEN, J. O., Oral Surg. Oral Med. Oral Pathol., 25 (1968) 158.

A. Pirkić

*Department of Clinical Pathology »Ljudevit Jurak«, University Hospital
»Sestre milosrdnice«, Vinogradska c. 29, 10000 Zagreb, Croatia*

PROMJENE U TKIVNOJ EKSPRESIJI C-ERB-2 ONKOGENA U ORALNOM LICHEN RUBERU

SAŽETAK

U radu je istražen intenzitet izražajnosti *c-erbB-2* antigena u oralnom lichen ruber planus (LRP) i u lichen ruber erosivus (LRE) u 30 bolesnika s oralnim lichenom. Rezultati su uspoređeni s kliničkim stupnjevima upale i hiperkeratoze. Izražajnost antigena *c-erbB-2* istražena je imunohistokemijskom APAAP metodom. Tkivna reakcija bila je mozaičkog tipa i pozitivna u pojedinačnim stanicama spinoznog sloja oralnog epitela, dok je u stanicama bazalnog sloja bila negativna. Reakcija jakog intenziteta zapažena je u međustaničnim mostićima spinoznog sloja. Intenzitet reakcije je bio neovisan o stupnju upale, ali je pozitivno korelirao sa stupnjem hiperkeratoze. U kontrolnoj grupi oralne leukoplakije reakcija je bila pozitivnog ishoda u stanicama svih slojeva oralnog epitela i uniformno jakog intenziteta. Promijenjena tkivna izražajnost *c-erbB-2* antigena u oralnom lichen ruberu indicira potencijalnu zloćudnu pretvorbu ove lezije.