

Has Ombredanne's Method of Hypospadiac Urethra Reconstruction Been Ignored with Reason?

Ante Kvesić¹, Šime Vučkov¹, Božidar Župančić², Mislav Bastić², Suzana Jonovska¹, Ante Čizmić², Miro Klarić³ and Zoran Bahtijarević²

¹ Department of Pediatric Surgery, University Hospital Center, Rijeka, Croatia

² Clinic of Pediatric Surgery, Clinical Hospital for Children, Zagreb, Croatia

³ Department of Psychiatry University Hospital, Mostar, Bosnia and Herzegovina

ABSTRACT

From January 1970 to December 1979 inclusive, 193 boys (aged 2 to 16) underwent surgery for distal hypospadias using Ombredanne's method at the Department of Pediatric Surgery University Hospital Center Rijeka and at the Department of Pediatric Surgery Zagreb. Follow-up period was 7 to 20 years (mean 13.4). 20 (10.36%) subjects had post-operative organic complications and 15 (7.77%) of them required surgical correction. According to these findings, the success rate using Ombredanne's method of reconstruction of the hypospadiac urethra in no way lags behind the success rate using MAGPI and Mathieu's methods as well as »Preputial island flap urethroplasty« for analogous cases. Out of 193 subjects who underwent surgery, 80 (41.45%) of those who were sexually mature and had normal psychosexual development were questioned. In this sample, 75 (93.75%) were satisfied with the post-operative appearance of the penis while only 5 (6.25%) were dissatisfied, 3 of which had hypoplastic penis. In 78 (97.50%) subjects questioned, the post-operative urinary squirt was normal and two of them had weak urinary squirt (2.50%), due to meatal stenosis. In conclusion, Ombredanne's method of reconstruction of the urethra in boys with distal hypospadias is equally successful as other methods used for this purpose.

Key words: urethra, hypospadias, Ombredanne method of therapy – two stage repair

Introduction

Hypospadias is a developmental disorder, which never directly endangers life but causes extreme difficulty in severe cases. It is commonly stated that frequency occurs in the ratio 1:300–350 of healthy-born male children^{1–4}. Hypospadias has been divided into several different categories according to the position of the external urethra opening and the most commonly cited category is that which divides the external opening of the frontal (distal) and rear (proximal). Examples of frontal hypospadias are those where the urethra opening rests in the glans area, coronary sulcus, subcoronary or distal part of the penis, while all other examples with a more proximally located urethra opening are proximal types. Frequency of distal hypospadias is 70–85%^{4–7}.

It is usually stated that there are more than 200 methods of reconstructing hypospadiac urethras and their modifications^{8–11}, which suggest that there is no universal method suitable for treating all forms of hypospa-

dia^{12,13}. Many surgical methods of treatment were in use at one stage but later were abandoned and forgotten¹⁴.

In 1911, Ombredanne inaugurated his technique for reconstructing a frontal type hypospadiac urethra, and it can be classified as belonging to that category which uses local genital tissue for that purpose^{15–17}. This method was used for decades in many medical centers. However, over the last couple of decades, it has been overtaken by other, more modern, methods. Today, it is used in some European centers while in American centers it has practically been abandoned over the last three decades^{18,19}.

Materials and Methods

From January 1970 to December 1979, 193 boys with distal hypospadias underwent surgery using Ombredanne's method of hypospadiac urethra reconstruction in the

Department of Pediatric Surgery in Rijeka and the Clinical Hospital Children in Zagreb. Table 1 shows the

TABLE 1
AGE OF PATIENTS WHO UNDERWENT SURGERY USING OMBREDANNE'S METHOD AT TIME OF OPERATION, LAST CHECK-UP AND FOLLOW-UP

Age group (years)	N (%) of patients operated by age groups	N (%) of patients followed-up* by age groups
0–2	0	0
2–4	51 (26.42)	0
4–6	86 (44.56)	8 (4.15)
6–8	33 (17.10)	20 (10.36)
8–10	12 (6.22)	30 (15.54)
10–12	7 (3.63)	22 (11.40)
12–14	2 (1.04)	15 (7.77)
14–16	2 (1.04)	13 (6.74)
16–18	0	10 (5.18)
18–20	0	16 (8.29)
20–22	0	14 (7.25)
22–24	0	11 (5.70)
24–26	0	8 (4.15)
26–28	0	11 (5.70)
28–30	0	8 (4.15)
30–32	0	7 (3.63)
TOTAL	193 (100%)	193 (100%)

* Mean follow-up 13.4 years

boys' ages when operated and on the last follow-up. We can see that the greatest number of patients underwent surgery within the first six years and two of them were even between 14 and 16 years old. Follow-ups were from 7 to 20 years (mean age 13.4). Sixty-four (64) boys (37.7%) had hypospadias and recurvation, which required correction to the penis axis. The operations were carried out at both centers by two surgeons.

Ombredanne's method is carried out with a two-stage repair. Figure 1 shows a sketch of the first reconstruction and Figure 2 the second stage of hypospadiac urethra reconstruction using this method. It is suitable for reconstruction of the urethra only for boys with distal hypospadias and, for this purpose, preputial tissue and the surrounding penis tissue is used. This method also leaves intact the urethral plate, which, together with the preputial lobe in the second stage of reconstruction, then forms a neourethra.

Results

From January 1970 to December 1979 inclusive, 193 boys were treated for distal hypospadias using Ombredanne's method (Table 1). We observed the results of application of this method of urethra reconstruction on the basis of an appraisal of four types of parameters: frequency of post-operative complications which require reintervention, post-operative normally developed or impaired psychosexual function, post-operative cosmetic appearance of penis and satisfaction with operation, and satisfaction with post-operative urination.

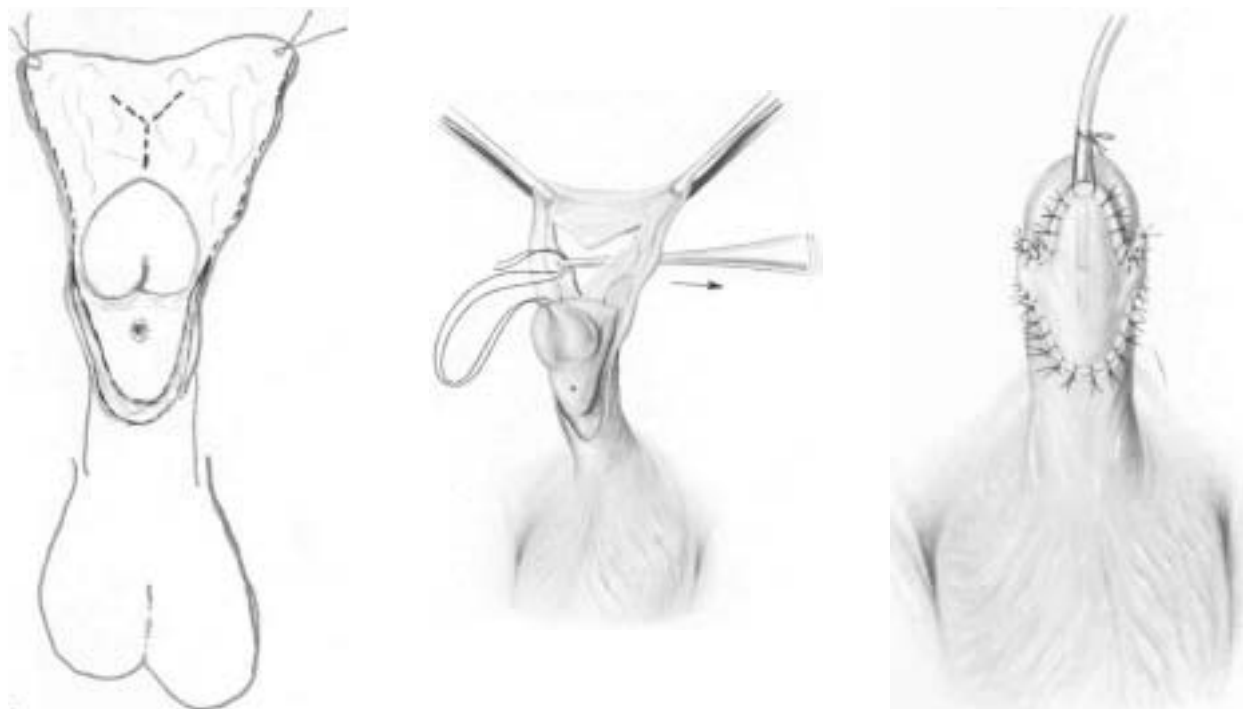


Fig. 1. Sketch of first-stage reconstruction of hypospadiac urethra using Ombredanne's method.

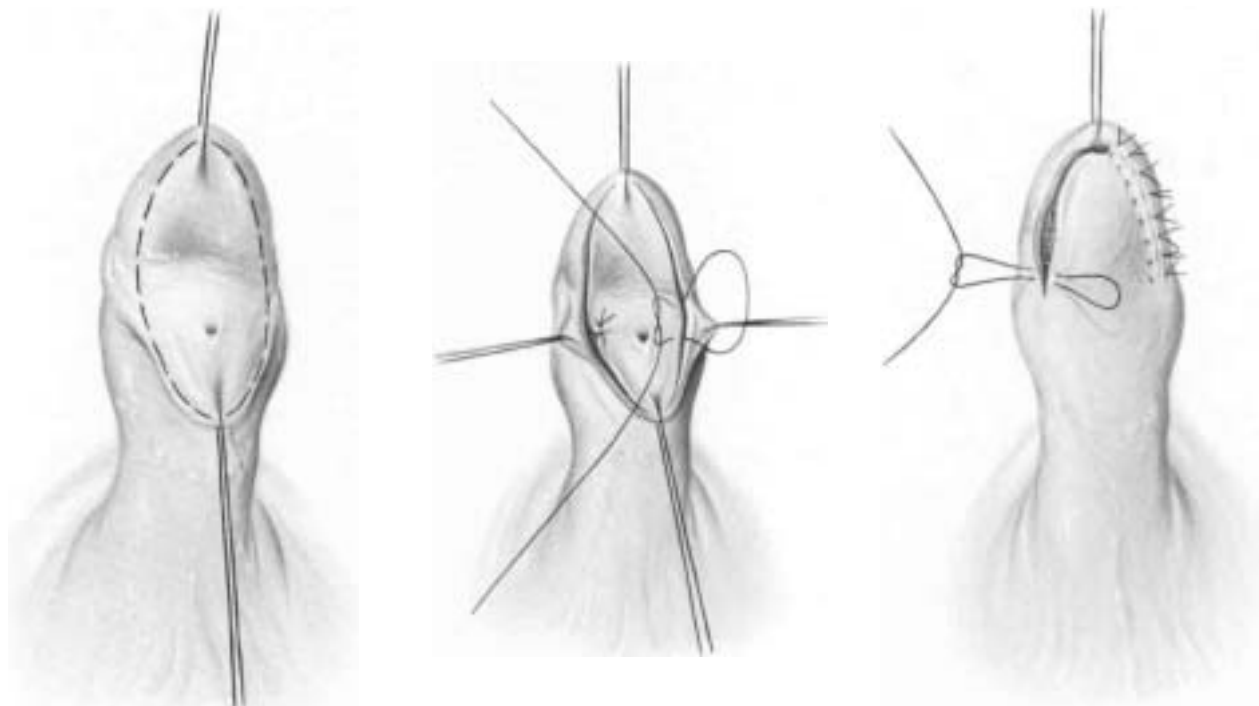


Fig. 2. Sketch of second-stage reconstruction of hypospadiac urethra using Ombrédanne's method.

TABLE 2
POST-OPERATIVE COMPLICATIONS FOLLOWING HYPOSPADIC URETHRA RECONSTRUCTION USING OMBRÉDANNE'S METHOD

Post-operative complication	Fistula	Stenosis	Meatus retraction	Meatal stenosis	Delusence	»Dog ears«	Total
N (%) of patients	5 (2.59)	0	0	2 (1.04)	6 (3.11)	7 (3.63)	20 (10.36)

The frequency of post-operative organic complications is shown in Table 2. Fistulas can be seen in 5 subjects (2.59%), dehiscence with meatus in 6 (3.11%), meatal stenosis in 2 (1.04%) and excessive skin ducts i.e. so-called »dog ears« in 7 (3.63%) subjects. Consequently in 20 surgery cases (10.36%) post-operative organic complications arose. In five cases, we had to occlude fistulas. From 6 boys who had partial lobe dehiscence immediately following the new external urethral opening, we were forced with three of them to carry out surgical correction but the condition was normal for the remaining 3 subjects. With 2 of them where meatal stenosis developed through simple dilatation with Hegar's probe, on several occasions we achieved conclusively a clear passage. Surgical resection was carried out on 7 boys who had post-operative excessive skin ducts. It can, therefore, be concluded that from 20 boys with distal hypospadias who were operated on using Ombrédanne's method, only 15 subjects (7.77%) had to have surgical post-operative correction following organic complications.

In Table 3, the results of a questionnaire with 80 subjects who underwent surgery for distal hypospadias are

shown. This examination tested the appearance of the penis, quality of erection, ejaculation, possibility of intercourse, masturbation and satisfaction with post-operative appearance of the penis. The remainder, however, did not reply to the questionnaire linked to psychosexual function. All those who replied to the questionnaire were sexually mature at the time of answering the questions. Five (6.25%) subjects post-operatively had a slightly deformed penis, while 75 (93.75%) subjects had straight penis (Table 3). 75 subjects (93.75%) were satisfied with the appearance of the penis while 5 subjects (6.24%) were dissatisfied. Dissatisfaction with 3 subjects was caused by a noticeably small penis, which, *a priori*, had been considerably less developed (hypoplastic), while with 2 subjects it was caused by a slight deformity following urethra reconstruction. They, however, blamed the operational technique for their deformed penis and were unwilling to accept again the possibility of correction.

Table 4 shows post-operative findings related to satisfaction in urinating with 80 subjects questioned. We can see that with 78 (97.50%) the squirt was normal while with only 2 (2.50%) it was weak. This was caused

TABLE 3
SEXUAL FUNCTION OF SUBJECTS WHO UNDERWENT SURGERY USING OMBRÉDANNE'S METHOD,
QUESTIONED AFTER OPERATION

Sexual function	Appearance of penis		Erection		Ejaculation		Intercourse		Satisfaction with appearance of penis		Masturbation	
	Straight	Slightly distorted	Yes	No	Yes	No	Orderly	With disturbance	Yes	No	Yes	No
N (%) of subjects questioned	75 (93.75%)	5 (6.25%)	80 (100%)	0	80 (100%)	0	53 (66.25%)	0	75 (93.75%)	5 (6.25%)	Nr	Nr

Nr – no response

TABLE 4
SATISFACTION WITH URINATION IN SUBJECTS WHO UNDERWENT SURGERY USING OMBRÉDANNE'S METHOD
OF HYOSPADIC URETHRA RECONSTRUCTION

N (%) of subjects questioned	Urinary squirt			
	Normal	Weak	Straight	Slightly veering to side
80 (100.0%)	78 (97.50%)	2 (2.50%)	77 (96.25%)	3 (3.75%)

by meatal stenosis, which was later removed by instrumental dilatation of the urethral meatus. In the last follow-up with those subjects questioned, a micturitional cystourethrograph was indicated and carried out but no trace of bladder trabeculation was found as possible consequences of the stenosis. The results of an examination of the direction of the urinary squirt are shown following reconstruction of the urethra (Table 4). It was found that with 77 subjects (96.25%) the squirt was normal while with 3 subjects, the squirt was slightly off course. These three subjects were, nevertheless, satisfied with the direction of the urinary squirt and were unwilling to accept the possibility of subsequent surgical correction.

Discussion

In the middle of the XIX century, the quest began for a method of surgically treating hypospadias¹ and continued to the end of that century^{13,20}. This research continued on the threshold of the XX century and it was just then, in 1911, that Ombredanne appeared and for the first time announced his method of hypospadiac urethra plastics using preputial tissue, flap of penis and urethral plate^{18,21}. In the middle of the XX century, numerous new methods of urethra plastics and their modification were invented²². Examining current world medical literature, three groups of methods are most commonly used for reconstruction of hypospadiac urethra: MAGPI^{6,23,24}, Mathieu's^{25–27} and the group »Preputial island flap urethroplasty«^{9,28–30}.

In the first decades following inauguration, Ombredanne's method was used for reconstruction of the urethra in boys with distal hypospadias in numerous medical centers of Europe and America^{15,31}. Today, it is rarely used and only in a small number of European centers,

while in America it has practically been completely abandoned^{18,19}. For more than half a century, it has been applied in both our medical centers for treating distal hypospadias. From our results, we can see that only 20 (10.36%) boys with distal hypospadias who were operated on using Ombredanne's method had organic complications. Of that number, only 15 (7.77%) of them needed surgical correction for post-operative complications (5 boys with urethral fistula, 3 with dehiscence and 7 with excessive skin ducts, so-called »dog-ears«) while with 2 subjects stenosis meatus urethra was eliminated with simple instrumental dilatation. Three subjects who had slight dehiscence were satisfied with their condition and did not seek surgical intervention.

Our experience has shown that we have had, therefore, good results using Ombredanne's method in reconstruction of the urethra in boys with distal hypospadias and these results do not lag behind the results of other authors who use MAGPI, Mathieu's and the group »Preputial island flap« methods. Fistula is the most indicative post-operative organic complication in appraising success of applied methods in reconstruction of hypospadiac urethra. Namely, this complication, however noticeable it is, always requires subsequent surgical therapy.

Jawad²⁴, using the MAGPI method of reconstructing hypospadiac urethra, had post-operative organic complications with 2.94% of subjects, Duckett³² with 2.6% and Duckett and Snyder²³ with 10.81%. Applying Mathieu's method in treating distal hypospadias, Buson et al.²⁵ had post-operative organic complications with 9.8% of boys who underwent surgery. Ulman et al.⁴ had 9.28% and Hakim et al.³³ had 3.90%. Using »Preputial island flap urethroplasty« Kass et al.³⁴ had 4.0% of organic complications following surgery; Chen et al.²⁸ had 18.33%;

Rushton and Belman⁷ had 5.0%; Basin et al.¹ had 6.95%. In our observed group of 193 boys with distal hypospadias who underwent surgery using Ombredanne's method, 20 (10.36%) of them had post-operative organic complications and only 15 (7.77%) of them required surgical correction.

In all 80 subjects questioned (only this number responded to the questionnaire), the psychosexual development was normal and the sexual function following puberty was also normal. The only point on which the subjects did not comment was the success or failure of masturbation and some of them up to the moment of responding to the questionnaire had not even had intercourse. This aspect of appraising the success of the method of reconstructing the hypospadiac urethra has not been covered in more detail in literature so it is difficult, in relation to these parameters, to make an adequate comparison of other authors' success and other methods. The results of our research in this respect coincide with those of Mureau et al.³⁵ and Berg et al.³⁶. We, therefore, consider on the basis of our research that

using Ombredanne's method of reconstructing hypospadiac urethra achieves total success.

From a review on Table 4, it can be seen that with 78 (97.50%) subjects, the urinary squirt was normal while with 2 of them it was weaker following meatal stenosis, which, nevertheless, did not require surgical correction but only instrumental dilatation of the meatus. Furthermore, quite a straight urinary squirt was achieved with 75 (96.25%) of subjects who had undergone surgery and responded to the questionnaire while with 5 (3.75%) of them the squirt was directed quite lightly to the side and in 4 of those cases the cause was post-operative dehiscence. We, therefore, consider that based on these criteria, using Ombredanne's method of hypospadiac urethra reconstruction, success is achieved analogously to cases using MAGPI and Mathieu's methods as well as »Preputial island flap urethroplasty«.

On the basis of our results compared with the results of other authors' achievements using other methods for analogous cases of hypospadias, we can conclude that Ombredanne's method has really not been neglected with reason.

REFERENCES

1. BASKIN, L. S., J. W. DUCKETT, T. F. LUE, *Urol.*, 48 (1996) 347.
2. DEVINE, C. J., C. E. HORTON, *J. Urol.*, 118 (1977) 188.
3. STECKLER, R. E., M. R. ZAONTZ, *J. Urol.*, 158 (1997) 1178.
4. ULMAN, I., V. ERICKI, A. AVANOGLU, A. GÖKDEMİR, *Eur. J. Pediatr. Surg.*, 7 (1997) 156.
5. BARTHOLD, J. S., T. L. TEER, J. F. REDMAN, *J. Urol.*, 155 (1996) 1735.
6. DUCKETT, J. W., *Urol. Clin. N. Amer.*, 8 (1981) 513.
7. RUSHTON, H. G., A. B. BELMAN, *J. Urol.*, 160 (1998) 1134.
8. AHO, M. O., O. K. TAMMELA, T. L. TAMMELA, *Eur. Urol.*, 32 (1997) 218.
9. BELMAN, A. B., *Urol.*, 49 (1997) 166.
10. MILLER, M. A., D. B. GRANT, *Brit. J. Urol.*, 80 (1997) 485.
11. ORR, J. D., *Z. Kinderchir.*, 39 (1984) 119.
12. JOHNSON, D., D. J. COLEMAN, *Brit. J. Plast. Surg.*, 51 (1998) 195.
13. WISHAHI, M. M., M. K. WISHAHI, N. KADDAH, *Eur. Urol.*, 17 (1990) 40.
14. CAIONE, P., N. CAPOZZA, A. LAIS, F. FERRO, E. MATARAZZO, S. NAPPO, *J. Urol.*, 158 (1997) 1168.
15. ABRAMOVIĆ, V., *Hypospadias – Alternative procedures*. In: ECKSTEIN, H. B., R. HOHENFELLNER, D. WILLIAMS: *Surgical Pediatric Urology*. (Georg Thieme Publishers, Stuttgart, 1977).
16. MAIER, W. A., G. TEWES, *Progr. Pediatr. Surg.*, 17 (1984) 79.
17. RETIK, A. B., S. B. BAUER, J. MANDELL, C. A. PETERS, A. COLONDY, A. ATALA, *J. Urol.*, 152 (1994) 749.
18. OMBRÉDANNE, L., *Press Médicale*, 19/1 (1911) 834.
19. SENSÖZ, Ö., S. CELEBIOGLU, C. N. BARAN, U. KOCER, A. T. TELLIOGLU, *Plast. Reconstr. Surg.*, 99 (1997) 93.
20. SMITH, D. R., *J. Urol.*, 97 (1967) 723.
21. KENAWI, M. M., *Brit. J. Urol.*, 47 (1976) 883.
22. DUCKETT, J. W., *Postgrad. Med. J.*, 66 Suppl. (1990) 62.
23. DUCKETT, J. W., H. M. SNYDER, *J. Urol.*, 147 (1992) 665.
24. JAWAD, A. J., *Int. Urol. Nephrol.*, 29 (1997) 681.
25. BUSON, H., D. SMILEY, Y. REINBERG, R. GONZALEZ, *J. Urol.*, 151 (1994) 1059.
26. KOFF, S. A., J. BRINKMAN, J. ULRICH, D. DEIGHTON, *J. Urol.*, 151 (1994) 466.
27. TORKUT, A., O. K. COSCUNFIRAT, *Plast. Reconstr. Surg.*, 99 (1977) 906.
28. CHEN, S., G. WANG, M. WANG, *J. Urol.*, 149 (1993) 814.
29. ELLSHWORTH, P. J., M. A. BARAZZA, P. S. STEVENS, *J. Pediatr. Surg.*, 31 (1996) 917.
30. KOYANAGI, T., K. NONAMURA, T. YAMASHITO, K. KANAGOWA, H. KIKIZAKI, *J. Urol.*, 152 (1994) 1232.
31. GROB, M.: *Lehrbuch der Kinderchirurgie*. (Thieme, Stuttgart, 1957).
32. DUCKETT, J. W., *Hypospadias*. In: WELSH, P. C., R. F. GITTES, A. D. PERLMUTTERE (Eds.): *Campbell's Urology*. (W. B. Saunders Co., Philadelphia, 1986).
33. HAKIM, S., P. A. MERGUERIAN, R. RABINOWITZ, L. D. SHORTLIFFE, P. H. MC KENNA, *J. Urol.*, 156 (1996) 836.
34. KASS, E. J., D. BOLONG, *J. Urol.*, 144 (1990) 520.
35. MUREAU, M. A., F. M. FLIJPER, J. C. van der MEULEN, F. C. VERHULST, K. A. SLOB, *J. Urol.*, 154 (1995) 1351.
36. BERG, R., J. SVENSSON, G. ASTRÖM, *J. Urol.*, 125 (1981) 313.

Š. Vučkov

Department of Pediatric Surgery, University Hospital Center Rijeka, Brdo 10, 51000 Rijeka, Croatia
e-mail: sime.vuckov@ri.t-com.hr

DA LI JE OMBRÉDANNEOVA METODA REKONSTRUKCIJE HIPOSPADNE URETRE BILA ZANEMARENA S RAZLOGOM?

S A Ž E T A K

Od siječnja 1970. do prosinca 1979. godine na Odjelu za dječju kirurgiju Kliničkog bolničkog centra u Rijeci i na Klinici za dječju kirurgiju u Zagrebu operirano je 193 dječaka, starosti od 2 do 16 godina, zbog distalne hipospadije primjenom Ombrédanneove metode. Pacijenti su praćeni od 7 do 20 godina (srednja vrijednost 13,4). Postoperacijske organske komplikacije imalo je 20 (10,36%) ispitanika koje su u njih 15 (7,77%) zahtijevale kiruršku korekciju. Prema tom nalazu postotak uspješnosti primjene Ombrédanneove metode rekonstrukcije hipospadne uretre ne zaostaje nimalo od uspješnosti primjene MAGPI i Mathieuove metode te »Preputial island flap urethroplasty« za analogne slučajeve. Od 193 (100,0%) operirana dječaka njih 80 (41,45%) je anketirano u zreloj spolnoj dobi. Imali su normalan psihoseksualni razvoj, a njih 75 (93,75%) bilo je zadovoljno postoperacijskim izgledom penisa, dok je samo njih 5 (6,25%) bilo nezadovoljno, od kojih su 3 imala apriorno hipoplastičan penis. U 78 (97,50%) anketiranih postoperacijski mlaz mokraće bio je uredan, a u dvojice tanak (2,50%) zbog meatalne stenozе. Kao zaključak, Ombrédanneova metoda rekonstrukcije uretre u dječaka s distalnom hipospadijom jednako je uspješna kao i druge najviše u tu svrhu rabljene metode.