

Dental Arch Relations Analysed in a 14th Century Fossil Skull of the Sao Tribe, Cameroon

Sylvain Santoni, Laurent Jean Sakka and Jean-Marc Garcier

Department of Anatomy, Faculty of Medicine, University of Auvergne, Clermont-Ferrand, France

ABSTRACT

Dental occlusal relations are rarely reported in paleo-anthropology. The manipulation of hemi-arch replicas, as well as the superimposition of drawings on calques traced from photographs, facilitated the description of the intra- and interarch relations. The occlusal interarch confrontation and the intermolar relation were observed and assessed in the horizontal, frontal and sagittal planes. Some measurements were helpful in the functional study. On the basis of knowledge in mandible kinematics a movement envelope of the first molar displacement during mastication was proposed. The dentition studied here was highly regular. It was a fine example of balanced wear for post-canine sectors. In spite of the lower canine extrusion, due to tribal mutilation of anterior teeth and to subsequent labret wearing, the interarch relations seemed not to have been altered.

Key words: paleo-odontology, dental arches, Von Spee curve, Wilson curve, helicoidal occlusal plane, movement envelope

Introduction

Absence of teeth on the maxilla and/or the mandible prevents observation of dental occlusion that could reveal the links between the dentition and the related anatomical structures. In comparative anatomy from morphological, functional and evolutionary standpoints^{1–10}, the dental occlusion completes the paleoanthropological study of a skull in a biodynamic approach^{11–13}. This work committed to me by Pr. Michel Sakka was carried out on the dentition of an almost complete skeleton of a Sao native from prehistoric Cameroon. Considering the wear displayed on the Sao fossil arches it is inappropriate to talk of cuspal interlocking and even less of maximal intercuspation. It would have been better to describe it as an «occlusal confrontation». Anthropologists and specialists in paleo-odontology specify molar relations in an anterior-posterior disposition^{11–14}. They use the Angle orthodontic classification (1899)¹⁵ but in this study the *Fédération Dentaire Internationale* (FDI) Classification is preferred¹⁶. These interarch relations are modified by wear, which also alters the Von Spee and Wilson curves^{17–23}. The mandible of Anthropomorphs provides food comminution in a chewing sequence displaying outward and inward excursions^{19–24}. Mills broke up the movement into a buccal and a lingual phase^{25–26}. Manipulating the tooth arches and their replicas made

it possible to analyse the kinematics of interarch displacement during chewing. Such kinematics revealed by the confrontation of molar occlusal surfaces, facilitated the understanding of the morphological evolution of the teeth, particularly in the case of the first molar which is one of the earliest teeth involved in mastication.

Material and Methods

Material

This skeleton was brought to light in Cameroon by the Annie and Jean-Paul Lebeuf 1978 Mission on the site of Sou (Logone and Chari Prefecture), in an occupation floor, and is evidence of African Prehistory. The skeleton lay in the second level, 2.20 m below the surface, and in January 1978 was dated back – 620 years (±80) by the Gif-sur-Yvette laboratory. The maxilla had 14 teeth : Six on the right: the canine, two premolars and three molars. Eight on the left: two incisors, the canine, two premolars and three molars. The dentition was incomplete. In the anterior part of its right half the two right incisors and a fragment of the alveolar bone were missing. In the posterior part a fragment of the

palatal process and a fragment of the horizontal part of the palatine facing the second and third right molars were missing. A fracture line in the anterior-posterior direction linked the two areas of bone loss (Figure 3). On the side of the right anterior palatine bone loss the right medial and lateral incisors had been lost *post-mortem*. On the left the two remaining incisors were stuck back in their sockets. The left canine was removable from its socket. The mandible had 12 teeth. It was complete but affected by several fracture lines in the symphysis, left ramus and right mandibular angle. The four incisors were missing. The shape of the anterior bone ridge revealed that the teeth had been lost *ante-mortem*. On the maxilla and on the mandible the 26 dental crowns were intact but worn. Both lower canine roots showed mesial wear on their cervical two-third portion. There was no particular deterioration of the bone structure apart from a small radicular exposure at the level of the LM¹ mesiobuccal root. Alveolysis was horizontal and generalized. This is the sign of good periodontal health in a living individual. Calculus was noticed on the dental necks especially on the lingual side. Some teeth could be moved by hand in their sockets. Except for the four mandibular premolars no tooth could be removed from its socket. A slight mesial rotation of the buccal surface of the first mandibular premolar was noticed.

Observation

The anthropological nomenclature was preferred to name the teeth and their cusps. The moulding of these fragile pieces and the making of their plaster replicas are described in a following article. The study of inter-arch relations was made easier by examination of the sole hemi-arch replicas in occlusion (interarch stable confrontation) instead of the complete arch replicas. Observation of the lingual and buccal surfaces was per-

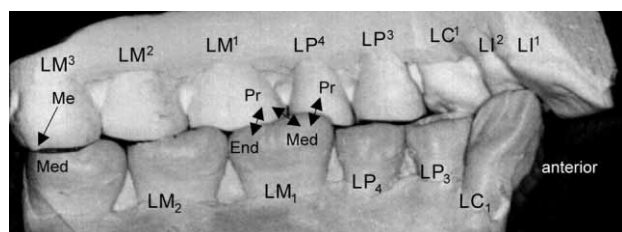


Fig. 1. Plaster replicas showing the Sao skull left hemi-arches in maximal interarch contact (lingual surfaces and part of the occlusal surfaces). Right-angle view obtained thanks to the absence of a contra-lateral hemi-arch. The observation of occluding zones is facilitated by hemi-arch instead of full arch manipulation, but it was difficult because of interference between LC₁ and LI₂. Note the canine extrusion that has progressively reduced the mandible labial excursive displacement. Every cusped tooth, except LM³, made contact with two antagonistic teeth in a 1–2 relation. Two double-pointing arrows (to the left) visualize the contacting zone between LM¹ protocone (Pr) and LM₁ entoconid (End) and metaconid (Med). The third double-pointing arrow (to the right) visualizes the contacting zone between LP⁴ protocone (Pr) and LM₁ metaconid (Med). The single arrow shows the posterior abutment (salient crest of LM³ metacone) stabilizing LM³ against LM₃.

formed at high and low angle. The relations according to FDI classification were recorded. From a one to one scale photograph of the mandibular arch in occlusal view, both maxilla hemi-arch drawings were traced on a transparency directly superimposed onto the picture. From the superimposition of both traces and the observation of the replica occlusion (Figures 1 and 2) a schematic representation of this inter-arch relation was proposed (Figure 3). The distances between M1 and M3 central fossae were also evaluated. An envelope of the first lower molar displacement was also derived on the basis of the wear facets present and on the probable mandible movements.

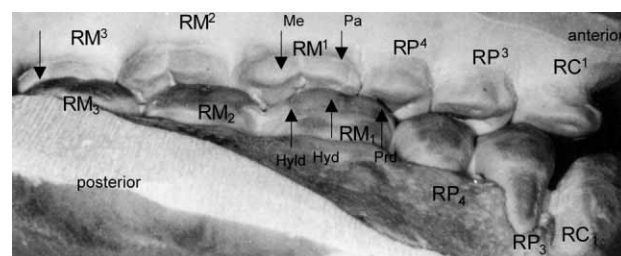


Fig. 2. Plaster replicas of the buccal and part of the occlusal surfaces of the right hemi-arches of the Sao skull (low-angle view). The molar relation is noted in Angle Class 1 or more precisely noted »M« according to FDI classification¹⁶. The upper overlap, maximal at premolar level, regularly declines towards the last molar.

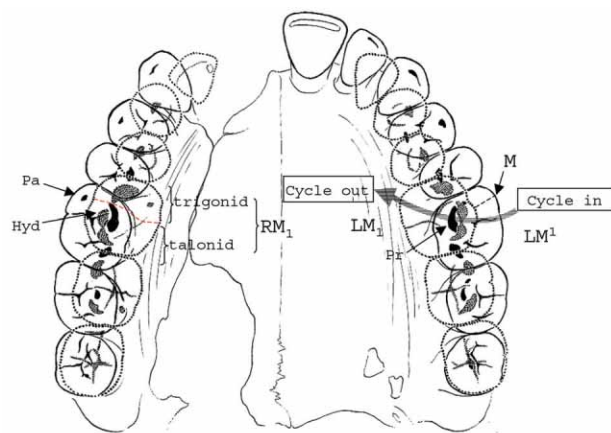


Fig. 3. Schematic view of the upper arch and its basal bone (maxilla) with superimposed contour of the lower dental arch of the Sao skull (dotted lines) in centric occlusion. The upper arch has a parabolic shape, whereas the lower arch is V-shaped. Upper and lower arch contours were drawn using photographs of samples in occlusal view, superimposed with tracings on transparencies. Manual confrontation of the related hemi-arch replicas was necessary to visualize a precise superimposition of both tracings. Note the »M« occlusal relation between LM¹ paracone (Pa) and LM₁ hypoconid (Hyd). On the chewing side (cycle in and cycle out), at the end of the closing movement, the M₁ hypoconid glides against the oblique ridge of M¹ (arrow). At the same time the M¹ protocone (Pr) comes into contact with the M₁ talonid like a pestle in a mortar.

Measurements

The axial views of the right and left, maxillary and mandibular molar sections, were used to measure the distances between the M1 and M2 central fossae on the one hand, and between those of M2 and M3 on the other hand (using Mac Draw pro ® 1.5 Fv 1 Software). For mandibular molars the chosen landmark was the intersection of the buccolingual and mesiodistal grooves on the occlusal surface corresponding to the lower portion of the molar central fossa. For maxillary molars the landmark was the deepest point of the occlusal groove separating the three cusps of the trigon.

Results

Arch curves and occlusal plane

Viewed occlusally, teeth turned upwards, the mandibular arch looked very regular except for its missing labial part (incisors). It was V-shaped, and the distal ends of the dental arch came slightly together in an ellipsoidal shape. The U-shape (or convexity) of the section implied that a homothetic convexity had existed at the anterior arch section of the mandible. The shape of the left maxillary hemi-arch was more convex than its antagonist, because the overlap of its upper buccal cusps decreased towards the back. This was not the case at the third molar level. Wear had erased nearly all the cusps and on the mandibular arch the hypoconid of M3s and the metaconid of LM₁ formed a plane. The metaconid of RM₁ did not reach that plane. Concerning each hemi-arch, it was a succession of three plane portions oriented differently in a helicoidal arrangement. The slope changes occurred between P₄ and M₁ and between M₂ and M₃. However only one slope change occurred on the maxilla between M¹ and M². The Von Spee curve, concave upwards, was very slightly marked. In the frontal view of the maxilla, the Wilson curve was slightly concave downwards at first molar level and upwards at third molar level.

Molar relation

Manual confrontation of hemi-arch replicas in mandible lateral displacement showed that a group function of disclusion had existed at premolar and molar level. Indeed manual positioning of the pieces was difficult due to the lower canine egression. This is why the replicas were fractioned into hemi-arches in order to facilitate the study of functional movements, the wear facets guiding thus the mandible arch displacements.

The position of M₁ in its relation with P₄ and M¹ (1–2 tooth relation) was a little more anterior (2.5 mm) than described in Angle molar class I. More precisely on the buccal side the occlusal margin of the M₁ hypoconid tip came into contact with the slightly convex ridge of the M¹ paracone. This is the »M« position of the FDI classification. It was more marked on the left than on the right. On the lingual side the M¹ protocone came into contact with the M₁ talonid (Figure 1). The M₂-M² relation is a

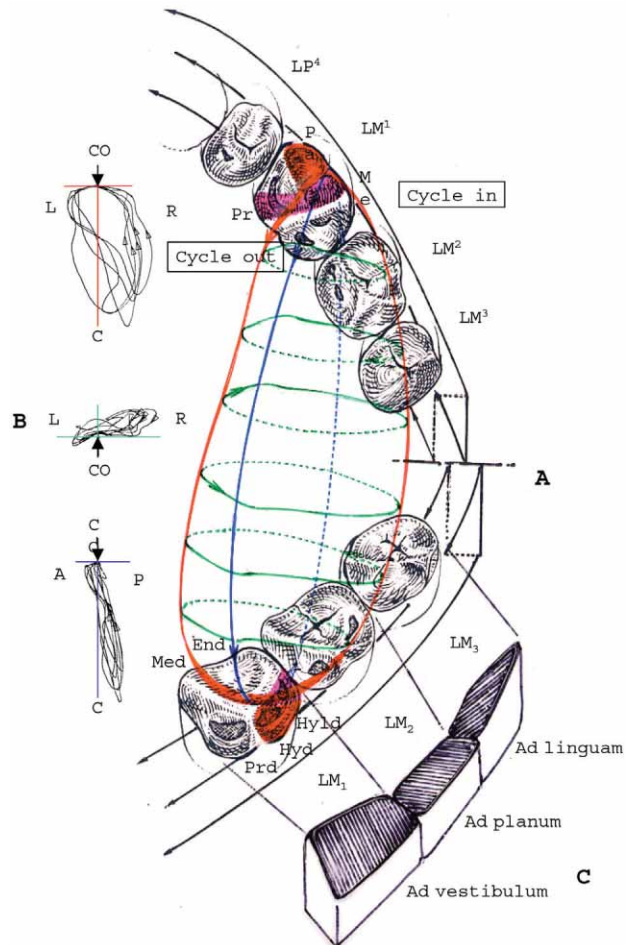


Fig. 4. Proposed envelope of the left lower first molar (LM₁) possible displacements during ipsilateral chewing cycle simulation (Sao Skull). A. – Left hemi-arches part are shown buccally and mesially. Both hemi-arches are related by a 3D representation of possible border and chewing movements of the left lower first molar central fossa. This was inferred from chewing movements recorded by Gibbs and al. (1981) in the case of extensive first molar tooth wear. B. – On the left of the drawing, superimposed cycles of left chewing in a frontal view (top figure), occlusal view (middle figure), lateral view (bottom figure) (redrawn, but not to the same scale, from Gibbs and al. 1981). At the end of the inward chewing cycle part (cycle in) the hypoconid of the left lower first molar (LM₁) contacts the paracone of the left upper first molar (LM¹) and then glides along its mesial slope to reach the centric occlusion. At the same time the hypoconulid glides against the mesial slope of the metacone and the protocone. The hypoconid and the hypoconulid play a pestle-like role by enlarging the opposed trigon fossa into a mortar-like shape. In the same manner the talonid takes the shape of an enlarged cup towards the metaconid. During the chewing 'cycle in', the LM¹ protocone glides in a guided movement on either side of the LM₁ enamel ridge so as to facilitate the mandible non-working excursion with no occlusal interference³⁹. At the end of the outward chewing cycle part (cycle out) the protocone glides along the central slopes of the hypoconid and the hypoconulid. C. – The three lower molars are represented in a schematic drawing indicating the disposition of their occlusal table as a result of abrasion. L – left, R – right, A – anterior, P – posterior, C – canal, CO – centric occlusion.

1–2 tooth relation as M_2 was also in contact with M^1 . The distal occlusal margin of the M^3 metacone, in the shape of a salient ridge, constituted a real distal stopper as it prevented any backward movement of the mandible starting from the centric occlusion. This stopping that could be clearly observed lingually (Figure 1) was completed mesially by a contact between the distal face of the M_3 metaconid internal slope and the M^3 protocone. M^3 came into contact with M_3 in a pestle-mortar 1-1 tooth relation. On the samples studied, the wear surfaces could be observed on either side of the M^1 oblique ridge between trigon and hypocone. So in the chewing cycle occlusal phase, in dental class I, the hypoconid glided along the enamel ridge slope of the antagonistic molar as down a toboggan (Figures 3 and 4), resulting in a wear process affecting the central fossa and contributing to the widening of the occlusal mortar inner walls.

Arch anterior relations

The examination of wear on maxillary incisor edges revealed that there were functional contacts with the mandibular incisors. The anterior interarch relation was estimated more labiodental than psalidodental, prior to the loss of the mandible incisors. The important distolingual wear facet of LI^2 is the result of the contact with the distal part of LC^1 in a 1-1 relation. There were diastemata between I^1 and I^2 and between I^2 and I^3 . The loss of the mandibular incisors increased the mesial drift and led to a slight labial inclination of the mandibular canines. A space appeared between C_1 and P_3 . On the left and on the right, P_3 came into contact with C^1 and P^3 in a 1–2 intercusp relation.

Intermolar measurements

The distances between the central fossae of M_1 and M_3 measured first on the right and then on the left were respectively 20.41 mm and 20.10 mm on the maxilla, 20.12 mm and 20.11 mm on the mandible.

Discussion

The moulding process and the replicas

The mandible and the broken maxilla of the Sao skull were reconstructed. Two teeth, LI^2 and LC^1 , were reset in their sockets. This reconstruction could have induced a slight, even minute, shift in the occlusion of some sections. Therefore, a stable interarch relation was difficult to obtain. So the centric occlusion was observed on fragmented replicas. It could be done directly in face or from high and low angles. Stability was examined in the contact between 2 or 3 individual teeth.

The occlusal plane

In ancient populations, attrition can alter the angle of the occlusal dental plane. On the Sao skull, supporting cusps (buccal on the mandible and lingual on the maxilla) got worn first, contributing to the progressive

modification of cusp slope inclination. Thus this attrition process initiated on M_1 modified the helicoid occlusal plane from an *ad linguam* slant to an *ad vestibulum* one. The occlusal surface of M_3 kept its *ad linguam* slant while the M_2 plane kept an intermediate slant. Had the absence of anterior guidance (labiodental tendency) due to incisor loss increased the helicoid aspect of the posterior occlusal plane? Prior to this tooth-loss, wear affected all the teeth, and a premolar and molar function group of disclusion ensued, as had already been noted by Beyron on Australian Aborigines²⁷. The Wilson curve, observed in a frontal view at first molar mandibular level is normally concave upwards at the age of six. Then it becomes concave downwards due to *ad vestibulum* wear as noted in the Sao's first molars. Sagittally, part of the Von Spee curve is constituted by the bucco-occlusal margins of premolar and molar occlusal planes. This often noted disposition was very slightly marked here, the third molar proclination being the only evidence of a Von Spee Curve. Finally, what was the repercussion of third molar late eruption on wear progress on the other teeth and on the evolution of the Von Spee curve? This curve was little marked in the Sao fossil and because of strong attrition it seemed to be preserved only thanks to the presence of the third molars. Some authors have underlined the role played by the third molar in relation to the Von Spee curve²⁸. Their study on prehistoric populations failed to conclude that the Von Spee Curve was preserved when wear increased. According to them there was no definite link between Von Spee Curve and dental attrition.

Occlusal confrontation

FDI Classification, more precise than Angle classification, was a simple measure to analyse anterior-posterior molar relations. Angle Classification was kept for the anterior section. The interarch contacting zone can be compared to an arthrody. According to Deshayes in the primal equilibrium²⁹, dental class I is more frequent in European populations. In this case the tip of the paracone is situated between the protoconid and the hypoconid, right in front of the lower first molar (M_1) buccal groove separating the two cusps. In classes II and III, an anterior and posterior half-cusp displacement of the maxillary molar is noted in respect to the lower molar. In the the Sao skull, with an Angle Molar Class 1 relation, the M_1 hypoconid glides against the oblique ridge of the antagonistic molar (metacone and then protocone) during the occlusal phase of the chewing cycle. The first upper molar occlusal mesial fossa has widened, due to wear, into a mortar shape. This process, which corresponded to a slight mandibular pro-gliding (forward gliding) movement, »M« position in FDI classification, was then reproduced on the other molars as they came into contact with the opposite arch. The helicoid and dissymmetrical arrangement of each hemi-arch occlusal surface increases through attrition. In this disposition, during chewing eccentric movements, an »interarch clearance«^{17–24} appears at premolar-molar level, indicative

of a flatter chewing cycle. As the occlusal anatomy of each tooth flattens with unequal tooth attrition³⁰ the occlusal table widens. But this helicoid curve is not found in some populations^{17,31–33}. Campbell observed that some individuals in a population display such an arrangement whereas others do not³¹. For Tobias²¹, the preceding observation is a significant element of differentiation in *Australopithecus* and *Homo habilis*. He explains that the type of wear depends on the differential width of both dental arches and on both lateral excursions (right and left) of the mandible.

Tooth migrations

Concerning the Sao skull there is strong belief that the four incisors were extracted. This ritual mutilation would have had some repercussions on the position of the teeth on each side of the toothless crest. Diastemata would have appeared between all the remaining lower and upper front teeth. The left mandibular canine tip was a little above the general occlusal plane (Figure 1). The forward tipping of its crown and the natural mesial drift favoured its egression which was not prevented by contact with the antagonistic lateral incisor. This had already been observed in the case of tribal mutilations³⁴. However the arch occlusal and general balance would be a little disturbed by the loss of the mandibular incisors. Posterior intra-arch interdental contacts and arch continuity had been preserved. We can surmise that the loss of anterior contact had loosened approximal contacts and lessened the corresponding proximal wear. The distance between the central fossae of the first and third molars, which was the same right and left, might support this assumption. The canines had thus become, by their progressive extrusion, the sole guiding anterior elements for the mandible displacement with interarch contacts are maintained. In these circumstances the role of the labret should not be underestimated. Was it a permanent ornament? Important wear seems to suggest so. In that case it would have played the role of a space retainer limiting the mesial migration of the canines and favouring the stability of the posterior sections. If so, what is the meaning of the very slight mesial rotation of the first lower premolar (P₃) buccal surfaces? This feature had already been observed in *A. afar-ensis*³⁵. Should it be regarded as a discrete dental trait? In other words, is the mesial rotation of the P₃ buccal aspect due to mesial tipping of the mesial tooth (canine), or is it a frequently encountered disposition?

Mandible displacement with interarch contacts

After the observations on mammals³⁶, on primates³⁷ and on man³⁸, Woda³⁹ stated that simplistic and mechanistic old theories describing interarch guiding relations with mandible performing excentric displacement should be abandoned. They should be replaced by more functional and natural guiding contacts performed in a centripetal direction. The concept of mutual protection between front and back teeth was developed in the past by a few Odontologists^{40,41}. From the dental wear point of

view, they applied it to a contemporary population but not to ancient adult populations. The concept was not in keeping with the type of occlusal relations as observed on the Sao skull. Each occlusal surface is but a stage, a photograph, in the course of the biological evolution of kinematic and dynamic relations as reflected by the wear on dental crowns. As no correlation between the amount of occlusal wear and the location of contact points in the lateral excursions of the mandible is found in another study⁴², a great variety of occlusal arrangements are beyond classification⁴³. But whether in canine disclusion or group function on the chewing side⁴⁴, contacts always appeared at first molar level in lateral excursions⁴⁵. All the research in this domain confirmed the existence of frequent interarch dental contacts during chewing both on the working and non-working aspects^{43,46,47}. So the occlusal surface of the maxillary molars would provide a guiding base for two oblique excursions: one forwards and inwards and the other forwards and outwards, in that order, or in the reverse order⁴⁸. The direction of the oblique outward excursion was roughly parallel to the transverse oblique ridge that unites the trigon and the hypocone of the first maxillary molar. It is also the direction of the distal buccal groove between the hypoconid and the hypoconulid of the first mandibular molar. A first upper molar firm rooting at maxillary level, added to a first lower molar denser bone structure at mandibular level, and combined to an optimal periodontal health, contributed to reduce the mesial drift of posterior teeth following the tribal extractions affecting anterior teeth. The mandible acts as the support for a series of genuine pestles making contact with a series of maxillary mortars. According to what is shown on contemporaneous individuals (with dental wear facets) the mandible movements were presumably that of an alternate right-left chewing that began at a very early age. Starting from the centric occlusion both ways in and out can take different directions, thus modifying the shape of the chewing cycle. Such dental relations indicate the end and the beginning of a chewing cycle which adapts to food texture through its shape, timing and force⁴⁹, and evolves with ageing⁵⁰ and number of teeth⁵¹. The chewing mode evolved with progressive tooth wear while maintaining balanced occlusal relations, and hence, according to Planas, adjusted the arches in a more functional shape⁵². In this theory the perfect symmetrical form of the mandibular arch distal parts is thought to favour mandible and maxilla balanced growth. The result is a balanced chewing function whose objective was to maintain the equilibrium of the stomatognathic system. Nevertheless, in the Sao skull, the lower canine extrusion seems to have constrained the mandible in a more vertical range of movements³⁸, but wear facets remained as a sign of a past behaviour.

Conclusion

The interarch relations in a nearly complete Sao dentition were studied by comparative observation of

the original samples and their plaster replicas. Dividing the replicas into sections (anterior teeth, canine, post-canine teeth) made the research on occlusion easier. Macrophotography provided additional elements to confirm the information collected through the mere observation and manual confrontation of the replicas. All the various observations and their cross-checking allowed a closer assessment of interarch relations so as to represent, through drawings, the occlusal confrontation in an occlusal view and to propose a 3D representation. The study of the cuspal excursions and the proposed schematic envelope rely on the clinician's knowledge and on his responsibility in the field of manducation. Even if ritual extractions and a slight anterior-lateral guidance (labiodental tendency with the sole presence of the canines) restrained the mandible lateral excursion, they did not modify the balance noted in the posterior sec-

tions. This was revealed by – 1 – the first molar wear pattern – 2 – the regular arch shape which showed symmetrical occlusal characteristics on both sides (Angle and FDI Classifications, Von Spee Curve, Wilson Curve, measurements recorded at molar level). It was the result of an alternate bilateral chewing that favoured mandibular and consequently maxillary alveolar growth, in a harmonious oro-facial environment.

Acknowledgements

This work is a part of the Sao skull study directed by Pr. Michel Sakka, M.D., Ph.D., anatomist. We are grateful for his comments, criticism and his practical help along this research. Thanks are also due to Dr. Pierre Bourdiol, orthodontist.

REFERENCES

1. SAKKA, M., *Mammalia*, 37 (1973) 478. — 2. SAKKA, M., C. R. Acad. Sci. Paris, 277 (1973) 865. — 3. SAKKA, M.: Anatomie comparée et fonctionnelle de l'ensemble anatomique de la nuque et de la voûte du crâne chez les Hominidés et les Pongidés. Ph.D. Thesis. In French. (University of Paris VII, Paris, 1974). — 4. SAKKA, M., *Mammalia*, 41 (1977) 85. — 5. SAKKA, M., *Bull. Mém. Soc. Anthropol. Paris*, 10 (1983) 285. — 6. SAKKA, M., *Morphologie évolutive, morphogenèse du crâne et Origine de l'Homme*. In: *Proceedings. (Table Ronde Internationale du 24 au 27 juin 1980 sous la direction de M. Sakka, CNRS, Paris, 1983)*. — 7. SAKKA, M., *Cranial Morphology and Masticatory Adaptations*. In: CHIVERS, D. J., B. A. WOOD, A. BILSBOROUGH (Eds.): *Food Acquisition and Processing in Primates*. (Plenum Press, New York, 1984) — 8. SAKKA, M., *Morphologie évolutive de la tête et du cou chez l'Homme et les grands Singes. Application aux hominidés fossiles*. In: *Ensembles anatomiques cervicaux. Cah. de Paléanthropol.* (CNRS, Paris, 1985). — 9. SAKKA, M., *Réflexions sur la définition de l'Homme et sur l'anthropologie*. In: SAKKA, M. (Ed.): *Définition et origines de l'Homme. Morphogenèse du crâne et anthropogenèse. (Table Ronde internationale du 5 au 8 juillet 1983 sous la direction de M. Sakka, CNRS, Paris, 1987)*. — 10. SAKKA, M., *Les Origines de l'Homme. Un autre regard*. (Messidor, Paris, 1991). — 11. HADJOUIS, D.: *Les populations médiévales du Val-de-Marne. Dysharmonies crânio-faciales, maladies bucco-dentaires et anomalies du développement dentaire au cours du Moyen-Age*. (Edit. Artcom', Paris, 1999). — 12. HADJOUIS, D., *Act. Odont. Stomat.*, 213 (2001) 35. — 13. HADJOUIS, D., *Dossiers d'Archéologie*, 282 (2003) 38. — 14. VIGNAL, J. N.: *Les reconstitutions faciales assistées par ordinateur*. (Edit. Artcom', Paris, 1999). — 15. ANGLE, *Dental Cosmos*, (1899) 350. — 16. BAUME, L. J., H. S. HOROWITZ, C. J. SUMMERS, O. BACKER DIRKS, W. A. B. BROWN, J. P. CARLOS, L. K. COHEN, T. J. FREER, E. P. HARVOLD, C. F. A. MOORREES, J. A. SALZMANN, G. SCHMUTH, B. SOLOW, H. TAATZ, *Int. Dent. J.*, 23 (1973) 530. — 17. ACKERMANN, F., *Int. Dent. J.*, 13 (1963) 532. — 18. TAYLOR, R. M. S., *Acta. Anat.*, 53 (1963) 97. — 19. GASPARD, M., *Act. Odont. Stomat.*, 69 (1965) 85. — 20. HALL, R. L., *Am. J. Phys. Anthropol.*, 45 (1976) 69. — 21. TOBIAS, P. V., *Am. J. Phys. Anthropol.*, 57 (1980) 173. — 22. OGAWA, T., T. OGIMOTO, K. KOYANO, *J. Prosth. Dent.*, 80 (1998) 67. — 23. SMITH, B. H., *Am. J. Phys. Anthropol.*, 63 (1984) 39. — 24. GASPARD, M.: *L'appareil manducateur et la mandibule. Première partie : Anatomie descriptive, Onto-*

genèse et phylogenèse de la mandibule humaine. Premier volume. (Prelat, Paris, 1978) — 25. MILLS, J. R. E., *The Dental Practitioner*, 6 (1955) 47. — 26. MILLS, J. R. E., *Proc. R. Soc. Med.*, 65 (1972) 392. — 27. BEYRON, H., *Acta. Odontol. Scand.*, 6 (1964) 598. — 28. SENGUPTA, A., D. K. WITTAKER, G. BARBER, J. ROGERS, J. H. MUSGRAVE, *Archs. Oral. Biol.*, 44 (1999) 925. — 29. DESHAYES, M. J., *L'identité humaine en question. Nouvelles problématiques et nouvelles technologies en paléontologie humaine et en paléanthropologie biologique. Actes du Colloque organisé par le Conseil Général du Val-de-Marne et l'Association pour la recherche et la publication d'études archéologiques du Val-de-Marne. Session IV : orthodontie, croissance crânio-faciale, odontologie. Discussion.* (Editions Artcom', Paris, 2000). — 30. HILLSON, S.: *Dental Anthropology*. (Cambridge University Press, Cambridge, 1996). — 31. CAMPBELL, T. D.: *Dentition and palate of the Australian aboriginal*. (The Hassell Press, Univ. of Adelaide, 1925). — 32. MURPHY, T. R., *Brit. Dent. J.*, 116 (1964) 483. — 33. MURPHY, T. R., *Arch. Oral. Biol.*, 9 (1964) 269. — 34. CAILLARD, P., *Bull. Mém. Soc. Anthropol. Paris*, 5 (1978) 261. — 35. LEONARD, W. R., M. HEGMON, *Am. J. Phys. Anthropol.*, 73 (1987) 41. — 36. MILLS, J. R. E., *Arch. Oral. Biol.*, 12 (1967) 645. — 37. KAY, R. F., K. M. HIEEMAE, *Am. J. Phys. Anthropol.*, 40 (1974) 227. — 38. GIBBS, C. H., H. C. LUNDEEN, P. E. MAHAN, J. FUJIMOTO, *J. Prosth. Dent.*, 46, 3 (1981) 308. — 39. WODA, A., *L'Orthodontie française*, 57 (1986) 501. — 40. SCHUYLER, C. H., *N. Y. Dent. J.*, 13 (1947) 445. — 41. D'AMICO, A., *J. South. Calif. Dent. Assoc.*, 26 (1958) 239. — 42. JOHANSSON, A., K. FAREED, R. OMAR, *J. Prosth. Dent.*, 71 (1994) 159. — 43. OGAWA, T., T. OGIMOTO, K. KOYANO, *J. Prosth. Dent.*, 80 (1998) 67. — 44. WODA, A., P. VIGNERON, D. KAY., *J. Prosth. Dent.*, 42 (1979) 335. — 45. CHRISTENSEN, L. V., D. C. MCKAY, *J. Craniomand. Pract.*, 15 (1997) 10. — 46. HOCHMAN, N., A. EHRlich, A. YAFFEY, *J. Oral. Rehab.*, 22 (1995) 221. — 47. BOURDIOL, P. L. MIOCHE, *Arch. Oral. Biol.*, 45 (2000) 691. — 48. RAJAONA, Z. J., A. WODA, M. LEJEUNE, *J. Biol. Buc.*, 15 (1987) 153. — 49. PEYRON, A., C. LASSAUZAY, A. WODA, *Exp. Brain Research*, 142 (2002) 41. — 50. BLANC, O., A. WODA, M. A. PEYRON, *Les cahiers de l'ADF*, 6 (2003) 44. — 51. VINTER, I., J. KRMPOTČ-NEMANIĆ, D. IVANKOVIĆ, D. JALSOVEC, *Coll. Antropol.*, 20 (1996) 555. — 52. PLANAS, P.: *La réhabilitation neuro-occlusale*. (Masson, Paris, 1992).

S. Santoni

Department of Anatomy, Faculty of Medicine University of Auvergne, 28 place Henri Dunant, 63000 Clermont-Ferrand, France
e-mail: sylvain.santoni@wanadoo.fr

ODNOSI ZUBNOG LUKA LUBANJE IZ 14. STOLJEĆA IZ PLEMENA SAO, KAMERUN

S A Ž E T A K

Dentalni okluzalni odnosi rijetko se istražuju u antropologiji. Obrada replika poluluka kao i prekrivanje na osnovu fotografija pospješili su opise intra- i interlučnih odnosa. U horizontalnoj, frontalnoj i sagitalnoj ravnini procijenjena je okluzalna međulučna konfrontacija i intermolarni odnos, a neka mjerenja pomogla su funkcionalnom istraživanju. Na temelju znanja o kinematici donje čeljusti predložen je ovoj pokreta prvog kutnjaka za vrijeme žvakanja. Proučavana denticija bila je vrlo pravilna. Bio je to dobar primjer uravnotežene istrošenosti na zubima u prostoru iza očnjaka. Unatoč ekstruziji donjih očnjaka, zbog plemenskih osakaćivanja prednjih zubi međulučni odnosi nisu se promijenili.