

Septic Arthritis due to *Streptococcus sanguis*

Inga Mandac^{1,3}, Ingrid Prkačin^{1,2}, Mirjana Sabljar Matovinović^{1,2} and Dunja Šušterčić¹

¹ »Merkur« University Hospital, Zagreb, Croatia

² Zagreb University, School of Medicine, Zagreb, Croatia

³ University of Applied Health Studies, Zagreb, Croatia

ABSTRACT

Septic arthritis may represent a direct invasion of joint space by various microorganisms, including bacteria, viruses and fungi. Although any infectious agent may cause bacterial arthritis, bacterial pathogens are the most significant because of their rapidly destructive nature. We present a case of septic arthritis in a 56-year old male patient due to *Streptococcus viridans* which is member of the viridans group streptococci. Patient was admitted to Our Hospital presented as fever of unknown origin, losing more than 30 kg of body weight during couple of months, and anemia of chronic disease as paraneoplastic process. He had long history of arterial hypertension and stroke. There was swelling and pain of the right sternoclavicular joint and precordial systolic murmur in physical status. A large diagnostic panel has been made, computerized tomography (CT) of right sternoclavicular joint showed widening of periarticular soft tissue and loss of clavicular corticalis. Cytologic analysis of synovial fluid showed more than 90% of polymorphonuclear leukocytes. There were no crystals on microscopic examination and Gram stain of fluid was negative. Blood cultures were positive for *S. sanguis* and there was a consideration about possible periodontal disease. Stomatologic examination verified periapical osteitis and extraction of potential cause of infection has been done. Therapy with benzilpenicilline was followed by the gradual improvement of clinical and laboratory parameters. Although viridans group streptococci and *Streptococcus sanguis* in particular are rare causes of septic arthritis in native joints, they should be considered in the differential diagnosis of periodontal disease.

Key words: septic arthritis, bacterial arthritis, *Streptococcus sanguis*, periodontal disease

Introduction

Septic arthritis, also known as infectious arthritis, may represent a direct invasion of joint space by various microorganisms, including bacteria, viruses, mycobacteria, and fungi. Reactive arthritis, a sterile inflammatory process, may be the consequence of an infectious process located elsewhere in the body. Although any infectious agent may cause arthritis, bacterial pathogens are the most significant because of their rapidly destructive nature. Failure to recognize and to appropriately treat septic arthritis results in significant rates of morbidity and may even lead to death. The 2 major classes of bacterial/suppurative arthritis are gonococcal and nongonococcal. Overall, although *Neisseria gonorrhoeae* remains the most common pathogen (75% of cases) among younger sexually active individuals, *Staphylococcus aureus* infection is the cause of the vast majority of cases of acute bacterial arthritis in adults and in children older

than 2 years. This pathogen is the cause in 80% of infected joints affected by rheumatoid arthritis.

Streptococcal species, such as *Streptococcus viridans*, *Streptococcus pneumoniae*, and group B streptococci, account for 20% of cases. Septic arthritis of the sternoclavicular joint occurring secondary to a pneumococcal chest infection was first described by Vogelieus in 1896. In 1988, Wohlgethan et al performed a comprehensive review of the literature and described 65 cases of sternoclavicular joint infection. They found that abscesses were present in 20% of these cases, irrespective of the type of organism or underlying systemic disease; in almost all cases, the abscess was unilateral¹. Sternoclavicular joint infection (SCJ) occurs in patients with predisposing risk factors, as intravenous drug use, hemodialysis, infected central venous line, diabetes mellitus and rheumatoid or

other inflammatory arthritis. Other reported risk factors are alcohol abuse, corticosteroid treatment, cancer, trauma, radiation therapy, chronic liver disease, surgery with median sternotomy. Most common noncontiguous foci of infection are pneumonia, cellulitis, endocarditis, urosepsis, septic pulmonary emboli, spontaneous bacterial peritonitis, epidural abscess, intra-abdominal abscess, gingivitis and disseminated tuberculosis. SCJ infection is a potentially life-threatening condition because of tight anatomic connection with the most important chest vascular structures. Very rarely SCJ infection occurs in previously healthy adults².

In this article, we present a case of septic arthritis caused by *Streptococcus sanguis* in a 56-years old male patient.

Case report

A 56-year old male patient was admitted to our Hospital presented as fever of unknown origin, he lost more than 30 kg of body weight in less than 6 months and laboratory examination showed anemia of chronic disease as paraneoplastic process. He had long history of arterial hypertension and stroke. On physical examination there was swelling and pain of the right sternoclavicular joint and precordial systolic murmur. In the initial laboratory evaluation, his hemoglobin concentration was lower, there was leukocytosis with neutrophilic predominance and erythrocyte sedimentation rate was elevated. A large diagnostic panel has been made in searching for the loci of infection. A chest X-ray was normal, echocardiogram did not detect any vegetation on the cardiac valves. Examination of abdomen, CNS, bone marrow, immunology parameters, tumor markers, showed no abnormality.

Computerized tomography (CT) of the right sternoclavicular joint showed widening of periarticular soft tissue and loss of clavicular corticalis. Synovial fluid was collected by syringe and its analysis demonstrated mixed viscosity and yellow colour, opaque clarity and more than 100 000 WBC/mm³. Cytologic analysis of synovial fluid showed more than 90% of polymorphonuclear leukocytes (Figure 1 and 2). There were no crystals on microscopic

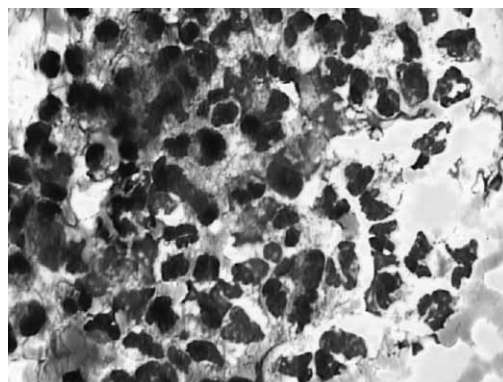


Fig. 2. Degenerative polymorphonuclear leukocytes in synovial fluid – May-Grünwald-Giemsa, x1000.

examination and Gram stain of fluid was negative. Blood cultures were positive for *S. sanguis* and because of positive cytologic evaluation of synovial fluid, there was a consideration about possible periodontal disease. Stomatologic examination verified periapical osteitis and extraction of potential cause of infection has been done. Therapy with benzilpenicilline was followed by the gradual improvement of clinical and laboratory parameters.

Although viridans group streptococci and *S. sanguis* in particular are rare causes of septic arthritis in native joints, they should be considered in the differential diagnosis of periodontal disease. A reasonable amount of aspirated synovial fluid is the best argument in favour of an objective articular disorder. In our case, such a simple evaluation (differential cell count analysis) was very helpful in making a diagnosis.

Discussion

Streptococcal septic arthritis accounts for 15–30% of all nongonococcal causes of bacterial arthritis in adults³. *S. viridans* has a low virulence, and infection by this microorganism usually appears on previously injured focus, even though its association with dental carries and bacterial endocarditis has been well established. *S. sanguis*,

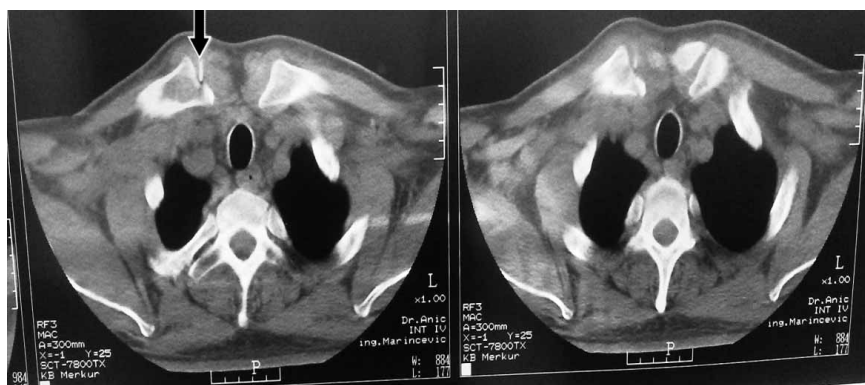


Fig. 1. CT scan of sternoclavicular joints shows a needle in the right sternoclavicular joint while taking sample of synovial fluid for cytologic analysis.

a member of the viridans group of streptococci, is a well known commensal of the mouth, upper respiratory tract, lower intestinal tract, genitourinary tract and skin of healthy humans^{4,5}. Clinical diagnosis requires a high index of suspicion since symptoms in the region of the SCJ can be confused with various rheumatic disorders, osteoarthritis, hyperostosis, Tietze's syndrome, abscess, or tumor. Infection can present with localized swelling with or without tenderness or decreased range of motion. A concise diagnosis is important since management differs depending on the cause. Laboratory studies usually are not helpful since an elevated white blood cell count or sedimentation rate is nonspecific, and blood cultures are frequently negative. When possible, aspiration of the joint for Gram stain and culture and cytologic analysis can be helpful in confirming the diagnosis and direct antibiotic treatment. Unfortunately, the failure rate with this method is high due to technical difficulty in aspiration of the small joint space. Unusual organisms such as tuberculosis or fungi in an appropriate host also should be considered^{6–8}.

Cytologic evaluations have to include both bacterial and synovial fluid analysis and search for microcrystals. Paucicellular (<1000 cells/mm³) synovial fluid is observed in different »mechanical« disorders. In the case of purulent synovial fluid the primary diagnosis is septic arthritis. However, the most common etiology is probably

crystal-induced acute arthritis. Differential cell count analysis performed in case of »inflammatory« (>1000 or 2000 cells/mm³) synovial fluid usually shows a predominance of polymorphonuclear cells. However, high cellularity may sometimes be associated with a predominance of other cells, i.e. lymphocytes, monocytes, eosinophils¹². There are few reports of septic arthritis due to *S. sanguis*. Nietzsche et al. described a young man with polymicrobial infection of the sternoclavicular joint due to *S. sanguis* and *Pasteurella multocida*⁹. Patrick and Lewis described a previously healthy 56-years old man with obvious dental carries who had septic arthritis of the knee due to *S. sanguis*¹⁰. Edson et al. reported a 66-year old man who developed septic arthritis of the knee due to *S. sanguis* after he had been treated for severe periodontal disease, which contributed to hematogenous spread¹¹. Papaioannides et al. presented a case of septic arthritis of the right knee due to *S. sanguis* in a 73-year old woman after she had been treated for severe periodontal disease⁴. Although viridans group streptococci in general and *S. sanguis* in particular, are rare causes of septic arthritis in native joints, they should be considered in the differential diagnosis of this disorder, especially in the setting of severe periodontal disease and dental caries. Cytologic analysis of synovial fluid may be a helpful diagnostic method especially if laboratory tests and blood cultures are nonspecific.

REFERENCES

1. MOHYUDDIN A, Ear Nose Throat J, 82 (2003) 618. — 2. GALLUCCI F, ESPOSITO P, CARNOVALE A, MADRID E, RUSSO R, UOMO G, Adv Med Sci, 52 (2007) 125. — 3. PETERS RH, RASKER JJ, JACOBS JW, PREVO RL, KARTHAUS RP, Clin Rheumatol, 11 (1992) 351. — 4. PAPAIOANNIDES D, BONIATSI L, KORANTZOPOULOS P, SINAPIDIS D, GIOTIS C, Med Princ Pract, 15 (2006) 77. — 5. JOHNSON CC, TUNKEL AR, Viridans streptococci, groups C and G streptococci. In: MANDELL, DOUGLAS AND BENETT (Eds) Principles and Practice of Infectious Disease (Philadelphia, 2005). — 6. YASUDA T, TAMURA K, FUJIWARA M, J, Bone Joint Surg Am, 77 (1995) 136. — 7. BEUTLER SM, BAYER AS, Drug Ther Hosp Ed, 7 (1982) 101. — 8. POTHULA V, MORRISON NG, MARTINEZ A, Infect Med, 67 (1991) 16. — 9. NITSCHE JF, VAUGHAN JH, WILLIAMS G, CURD JG, Arthritis Rheum, 25 (1982) 467. — 10. PATRICK MR, LEWIS D, Br J Rheum, 31 (1992) 569. — 11. EDSON RS, OSMON DR, BERRY DJ, Mayo Clin Proc, 77 (2002) 709. — 12. DOUGADOS M, Baillieres Clin Rheumatol, 10 (1996) 519.

I. Mandac

»Mercur« University Hospital, Zajčeva 19, 10000 Zagreb, Croatia
e-mail: imandac@yahoo.com

SEPTIČKI ARTRITIS UZROKOVAN *STREPTOCOCCUS SANGUISOM*

SAŽETAK

Septički artritis može nastati nakon izravnog ulaska različitih mikroorganizama (bakterija, virusa, gljiva) u zglobni prostor. Bilo koji uzročnik infekcije može dovesti do bakterijskog artritisa, ali bakterijski patogeni su najznačajniji jer dovode do brzog uništenja zgloba. U radu prikazujemo slučaj 56-godišnjeg bolesnika sa septičkim artritismom uzrokovanim sa *Streptococcus viridansom* koji pripada viridans grupi streptokoka. Primljen je u bolnicu pod kliničkom slikom febriliteta nepoznate etiologije, a u anamnezi se isticao podatak o gubitku više od 30 kg tjelesne težine unazad nekoliko mjeseci i anemija kronične bolesti ili u sklopu paraneoplastičnog procesa. Duži niz godina se liječio od arterijske hipertenzije, a prebolio je i cerebrovaskularni inzulit. U fizikalnom statusu nađena je otekline i bol desnog sternoklavikularnog zgloba te sistolički šum prekordijalno. Učinjena je opsežna dijagnostička obrada. Kompjuterizirana tomografija

desnog sternoklavikularnog zgloba pokazala je proširenje periartikularnog mekog tkiva i gubitak kortikalisa klavikule. Citološka analiza sinovijalne tekućine našla je više od 90% polimorfonuklearnih leukocita. Mikrobiološkom analizom sinovijalne tekućine nije nađeno izolata. Hemokulture su bile pozitivne na *S. sanguis* radi čega se posumnjalo na moguću infekciju zubnog tkiva. Stomatološkom obradom nađe se periapikalni ostitis te je učinjena ekstrakcija žarišta. Započeta je terapija benzilpenicilinom što je dovelo do postupnog poboljšanja kliničkih i laboratorijskih parametara. Iako su viridans streptokoki i *S. sanguis* rijetki uzročnici septičkog artritisa, potrebno ih je uzeti u obzir ukoliko postoji i periodontalna infekcija.