

Rectal Metastasis from Lobular Carcinoma of the Breast: A Case Report

Melita Perić Balja¹, Danko Velemir Vrdoljak², Mladen Stanec², Sanda Šitić¹, Dubravka Krleža Supić³ and Fabijan Knežević¹

¹ Department of Pathology, University Hospital for Tumors, Zagreb, Croatia

² Department of Surgery, University Hospital for Tumors, Zagreb, Croatia

³ Department of Anesthesiology and Resuscitation, University Hospital for Tumors, Zagreb, Croatia

ABSTRACT

Rectal metastases from breast carcinomas are very rare. They often occur in lobular invasive breast carcinoma (ILC), usually after a long disease-free period. It is important to be aware of these unusual metastatic patterns of ILC of the breast because of the possibility of systemic therapy. We present a case of 83-year old woman with rectal metastasis from ILC seven years after surgery of primary tumor.

Key words: breast carcinoma, lobular, rectal metastasis

Introduction

Breast cancer is the most frequent malignancy in the female population. According to the data from Croatian National Cancer Registry breast cancer incidence is 95.7/100 000, and accounts for 24% of all cancers among women¹.

Breast carcinoma usually metastasizes to lymph nodes, lung, bone, liver or brain, and rarely to gastrointestinal tract (GI)². The most frequent organ involved in GI tract is the stomach, followed by small intestine^{3–14}, while colonic and rectal metastases are extremely rare^{15–22}. Recognition of rectal metastases is important because they could easily be misdiagnosed as primary rectal adenocarcinoma due to clinical presentation. It is also very important to diagnose it properly because of the therapy.

We present a case of an 83-year old woman with metastatic lobular breast carcinoma to the rectum presenting with obstruction. The breast tumour was diagnosed 7 years prior to the presentation of rectal metastasis.

Case Report

An 83-year old blind woman had undergone left modified radical mastectomy and axillary lymph node dissection in June 2002 due to breast carcinoma. Histopatho-

logical examination revealed a 2 cm infiltrating lobular carcinoma of histological grade 2, with 9 from 12 resected axillary lymph nodes infiltrated by tumour cells (pT1N2). All 4 interpectoral Rotteri lymph nodes were also infiltrated. Immunohistochemical analysis of oestrogen receptor showed strong nuclear positivity (100%) and analysis of progesterone receptor revealed strong nuclear positivity (70%), while c-erbB2 was negative.

There was no evidence of distant metastasis at the time of diagnosis. The patient received postoperative radiotherapy and hormonal therapy (Nolvadex 20 mg daily for five years).

In October 2009 the patient was admitted to hospital because of absolute constipation for ten days. Digitorectal examination revealed hard thickening in more than 2/3 circumference of the rectum, with lumen stenosis. This was confirmed by gastrointestinal X-ray. Endoscopy was made and small biopsy was taken. Microscopically tumour was composed of single-file stands of infiltrating small tumour cells with relatively little nuclear polymorphism, loosely dispersed throughout lamina propria, with the presence of signet-ring cells. Dysplasia in adjacent colonic epithelium was absent (Figures 1 and 2). Tumour cells were positive for cytokeratin 7 and negative for cytokeratin 20 and E-cadherin. Immunohistoche-

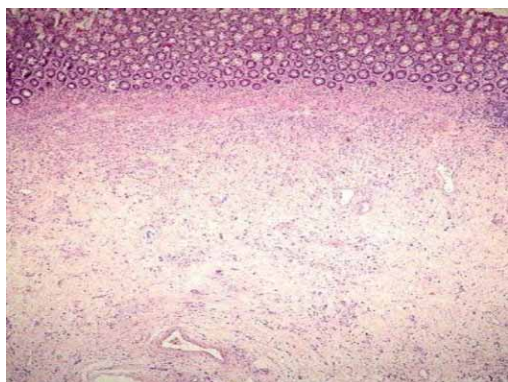


Fig 1. Tumor cells dispersed throughout lamina propria of colon (H&E, x40).

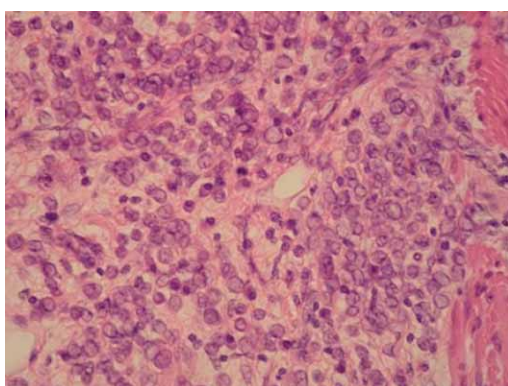


Fig 2. Microscopically tumor was composed of single-file stands of infiltrating small tumor cells with the presence of signet-ring cells (H&E, x400).

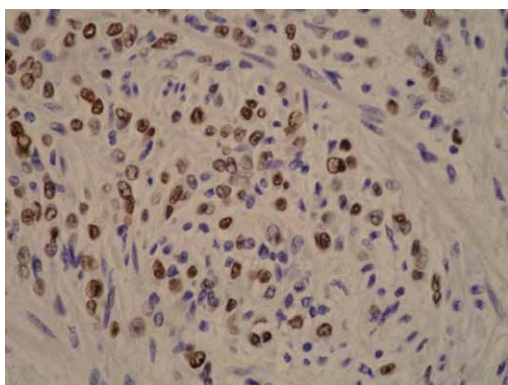


Fig 3. Immunohistochemically tumor cells were positive for oestrogen receptor protein (ER, x400).

mical staining was positive for oestrogen receptor protein (70%) (Figure 3) and negative for progesteron receptor protein as well as c-erbB2. Histological and immunohistochemical analysis of described tumor confirmed metastasis of lobular breast cancer.

Review of slides from primary tumour and additional immunohistochemical staining with E-cadherin (tumour

cells were negative) confirmed that primary tumour was invasive lobular carcinoma.

Because of clinical symptoms (constipation) anorectal amputation (Miles operation) was done. Macroscopic examination revealed rectal stenosis and slightly elevated, whitish, hard tumour on 4 cm from annocutaneous border, infiltrating the entire rectum, measuring 7x4 cm. Microscopically tumour was composed of single-file stands and little clusters of infiltrating small tumour cells with relatively little nuclear polymorphism, and with the presence of signet-ring cells. Adjacent colonic epithelium was without signs of dysplasia or atypia. Tumour cells infiltrated all layers of rectum extending into pericolic fat tissue. Four of ten lymph nodes from pericolic fat tissue were infiltrated by tumour cells.

No other site of disease was found by abdominal computed tomography, ultrasound and bone X-ray. The patient was released from the hospital 10th postoperative day as a disease free. Treatment with anastrozole was started three weeks after surgery. Six months after surgery patient is well, without any signs of disease.

Discussion

Gastrointestinal metastases of breast cancer are rare and usually associated with disseminated disease. Only exceptionally are first manifestations of the disease^{12,13}.

Metastases from breast cancer to the stomach and small intestine have been more frequently reported³⁻¹⁴ compared to colonic^{3,6,8,15,16,21,22} and rectal involvement^{17,18,22}. Metastases to the rectum are extremely rare. In a review of the literature, we only found two small series and a few case reports^{17,18,22}.

Although some necropsy studies have described an incidence rate of colon involvement that varies from 3% to 18% they are symptomatic in only 0.07% of cases¹⁵.

Clinical presentation of metastatic disease to the GI tract is diverse. Symptoms may be similar to that of primary GI malignancies¹⁷, as it happened in our case or non-specific.

The disease-free interval between primary breast cancer and gastrointestinal involvement is usually five to six years, although ten or more years have rarely been reported^{17,21}.

Infiltrating lobular carcinoma has a particular affinity for the gastrointestinal tract, with a metastasis rate of 4.5% vs. 0.2% from infiltrating ductal carcinoma (which involves oesophagus, stomach, small bowel, extra hepatic bile duct)¹⁹.

Clinical and histological features which help us to distinguish gastrointestinal breast versus primary colon cancer are: (1) absence of dysplasia in adjacent colonic epithelium suggests a metastatic growth; (2) tumour cells positivity for ER protein, cytokeratin 7, and negativity for cytokeratin 20 and E-cadherin; (3) history of breast cancer. Immunohistochemistry may be very useful in reaching the correct diagnosis. The most helpful immunohistochemical markers are gross cystic disease

fluid protein-15 (GCDFP-15), oestrogen (ER) and progesterone (PgR) receptors. Metastatic breast carcinomas are usually positive for GCDFP-15 and often for ER and/or PgR, in contrast to most colorectal or gastric carcinomas, which are negative^{23,24}. Positive immunohistochemical reaction for cytokeratin 7 and negative for E-cadherin is suggestive for metastatic lobular carcinoma.

Endoscopy should be performed in order to accurately detect the site of lesion. Sometimes biopsy obtained during endoscopy will not reveal malignant cells and second endoscopy is required. Repeated endoscopies may prevent unnecessary surgical procedures.

If we consider that gastrointestinal involvement is a sign of systemic disease, systemic therapy (chemotherapy, endocrine treatment or both) is usually employed. Surgery is usually necessary for an exact diagnose or for acute clinical manifestations.

REFERENCES

1. CROATIAN NATIONAL CANCER REGISTRY: Cancer incidence in Croatia 2006, Bulletin no 31, Zagreb, 2008 — 2. ROSEN, PP.: Rosen's breast pathology. (Lippincott Williams & Wilkins, Philadelphia, 2001). — 3. SCHWARTZ RE, KLIMSTRA DS, TURNBULL AD, Am J Gastroenterol, 93 (1998) 111. — 4. WASHINGTON K, McDONAGH D, Mod Pathol, 8 (1995) 427. — 5. TAAL BG, HARTOG JAGER FC, STEINMETZ R, PETERSE H, Gastrointest Endosc, 38 (1992) 130. — 6. NAZARENO J, TAVES D, PREIKSAITIS HG, World J Gastroenterol, 12 (2006) 6219. — 7. NIHON-YANAGI Y, PARK Y, OOSHIRO M, AOKI H, SUZUKI Y, HIRUTA N, KAMEDA N, KATOH R, Breast Cancer, 16 (2009) 83. — 8. McLEMORE EC, POCKAJ BA, REYNOLDS C, GRAY RJ, HERNANDEZ JL, GRANT CS, DONOHUE JH, Annals of Surgical Oncology, 12 (2004) 886. — 9. JONES GE, STRAUSS DC, FORSHAW MJ, DEERE H, MAHEDEVA U, MASON RC, World Journal of Surgical Oncology, 5 (2007) 75. — 10. AURELLO P, D'ANGELO F, COSENZA G, PETROCCA S, STOPPACCIARO A, RAMACCIATO G, ZIPARO V, Am Surg, 72 (2006), 456. — 11. CASCINU S, LUZI FEDELI S, FEDELIA, CATALANO G, Tumori, 75 (1989) 150. — 12. CIULLA A, CASTRONOVO G, TOMASELLO G, MAIORANA AM, RUSSO L, DANIELE E, GENOVA G, World Journal of Surgical Oncology, 6 (2008) 78. — 13. SAVANIS G, SIMATOS

The decision-making process of whether to treat these patients surgically should be based on the clinical presentation and symptoms, the availability of chemotherapeutic options and a quality-of-life discussion²⁵.

Patients with rectal metastases commonly present having already developed stenosis and obstruction requiring urgent correction, like in our case.

Conclusion

Rectal metastases from breast carcinomas are very rare. Diagnosis is often difficult because of a prolonged disease-free interval before metastatic presentation. Nevertheless, in patients with lobular carcinoma this possibility should be suspected in the case of symptoms suggesting a rectal lesion.

G, TZAI DA O, TSIKKINIS C, AMMARI A, KAFASIS E, NISIOTIS A, J BUON, 11 (2006) 79. — 14. LOTTINI M, NERI A, VUOLO G, TESTA M, PERGOLA L, CINTORINO M, GUARNIERI A, Tumori, 88 (2002) 427. — 15. PUGLISI M, VARALDO E, ASSALINO M, ANSALDO G, TORRE G, BORGONOVO G, World J Gastroenterol, 15 (2009) 1388. — 16. HABERSTICH R, TUECH JJ, WILT M, RODIER JF, Tech Coloproctol, 9 (2005) 237. — 17. BAMIAS A, BALTAYIANNIS G, KAMINA S, FATOUROS M, LYMPEROPOULOS E, AGNANTI N, TSIANOS E, PAVLIDIS N, Annals of Oncology, 12 (2001) 715. — 18. CERVI G, VETTORETTO N, CERVI E, VILLANACCI V, GRIGOLATO P, GIULINI SM, Dis Colon Rectum, 44 (2001) 453. — 19. BORST MJ, INGOLD JA, Surgery, 114 (1993) 641. — 20. THERAUX J, BRETAGNOL F, GUEDJ N, CAZALS-HATEM D, PANIS Y, Gastroenterol Clin Biol, (2009) — 21. UYGUN K, KOCAK Z, ALTANER S, CICIP I, TOKATLI F, UZAL C, Yonsei Medical Journal, 47 (2006) 578. — 22. TAAL BG, den HARTOG JAGER FC, STEINMETZ R, PETERSE H, Gastrointest Endosc, 38 (1992) 136. — 23. RAYU U, MA CK, SHAW A, Mod Pathol, 6 (1993) 516. — 24. KAUFMANN O, DEIDESHEIMER T, MUEHLENBERG M, DEICKE P, DIETEL M, Histopathology, 29 (1996) 233. — 25. EASSON AM, ASCH M, SWALLOW CJ, Surg Oncol Clin N Am, 10 (2001) 161.

M. Perić Balja

Department of Pathology, University Hospital of Tumors, Ilica 197, 10000 Zagreb
e-mail: melitapericbalja@yahoo.com

REKTALNA METASTAZA LOBULARNOG KARCINOMA DOJKE: PRIKAZ SLUČAJA

SAŽETAK

Rektalne metastaze karcinoma dojke su vrlo rijetke. Češće se javljaju kod lobularnog invazivnog karcinoma dojke, obično nakon dugog perioda bez bolesti. Zbog mogućnosti sistemske terapije, važno je biti svjestan tog neobičnog metastatskog obrasca kod invazivnog lobularnog karcinoma dojke. Prikazujemo slučaj 83-godišnje žene sa rektalnom metastazom lobularnog karcinoma sedam godina nakon operacije primarnog tumora.