

# The Role of Endoscopic Ultrasound in Evaluation of Gastric Subepithelial Lesions

Tajana Pavić, Davor Hrabar and Marko Duvnjak

Department of Gastroenterology and Hepatology, »Sestre Milosrdnice« University Hospital, Zagreb, Croatia

## ABSTRACT

*A subepithelial mass is a common finding during endoscopic procedures. Endoscopic ultrasound (EUS) is an important diagnostic modality in the evaluation of subepithelial lesions of the gastrointestinal tract. EUS is the diagnostic test of choice to assess the size, margins, the layer of origin, echotexture, and to differentiate between an intramural and extramural lesion. However, the EUS imaging lacks the specificity. EUS-guided fine needle aspiration (EUS-FNA) or core biopsy can help establish a tissue diagnosis and potentially characterize malignant risk. The aim of this article is to review the diagnosis and management of the most common subepithelial gastric lesions with an emphasis on the role of endoscopic ultrasound.*

**Key words:** subepithelial, submucosal, endoscopic ultrasound.

## Introduction

Subepithelial mass lesions in the stomach, often referred to as submucosal lesions, although they may arise from layers of the gastric wall other than histological submucosa, are small, mostly asymptomatic lesions covered with normal mucosa incidentally found on endoscopic or radiological examinations<sup>1</sup> (Figure 1). Occasionally they may be large and outgrow their vascular supply resulting in ulceration and bleeding. The differential diagnosis of these lesions ranges from clinically insignificant to malignant conditions. Standard endoscopy

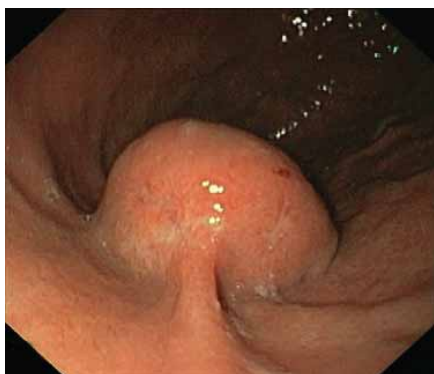

Fig. 1. Endoscopic view of the subepithelial gastric lesion (GIST).

with biopsy is not reliable for providing diagnostic material. Cross-sectional imaging techniques such as transabdominal ultrasonography, computed tomography and magnetic resonance are able to characterize the structures outside the gastric wall, but often fail to distinguish between the various causes of masses within the gastric wall. Endoscopic ultrasonography (EUS) is currently the most effective method for differentiating between subepithelial lesions and wall impressions caused by extramural protrusions<sup>2,3</sup>. EUS imaging of a subepithelial lesion can provide us with information regarding the size, margins, originating layer, internal echogenicity, echo pattern and vascular supply. Although these endosonographic findings are helpful in categorization of a lesion, they cannot absolutely determine the type of a lesion or its benign or malignant nature. Based on the clinical context, EUS-guided fine needle aspiration (EUS-FNA) or core biopsy can help establish a tissue diagnosis and potentially characterize malignant risk<sup>4</sup>.

## Epidemiology

Every endoscopist has encountered subepithelial lesions during endoscopy, but there are no reliable data on their incidence, since the majority of cases remain asymptomatic and undiagnosed. One retrospective study

reported an incidence of 0.36% during upper endoscopies in eight consecutive years<sup>5</sup>. The distribution of subepithelial masses in the upper gastrointestinal tract is not uniform – approximately 60% are found in the stomach, 30% in the esophagus and 10% in the duodenum<sup>6</sup>.

### Endosonographic Characterization of Subepithelial Lesions

Endosonography of the gastrointestinal tract wall at a scanning frequency of 5–12 MHz typically exhibits five distinct layers. Depending on the region of the gastrointestinal tract being examined and the frequency of the ultrasound transducer (up to 20 MHz), nine layers can be visualized<sup>7</sup>. The five layers seen on ultrasound images of the normal gastrointestinal tract do not directly correspond to the histological layers but approximate to: layer 1 – mucosal interface, layer 2 – muscularis mucosae, layer 3 – submucosa plus the acoustical interface between the submucosa and muscularis propria, layer 4 – muscularis propria minus the acoustical interface between the submucosa and muscularis propria, and layer 5 – serosa and subserosal fat<sup>8</sup> (Figure 2). Extramural lesions cause compression to all five layers. Endosonographic characterization of subepithelial lesions is based on their: layer of origin, size, margins (smooth/irregular), echogenicity (anechoic, hypoechoic, hyperechoic, mixed), texture (homogenous, inhomogeneous), presence of defined internal structures (calcifications, strains, tubular structures) and position towards neighboring structures<sup>9</sup>. It is also possible to estimate blood perfusion by Doppler imaging, visualize existing enlarged regional lymph nodes, superficial hepatic focal lesions and free

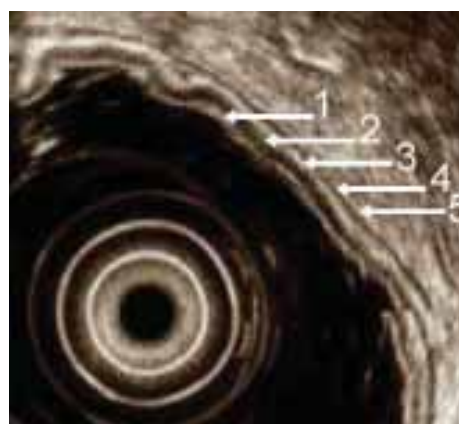


Fig. 2. Normal five-layered gastric wall structure: 1) mucosal interface, 2) muscularis mucosae, 3) submucosa, 4) muscularis propria, 5) serosa.

peritoneal fluid. Numerous attempts have been made to correlate specific endosonographic findings with histopathological characteristics of certain lesions because studies have shown that up to 20% of them may be neoplastic<sup>10</sup> (Table 1).

Hypoechoic lesions are clinically the most important lesions within the gastric wall because of their malignant potential. In the eight larger endosonographic studies with histological controls, the following criteria were markers of malignancy: irregular outline, presence of echogenic or cystic internal structures, inhomogeneous echo pattern, diameter exceeding 3–4 centimeters and the presence of enlarged regional lymph nodes<sup>2,11–17</sup>. However, correlation of EUS characterization and the final pathology matches in only 77% of subepithelial le-

TABLE 1  
DIFFERENTIAL DIAGNOSIS OF INTRAMURAL SUBEPITHELIAL LESIONS BASED ON EUS FEATURES<sup>9,40</sup>

Type of lesion	EUS layer	EUS appearance
Benign		
Leiomyoma	2, 3, 4	Hypoechoic, usually in the esophagus
Neurogenic tumors Neuroma, schwannoma, ganglioneuroma	3 or 4	Hypoechoic
Lipoma	3	Hyperechoic, smooth margins
Cysts	3	Anechoic, compressible, 3–5 layer walls suggestive of duplication cyst
Heterotopic pancreas	2 or 3	Hypoechoic or mixed echogenicity (ductal structures, central cyst)
Granular cell tumor	2 or 3	Hypoechoic, smooth margins
Varices	3	Anechoic, perfusion visible
Lymphangioma	3	Anechoic, frequently polycystic, no perfusion
Malignant or with malignant potential		
GIST	4 (rarely 2 or 3)	Hypoechoic, bigger than 3 cm, irregular margins, hyperechoic spots, disruption of EUS layers
Lymphoma	2, 3, 4	Hypoechoic
Carcinoid	2 or 3	Hypoechoic, smooth margins
Metastases	Any	Hypoechoic



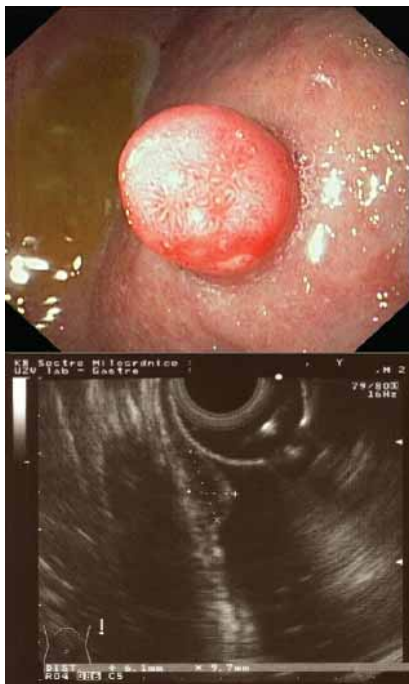

Fig. 4. Carcinoid of the gastric fundus. The endoscopic picture shows a polypoid lesions with normal-appearing overlying mucosa. The endosonographic picture shows inhomogenous, hypoechoic lesion originating from the second layer.

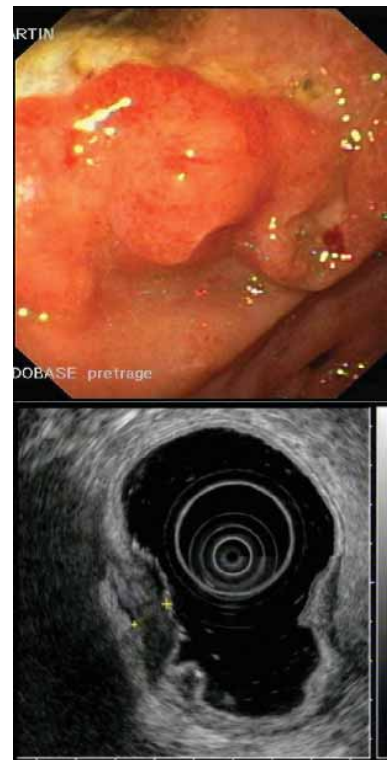


Fig. 5. Gastric MALT lymphoma presenting as an ulcerated polypoid mass, endosonographically showing a hypoechoic lesion extending through the entire wall.

layer, or extending through the entire wall (Figure 5). EUS-FNA can be used to obtain tissue for flow cytometry to establish the diagnosis<sup>1</sup>.

### Benign Subepithelial Lesions

#### Lipomas

Lipomas are benign tumors composed of mature lipocytes. They account for less than 1% of all intramural gastric lesions<sup>36</sup> They are typically solitary lesions, endoscopically exhibit slightly yellow shimmering through mucosa, with a pillow sign when probed with forceps<sup>36</sup>. Endosonographically lipomas appear as intensely hyperechoic, well demarcated lesions located in the third layer<sup>37</sup> (Figure 6). Those characteristics make it possible to diagnose a lipoma in most cases with no need in further EUS follow up<sup>1</sup>. The incidentally found lipoma does not require treatment, except for symptomatic lesion which causes bleeding or obstruction.

#### Leiomyomas

Leiomyomas are benign gastrointestinal mesenchymal tumors with muscular differentiation. They are rarely found in stomach, whereas in the esophagus they are the most common subepithelial tumors. They arise from the second or the fourth layer. Endosonographically they appear as well demarcated, hypoechoic, sometimes even anechoic lesions. On immunohistochemistry they show positive staining for smooth muscle actin and desmin and negative staining for CD117, CD34 and S100<sup>9</sup>.

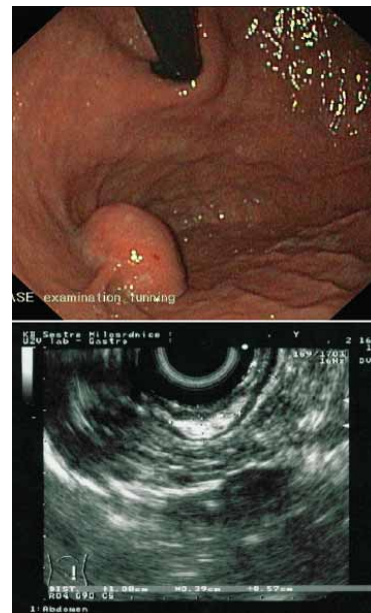


Fig. 6. Lipoma arising from the gastric fundus, endosonographically appearing as a hyperechoic lesion originating from the third layer.

#### Heterotopic pancreatic tissue

The term is used to describe ectopic pancreatic tissue outside its normal location with no connection to the

pancreas. It is typically located in the gastric antrum, and on endoscopy exhibit central umbilication. Endosonographically they arise within the second or third layer, appearing as a heterogeneous hypoechoic lesion with poorly defined margins which may contain cystic spaces, duct-like structures, hyperechoic spots and calcifications<sup>9</sup> (Figure 7). Although the endosonographic findings are so variable, they correlate well with histological findings and along with typical endoscopic features, pancreatic heterotopia may be diagnosed with reasonable degree of certainty<sup>38</sup>.

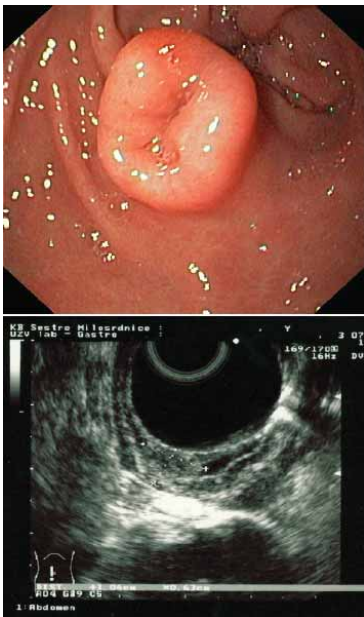


Fig. 7. Antral heterotopic pancreas seen as an umbilicated lesion on endoscopy. Endosonographically it appears as an isoechoic lesion with a slightly inhomogenous texture arising from the second layer.

### Duplication cyst

Duplication cysts result from an error in the embryonic development of the foregut causing invagination and fusion of the longitudinal folds during embryonic development. They are primarily diagnosed in the pediatric population, in adults they are usually asymptomatic and are more common in women, located either within or adjacent to the GI wall. The diagnosis can be made with EUS which will show an anechoic, smooth, spherical structure with well defined wall<sup>39</sup>. There are only rare reports of malignancy developing in duplication cysts<sup>40</sup>.

## REFERENCES

1. HWANG JH, RULYAK SD, KIMMEY MB, *Gastroenterology*, 130 (2006) 2217. — 2. ROSCH T, KAPFER B, WILL U, BARONIUS W, STROBEL M, LORENZ R, ULM K, *Scand J Gastroenterol*, 37 (2002) 856. — 3. GRESS F, SCHMITT C, SAVIDES T, FAIGEL DO, CATALANO M, WASEF W, ROUBEIN L, NICKL N, CIACCIA D, BHUTANI M, HOFFMAN B, AFFRONTI J, *Gastrointest Endosc*, 53 (2001) 71. — 4. GAN SI, RA-
- JAN E, ADLER DG, BARON TH, ANDERSON MA, CASH BD, DAVILA RE, DOMINITZ JA, HARRISON ME, IKENBERRY SO, LICHTENSTEIN D, QURESHI W, SHEN B, ZUCKERMAN M, FANELLI RD, LEE KK, GUILDER TV, *Gastrointest Endosc*, 66 (2007) 425. — 5. HEDENBRO JL, EKELUND M, WETTERBERG P, *Surg Endosc*, 5 (1991) 20. — 6. POLKOWSKI M, BUTRUK E, *Gastrointest Endosc Clin N Am*,

EUS FNA can aid in ruling out pancreatic pseudocyst or pancreatic cystic neoplasm. In asymptomatic patients observation alone is a reasonable option if the diagnosis is certain<sup>41</sup>.

## Management Strategies for Subepithelial Lesions

All symptomatic tumors (pain, hemorrhage, obstruction, endocrine activity) require endoscopic or surgical resection. Also, such treatment is required for all asymptomatic lesions that meet any of the following criteria: two or more of the endosonographic criteria for malignancy (tumor size bigger than 30 mm, irregular outline, inhomogeneous echostructure, not clearly defined layer of origin with infiltrative growth, enlarged local lymph nodes), development of symptoms during follow-up, significant increase in size (more than 10 mm or more than 50% in diameter), changes in EUS appearance during follow-up and cytological, histological, immunocytochemical, immunohistochemical or cytogenetic criteria of malignant or potentially malignant neoplasm<sup>1,9</sup>. EUS is useful in assessing potential endoscopic resectability and also in providing a surgeon with information about the local topography, depth of infiltration and local lymphadenopathy. Generally, tumors that are smaller than 20 mm (30 mm in suitable locations) and not exceeding the fourth layer are suitable for endoscopic resection.

Asymptomatic subepithelial lesions greater than 10 mm in diameter on EUS, unless the features of lipoma are obviously present, require further evaluation that should be put in the context of the availability of diagnostic and therapeutic modalities, local expertise, individual risk and patient's preference<sup>42–44</sup>. Hypoechoic third and fourth-layer lesions should undergo EUS-FNA and immunohistochemistry. If a diagnosis is not obtained, than Trucut biopsy or endoscopic mucosal resection (for lesions not involving muscularis propria) can be considered. Endosonographic follow-up is an acceptable alternative to endoscopic resection in a subgroup of patients with small hypoechoic and cystic lesions that meet certain criteria, which is in accordance to our unpublished data. These are: size less than 30 mm, smooth outline, homogenous texture, layer of origin clearly discernible with no evidence of infiltrative growth, or local lymphadenopathy, and no equivocal cytological or histological criteria of malignancy on FNA. The suggested interval is six months after the initial diagnosis, then six months later, and then yearly afterwards<sup>1,9</sup>.

- 15 (2005) 33. — 7. SAFTOIU A, VILMANN P, CIUREA T, Rom J Gastroenterol, 12 (2003) 2215. — 8. KIMMEY MB, MARTIN RW, HAGGITT RC, WANG KY, FRANKLIN DW, SILVERSTEIN FE, Gastroenterology, 96 (1989) 433. — 9. JANSSEN C, DIETRICH CF, Endoscopic ultrasound in subepithelial tumors of the gastrointestinal tract. In: DIETRICH CF (Ed) Endoscopic ultrasound: an introductory manual and atlas (Thieme, New York, 2006). — 10. ZAKAI DM, SNADY H, PARADISO H, AGARWAL B, Am J Gastroenterol, 95 (2000) 2644. — 11. HIZAWA K, KAWASAKI M, KOUZUKI T, SUEKANE H, MATUMOTO T, FUJISHIMA M, Dig Endosc, 12 (2000) 120. — 12. CHAK A, CANTO MI, ROSCH T, DITTLER HJ, HAWES RH, TIO LT, LIGHTDALE CJ, BOYCE HW, SCHEIMAN J, CARPENTER SL, VAN DAM J, KOCHMAN ML, SIVAK MV, Gastrointest Endosc, 45 (1997) 468. — 13. KAWAMOTO K, YAMADA Y, UTSUNOMIYA T, OKAMURA H, MIZUGUCHI M, MOTOOKA M, HIRATA N, WATANABE H, SAKAI K, KITAGAWA S, KINUKAWA N, MASUDA K, Radiology, 205 (1997) 733. — 14. BRAND B, OESTERHELWEG L, BINMOELLER KF, SRIRAM PV, BOHNACKER S, SEEWALD S, DE WEERTH A, SOEHENDRA N, Dig Liver Dis, 34 (2002) 290. — 15. NICKL N, GRESS F, MCCLAVE S, FOCKENS P, CHAK A, SAVIDES T, CATALANO M, BEHLING C, ODEGAARD S, CHANG K, ROSCH T, HAWES R, SCHEIMAN J, SAHAI A, SIVAK M, ISENBERG G, HOFFMAN B, AABAKKEN L, JOWELL P, JONES W, KIMMEY M, SCHMITT C, Gastrointest Endosc, 55 (2002) AB98. — 16. NICKL N, BEHLING C, MCCLAVE S, CHAK A, ODEGAARD S, ROSCH T, CHANG K, CATALANO M, SAVIDES T, FOCKENS P, KIM B, SCHEIMAN J, Gastrointest Endosc, 49 (1999) AB211. — 17. PALAZZO L, LANDI B, CELLIER E, CUILLERIER E, ROSEAU G, BARBIER JP, Gut, 46 (2000) 88. — 18. WIERSEMA MJ, VILMANN P, GIOVANNINI M, CHANG KJ, WIERSEMA LM, Gastroenterology, 112 (1997) 1087. — 19. FLETCHER CD, BERMAN JJ, CORLESS C, GORSTEIN F, LASOTA J, LONGLEY BJ, MIETTINEN M, O'LEARY TJ, REMOTTI H, RUBIN BP, SHMOOKLER B, SOBIN LH, WEISS SW, Hum Pathol, 33 (2002) 459. — 20. DEWITT J, EUS in pancreatic neoplasms. In: HAWES RH ET FOCKENS P (Eds) Endosonography (Saunders Elsevier, Philadelphia, 2006). — 21. SEPE P, MOPARTY B, PITMAN M, SALTZMAN JR, BRUGGE WR, Gastrointest Endosc, 70 (2009) 254. — 22. TADIĆ M, ŠTOOS-VEIĆ T, VUKELIĆ -MARKOVIĆ M, CURIĆ J, BANIĆ M, ČABRIJAN Z, GRGUREVIĆ I, KUJUNDŽIĆ M, Coll Antropol, 34 (2010) 377. — 23. LEVY MJ, JONDAL ML, CLAIN J, WIERSEMA MJ, Gastrointest Endosc, 57 (2003) 101. — 24. WIERSEMA MJ, LEVY MJ, HAREWOOD GC, VAZQUEZ-SEQUEIROS E, JONDAL ML, WIERSEMA LM, Gastrointest Endosc, 56 (2002) 275. — 25. O'TOOLE D, PALAZZO L, AROT CARENA R, DANCOUR A, AUBERT A, HAMMEL P, AMARIS J, RUSZNIEWSKI P, Gastrointest Endosc, 53 (2001) 470. — 26. NOWAIN A, BHAKTA H, PAIS S, KANEL G, VERMA S, J Gastroenterol Hepatol, 20 (2005) 818. — 27. TRUPIANO JK, STEWART RE, MISICK C, APPELMAN HD, GOLDBLUM JR, Am J Surg Pathol, 26 (2002) 705. — 28. LI SQ, O'LEARY TJ, BUCHNER SB, PRZYGDZKI RM, SOBIN LH, EROZAN YS, ROSENTHAL DL, Acta Cytol, 45 (2001) 9. — 29. MIETTINEN M, LASOTA J, Arch Pathol Lab Med, 130 (2006) 1466. — 30. ANDO N, GOTO H, NIWA Y, HIROOKA Y, OHMIYA N, NAGASAKA T, HAYAKAWA T, Gastrointest Endosc, 55 (2002) 37. — 31. MODLIN IM, LYE KD, KIDD M, Am J Gastroenterol, 99 (2004) 23. — 32. RINDI G, AZZONI C, LA ROSA S, KLERSY C, PAOLOTTI D, RAPPEL S, STOLTE M, CAPELLA C, BORDI C, SOLCIA E, Gastroenterology, 116 (1999) 532. — 33. NAKAMURA S, LIDA M, YAO T, FUJISHIMA M, Gastrointest Endosc, 37 (1991) 535. — 34. MODLIN IM, KIDD M, LATICH I, ZIKUSOKA MN, SHAPIRO MD, Gastroenterology, 128 (2005) 1717. — 35. BROOKS JJ, ENTERLINE HT, Cancer, 51 (1983) 701. — 36. MADERAL F, HUNTER F, FUSELIER G, GONZALES-ROGUE P, TORRES O, Am J Gastroenterol, 79 (1984) 964. — 37. NAKAMURA S, IIDA M, SUEKANE H, MATSUI T, YAO T, FUJISHIMA M, Am J Gastroenterol, 86 (1991) 619. — 38. MATSUSHITA M, HAJIRO K, OKAZAKI K, TAKAKUWA H, Gastrointest Endosc, 49 (1999) 493. — 39. FAIGEL DO, BURKE A, GINSBERG GG, STOTLAND BR, KADISH SL, KOCHMAN ML, Gastrointest Endosc, 45 (1997) 99. — 40. KURAOKA K, NAKAYAMA H, KAGAWA T, ICHIKAWA T, YASUI W, J Clin Pathol, 57 (2004) 428. — 41. VAN DAM J, RICE TW, SIVAK MV JR, Am J Gastroenterol, 87 (1992) 762. — 42. HWANG JH, KIMMEY MB, Gastroenterology, 126 (2004) 310. — 43. ECKARDT AJ, WASSEF W, Gastrointest Endosc, 62 (2005) 209. — 44. HUMPHRIS JL, JONES DB, Journal of Gastroenterol Hepatol, 23 (2008) 556.

T. Pavić

Department of Gastroenterology and Hepatology, »Sestre Milosrdnice« University Hospital, Vinogradska 29, Zagreb, Croatia  
e-mail: tajana.pavic@gmail.com

## ULOGA ENDOSKOPSKOG ULTRAZVUKA U EVALUACIJI SUBEPITELNIH LEZIJA U ŽELUCU

### SAŽETAK

Subepitelni tumor, ili u literaturi češće spominjani termin »submukozni« tumor, je prominenција sluznice gastrointestinalnog sustava pokrivena normalnim epitelom koja se često nalazi tijekom endoskopskih pretraga probavnog trakta. Endoskopski ultrazvuk (EUZ) je značajna dijagnostička metoda u evaluaciji ovih lezija. EUZ-om je moguće definirati da li se radi o intramuralnoj masi ili kompresiji izvana, procijeniti veličinu i rubove lezije, ehoteksturu, vaskularizaciju, te odrediti sloj stjenke iz kojeg raste. Budući da EUZ nije dovoljno specifičan u određivanju etiologije subepitelnih lezija, tankoiglena aspiracija ili biopsija pod kontrolom EUZ-a može nam pomoći u postavljanju dijagnoze i određivanja malignog potencijala. Cilj ovog članka je pregled najčešćih subepitelnih želučanih lezija, njihova dijagnostika i terapija, s naglaskom na ulogu EUZ-a.