

# Use of Digital Photographs for Artificial Tooth Selection

Asja Čelebić<sup>1</sup>, Jasmina Stipetić<sup>1</sup>, Petra Nola<sup>1</sup>, Nikola Petričević<sup>1</sup>  
and Milan Papić<sup>2</sup>

<sup>1</sup> School of Dental Medicine, University of Zagreb, Croatia

<sup>2</sup> Department of Practical Sciences, University of Split, Croatia

## ABSTRACT

*Digital photography has become available to everybody. The aim of this study was to examine possibility of calculating the width of a missing central incisor using digital photographs. Digital photographs were obtained from 51 dentate subjects using a 3.1 Megapixel digital camera from various distances: 35 cm, 70 cm, 1 m and 1.5 m. For the calculation of the width of maxillary left central incisor (MLI), the following equation was used:  $MLI_{calculated} = \text{Photographic width of MLI} \times IPD / \text{photographic IPD}$ . Statistical analysis was made (Kolmogorov-Smirnov test, dependent sample t-test, correlation and frequencies) using SPSS 10.0 for Windows. Results revealed no significant difference between the calculated MLI (70 cm, 1 m and 1.5 m distance) and actual MLI, however calculated MLI from 35 cm distance was significantly different from the actual MLI value ( $p < 0.01$ ). The highest correlation was between calculated MLI (70 cm distance) and actual MLI. However, the highest percentage of results from a distance of 70 cm also fitted within  $\pm 0.3$  mm;  $\pm 0.5$  mm and  $\pm 1$  mm difference from the actual MLI values. However, the results obtained from 1 m distance were also satisfactory. The technique of use of digital photography is of proven value in calculating the width of a maxillary central incisor. The photographs using a simple digital camera should be taken from a distance from 70 cm to 1 m. Saving such photographs in a dental office may eventually be helpful for calculating dimensions of artificial teeth.*

**Key words:** artificial versus natural tooth dimensions, digital photographs, camera-object distance

---

## Introduction

Due to rising patient expectations and recent developments in material composi-

tion and clinical techniques, the demand for restorations that replicate the natural

dentition has increased significantly. One of the difficult aspects of complete or partial removable denture prosthodontics is the selection of appropriately sized maxillary anterior teeth, which is very important considering the fact that aesthetics has been one of the most important factors for patients' satisfaction<sup>1–5</sup>.

During the last century investigators have used various methods and anatomical landmarks to aid in the selection and placement of artificial teeth for complete dentures<sup>6–14</sup>, but none of them seem to be fully accurate and satisfactory. The use of patient's old photographs for denture teeth selection has also been recommended<sup>15,16</sup>. Wehner et al.<sup>15</sup> and Bindra et al.<sup>16</sup> described a method of calculating dimensions of maxillary central incisor by measurements made on pre-extraction photograph and on the patient by substituting in the following equation: calculated central incisor's width = actual interpupillary distance × photographic width of central incisor / photographic interpupillary distance. However, the quality of an old photograph has been questioned for this purpose.

Recent development of digital photography and wide use of personal comput-

ers and their low cost have made these techniques and equipment available to almost everybody. Therefore, the aim of this study was to check the usefulness of digital photography in calculating the tooth dimensions, as well as to study the effect of a camera-object distance on the accuracy of calculated tooth dimension.

### Subjects and Methods

Fifty one dentate subjects, 18 to 48 years old (30 females and 21 males) participated in this study. All subjects were well-informed and gave a written consent.

Digital photographs were obtained from each subject using a digital camera (Fuji Finepix A310 3.1 Megapixel 3× Optical/2.9× Digital Zoom) on an adjustable tripod (Manfrotto Tripod Digi MN714SHB) in a portrait mode. Subjects were sitting in a chair in an upright position and the camera was adjusted on the tripod in the height of the subject's tip of nose. Four photographs were made, the first one from a distance of 35 cm, the second one from a distance of 70 cm, the third one from a distance of 1 meter and the fourth photograph from a distance of 1.5 meters (Figure 1). Images were transferred by an

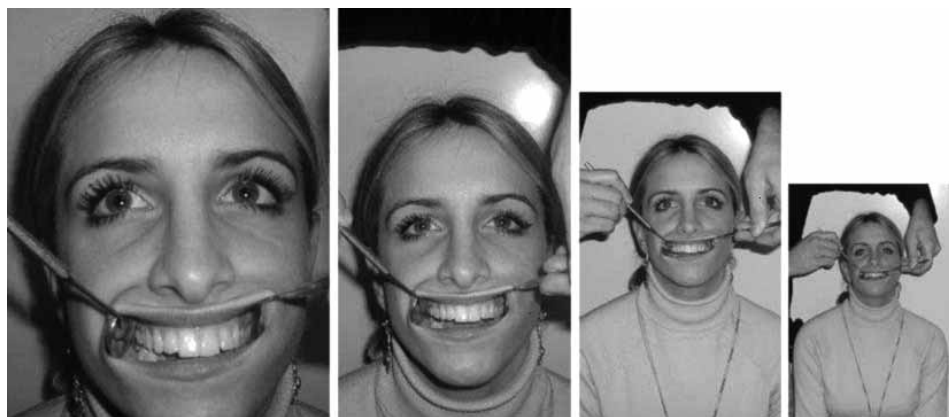

Fig. 1. Four photographs from different distances between camera and object (distance of 35 cm, 70 cm, 1 m and 1.5 m), with permission of the subject.

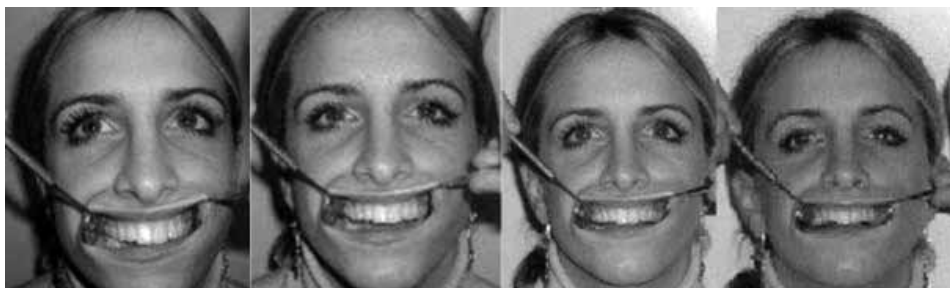

Fig. 2. Images were stretched or reduced in size, cut and enlarged in the Paint Microsoft Office Program, so that a full size of a face could fit to an A4 size paper (29.7 cm × 21 cm), with permission of the subject.

USB port to a personal computer in JPEG format and Microsoft Office Paint program was used to stretch or reduce an image, so that a full size of a face could fit to an A4 size paper (29.7 cm × 21 cm) (Figure 2). After that, images were printed in color using an A4 laser printer (Xerox Phaser 6250N; resolution 2400 dpi).

The width of the maxillary left incisor (MLI) and interpupillary distance were measured on participants by a precise caliper (MEBA, Zagreb, Croatia) with a precision of 0.1 mm. The interpupillary distance was measured between the centers of pupillas (IPD), which had been marked on a wooden spatula while each subject was looking at the object at least four meters distant from the eyes. Afterwards the same measurement was repeated on each of the four printed images on A4 paper. To calculate the width of MLI the following equation was used:  $MLI_{\text{calculated}} = \text{photographic width of MLI} \times \text{IPD} / \text{photographic IPD}$ .

Intraobserver and interobserver variability was assessed for both clinical and photographic measurements. Three different observers measured ten subjects and their photographs in two different occasions. There was no significant difference between the two occasions (t test for dependent samples;  $p > 0.05$ ) and between

three different observers (one way ANOVA;  $p > 0.05$ ). Maximum difference between three observers in two time intervals was 0.8 mm for interpupillary distance, 0.2 mm for the width of MLI, 0.2 for the interpupillary distance on photographs and 0.1 mm for the width of MLI on photographs. These values were within acceptable limits clinically. Finally, one observer completed all the measurements.

Statistical analysis was made using SPSS 10.0 for Windows (Chicago, Illinois). The normality of the distribution was tested by the one sample Kolmogorov-Smirnov test, descriptive statistics was also made, as well as t tests for dependent samples.

## Results

The results for the calculated tooth width from 4 different photographs are shown in the Figure 3. The width of MLI calculated using the photograph (35 cm distance) showed bigger values than the actual width, which is a tendency to overestimate the actual width.

The results of the dependent t test between calculated MLI width from each photograph (35 cm, 70 cm, 1 m and 1.5 m distance) and the actual width are shown in the Table 1. There was a statistically significant difference between the calcu-

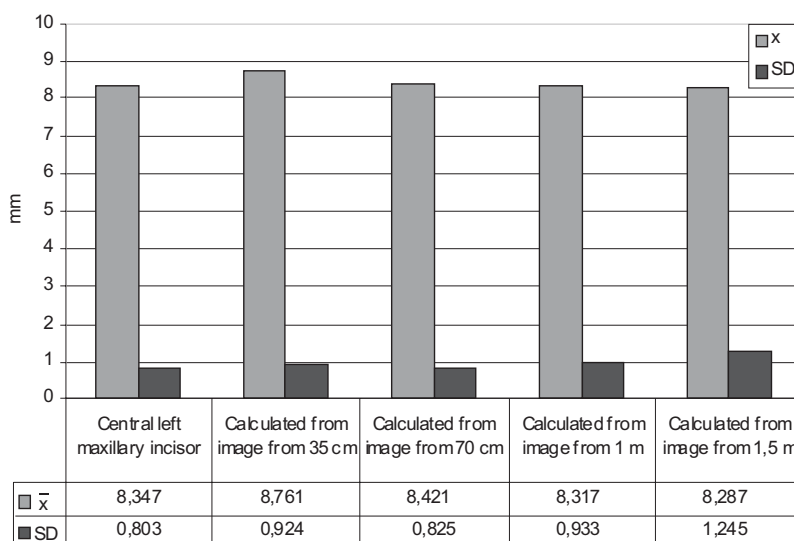


Fig. 3. Width of the actual left maxillary incisor (MLI) and calculated width of MLI from photographs made with a digital camera from 35 cm distance, 70 cm distance, 1 m distance and 1.5 m distance

lated MLI width and the actual MLI width for the photographs taken from a 35 cm distance ( $p < 0.05$ ), while for photographs from 70 cm, 1 m and 1.5 m there was no significant difference between means of calculated MLI width and the actual width ( $p > 0.05$ ).

Paired intercorrelations are presented in the Table 2. All calculated MLI values were significantly correlated with actual MLI value and the highest correlation (0.914) was between actual MLI width

and the MLI width calculated from an image made from a 70 cm distance.

Percentage of calculated maxillary left central incisor (MLI) values that fell within  $\pm 0.3$  mm;  $\pm 0.5$  mm and  $\pm 1$  mm range of the actual MLI values are shown in the Table 3. If a clinician would be satisfied with a difference of calculated MLI that would provide a central incisor of  $\pm 0.3$  mm of a patient's natural tooth, then 33% of the results calculated from an image from 35 cm distance would be acceptable,

**TABLE 1**  
t-TEST FOR DEPENDENT SAMPLES BETWEEN ACTUAL MAXILLARY CENTRAL INCISOR VALUE (MLI) AND CALCULATED MLI VALUES FROM IMAGES MADE WITH A DIGITAL CAMERA FROM 35 CM DISTANCE, 70 CM DISTANCE, 1 M DISTANCE AND 1.5 M DISTANCE

VARIABLE	t	df	p
Measured MLI value : calculated MLI value – 35 mm	-3.813	50	<0.001
Measured MLI value : calculated MLI value – 70 mm	-1.55	50	0.127
Measured MLI value : calculated MLI value – 1 m	0.299	50	0.766
Measured MLI value : calculated MLI value – 1.5 m	0.437	50	0.664

t = t-value; df = degree of freedom; p = p-value

**TABLE 2**  
 PAIRED SAMPLES CORRELATIONS BETWEEN  
 ACTUAL MAXILLARY CENTRAL INCISOR  
 VALUE (MLI) AND CALCULATED MLI VALUES  
 FROM IMAGES MADE WITH A DIGITAL CAMERA  
 FROM 35 CM DISTANCE, 70 CM DISTANCE, 1 M  
 DISTANCE AND 1.5 M DISTANCE

	N	Correlation	Sig.
MLI & calculated MLI 35 cm	51	0.605	<0.001
MLI & calculated MLI 70 cm	51	0.914	<0.001
MLI & calculated MLI 1 m	51	0.657	<0.001
MLI & calculated MLI 1.5 m	51	0.608	<0.001

N=number of cases; Sig.= significance at 99% probability

66.7% of the results from a 70 cm distance, 37.3% results from 1 m distance and 17.6% results from 1.5 m distance, respectively. If we would be satisfied that the difference of calculated MLI of  $\pm 0.5$  mm is of no clinical relevance, then 45.1% of the results from a 35 cm distance would be acceptable, 86.3% of the results from a 70 cm distance, 64.7% results from 1 m distance and 41.2% results from 1.5 m distance. However,  $\pm 1$  mm is of clinical relevance, but if we still consider it acceptable, then 82.4% of the results from a 35 cm distance is satisfactory, all the results (100%) from a 70 cm distance, 88.2% re-

**TABLE 3**  
 PERCENTAGE OF CALCULATED MAXILLARY  
 LEFT CENTRAL INCISOR (MLI) VALUES THAT  
 FIT WITHIN  $\pm 0.3$  MM;  $\pm 0.5$  MM AND  $\pm 1$  MM  
 RANGE FROM THE ACTUAL MLI VALUES

DISTANCE	% within		
	$\pm 0.3$ mm	$\pm 0.5$ mm	$\pm 1$ mm
35 cm	33.3	45.1	82.4
75 cm	66.7	86.3	100
1m	37.3	64.7	88.2
1.5m	17.6	41.2	76.5

sults from 1 m distance and 76.5% results from 1.5 m distance.

### Discussion

Tooth selection is considered a very important factor in the construction of complete dentures that function harmoniously and comfortably and preserve the denture-supporting tissues. Over the last century, several factors have been proposed as aids for artificial tooth selection, and numerous methods have been devised for the evaluation of reliable aesthetic factors in determining artificial tooth form and placement of artificial teeth for complete dentures<sup>6-14</sup>, but none of them seem to be fully satisfactory. Accurate pre-extraction records were mostly not available. Bindra et al.<sup>16</sup> described a technique of calculating the width of a central incisor when the only available evidence is a pre-extraction photograph. However, he stated that it is of value only when the photograph is a full-face portrait of sufficient size with visible frontal teeth, which is not often available in everyday life.

Worldwide frequent use of digital photography and its low cost has made this technique available to almost everybody. Therefore, this study was made with the idea that general practitioners can easily take digital photographs of their patients with frontal teeth visible and save and keep them in a personal computer, or provide a patient with a CD with his/her portrait with visible frontal teeth.

Therefore, the aim was to check the usefulness of digital photography in calculating the tooth dimensions, as well as to study the effect of camera-object distance on accuracy of the calculated tooth dimension.

The camera used in this study is not a professional one and it is not expensive, so it is available to everybody. No knowledge of how to make professional photographs is needed. The program Paint, used

in this study is a part of »Microsoft Office« package, also available to everybody and no knowledge of learning complicated programs are needed, so it is also available to all dental practitioners.

The results obtained in this study showed that the calculated MLI values (distance of 35 cm) were significantly different from actual MLI values (Figure 3 and Table 1;  $p < 0.01$ ) and the results of calculated MLI values from images (distances of 70 cm, 1 m and 1.5 m) were not significantly different from actual MLI values (Figure 3 and Table 1;  $p > 0.05$ ), respectively. The image taken from a distance of 35 cm were probably distorted, as according to manufacturer's manual, the focus range for the camera used in this study is normal: 2.0 ft to infinity, Macro: 0.3 ft. – 2.6 ft.

All calculated MLI values were significantly correlated with an actual MLI value and the highest correlation (0.914) was between actual MLI width and the MLI width calculated from an image made from 70 cm distance, indicating that the distance of 70 cm is the best for such

measurements. However, the distance of 1 m is also acceptable.

The length of a central incisor was not calculated in this study, because sometimes longer tooth is necessary to compensate for bone resorption after extraction<sup>17–20</sup>. Similar conclusions may be derived analyzing clinical relevance of the results, again the distance of 70 cm revealed the best results (Table 3) and the distance of 1 m acceptable results.

However, better digital cameras with better optical and digital characteristics would give even better results. They are becoming less and less expensive, so in future such equipment will be available to everybody.

## Conclusion

The technique of use of digital photography is of proven value in calculating the width of a maxillary central incisor. The photographs using a simple digital camera should be taken from a distance from 70 cm to 1 m. Saving of such photographs may be helpful in calculating dimensions of artificial teeth in future.

## REFERENCES

1. ČELEBIĆ, A., M. VALENTIĆ-PERUZOVIĆ, J. STIPETIĆ, Z. DELIĆ, T. STANIČIĆ, L. IBRAHIMAGIĆ, Coll. Antropol., 24 Suppl (2000) 71. — 2. ČELEBIĆ, A., D. KNEZOVIĆ ZLATARIĆ, M. PAPIĆ, V. CAREK, I. BAUČIĆ, J. STIPETIĆ, J. Gerontol. A Biol. Sci. Med. Sci., 58 (2003) M948. — 3. ČELEBIĆ, A., D. KNEZOVIĆ ZLATARIĆ, J. Dent., 31 (2003) 445. — 4. KNEZOVIĆ ZLATARIĆ, D., A. ČELEBIĆ, Int. J. Prosthodont., 14 (2001) 423. — 5. KNEZOVIĆ ZLATARIĆ, D., A. ČELEBIĆ, M. VALENTIĆ-PERUZOVIĆ, R. ČELIĆ, I. FILIPOVIĆ-ZORE, M. BAUČIĆ, Coll. Antropol., 24 (2000) 485. — 6. WILLIAMS, J. L., Dent. Digest, 26 (1920) 400. — 7. SELLEN, P. N., D. C. JAGGER, B. D. S. HARRISON, J. Prosthet. Dent., 80 (1998) 163. — 8. SELUK, L. W., P. W. BRODBELT, G. H. WALKER, J. Oral Rehabil., 14 (1987) 139. — 9. BELL, R. A., J. Am. Dent. Assoc., 97 (1978) 637. — 10. MAVROSKOUFIS, F., G. M. RITCHIE, J. Prosthet. Dent., 43 (1980) 501. — 11. FRUSH, J. P., R. D. FISHER, J. Prosthet. Dent., 7 (1957) 5. — 12. IBRAHIMAGIĆ, L., V. JEROLIMOV, A. ČELEBIĆ, V. CAREK, I. BAUČIĆ, D. KNE-

ZOVIĆ ZLATARIĆ, Coll. Antropol., 25 (2001) 619. — 13. LaVERE, A. M., K. R. MARCROFT, R. C. SMITH, R. J. SARKA, J. Prosthet. Dent., 67 (1992) 661. — 14. SELLEN, P. N., D. C. JAGGER, B. D. S. HARRISON, Int. J. Prosthodont., 12 (1999) 51. — 15. WEHNER, P. J., J. C. HICKEY, O. O. BOUCHER, J. Prostet. Dent., 18 (1967) 222. — 16. BINDRA, B., R. M. BASKER, J. N. BESFORD, Int. J. Prosthodont., 14 (2001) 173. — 17. KOVAČIĆ, I., A. ČELEBIĆ, D. KNEZOVIĆ ZLATARIĆ, J. STIPETIĆ, M. PAPIĆ, Coll. Antropol., 27 Suppl (2003) 69. — 18. KNEZOVIĆ ZLATARIĆ, D., A. ČELEBIĆ, M. VALENTIĆ PERUZOVIĆ, R. ČELIĆ, Coll. Antropol., 26 Suppl (2002) 107. — 19. KOVAČIĆ, I., A. ČELEBIĆ, V. BRATOLIĆ, F. KOVAČIĆ, D. KNEZOVIĆ ZLATARIĆ, D. KOMAR, M. KATUNARIĆ, Coll. Antropol., 26 Suppl (2002) 111. — 20. KATANEC, D., B. PAVELIĆ, Z. IVASOVIĆ, Coll. Antropol., 28 (2004) 331. — 21. HAUSER, G., H. ULMER, B. PETERSON, S. KIRCHENGAST, C. TROST, A. VIENNA, W. SCHEIN, Coll. Antropol., 26 Suppl (2002) 82.

A. Čelebić

*Department of Prosthodontics, School of Dental Medicine, University of Zagreb,  
Gundulićeva 5, 10000 Zagreb, Croatia  
e-mail: celebic@sfzg.hr*

## **UPOTREBA DIGITALNE FOTOGRAFIJE U IZRAČUNAVANJU DIMENZIJA UMJETNIH ZUBI**

### **S A Ž E T A K**

Digitalna fotografija postala je svima dostupna. Svrha ovog rada bila je proučiti mogućnost izračunavanja širine izgubljenog zuba pomoću digitalne fotografije. Fotografije su napravljene kod 51 ozubljenog ispitanika pomoću digitalnog foto-aparata (3.1 Megapixel) iz različitih udaljenosti: 35 cm, 70 cm, 1 m i 1,5 m. Za izračun širine središnjeg maksilarnog lijevog sjekutića (MLI), uporabljena je slijedeća formula:  $MLI_{izračunata} = \text{Širina MLI na fotografiji} \times \text{razmak između pupila} / \text{razmak između pupila na fotografijama}$ . Napravljena je statistička analiza (Kolmogorov-Smirnov test, t-test za zavisne uzorke, korelacije i frekvencije) pomoću programa SPSS 10.0 za Windows. Rezultati su pokazali da nije bilo statistički značajne razlike između izračunate MLI (s fotografija snimljenih sa 70 cm, 1 m i 1,5 m udaljenosti) i prave (izmjerene) MLI, međutim izračunata MLI sa fotografija uzetih sa 35 cm udaljenosti statistički se značajno razlikovala od prave MLI vrijednosti ( $p < 0.01$ ). Najveća korelacija bila je između izračunate MLI (70 cm udaljenost) i prave MLI. Najveći postotak rezultata koji ne odstupaju više od  $\pm 0.3$  mm;  $\pm 0.5$  mm i  $\pm 1$  mm od pravih MLI vrijednosti također je izračunat s fotografija uzetih sa 70 cm udaljenosti. I rezultati dobiveni s udaljenosti od 1 m bili su zadovoljavajući. Upotreba digitalne fotografije pokazala je svoju vrijednost u izračunavanju širine gornjeg središnjeg sjekutića. Fotografije pomoću najjednostavnijeg digitalnog foto-aparata trebaju se snimiti s udaljenosti od 70 cm do 1 metra. Pohranjivanje ovakvih fotografija u svakoj stomatološkoj ordinaciji može jednog dana pomoći u izračunavanju dimenzija umjetnih zuba.