

Insights into a Mummy: A Paleoradiological Analysis

Mislav Čavka^{1,2}, Ivor Janković², Petra Rajić Šikanjić², Nino Tičinović¹, Stipe Radoš¹, Gordana Ivanac¹ and Boris Brkljačić¹

¹ Department of Diagnostic and Interventional Radiology, Dubrava University Hospital, Zagreb, Croatia

² Institute for Anthropological Research, Zagreb, Croatia

ABSTRACT

The aim of the study was to analyze possible human skeletal remains within the wrappings of a mummy from the Archaeological Museum, Zagreb, Croatia through the use of the multidetector CT (MDCT) technology. Plain X-ray films and MDCT images of the mummy were taken in both frontal and lateral views. In a single volumetric acquisition of the whole body by MDCT, 0.75 mm axial slices were obtained and combined with sagittal and coronal reformatting and three-dimensional (3D) reconstruction. Sex and age was assessed visually using standard anthropological methods. The results suggest that the mummy was of an adult female, most likely over 40 years of age at death. Pathologies observed included degenerative changes on the vertebral column and healed fractures of the lower right arm. Damage of the ethmoid bone at the roof of the nasal cavity was most likely caused by mortuary brain removal practice. Remnants of a resin and an unusual object were found inside the cranial cavity. An elongated metal object and additional three metal »belts« can be seen on the lower portion of the body. All internal organs were removed and thoracic and abdominal cavities were filled with various substances, most likely mud and pieces of linen cloth.

Our results show that the MDCT is a very useful technique for assessing the human remains in archeological samples, especially in comparison to the use of plain film (X-ray), where important details are obscured and 3D imaging impossible.

Keywords: paleoradiology, mummies, paleopathology, CT

Introduction

In 2008 a mummy was given to the Institute for Anthropological Research in Zagreb for further analysis. The mummy was originally given as a gift from the Zagreb Archbishop Juraj Haulik to the Archaeological Museum in Zagreb sometime in the 19th century. It was stored in a fake Egyptian sarcophagus, and whether the wrapping contained human remains was uncertain. Upon brief visual examination it was possible to conclude that the bones that were clearly visible (part of the mandible and maxillary bone containing several teeth) were indeed human. However, as the rest of the body was wrapped inside a cloth, we have decided that the best way to proceed is through a radiological study that will minimize the damage to the mummy. As the sarcophagus was not an original ancient Egyptian product, but a later »fake«, a date for the mummy was also unknown. Therefore, a part of a lower right first molar was extracted for

radiocarbon dating (C14). Direct dating using AMS (Beta – 252265) provided a date of between 410 and 370 years B.C. (Cal).

A small fragment of a glass eye, and a fragment of the fabric in which the mummy was wrapped in were also taken for further analyses. The overall condition of the mummy was good, except for some traces of microbiological material on the wrapping, samples of which were taken and the microbiological analysis is in progress.

The main aim of this work were to study the mummy with minimal damage to the specimen. One of the first questions to answer was a simple one: what was inside the wrapping, i.e. are there any human remains in it at all? From this simple question, we have approached more elaborate, albeit standard anthropological questions, such as age assessment, sex assessment, presence of pa-

thologies or any other irregularities etc. Further, we were interested in the process of mummification itself, and see how multidetector CT (MDCT) and post-processing techniques can help us in answering some of these questions.

Materials and Methods

Radiologic study of the mummy was done at the Department of Diagnostic and Interventional Radiology, Dubrava University Hospital, Zagreb, Croatia. Radiographs of the whole body were done in frontal and lateral views. RAD Speed, Shimadzu Europa GmbH, Duisburg, Germany was used. Slices were obtained using 16×0.75 collimation and images were reconstructed at 1-mm section thickness and 0.7-mm reconstruction increment using MDCT unit (Sensation 16; Siemens AG Medical Solutions, Erlangen, Germany). Mummy was lying on its back and the scanning was done headfirst. Sagittal and coronal reformatting and three-dimensional (3D) reconstruction was done on Leonardo workstation (Siemens AG Medical Solutions, Erlangen, Germany) and Aquarius workstation (Terarecon Inc, San Mateo, USA). Scanning parameters were: 163 mA, 120 kV. There was no gantry tilt. More than 2000 images were produced.

Anthropological analyses included determination of sex, age at death, and pathological conditions. Sex determination was based on the visual observation of morphological characteristics of skull and pelvic bones^{1,2}. Age at death was assessed on the basis of epiphyseal closures, dental wear, and structural changes in spongy bone of proximal ends of humerus and femur^{1,2}, and pathological changes that are known to be correlated with age^{3,4}.

Results and Discussion

The overall state of preservation of the mummy was very good. Almost all skeletal elements were preserved. The body was wrapped in cloth, with the exception of the face on which glass eyes were added. The left eye was almost intact while the right was severely damaged. There was a large hole in the cloth in the abdominal region.

The CT scan provided images of excellent contrast and resolution and allowed us to see the details which could not be observed on a regular X ray (Figures 1 and 2). Further, a detailed visualization of body cavities was possible through a combination of images and 3D reconstruction.

Sagittal reformatted images provided an insight into the method of brain removal.

Brain was removed through nasal cavity, as shown by the damage on the ethmoid bone (Figure 3). This was a common method used for brain removal in Egyptian mummies from the New Kingdom (XVIII – XX; 1550–1064 B.C.) onwards, in which an object (possibly a metal rod) was inserted through the nasal passage in order to extract the brain matter³. No other skull bones were visibly damaged. In the posteroinferior part of the cranial cav-

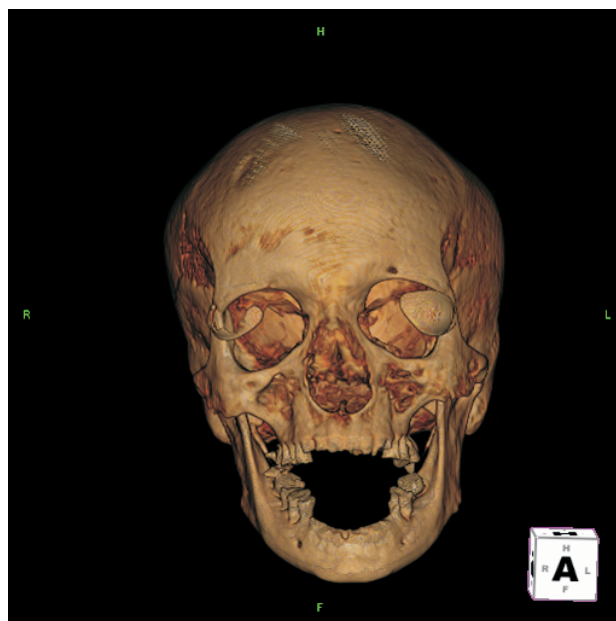

Fig. 1. VRT reconstruction of the cranium in anterior view.

ity a homogenous mass (Figure 4) is seen with the density of 70 Hounsfield units (HU), which is similar to the values for resin for several mummies, including the »Trier mummy«^{5,6}. A tubular structure approximately 10 cm in length can be observed inside the cranial cavity (Figure 4). It extends from the left parietal bone to the resin like fluid in the occipital bone. Difference in density of this structure can be observed. The inner part has HU values from –450 to –300, while the outside surface measures from 0 to 100 HU. In several Egyptian mummies (again from the New Kingdom onwards) similar resin

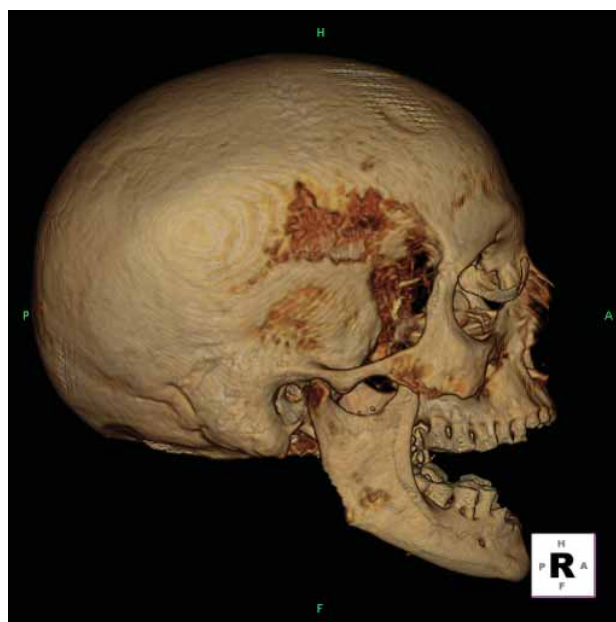

Fig. 2. VRT reconstruction of the cranium in lateral view.

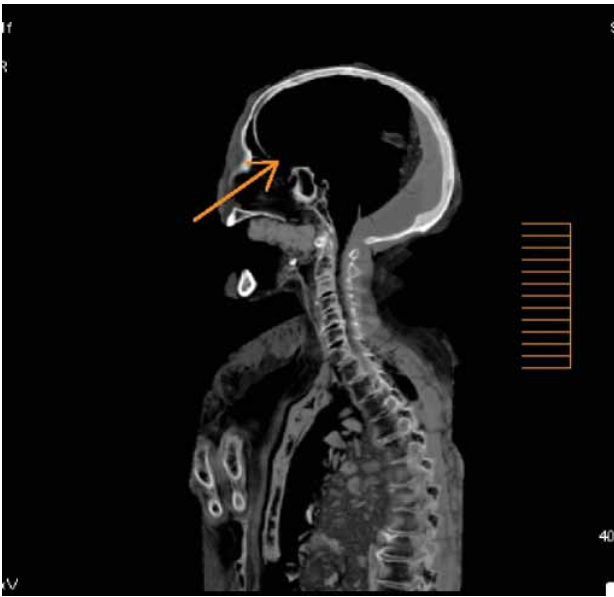

Fig. 3. sagittal reconstruction showing damage caused by the brain removal.

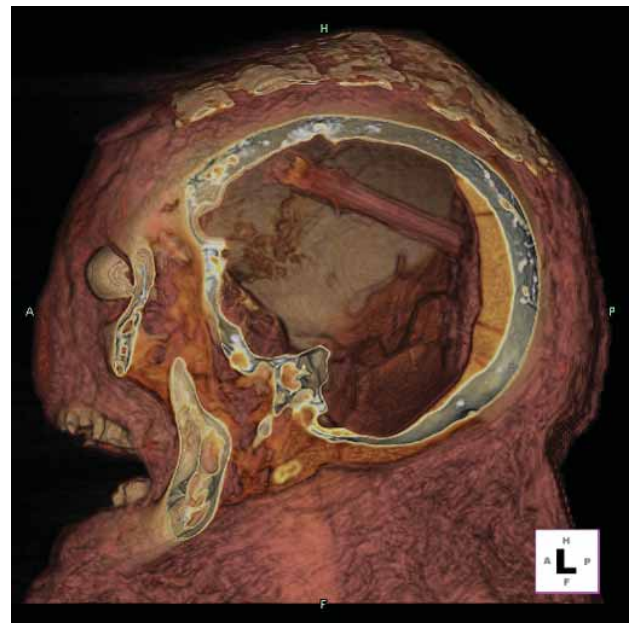


Fig. 4. VRT reconstruction of the cranial cavity.

was found³. It was noted as a part of the mummification process in which liquid was poured inside the cranial cavity after the brain removal³. Remnants of the falx, tentorial and dural matter have been noted on some Egyptian mummies from the third intermediate (XXI –

XXV dynasty; 1064–656 B.C.) period and we may be seeing the same thing here. However, the regular shape of this object may indicate artificial object (e.g. a wooden stick used in brain removal, or some other item). As this type of object is a rare find, endoscopic examination may

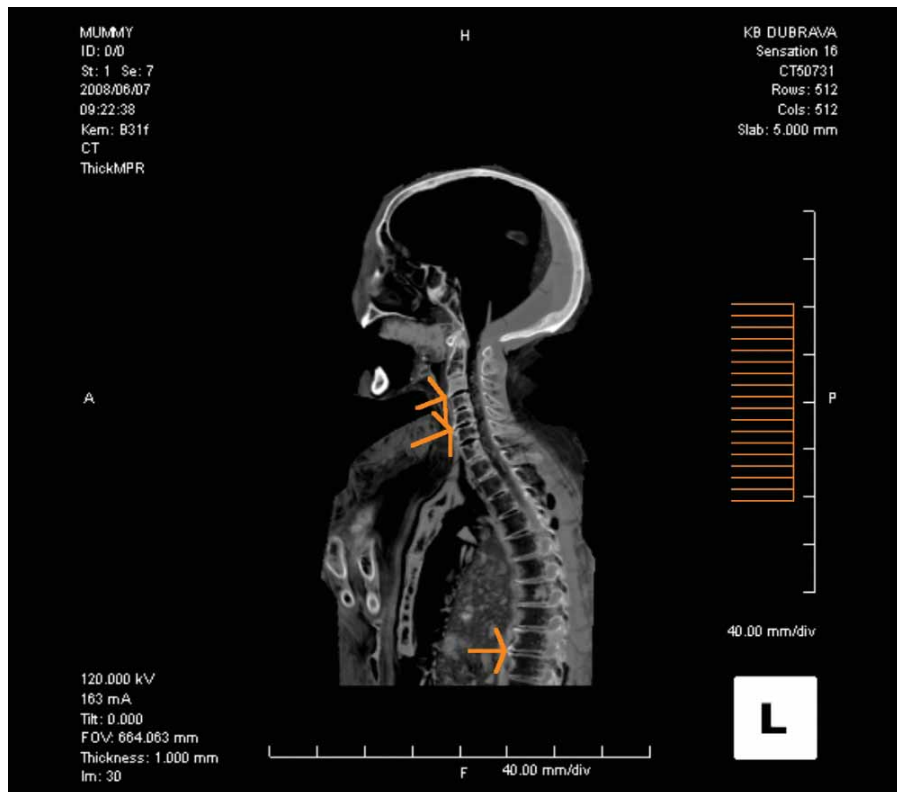


Fig. 5. sagittal reconstruction showing degenerative changes on the vertebral column.

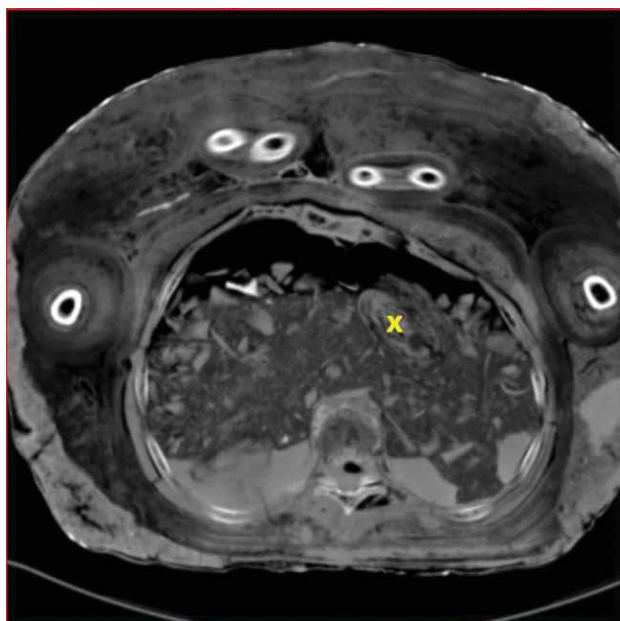


Fig. 6. transversal view showing the oval object in thoracic cavity.

help shed some light into this. Eye orbits were almost completely empty with some soft tissue remains in the left orbital cavity (possibly remnants of orbital muscles or nerve). The value of HU for the aforementioned glass eyes is around 1500. Morphological observations on the skull (supraorbital and mastoid region, gonial angle and chin) indicate a gracile person, most likely female.

CT of the dental region shows that all teeth are present in the maxilla, while in the mandible 7 teeth remained. This loss is most likely postmortal. Dental wear

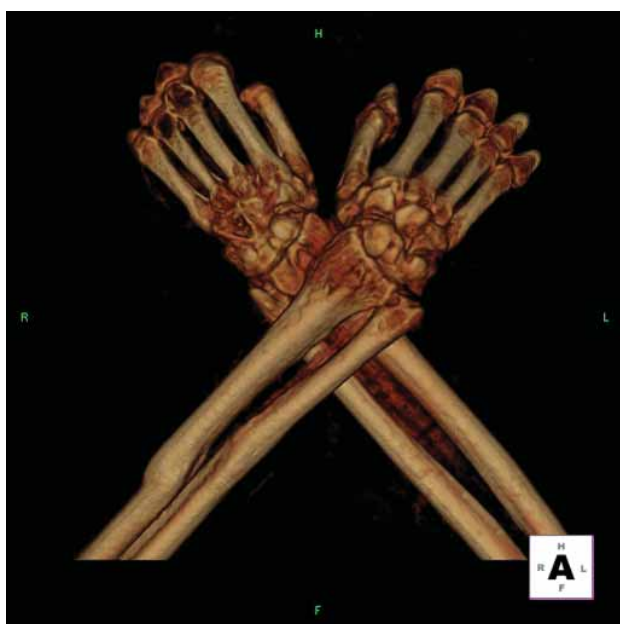

Fig. 7. VRT reconstruction showing healed fractures of radius and ulna.

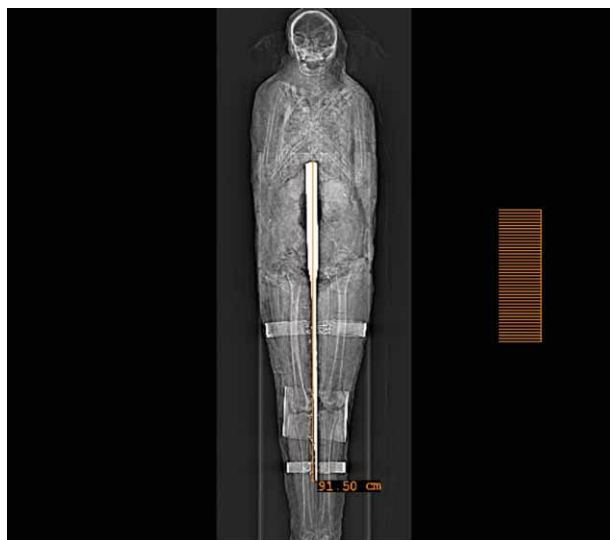


Fig. 8. CT scout image showing the metal objects.

is quite severe and points to an older person of 40+ years of death. Cervical and thoracic vertebrae show presence of osteophytes. This is commonly associated with degenerative changes in persons over 30 years of age⁷ (Figure 5). Observed changes in the long bone density are in agreement with older age^{1,8}.

Inside the oral cavity a linen »packing« has been inserted. This is also seen in the ventral part of the neck. All internal organs were removed, and thoracic and abdominal cavities are filled-in with artificial material that exhibits three different density values: 1. approximately –300; 2. approximately 100; 3. approximately 1000 HU. These values may indicate mud (first value), linen wrappings (second value), and resin fluid or shattered bones (third value) (for more details see³ and references therein). Similar objects have been noted in mummies of the Third Intermediate Period (XXI–XXV dynasty, 1064–656 B.C.), presumably to make the mummy appear more life-like³.

At the level of 9th thoracic vertebra, an oval structure can be seen, approximately 5x2 cm in size (Figure 6). Mummies from the 21st dynasty had viscerae that were enclosed in a linen wrapping reinserted into the body³. It is unclear whether this is the case here.

The mummy's arms were crossed on the chest. There is a fracture on both right radial and ulnar mid-diaphysis (Figure 7). Fractures are completely healed, with a slight angulation seen on the callus.

The pelvic region was very distorted and damaged as a result of the postmortal displacement.

There is a defect on the sacrum and another hole can be seen at that level. Size of the greater sciatic notch as seen on radiographs indicates female sex.

Femoral heads are outside acetabula, and femora are rotated laterally. This is also a post mortal event. Scanning revealed an additional hole on the dorsal side, approximately in the sacral region.




Fig. 9. VRT reconstruction of the metal objects.

Metal objects associated with the lower portion of the body were clearly visible on both radiographs and CT scans (Figure 8). The most prominent feature is an elongated object (bar) of 91.5 cm in length and made of metal. The object is positioned in superoinferior direction, starting approximately at the level of 10th thoracic vertebra, and extending to the midshaft of the lower legs. Three belt-like metal structures are also present (Figure 9). The uppermost one, located at the femoral midshaft is 4 cm wide. The middle belt is located at the knee joint and reaches 14.5 cm in width, while the lowermost one is 3 cm wide and located at the midshaft of the lower leg. Belts were connected on the ventral side of the body with metal wires. Their function was most likely to secure and reinforce the position of the lower body and the function of the metal »shaft« is uncertain. The presence of metal

REFERENCES

1. WEA (Workshop of European Anthropologists Recommendation for age and sex diagnosis of skeletons), *J Hum Evol*, 9 (1980) 517. — 2. BUIKSTRA J, UBELAKER D, Standards for data collection from human skeletal remains (Arkansas Archaeological Survey, Fayetteville, 1994). — 3. AUFDERHEIDE AC, The scientific study of mummies (Cambridge University Press, Cambridge, 2003). — 4. ORTNER DJ, Identification of Pathological Conditions in Human Skeletal Remains (University Press,

objects excluded the possibility of use of MRI in our analysis as it would require their removal and thus cause serious damage to the specimen.

Conclusion

Advances in technology offer a novel insight and means to analyze human skeletal remains. Especially, computer assisted radiological procedures provide us with non-destructive means of analyzing internal structures of various structures. We used a multidetector CT (MDCT) combined with computerized post-processing methods in order to study internal structures of a mummified body. We have been able to determine the sex and approximate age of the deceased, as well as get an insight into the process of mummification without unwrapping the body. Further, it was possible to compare the results of the already available data on mummies and mummification procedures. The removal of the brain and internal organs is consistent with procedures used in ancient Egypt, and the details such filling in the abdominal and thoracic cavity are consistent with examples from the 21st Dynasty onwards, while the results of the radiometric dating to between 410 and 370 years B.C. (Cal) suggest the mummy is from the Late Period (XXVIII-XXX dynasty), in which a decline in the quality of the mummification procedures can be observed. Further analyses will include the endoscopy of the cranial cavity and study of the wrappings.

Acknowledgements

Authors would like to express their gratitude to Igor Uranić and Jacqueline Balen of the Archaeological Museum in Zagreb for their help during the analysis and James C. Ahern of the Department of Anthropology of the University of Wyoming for insightful comments on the manuscript. Research was partially supported by the Ministry of Science, Education and Sports of the Republic of Croatia (project no. 196-196-2766-2740).

Washington DC, 2005). — 5. MARX M, D'AURIA SH, *CT Radiographics*, 6 (1986):321. — 6. SIGMUND G, MINAS, M, *European Radiol*, 12 (2002) 1854. — 7. AUFDERHEIDE AC, RODRÍGUEZ-MARTÍN C, *The Cambridge encyclopedia of human paleopathology* (Cambridge University Press, Cambridge, 2003). — 8. ACSÁDI G, NEMESKÉRI J, *History of human life span and mortality* (Akadémiai Kiadó, Budapest, 1970).

I. Janković

Institute for Anthropological Research, Gajeva 32, 10000 Zagreb, Croatia
e-mail: ivor.jankovic@inantro.hr

UVID U MUMIJU: PALEORADIOLOŠKA ANALIZA

SAŽETAK

U radu su prikazani rezultati analize mumije iz fundusa Arheološkog muzeja u Zagrebu. Konvencionalne Roentgen (RTG) snimke mumije snimljene su u dvije projekcije. Na MDCTu dobiveni su izometrijski aksijalni 0,75 mm slojevi te naknadno kombinirani sa sagitalnim, koronarnim te trodimenzionalnim (3D) rekonstrukcijama. Spol i dob određena je na temelju standardnih vizualnih antropoloških metoda. Rezultati analize ukazuju na to da ostaci pripadaju odrasloj ženskoj osobi, najvjerojatnije starijoj od 40 godina. Uočene su patološke promjene kralješnice kao i zaliječene frakture desne podlaktice. Oštećenje rešetnice unutar nosne šupljine najvjerojatnije je nastalo prilikom uklanjanja mozga. Unutar lubanjske šupljine prisutni su ostaci smole kao i neidentificiran predmet. Dugoljast metalni predmet i tri metalna remena uočena su u predjelu donjeg dijela tijela. Svi unutarnji organi nedostaju a unutar torakalne i abdominalne šupljine prisutni su razni predmeti, najvjerojatnije blata i tkanine. Rezultati pokazuju da je MDCT vrlo korisna tehnologija za analizu ljudskih kosturnih ostataka iz arheološkog konteksta, posebice u usporedbi s tradicionalnim radiografskim metodama (x zrake) budući da otkriva puno više detalja.