

Real Mineral Density of the Sternum

Robert Selthofer¹, Vasilije Nikolić¹, Tomislav Mrčela², Radivoje Radić¹, Igor Lekšan¹, Kristijan Dinjar¹ and Kristina Selthofer-Relatić³

¹ Department of Anatomy, School of Medicine, »J. J. Strossmayer« Osijek University, Osijek, Croatia

² Faculty of Electrical Engineering, »J. J. Strossmayer« Osijek University, Osijek, Croatia

³ Department of Cardiology, Osijek University Hospital Center, Osijek, Croatia

ABSTRACT

Mineral density of the sternum is insufficiently known. The aim of this research was to investigate mineralisation of the sternum and collect normative data on mineral density of the standard male and female sternum in elderly people (average age of female samples was 64 and male's was 62 years). The research was conducted on 93 cadaveric sternums, 56 male and 37 female samples. To determine regional mineral density of the sternum each sample was cut into six bony segments (Figure 1). Mineral density of every segment was determined using the method of ashing. Male sternums were on average denser than female ones in all segments. Average mineral density of the manubrium in women was 0.169 g/cm³ and 0.220 g/cm³ in men. Average mineral density of the body of the sternum also showed existence of sex difference; it was 0.160 g/cm³ in women and 0.227 g/cm³ in men. Both male and female sternums showed identical mineral density distribution. Mineral density of the manubrium and the body was roughly equal, while the analysis of longitudinal segments showed that the central part of both the manubrium and the body of the sternum was denser than lateral parts. Complex determination of the real mineral density for defined segments of the sternum and analysis of the obtained results were used to create the map of mineral density of the sternum in men and women (Figure 2). Maximum density values were four times greater than minimum density values for analysed samples. These data showed that osteoporosis also occurs on the sternum. Loss of structure and lower mineral density decrease the sternum quality and increase the risk of sternal dehiscence after median sternotomy.

Key words: sternum, bone mineral density, osteoporosis, median sternotomy

Introduction

The sternum is of utmost significance in cardiac surgery and emergency medicine. Accessing the heart and major blood vessels through median sternotomy is the most frequent surgical approach used in cardiac surgery^{1,2}. On the other hand, the sternum density is extremely significant in the procedure of closed heart massage when pressure is applied manually over the sternum while performing cardiopulmonary resuscitation (CPR)³.

To ensure optimal outcome of both cardiosurgical procedures and cardiac resuscitation it is necessary to have quality sternum of suitable strength and toughness, which will cause no complications during or after performed procedures. Suture dehiscence of the sternum after median sternotomy is a severe complication of cardiosurgical procedures which causes high morbidity and mortality⁴⁻⁶. Furthermore, the cases of sternum fractures

sustained during heart massage are described in the literature, sometimes even causing death due to injury to the myocardium caused by sharp bone fragments⁷.

Quality sternum has optimal strength and toughness, which makes it resistant to fractures⁸⁻¹⁰. Bone weakening and quality loss is known as osteoporosis. The main consequence of this process is bone fracture at minimal strain. Since osteoporosis has become widespread nowadays, especially among elderly population, it is being referred to as »silent epidemic«^{11,12}. It includes degradation of the mineral and collagenous bone matrix which results in weak and fragile bone which is fractured when performing usual activities. Osteoporosis is mostly detected by detection of disturbed mineral structure of the bone, and the most reliable method is dual energy X-ray absorptiometry (DEXA)^{13,14}.

Mineral density of the sternum is insufficiently known. The aim of this research was to investigate mineralisation of the sternum and obtain normative data on mineral density of standard female and male sternum in elderly population. The obtained data will be used to explain and define the existence and dynamics of the process of osteoporosis on the sternum. Furthermore, we will investigate density of particular segments of the sternum to create a map of regional density of the sternum.

Materials and Methods

The research was carried out on 93 cadaveric sternums, 56 male and 37 female samples. Average age of female samples was 64 and male's was 62 years. Materials were obtained from osteological collection of the Institute for Anatomy of the School of Medicine Osijek, »J. J. Strossmayer« Osijek University. All the samples were cleaned of all soft tissues and fixed in formalin solution. To determine regional mineral density of the sternum we have designed a preparation protocol for all the samples used in the research. Each sternum was cut into six bony segments. The manubrium was longitudinally cut into three segments in the length of 6 cm: two lateral segments from the beginning of the jugular notch and the central segment as wide as the jugular notch. The body was also cut longitudinally into three segments of approximately same width and 6 cm long. Every bony segment was precisely marked so that its position within the sternum is known (Figure 1).

Mineral density was determined using the method of ashing^{15,16}. Samples volume was measured applying the Archimedes' principle before the procedure of ashing. Graduated cylinders of various sizes were used. The precision of measured volume was 0.1 cm³. To determine the mass of the mineral content laboratory furnace for ashing was used (Instrumentaria Zagreb). Defined ster-

num segments were ashed in special ceramic pots at the temperature of 800°C for 5 hours. These sternum segments were left in the furnace until it cooled down, that is for another 20 hours^{17,18}. To verify the protocol of the experiment we performed experimental ashing following the already mentioned conditions on sternum samples and measured the mass of the mineral content that was obtained. After repeating ashing of the same samples at 800°C for 5 hours the measured mineral content had identical mass. The protocol of the experiment was accepted after it was determined that by continuing the ashing mineral mass did not change. The mass was measured by scales with a precision of 0.01 g. Before each ashing the mass of every single ashing pot was measured. After ashing, according to the protocol mentioned before, the mass of the ashing pot and the obtained mass of ashes were measured together. The mass of ashes (mineral) for every sternum segment was calculated by subtracting the mass of the empty ashing pot. Real mineral density of every single sternum segment that was ashed was obtained by dividing the mass of ashes by the volume of each segment determined before the ashing.

Results

Regional density and mineralisation distribution in the sternum regardless of the sex

According to Table 1 the central parts of both the manubrium and the body of the sternum have greater density than lateral parts, while there are no statistically significant difference in density of central parts of the manubrium and the body as well as in density of lateral parts of the manubrium and the body. Analysing the density of the sternum in general we concluded that there is great variability of density between individual samples. The density varies between 0.108 g/cm³ and 0.438 g/cm³. It is evident that the maximum value is four times greater than the minimum value.

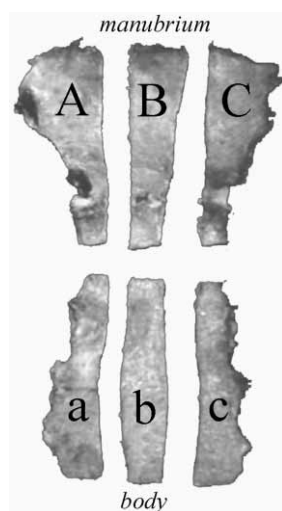

Fig. 1. Division of the sternum into segments, A – central part of the manubrium, B and C – lateral parts of the manubrium; a – central part of the body, b and c – lateral parts of the body.

TABLE 1
REAL MINERAL DENSITY OF THE STERNUM PER SEGMENTS DETERMINED BY THE METHOD OF ASHING IN A LABORATORY FURNACE

(g/cm ³)	Female (N=56)			Male (N=37)		
	$\bar{X}\pm SD$	Max.	Min.	$\bar{X}\pm SD$	Max.	Min.
Manubrium						
A	0.164±0.03	0.222	0.123	0.215±0.06	0.436	0.119
B	0.184±0.03	0.277	0.125	0.236±0.06	0.445	0.124
C	0.160±0.02	0.196	0.112	0.210±0.06	0.429	0.117
Body						
a	0.152±0.03	0.228	0.098	0.222±0.05	0.411	0.129
b	0.177±0.04	0.276	0.097	0.242±0.07	0.480	0.112
c	0.151±0.03	0.246	0.099	0.227±0.06	0.423	0.113

Sex differences in mineral density

Table 2 shows that male sternums are on average denser than female ones in all segments. Average mineral density of the manubrium in women is 0.169 g/cm³, while it is 0.220 g/cm³ in men. Average mineral density of the body of the sternum also shows existence of sex differences, it is on average 0.160 g/cm³ in women and 0.227 g/cm³ in men. The analysis of maximum and minimum values of mineral density showed that the difference varies according to sex. The difference between maximum and minimum values is 2.5 times greater in women, while in men maximum value is 4 times greater than minimum value. Analysis of mineral density according to segments and sex showed no significant difference. Both male and female samples had identical distribution of density in the sternum. Mineral density of the manubrium and the body of the sternum is roughly equal, while the analysis of the longitudinal segments showed that the central part in both the manubrium and the body is denser than lateral parts. Such density distribution does not depend on sex, regardless of evident differences in mineral density of the sternum in men and in women in absolute values.

Mineral density map of the sternum

Measuring unit used to express mineral density is g/cm³. In this research the sternum was cut into six defined segments and mineral density of each segment was determined (Figure 1). This procedure enabled creation of the map of mineral density of the sternum (Figure 2). Analysis of density *per* segment shows that central parts of both the manubrium and the body of the sternum have greater density than lateral parts, while there is no difference in density of central parts of the manubrium and the body as well as of lateral parts of the manubrium and the body of the sternum. Complex determination of the real mineral density for defined segments of the sternum and analysis of the obtained results were used to create the mineral density map of the sternum. Since it was proved that mineral density varies with sex, we created a map of mineral density of the sternum in women and in

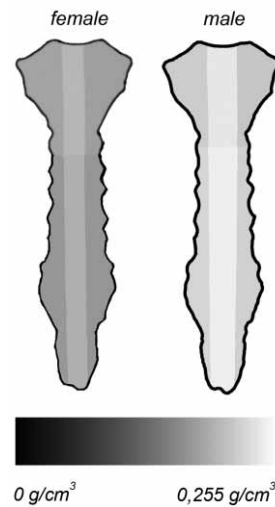


Fig. 2. Mineral density map of the female and the male sternum.

men respectively. The map is presented in 255 shades of grey colour, where the difference between the shades presents the difference in the mineral density of the sternum of 0.001 g/cm³ (Figure 2).

Discussion

Mineral density of a bone *in vivo* is frequently determined by the method of dual energy X-ray absorptiometry, which represents the »golden standard«, especially in the process of diagnostics of osteoporosis¹⁹. Superposition of the thoracic spine to the sternum makes impossible the use of this method to determine mineral density of the sternum *in vivo*. This is the reason why there are no data in the literature about the mineral density variations and dynamics of the process of osteoporosis

TABLE 2

SEX DIFFERENCES IN MINERAL DENSITY OF THE STERNUM PRESENTED FOR DEFINED STERNUM SEGMENTS

g/cm ³	Female±SD (N=56)	Male±SD (N=37)	T	p
Manubrium				
A	0.164±0.03	0.215±0.06	4.48	<0.001
B	0.184±0.03	0.236±0.06	4.05	0.001
C	0.160±0.02	0.210±0.06	4.16	<0.001
Body				
a	0.152±0.03	0.222±0.05	5.45	<0.001
b	0.177±0.04	0.242±0.07	4.36	<0.001
c	0.151±0.03	0.227±0.06	5.17	<0.001

*p≤0.001

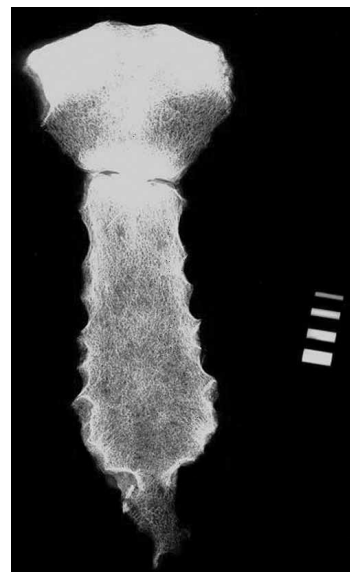


Fig. 3. Depiction of bony trajectories in the X-ray of the sternum.

sis on the sternum²⁰. The research was carried out on sternum samples obtained from the people older than 60 years. It is well known that cardiosurgical procedures, where median sternotomy is applied, are mostly performed in elderly patients and therefore the knowledge of mineralisation and structure of the sternum is of utmost importance in that age group.

Using the method of ashing, mineral density of the bone *in vitro* was determined and subsequently real sternum mineral density was calculated. Research resulted with several important facts. Significant sex difference was found in sternum mineral density. As expected, male sternums are in average denser than females in all segments. Complex dividing of the sternums into six defined segments enabled creation of the maps of sternum mineral density for both sexes. Results lead to conclusion that there is identical general distribution of density of the sternum regardless of the sex. It is further explained by the analysis of bony trajectories on the sternum. The bony trajectories on the manubrium start from clavicular notches and join in the upper third of the central part of the manubrium, where they start spreading caudally as a united central bundle. The system of bony trajectories on the body of the sternum is a continuation of the bony trajectories of the manubrium, so the main bundle is situated medially (Figure 3). Furthermore, we proved

that there is statistically significant decrease of density with aging in the female population above 60 in the analysed samples of female sternums. This wasn't found in analysed male sternums. These facts also prove that female sternums are prone to osteoporosis. Such results are in compliance with the data from the literature indicating that the process of osteoporosis affects female bones more quickly and noticeably than male bones^{23,24}. Osteoporotic comorbidity is important factor in making osteoporosis faster. It affects both sexes so it couldn't be responsible for gender difference obtained in sternum mineral density. There is significantly great difference in density between particular samples, which is 4 times greater in male samples and 2.5 times in female samples. Such findings can be explained by existence of lower peak density in women and consequently lesser difference between maximum and minimum mineral density values. It has been known that peak mineral density of the female skeleton is lesser than in male^{25,26}. From the obtained results it is evident that the process of osteoporosis affects the sternum. This research suggest that osteoporotic sternum could be important risk factor in developing sternal dehiscence and further mediastinitis. The data on real mineral density of the sternum and its dynamics could help in developing optimal models for testing different suture techniques on sternum after median sternotomy.

REFERENCES

1. CHENG W, CAMERON DE, WARDEN KE, FOUGER JD, GOTT VL, Ann Thorac Surg, 55 (1993) 737. — 2. LOSANOFF JE, JONES JW, RICHMAN BW, Cardiovasc Surg, 10 (2002) 102. — 3. BAUBIN M, RABL W, PFEIFFER KP, BENZER A, GILLY H, Resuscitation, 43 (1999) 9. — 4. LOSANOFF JE, RICHMANN BW, JONES JW, Eur J Cardio-thorac Surg, 21 (2002) 831. — 5. COHEN DJ, GRIFFIN LV, Ann Thorac Surg, 73 (2002) 563. — 6. JUTLEY RS, SHEPERD DET, HUKINS DWL, JEFFREY RR, Cardiovasc Surg, 11 (2003) 85. — 7. MACHII M, INABA H, NAKAE H, SUZUKI I, TANAKA H, Resuscitation, 43 (2000) 151. — 8. TURNER CH, Osteoporos Int, 13 (2002) 97. — 9. PIETSCHMANN P, RAUNER R, SIPOS W, KERSCHAN-SCHINDL K, Gerontology, 55 (2008) 3. — 10. KAŠTELAN D, KRALJEVIĆ I, KARDUM I, KASOVIĆ M, DUŠEK T, PROTULIPAC JM, GILJEVIĆ Z, PERKOVIĆ Z, JELČIĆ J, AGANOVIĆ I, KORŠIĆ M, Coll Antropol, 31 (2007) 701. — 11. SIPOS W, PIETSCHMANN P, RAUNER R, KERSCHAN-SCHINDL K, PATSCH J, Wien Med Wochenschr, 159 (2009) 230. — 12. SEEMAN E, Lancet, 359 (2002) 1841. — 13. ARMSTRONG III DW, SHAKIR KMM, DRAKE III AJ, Bone, 27 (2000) 835. — 14. MISKIĆ B, BISTROVIĆ D, VIZNER B, COSIĆ V, MISKIĆ D, HERMAN D, Coll Antropol, 30 (2006) 767. — 15. ECONOMOS CD, NELSON ME, FIATRONE MA, KEHAYIAS JJ, DALLAL GE, HEY-

SMFIELD SB, WANG J, YASUMURA S, MA R, PIERSON RN JR, Osteoporos Int, 10 (1999) 200. — 16. WOHL GR, LOERHKE L, WATKINS BA, ZERNICKE RF, Calcif Tissue Int, 63 (1998) 74. — 17. OTT SM, OHANLAN M, LIPKIN EW, NEWELL-MORISS L, Bone, 20 (1997) 553. — 18. TÖYRAS J, KRÖGER H, JURVELIN JS, Bone, 25 (1999) 725. — 19. JURIMAE T, HURBO T, JURIMAE J, Coll Antropol, 32 (2008) 61. — 20. SELTHOFER R, NIKOLIĆ V, MRČELA T, RADIĆ R, LEKŠAN I, RUDEŽ I, SELTHOFER K, Coll Antropol, 30 (2006) 43. — 21. SELTHOFER R, Problem of structure and strength of the sternum after cardiac surgery median sternotomy and suture. Ph. D. Thesis. In Croat (»J. J. Strossmayer« University, Osijek, 2005). — 22. NIKOLIĆ V, HUDEC M, Principi i elementi biomehanike (Školska knjiga, Zagreb, 1988). — 23. LANG TE, GUGLIELMI G, VAN KUIJK C, DE SERIO A, CAMMISA M, GENANT HK, Bone, 30 (2002) 247. — 24. RUDAN I, ŠKARIĆ-JURIĆ T, SMOLEJ-NARANČIĆ N, JANČIJEVIĆ B, RUDAN D, MARTINOVIĆ KLARIĆ I, BARAĆ L, PERIĆIĆ M, GALIĆ R, LETHBRIDGE-ČEJKU M, RUDAN P, Coll Antropol, 28 (2004) 585. — 25. PHILLIPOV G, PHILIPS PJ, Osteoporos Int, 12 (2001) 362. — 26. STINI WA, Coll Antropol, 27 (2003) 23.

R. Selthofer

Department of Anatomy, School of Medicine, »J. J. Strossmayer« Osijek University, Huttlerova 4, Osijek, Croatia.
e-mail: selthofer.robert@kbo.hr

PRAVA MINERALNA GUSTOĆA PRSNE KOSTI

S A Ž E T A K

Mineralna gustoća prsne kosti je nedovoljno poznata. Cilj je rada istražiti mineralnu gustoću prsne kosti kod žena i muškaraca starije životne dobi (prosječna dob žena je bila 64, a muškaraca 62 godine). Istraživanje je provedeno na 93 kadaverična uzorka prsne kosti (56 muških i 37 ženskih uzoraka). Svaka prsna kost je podijeljena na šest definiranih segmenata s ciljem oblikovanja karte mineralne gustoće sternuma (slika 1). Mineralna gustoća je određena metodom žarenja. Muški sternumi su prosječno gušći od ženskih u svim segmentima. Prosječna mineralna gustoća drška prsne kosti kod žena je $0,169 \text{ g/cm}^3$, dok je kod muškaraca $0,220 \text{ g/cm}^3$. Spolna razlika uočljiva je i kada promatramo gustoću tijela prsne kosti; kod žena iznosi $0,160 \text{ g/cm}^3$, dok je kod muškaraca $0,227 \text{ g/cm}^3$. I kod ženskih i muških uzoraka je utvrđen identičan opći plan mineralizacije. Mineralna gustoća drška i tijela prsne kosti je podjednaka, dok je analizom longitudinalnih segmenata dokazano da su središnji dijelovi i drška i tijela prsne kosti gušći od postraničnih. Kompleksna analiza mineralne gustoće po segmentima rezultirala je kartom mineralne gustoće (slika 2). Uočene su izrazite razlike u mineralnoj gustoći među pojedinim uzorcima koje iznose i do četiri puta. Takvi podaci sugeriraju postojanje osteoporoze na prsnoj kosti. Gubitak mineralne mase i strukture smanjuju kvalitetu prsne kosti i povećavaju rizik za nastanak dehiscencije prsne kosti nakon medijane sternotomije.