

Pain Relieve after Impacted Wisdom Teeth Extraction Dependent on the Drug Therapy

Edin Selimović¹, Lejla Ibrahimagić-Šeper¹, Nikola Petričević² and Petra Nola-Fuchs³

¹ Public Institute Health Center Zenica, Zenica, Bosnia and Herzegovina

² University of Zagreb, School of Dental Medicine, Department of Prosthodontics, Zagreb, Croatia

³ Zagreb Dental Polyclinic, Zagreb, Croatia

ABSTRACT

Purpose of this study was to compare the effects of combined therapy using nonsteroid anti-inflammatory analgetics and corticosteroids, and the effects of the mono-therapy with same drugs for post-operative pain after surgical removal of the impacted mandibular third molar. The study was completed at the Department of Oral Surgery and at the Department of Dental Medicine of the Public Institute Health Center Zenica in Zenica. The research included 60 patients divided into 3 groups using random selection, including both sexes. Age range was between 18 and 45 years. All participants came without any pain or other inflammatory symptoms at the time of oral surgical intervention. Two medicaments were prescribed after the impacted tooth removal: 15 mg of nonsteroid anti-inflammatory analgesic drug (Meloxicam, Bosnalijek, BiH) and 32 mg Methylprednisolone (corticosteroid, Bosnalijek, BiH). Both medicaments were applied per os, according to schedule determined by the research protocol. The level of post-surgical pain was evaluated by the 1–10 visual analog scale (VAS). One way ANOVA was made with Tuckey post-hoc tests. Statistically significant difference ($p < 0.05$) was found between the group treated with mono therapy and the group treated with combined therapy. Application of mono therapy using only corticosteroids or only nonsteroid anti-inflammatory pain-killers was less effective compared to the combined therapy with both medicaments after surgical removal of the impacted mandibular third molar.

Key words: impacted third molars, pain, analgesic drug (pain-killers), corticosteroids

Introduction

The post-surgical complications may occur after each surgical removal of the impacted mandibular third molar. Major complications may rarely appear in a form of paresthesia or fracture of the mandible, but minor complications such as swelling, pain and trismus are more or less predictable. The increase in incidence of the post-surgical complications may be correlated with the duration of surgical treatment, age of the patient, as well as with the depth of the impacted mandibular third molar. During the first 4 to 7 days after the surgical treatment, the negative impact to the quality of life can be expected. After that, it is common to observe the decrease of the expected post-surgical complications resulting in a significant improvement of the quality of life^{1–11}.

Removal of the impacted mandibular third molar is a widely used model for evaluation of the medicaments, as almost always minor post-surgical complications may be

expected^{1,2}. Thus, the patients are not exposed to experimental infliction in order to provoke the post-surgery complications, which is a significant ethical aspect in the research.

The aim of the study was to compare the effects of the monotherapy using nonsteroid anti-inflammatory analgetic drugs or corticosteroids, and the effects of the combined therapy with anti-inflammatory analgetic drugs and corticosteroids on the post-surgical pain relieve after the removal of the impacted mandibular third molar.

Material and Methods

The research included 60 patients who had surgical removal of the impacted third molar. All the molars finished their growth and the roots were developed, and the molars had mesioangular position (Winter II Class). All

surgical procedures were completed at the Department of Oral Surgery, Department of Dental Medicine of the Public Institute Health Center Zenica in Zenica, BiH.

Surgical approach was (cut according to Sicher) made with standard surgical instruments and uniform corticotomy from the vestibular side in each patient. Patients were divided into three groups using the random selection. Each group included twenty patients, both genders, with age range from 18 to 45 years. Diagnose of the impacted third mandibular molar was made after the clinical examination and RTG analysis (panoramic radiograph). The patients who had unfavorable kidney or liver conditions, blood dyscrasia, gastric ulceration, unfavorable heart conditions, and any allergic reactions reported in the past to some of the medicaments prescribed in the present study were excluded, as well as patients in pregnancy and lactation. The research did not include the patients who had been taking analgesics or anti-inflammatory medicaments 24 hours prior to the surgery, nor the patients with recognizable pre-surgery swelling, post-surgery bleeding or infection.

All patients gave the written consent, which had been obtained prior the treatment.

Impacted teeth were extracted under the local anesthesia with the dosage of 4 ccm of the 2% Xylocain with adrenalin (1:80000).

A file was made for every patient with his RTG records and the results obtained in the study. Detailed description of the wound, condition of the suture and the healing status during the post-surgery period were recorded.

The level of pain was evaluated twice: pain 2 (level of pain on the second day after the surgical treatment) and pain 7 (level of pain on the seventh day after the surgical treatment), both based on the patient's self-evaluation using the analogue-visual scale from 1 to 10 (VAS).

Two medicaments were used, Meloxicam (Melox Forte) 15 mg (nonsteroidal anti-inflammatory analgesic drug from the group of selective inhibitors of cyklooxygenase-2) and Methylprednisolone (Medrol) 32 mg (synthetically manufactured glucocorticoid). Both medicaments were applied *per os* according to following scheme: the first group received only the Meloxicam therapy of 15 mg, one hour before the surgical procedure and 15 mg daily for the next two days. The second group of subjects received only Methylprednisolone therapy of 32 mg, one hour before the surgical procedure and 32 mg twelve hours after the surgical procedure. The third group of subjects received the combined therapy of the both medicaments (Meloxicam + Methylprednisolone).

The software SPSS 16. for Windows was used (Chicago, Illinois, USA). The normality of the distribution was tested by the Kolmogorov-Smirnov test. The descriptive statistics was calculated. The significance of the differences between the mean values was assessed by the one-way ANOVA and Tuckey post-hoc tests.

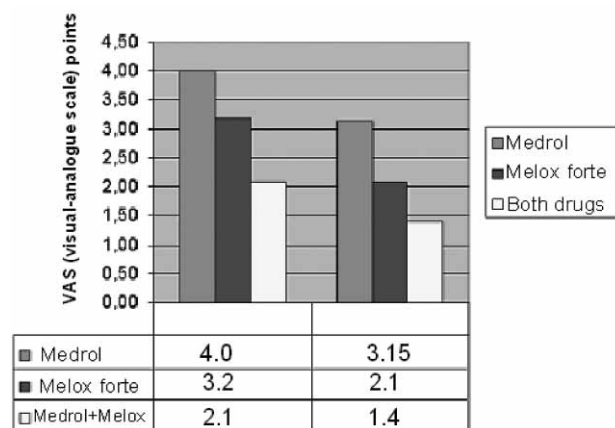


Fig. 1. Pain level on the second and the seventh day after the surgical treatment for the three groups of patients (the first group used only nonsteroidal anti-inflammatory analgesic drug (Melox Forte), the second group used corticosteroid (Medrol) and the third group used the combined therapy with the both medicaments).

Results

Mean values of the self-assessment of the pain level (1-10 visual-analogue scale points) after post-surgical therapy using different drugs are presented in the Figure 1.

Table 1 presents Tukey HSD tests (the statistical significance of the differences in pain level between the 3 groups under different post-surgical drug therapy). There was a statistically significant difference ($p < 0.05$) between the groups with monotherapy with Medrol or monotherapy with Melox Forte (in the both observed time intervals: the second and the seventh day after the surgical treatment), and the combined Medrol and Melox Forte therapy. The combined therapy had significantly lower pain level, as assessed using the 1-10 VAS.

Discussion

Oral surgical procedure causes »damage« to tissue which leads to release of potassium, serotonin and histamines from the damaged cells, and the release of bradykinin from the damaged blood vessels. This causes the activation of nociceptors, change of the tissue coloration and edema as a response of the tissue. Bradykinin causes release of prostaglandin and activation of nociceptors. Prostaglandins induce the increase of permeability of blood vessels and increase of sensitivity of nociceptors. Transfer of neural impulses from the irritated nerve fibers induces the release of the P substance in and around the tissue damage, which is responsible for further release of Bradykinin and histamine which activate other nociceptors and worsen the reaction of the tissue to injury.

Basis for clinic experiments of evaluation of different medicaments after surgical procedures is a surgically induced inflammatory process manifested with classical

TABLE 1
COMPARISON OF GROUPS USING TUKEY HSD TEST CONSIDERING THE PAIN PARAMETERS FOR THE SECOND AND SEVENTH DAY AFTER THE SURGERY

Pain parameters	(I) Therapy	(J) Therapy	Average value of the difference	Standard error	95% trust interval	
Pain_B2	Medrol	Melox forte	.800(*)	.094	.57	1.03
		Combined	1.900(*)	.094	1.67	2.13
	Melox forte	Medrol	-.800(*)	.094	-1.03	-.57
		Combined	1.100(*)	.094	.87	1.33
	Combined	Medrol	-1.900(*)	.094	-2.13	-1.67
		Melox forte	-1.100(*)	.094	-1.33	-.87
Pain_B7	Medrol	Melox forte	1.050(*)	.152	.68	1.42
		Combined	1.750(*)	.152	1.38	2.12
	Melox forte	Medrol	-1.050(*)	.152	-1.42	-.68
		Combined	.700(*)	.152	.33	1.07
	Combined	Medrol	-1.750(*)	.152	-2.12	-1.38
		Melox forte	-.700(*)	.152	-1.07	-.33

* Values of the difference with level of significance 0.05

symptoms like pain, swelling, heat and various functional damages.

Pre-medication with Meloxicam has shown as an effective way to influence the post-surgery pain³. The description of pain is always subjective⁴. International association for pain defines it as »unpleasant feeling and emotional experience which is related to real or potential damage of tissue, or it is described with expression describing such similar damage«⁵. Different scales and questionnaires have been reported in different studies for self-assessment of the level of pain, or satisfaction with the therapy or for assessment of the oral-related quality of life¹²⁻²¹. Visual-analogue scale from 1 to 10 was used in this study for assessment of the level of post-operative pain, as it was more comprehensible to the patients than just visual scale. Moreover, the similar grading system is being used in schools and faculties in Bosnia.

Systemic approach to solving problem of post-surgery pain after oral surgical procedures most commonly resulted in application of analgesic drugs and rarely corticosteroids. Clinical practice includes a widespread application of analgo-antipyretics, most commonly nonsteroidal anti-inflammatory antirheumatic drugs, which ensure effective analgesis in moderate post-surgical pain. Sometimes the anti-inflammatory analgesic drugs were applied with opioid group of analgesic drugs, prescribed in strong post-surgical pain⁷.

However, application of any medicament includes side effects which may be developed, and the therapy is directed towards finding the medicaments with best therapeutic effect and the least side effects.

All opiates cause the depression of the center for breathing, sedation, sleepiness, sluggishness, nausea, vomiting and constipation. One side effect is also the mood change which varies from euphoria to dysphoria. Thus,

inclusion of opiates into the post-surgical medicamentous therapy can be taken into account only in case of failure of the maximum dose of nonsteroidal anti-inflammatory analgesics, and only mild opiates may be prescribed.

The Meloxicam has analgesic and anti-inflammatory effect and it has been proven successful in the control of the post-surgery pain after the removal of the impacted mandibular third molars. Calvo et al. examined the effectiveness of the Meloxicam in 15 and 7.5 mg doses and found significantly better results using higher Meloxicam dose⁸. They determined that the higher dose of Meloxicam should be recommended when the oral surgical procedure includes osteotomy.

Buyukkurt et al. examined the effect of the individual intramuscular doses of Prednisolone and the combination of Prednisolone-Diclofenac therapy on the post-surgery pain, trismus and edema after the surgical removal of the impacted mandibular third molar⁹. Their study proved that the combination of Prednisolon-Diclofenac was better for the pain suppression in comparison with the control group ($p < 0.05$). Schultze-Mosgau et al. tested the combined therapy with nonsteroidal analgesic Ibuprofen and corticosteroid Methylprednisolone for swelling and pain¹⁰. The Efficiency of 32 mg of corticosteroid Methylprednisolone for swelling and pain administered 12 hours before and after surgical treatment in combination with 400 mg of nonsteroidal anti-inflammatory analgesic Ibuprofen a day after the surgery and two following days after the removal of the impacted mandibular third molar was tested in that research. Authors concluded that the combined therapy with Ibuprofen and Methylprednisolone caused good analgesia and anti-inflammatory activity. Bamgbose et al. compared the mutual effect of the corticosteroid Dexametazon and the nonsteroidal anti-inflammatory analgesic Diclofenac K with the individual effect of the nonsteroidal anti-inflam-

matory analgesic Diclofenac K¹¹. The combined therapy with corticosteroids and nonsteroidal anti-inflammatory analgesics had a stronger impact on the decrease of pain and post-surgery swelling even after 48 hours ($p < 0.05$) compared to individual nonsteroidal anti-inflammatory analgesic.

REFERENCES

1. NORHOLT SE, Int J Oral Maxillofac Surg, 27 (1998) 1. — 2. MECHAN R, SEYMOUR A, Br J Oral Maxillofac Surg, 31 (1993) 360. — 3. AOKI T, YAMAGUCHI H, NAITO H, SHIHIKI K, IZAWA K, OTA Y, SAKAMOTO H, KANEKO A, Int J Oral Maxillofac Surg, 35 (2006) 613. — 4. BUFALARI A, ADAMI C, ANGELI G, SHORT CE, Veterinary Research, 31 (2007) 55. — 5. MERSKEY H, WATSON GD, Pain, 7 (1979) 271. — 6. POZOS-GUILLEN A, MARTINEZ-RIDER R, AGUIRRE-BANUELOS P, PEREZ-URIZAR J, Proc West Pharmacol Soc, 48 (2005) 61. — 7. POZOS-GUILLEN A, MARTINEZ-RIDER R, AGUIRRE-BANUELOS P, PEREZ-URIZAR J, J Oral Maxillofac Surg, 65 (2007) 1315. — 8. CALVO AM, SAKAI VT, GIGLIO FPM, MODENA KCS, Int J Oral Maxillofac Surg, 36 (2007) 26. — 9. BUYUKKURT MC, GUNGORMUS M, KAYA O, J Oral Maxillofac Surg, 64 (2006) 1761. — 10. SCHULTZE-MOSGAU S, SCHMELZEISEN R, FROLICH JC, SCHMELE H, J Oral Maxillofac Surg, 53 (1995) 2. — 11. BAMGBOSE BO, AKINWANDE JA, ADEYEMO WL, LADEINDE AL, AROTIBA GT, OGUNLEWE MO, Head Face Med, 1 (2005) 11. — 12. PETRICEVIĆ N, CELEBIĆ A, PAPIĆ M, RENER-SITAR K, Coll Antropol, 33 (2009) 841. — 13. RENER-SITAR K, CELEBIĆ A, STIPETIĆ J,

The results of the present study are in line the above mentioned studies. The pain supression (releif) after the impacted third mandibular molar removal the combined therapy with nonsteroidal anti-inflammatory analgesic drugs and corticosteroids (Medrol and Melox Forte) is superior to monotherapy with each of the mentioned drugs.

MARION L, PETRICEVIĆ N, ZALETEL-KRAGELJ L, Coll Antropol, 32 (2008) 513. — 14. RENER-SITAR K, PETRICEVIĆ N, CELEBIĆ A, MARION L, Croat Med J, 49 (2008) 536. — 15. ZLATARIĆ DK, CELEBIĆ A, Int J Prosthodont, 21 (2008) 86. — 16. CELEBIĆ A, KNEZOVIĆ-ZLATARIĆ D, PAPIĆ M, CAREK V, BAUCIĆ I, STIPETIĆ J, J Gerontol A Biol Sci Med Sci, 58 (2003) M948. — 17. CELEBIĆ A, KNEZOVIĆ-ZLATARIĆ D, J Dent, 31 (2003) 445. — 18. CELEBIĆ A, VALENTIĆ-PERUZOVIĆ M, STIPETIĆ J, DELIĆ Z, STANIĆIĆ T, IBRAHIMAGIĆ L, Coll Antropol, 24 (2000) 71. — 19. STIPETIĆ J, CELEBIĆ A, JEROLIMOV V, VINTER I, KRALJEVIĆ S, RAJIĆ Z, Coll Antropol, 24 (2000) 25. — 20. RENER-SITAR K, CELEBIĆ A, PETRICEVIĆ N, PAPIĆ M, SAPUNDZHIEV D, KANSKY A, MARION L, KOPAC I, ZALETEL-KRAGELJ L, Coll Antropol, 33 (2009) 1177. — 21. KNEZOVIĆ ZLATARIĆ D, CELEBIĆ A, VALENTIĆ-PERUZOVIĆ M, JEROLIMOV V, PANDURIĆ J, J Oral Rehabil, 30 (2003) 847. — 22. ZLATARIĆ DK, CELEBIĆ A, Int J Prosthodont, 14 (2001) 423. — 23. ZLATARIĆ DK, CELEBIĆ A, VALENTIĆ-PERUZOVIĆ M, J Periodontol, 73 (2002) 137. — 24. TROMBELLI L, MINENNA P, FRANCESCHETTI G, MINENNA L, FARINA R, J Periodontol, 81 (2010) 158.

N. Petričević

University of Zagreb, School of Dental Medicine, Department of Removable Prosthodontics, Gundulićeva 5,
10000 Zagreb, Croatia
e-mail: petricevic@sfzg.hr

SMANJENJE BOLA NAKON VAĐENJA IMPAKTIRANOG DONJEG UMNJAKA OVISNO O VRSTI MEDIKAMENTOZNE TERAPIJE

SAŽETAK

Svrha rada je uporediti utjecaj kombinirane terapije nesteroidnim antiinflamatornim analgeticima i kortikosteroidima i monoterapije istim lijekovima na otklanjanje post-operativnog bola nakon kirurškog zahvata: vađenja impaktiranog donjehg umnjaka. Rad je napravljen u Zavodu za Oralnu kirurgiju, Odjela za Stomatologiju, Instituta za zdravlje Zenica u Zenici, BiH. Uključeno je 60 pacijenata oba spola podijeljenih u 3 grupe. Dobni raspon bio je od 18 do 45 godina. Nitko od ispitanika nije imao/la bolne ili upalne senzacije neposredno prije kirurškog zahvata. Dva lijeka prepisana su nakon zahvata: 15 mg nesteroidnog anti-inflamatornog analgetika (Meloxicam, Bosnalijek, BiH) i 32 mg Methylprednisolone (kortikosteroid, Bosnalijek, BiH). Oba lijeka uzeta su *per os* prema shemi protokola. Razina post-kirurške boli evaluirana je pomoću vizualno-analogne skale (VAS) od 1 do 10. Statistika je obuhvatila analizu: One way ANOVA i Tuckey post-hoc testove. Statistički značajna razlika ($p < 0,05$) nađena je između ispitanika tretiranih mono-terapijom i ispitanika tretiranih kombiniranom terapijom. Rezultati ovog istraživanja ukazuju da je mono terapija samo kortikosteroidima ili samo nesteroidnim protuupalnim lijekovima manje je efikasna od kombinirane terapije kortikosteroidima i protuupalnim nesteroidnim lijekovima nakon vađenja impaktiranog donjeg umnjaka.