

Henoch-Schönlein Purpura Complicated by Appendicitis, Intussusception and Ureteritis

Mladen Jašić¹, Mirna Šubat-Dežulović², Harry Nikolić³, Nives Jonjić⁴, Koraljka Manestar² and Matko Dežulović⁵

¹ Pula General Hospital, Department of Pediatrics, Pula, Croatia

² University of Rijeka, Rijeka University Hospital Center, Department of Pediatrics, Rijeka, Croatia

³ University of Rijeka, Rijeka University Hospital Center, Department of Child Surgery, Rijeka, Croatia

⁴ University of Rijeka, School of Medicine, Department of Pathology, Rijeka, Croatia

⁵ Specialized Hospital for Orthopedics and Trauma, Schwarzenbruck, Bayern, Germany

ABSTRACT

Henoch-Schönlein purpura (HSP) is the most common childhood systemic small-vessel vasculitis with skin, joint, gastrointestinal (GI) and renal involvement. Uncommon GI complications are intussusception, bowel perforation and rarely reported appendicitis. HSP-associated stenosing ureteritis represents a rare and potentially serious complication. We present a 5-year-old boy with severe and prolonged course of HSP and three very rare complications that occurred sequentially: appendicitis, intussusception and ureteritis. Only three days after admission, he developed clinical signs of acute appendicitis indicating surgical intervention. Histological analysis of excised appendix showed inflammation but without signs typical for vasculitis. Two weeks later, with the recurrence of HSP, he again developed clinical picture of acute abdomen. Ultrasound and radiologic evaluation demonstrated ileo-ileal intussusception and the second laparotomy was undertaken. Histological analysis of the resected bowel tissue showed typical signs of leucocytoclastic vasculitis. In the fourth week of his illness, serial urinalysis showed nephritic urinary sediment indicative of renal involvement. Unexpectedly, control abdominal ultrasound demonstrated mild hydronephrosis of the left kidney, not seen on previous ultrasound evaluations. Undertaken excretory urography and computed tomography (CT) scan showed stenosis of upper/midureter with mild dilation of upper part of the left ureter suggesting unilateral HSP-associated stenosing ureteritis. Eventually, the patient was discharged and closely followed-up for the next two years. He had no further recurrence of HSP, the urinalysis normalized after six months, while mild unilateral hydronephrosis remained unchanged. Our search of the literature did not show reports of HSP complicated by appendicitis, intussusception and ureteritis, and to our knowledge this is the first case with three different illness events that occurred sequentially. We emphasize the necessity of repeated ultrasound evaluations in the course of HSP, especially in cases with severe GI and renal involvement.

Key words: Henoch-Schönlein purpura, appendicitis, intussusception, ureteritis

Introduction

Henoch-Schönlein purpura (HSP) is acquired, most common systemic small-vessel vasculitis that mainly affects skin, joints, gastrointestinal tract and kidney. It can affect any organ including lungs, gonads and central nervous system¹. Gastrointestinal (GI) manifestations range from mild to colicky abdominal pain and are commonly associated with occult bleeding or less common haematochezia and melena. Severe abdominal pain often necessitates surgical consultation for evaluation of possible

intussusception, bowel perforation or rarely reported acute appendicitis²⁻⁷. Renal involvement usually occurs after the onset of other symptoms, ranging from mild hematuria to overt nephritis and contrary to other manifestations of HSP, persistent renal impairment may occur¹. HSP-associated stenosing ureteritis represents a rare complication of affecting lower urinary tract⁸⁻¹⁰. The symptoms of stenosing ureteritis are typically severe but may be masked by renal and GI symptoms⁸ or as re-

ported, ureteritis may be diagnosed incidentally⁹. Despite surgical interventions in some reported cases, stenosing ureteritis has an uncertain prognosis¹⁰.

In the past few years, ongoing controversy concerns the treatment of HSP and its complications. Contrary to unpredictable success of steroids shown to date in improving long-term renal outcome^{11,12}, anecdotal evidence and limited number of retrospective studies advocate steroids in resolving abdominal symptoms, even capable in preventing surgery interventions^{13,14}. However, in patients with clinical picture of acute abdomen, especially those with intussusception, surgical intervention is unconditionally indicated and life saving¹⁴. Our search of the literature showed very rare reports of HSP complications including appendicitis, intussusception and ureteritis. To our knowledge, this is the first case of HSP with three very complications that occurred sequentially in a single patient.

Case Report

A 5-year old boy was admitted to the hospital with a purpuric rash affecting lower limbs and gluteal region, with edema and tenderness of right hand and both ankles. Except for three day history of fever, his previous medical history was unremarkable. At admission, he had typically distributed purpuric rash and joint involvement, temperature 37.5°C and clinically evident signs of the upper respiratory tract infection. Laboratory tests showed slightly elevated C-reactive protein (CRP) 39.5 mg/L and white blood cells (WBC) $15.1 \times 10^9/L$, but normal hemoglobin and platelets counts. Serum electrolytes, glucose, blood urea nitrogen, creatinine, coagulation tests, serum protein electrophoresis and serum immunoglobulins including IgA were all normal. Initially, he was treated with non-steroidal-anti-inflammatory-drugs, recommended to rest and because of diagnosed rhinosinusitis he got antibiotics (cefuroxim). On day 3rd, he

started vomiting and complaining of abdominal pain, his abdomen was meteoristic and palpatory painful. Abdominal x-rays and ultrasonography showed no pathology. However, due to the clinical picture of acute abdomen, consultant surgeon recommended explorative laparotomy and appendectomy was performed. Histological analysis of excised appendix showed inflammatory cells but without fibrinoid necrosis which is a typical sign of leucocytoclastic vasculitis. On the second postoperative day, as new eruptions of purpuric rash were observed, corticosteroid therapy was initiated (methylprednisolone 2 mg/kg/day). In the next ten days his condition gradually improved; skin lesions disappeared and steroids were withdrawn. Only three days later, he started to complain of colicky abdominal pain, followed by the reappearance of new purpuric skin lesions and haematochesia a day after. The treatment with steroids was restarted, and in the next few days he felt better. At that time, control abdominal ultrasounds did not show any pathology and urinalysis was normal. Then suddenly, on day 21st, he developed the clinical picture of acute abdomen. On examination, he was lethargic, mildly dehydrated with distended abdomen. Control WBC was $42,39 \times 10^9/L$ (90% of neutrophils). Undertaken abdominal x-rays showed distention with air-liquid levels in the bowel indicating ileus. The control ultrasound showed dilatation and thickening of the bowel wall with suspected focal bowel mass like »pseudo-kidney« structure suggestive of ileo-ileal intussusception. After the consultation with the surgeon, the patient was transferred to the tertiary care pediatric center where he underwent the second laparotomy. An ileo-ileal type intussusception was found and since it was not possible to desinvaginate it manually, a partial bowel resection (19 cm) with termino-terminal anastomosis was performed. Histological analysis of resected bowel wall sho-

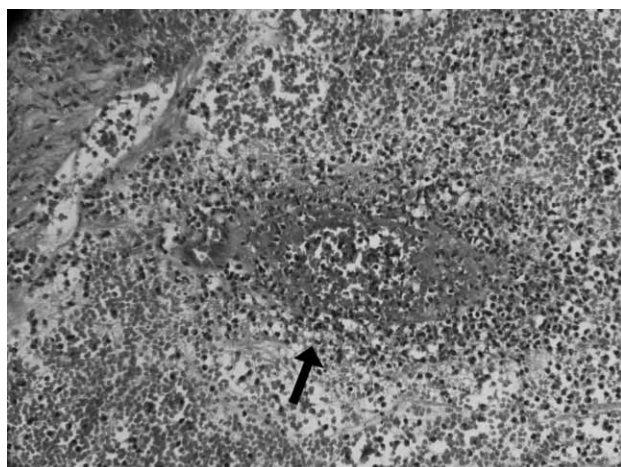


Fig. 1. The bowel wall blood vessel (arrow) with fibrinoid necrosis and neutrophilic infiltrations conclusive of leucocytoclastic vasculitis (H&E, x150).

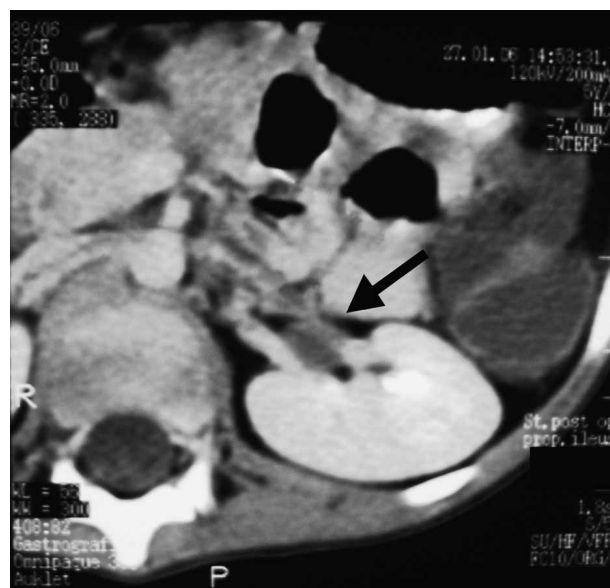

Fig. 2. Abdominal CT scan showing the dilated upper part of left ureter (arrow). Extraureteral obstruction is excluded.

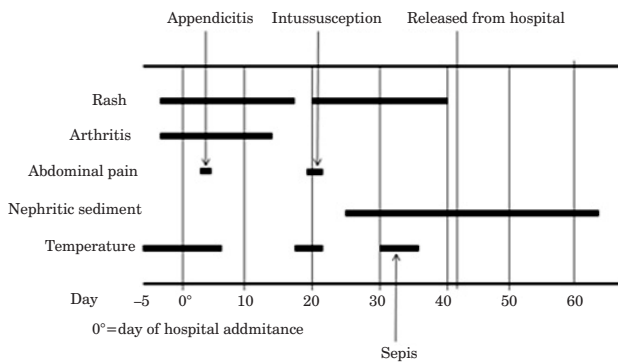


Fig. 3. Clinical course of our patient with HSP complicated by appendicitis, intussusception and unilateral ureteritis.

wed typical signs of leucocytoclastic vasculitis (Figure 1). Following the second laparotomy, within the next week, his condition was further complicated by fever, vomiting and abdominal pain. Laboratory test showed elevated ESR 61 mm/h and CRP 64 mg/L but normal WBC $10.6 \times 10^9/L$. Because of isolated *Enterobacter agglomerans* from haemoculture, postoperative septicaemia was presumed and he was treated with antibiotics (meropenem, metronidazol, netilmycin). However, in the same time, urinalysis showed typical nephritic sediment with 1+ protein and 3+ blood, large number of red blood cells (RBC), a few leucocytes and several RBC, coarse granular and hyaline casts, suggesting the development of HSP nephritis. Except for typical nephritic urine sediment, he had no hypertension, blood urea nitrogen (3.6 mmol/L) and serum creatinine (64 $\mu\text{mol/L}$) were normal, and his diuresis remained unchanged. Unexpectedly, control abdominal ultrasound showed on longitudinal scan 10 mm dilatation of left pyelon suggesting mild hydronephrosis of the left kidney, which was not seen on previous ultrasound exams. Undertaken excretory urogram studies showed left stenosis of upper/midureter confirmed by computed tomography (CT) scan showing mild dilatation of the left upper ureter (Figure 2). Based on CT-scan findings, without demonstrated intrinsic or extrinsic cause of obstruction, the diagnosis of unilateral stenosing ureteritis was made.

Eventually, our patient's condition improved and on 41st day of hospitalization he was released from hospital. He was closely followed up for the next two years, his urinalysis normalized after six months, while mild unilateral hydronephrosis remained unchanged. Clinical course of our patient with three very rare complications that developed sequentially including appendicitis, intussusception and HSP-associated ureteritis are summarized in Figure 3.

Discussion

Recently proposed diagnostic criteria for HSP include palpable purpura as a mandatory criterion with at least one other manifestation: abdominal pain, IgA deposition,

arthritis or arthralgia, or renal involvement¹⁵. Our presented case of a 5-year-old boy with severe and prolonged course of HSP fulfills all the proposed criteria. In addition, he had three very rare complications that developed sequentially: appendicitis, intussusception and unilateral ureteritis. The prolonged course of his illness was first, complicated by appendicitis, and two weeks later by intussusception, in both situations indicating unconditionally urgent surgical intervention. The third complication was an unexpected finding of mild hydronephrosis with stenosis of left upper/midureter determined by ultrasonography, excretory urography and CT-scan suggesting HSP-associated unilateral stenosing ureteritis.

There are several points to discuss. Gastrointestinal manifestations of HSP occur in 35–70% of cases, ranging from mild to colicky abdominal pain and are commonly associated with occult bleeding or less common haematochesia and melena^{2,7,16}. Major GI complications that develop in about 5 to 10% of patients include intussusception, perforation, intestinal haemorrhage and rarely reported appendicitis^{3–6}. Simultaneous occurrence of appendicitis in patients with HSP is extremely rare as reported in only a few cases with documented fibrinoid necrosis and immunoglobulin A deposits in excised appendix^{3–5}. In the past it was not uncommon for patients with HSP and colicky abdominal pain to undergo unnecessary laparotomy. Delayed diagnosis or misdiagnosis nowadays should not be a problem based on ultrasonography that can demonstrate distended appendix surrounded by hyperechoic inflamed fat⁴. In our case, however, despite normal findings on abdominal ultrasound, consultant surgeon indicated explorative laparotomy. Histological analysis of excised appendix confirmed inflammation but without fibrinoid necrosis which is a typical signs of leucocytoclastic vasculitis. Unfortunately, as immunohistochemical analysis was not done^{6,17}, we may speculate that appendicitis was a random event ethiologically not associated with vasculitis.

Second GI complication that developed in our patient was ileo-ileal type intussusception. As reported, intussusception is a rare complication occurring in up to 5% of patients with HSP^{2,7,13,16}. However, intussusception is the most common indication for surgical intervention^{14,16}. Ultrasonography has proved valuable in diagnosing intraabdominal pathology in patients with HSP, sensitive enough to distinguish bowel wall edema, bowel dilatation, ileus and intussusception^{18–20}. In our patient, the diagnosis of ileo-ileal type intussusception was based on repeated abdominal X-ray and ultrasound indicating urgent surgical intervention. Histological analysis showed signs of leucocytoclastic vasculitis conclusive with the etiology of intussusception associated with HSP.

The third complication that developed in our patient was suspected unilateral stenosing ureteritis and found incidentally. Control ultrasound undertaken following the second laparotomy, in the course of postoperative septicemia and nephritis demonstrated mild hydronephrosis of the left kidney not shown on previous examinations. As demonstrated by imaging studies, stenosis of

upper/midureter with dilatation of the left upper ureter and without demonstrated cause of obstruction suggested HSP-associated ureteritis. HSP-associated ureteritis is a very rare complication of the lower urinary tract⁸. It is the consequence of periuretral vasculitis with ureter wall ischemia and usually diagnosed by imaging studies⁹ and represents a rare complication of HSP, typically presenting with severe manifestations and not uncommonly, in certain situations necessitating urological interventions¹⁰. A recently reported review of stenosing ureteritis in twenty reported cases shows that macrohaematuria and colicky abdominal or flank pain were present in half of the patients with a random finding masked by severe GI or renal symptoms in others. Beside recommended steroid treatment, almost half of the reported cases underwent surgical interventions. The outcome remission was achieved in two thirds of patients with residual hydronephrosis and poor renal function in one third of cases⁸. The diagnosis of HSP-associated stenosing ureteritis is based on imaging studies that should be applied regularly as the true incidence and spectrum of this complications remains unknown.

HSP is a self-limited disease. Skin and joint manifestations of HSP necessitates only symptomatic treatment including pain control and adequate hydration. Acute gastrointestinal^{2-7,21}, renal^{8,13,14,15,22,29}, and other complications²³⁻²⁶ need to be immediately evaluated so that the correct treatment modality can be applied²⁷⁻³¹. There is a lot of controversy in the management of acute HSP complications.

Contrary to unproven benefit of steroid therapy in preventing renal manifestations of HSP, in cases with

overt nephritis the use of steroids is supported in addition to other immunosuppressive agents and plasmapheresis^{11,12,29-31}. As the renal involvement in HSP is quite variable, with the majority of patients demonstrating spontaneous resolution, treatment strategies including steroids are based on a risk of progressive and long-term renal morbidity.

Anecdotal evidence and limited number of retrospective studies advocate steroids in resolving abdominal symptoms. The improvement of acute gastrointestinal symptoms may be achieved by pulse intravenous methylprednisolone^{1,13,15}. Although steroids may prevent GI complications, surgical intervention unconditionally has the exact importance in cases with clinical picture of acute abdomen^{4,14}. As presented, steroid therapy started after appendectomy in our patient with the recurrence of purpura and colicky abdominal pain did not prevent the development of intussusception indicating surgical intervention as the life-saving treatment modality.

Conclusions

HSP is a self-limited disease often associated with various complications, especially with GI and renal involvement. As clinical features may mislead the clinicians, serial physical, ultrasonographic and radiologic examinations are needed to diagnose the conditions necessitating surgery intervention. There is evidence that steroid therapy at the onset of the disease does not prevent renal but may prevent GI complications. However, surgical intervention unconditionally has the exact importance in cases with clinical picture of acute abdomen.

REFERENCES

- MILLER ML, PACHMAN LM, Vasculitis syndromes. In: KLEIGMAN RM, BEHRMAN RE, JENSON HB, STANTON BF (Eds) Nelson Textbook of Pediatrics (Saunders, Philadelphia, 2007). — 2. CHOONG CK, BEASLEY SW, *J Paediatr Child H*, 34 (2002) 405. — 3. BINSTADT BA, FLEEGLER EW, *J Paediatr Surg*, 40 (2005) 24. — 4. KIM CJ, CHUNG HY, KIM SY, KIM YO, RYU SY, KIM JC, CHUNG JH, *J Korean Med Sci*, 20 (2005) 899. — 5. JANGJOO A, AMOUZESHI A, JALALI AN, *J Paediatr Surg*, 43 (2008) 33. — 6. OHNO Y, OHGAMI H, *Paediatr Surg Int*, 10 (1995) 563. — 7. EBERT EC, *Dig Dis Sci*, 53 (2008) 2011. — 8. SIMOU E, SERVIS A, SALAKOS C, PAPAPOPOULOU F, STEFANIDIS CJ, SIAMOPOULOU A, *Paediatr Nephrol*, 23 (2008) 821. — 9. GRADY BRUCE R, BISHOF NA, JACKSON EC, SKINKER DM, McROBERTS JW, *Paediatr Nephrol*, 11 (1997) 347. — 10. SOREIDE K, *J Paediatr Surg*, 40 (2005) 1243. — 11. ZAFFANELLO M, FANOS V, *Paediatr Nephrol*, 24 (2009) 1901. — 12. BOGDANOVIĆ R, *Acta Paediatr*, 98 (12) (2009) 1882. — 13. WANG L, HUANG FC, KO SF, CHENG MT, *Clin Rheumatol*, 22 (2003) 140. — 14. MIR E, *Z Kinderchir*, 43 (1988) 391. — 15. OZEN S, RUPERTO N, DILON MJ, BAGGA A, BARRON K, DAVIN JC, KAWASAKI T, LINDSLEY C, PETTY RE, PRIEUR AM, RAVELLI A, WOO P, *Ann Rheum Dis*, 65 (2006) 936. — 16. CHANG WL, YANG YH, WANG LC, LIN YT, CHIANG

- BL, *Acta Paediatr*, 93 (2004) 1473. — 17. ŠUBAT-DEŽULOVIC M, KNEZIC I, PERŠIĆ M, GLIGORA M, *Period Biol*, 90 (1988) 478. — 18. SITI KAMARIACH CM, ROHAIZAN Y, *IMJ*, 8 (2009) 37. — 19. HU SC, FEENEY MS, MCNICHOLAS M, O'HALPIN D, FITZGERALD RJ, *Arch Dis Child*, 66 (1991) 1065. — 20. NCHIMI A, KHAMIS J, PAQUOT I, BURY F, MAGOTTEAUX P, *J Paediatr Gastroenterol Nutr*, 46 (2008) 48. — 21. PERŠIĆ M, LEKOVIĆ A, ŠUBAT-DEŽULOVIC M, *Gastroenterohepatol Arh*, 5 (1986) 24. — 22. ŠUBAT-DEŽULOVIC M, PERŠIĆ M, ŠČUKANEC-ŠPOLJAR M, *Liječ Vjes*, 118 (1996) 26. — 23. AL-HARBI NN, *Paediatr Nephrol*, 17 (2002) 762. — 24. DAVID S, SCHIFF JD, POPPAS DP, *Urology*, 61 (2003) 1035. — 25. DAVOL P, MOWAD J, MOWAD CM, *Cutis*, 77 (2006) 89. — 26. HA TS, LEE JS, *Acta Paediatr*, 96 (2007) 552. — 27. PAVLOVIC M, RADLOVIC N, LEKOVIĆ Z, BERENJI K, NOVAK A, *Srp Arh Celok Lek*, 135 (2007) 208. — 28. GEDALIA A, *Curr Rheumatol Rep*, 6 (2004) 195. — 29. BAYRAKCI US, TOPALOGLU R, SOYLEMEZOGLU O, KALYONCU M, OZEN S, BESBAS N, BAKKALOGLU A, *J Nephrol*, 20 (2007) 406. — 30. HUBER AM, KING J, MCLAIN P, KLASSEN T, POTHOS M, *BMC Med*, 2 (2004) 7. — 31. RONKAINEN J, KOSKIMIES O, ALA-HOUHALA M, ANTIKAINEN M, MERENMIES J, RAJANTIE J, ORMALA T, TURTIENEN J, NUUTINEN M, *J Paediatr*, 149 (2006) 241.

M. Jašić

*Pula General Hospital, Department of Pediatrics, Zagrebačka 30, 52100 Pula, Croatia
e-mail: mladen.jasic@gmail.com*

APENDICITIS, ILEUS I URETERITIS KAO KOMPLIKACIJE PURPURE HENOCH-SCHÖNLEIN

S A Ž E T A K

Purpura Henoch-Schönlein (HSP) je najčešći sistemski vaskulitis malih krvnih žila dječje dobi. Zahvaća kožu, zglobove, gastrointestinalni (GI) sustav te bubrege. Ileus, perforacija stijenke crijeva i masivno krvarenje iz probavnog trakta su izuzetno rijetke komplikacije, a izvanredno rijetko, u sklopu bolesti može se razviti i apendicitis. Među renalnim komplikacijama HSP, vrlo rijetko opisuje se steozirajući ureteritis. Prikazan je petogodišnji dječak sa iznimno ozbiljnim i dugotrajnim tijekom HSP i postepenim razvojem triju vrlo rijetkih komplikacija: apendicitisa, ileusa i stenozirajućeg ureteritisa. Na početku bolesti, dječak je razvio sliku akutnog abdomena i zbog toga je apendektomiran. Histološka analiza reseciranog apendiksa potvrdila je upalnu reakciju ali bez znakova tipičnih za vaskulitis. Dva tjedna kasnije sa recidivom purpura, dječak je ponovno razvio sliku akutnog abdomena. Ponavljanim ultrazvučnim i radiološkim pretragama utvrđena je ileo-ilealna intususcepcija i bolesnik je po drugi put laparotomiran. Histološka analiza reseciranog crijeva je pokazala tipičnu sliku leukocitoklastičnog vaskulitisa. U daljnjem tijeku bolesti analizom urina potvrđen je razvoj nefritisa. Neočekivano, kontrolnim ultrazvučnim pregledom otkrivena je i dilatacija gornjeg segmenta uretera te blaga hidronefroza lijevog bubrega koja se do tada nije vidjela. CT abdomena potvrdio je dijagnozu unilatarnog stenozirajućeg ureteritisa. Usprkos pojavi triju vrlo rijetkih komplikacija HSP, dječak je konačno otpušten iz bolnice i redovito kontroliran kroz naredne dvije godine. Tijekom praćenja, dječak nije više imao relapsa HSP, nalaz urina se normalizirao nakon 6 mjeseci, a zaostala je blaža unilaterarna hidronefroza. U literaturi su opisani rijetki slučajevi komplikacija HSP kao što su apendicitis, ileus ili ureteritis, a prema našim saznanjima ovo je prvi slučaj u kojemu su se javile sve tri gore navedene komplikacije, od kojih su intususcepcija i ureteritis nesumnjivo vezani uz anafilaktoidnu purpuru. Naglašavamo važnost ponavljanja ultrasonografskog pregleda u bolesnika sa HSP i izraženim GI i renalnim manifestacijama.