

Gynaecol Perinatol 2009;18(4):169–177

Al Azhar University, Faculty of Medicine, Nasr city, Cairo, Egypt

## **IMAGING THE INTERNAL URETHRAL SPHINCTER AND THE VAGINA IN NORMAL WOMEN AND WOMEN SUFFERING FROM STRESS URINARY INCONTINENCE AND VAGINAL PROLAPSE**

### **PRIKAZ UNUTRAŠNJEG SFINKTERA URETRE I VAGINE U ZDRAVIH ŽENA I OBOLJELIH OD STRES INKONTINENCIJE MOKRAĆE I PROLAPSA VAGINE**

*Abdel Karim M. El Hemaly, Ibrahim M. Kandil, Asim Kurjak, Ahmad G. Serour,  
Laila A.S. Mousa, Amr M. Zaied, Khalid Z. El Sheikha*

*Original paper*

**Key words:** internal urethral sphincter (IUS), three dimension ultrasound (3D-US), magnetic resonance image (MRI), vaginal prolapse, stress urinary incontinence (SUI)

**SUMMARY. Introduction.** The internal urethral sphincter (IUS) is a cylinder formation that extends from the urinary bladder neck to the urogenital diaphragm. It is composed of a strong collagen sheet with muscle fibers that intermingle with the collagen in the middle of the cylinder's thickness. The strong collagen sheet gives the IUS the high wall tension necessary to create the high urethral pressure. The muscle fibers, innervated by alpha sympathetic nerves (T10-L2) are responsible for closure and opening the urethra. Urinary continence depends on the presence of an intact and strong IUS and of an acquired behavior, gained by learning and training in early childhood, how to maintain a high alpha sympathetic tone at the IUS keeping it closed until there is a need. Normal vagina is a cylinder of collageno-elastic-muscular tissues. Its strong collagen sheet is responsible for keeping it in its normal upward position. Labors cause redundancy and weakness of the vaginal walls with subsequent prolapse and lacerations of the IUS which is intimately overlying the anterior vaginal wall resulting in stress urinary incontinence (SUI). **Objectives.** To image by 3D-US and MRI the IUS and the vagina; and to examine their histopathology. **Methods.** Histopathology as well as 3D-US and MR imaging are done. **Results.** Images show the IUS as a compact tissue cylinder that extends from the bladder neck to the urogenital diaphragm in continent women; IUS is torn in women with SUI. **Conclusion.** The anterior vaginal wall and the IUS are torn in patients with SUI and with vaginal prolapse. They are intact in continent women.

*Izvorni članak*

**Ključne riječi:** unutrašnji uretralni sfinkter (IUS), trodimenzionalni ultrazvuk (3D-UZ), magnetska rezonancija (MR), prolaps vagine, stresna inkontinencija mokraćne (SUI)

**SAŽETAK. Uvod.** Unutrašnji uretralni sfinkter (IUS) je cilindričnog oblika, proteže se od vrata mokraćnog mjegura do urogenitalne dijafragme. Sastoji se od čvrstog kolagenog sloja s mišićnim vlaknima koja su izmiješana s kolagenom u sredini debljine cilindra. Jaki kolageni sloj daje IUS-u snažnu napetost stijenke potrebnu da stvori visoki intrauretralni tlak. Mišićna vlakna, inervirana alfa simpatičnim živcima (Th10-L2) su odgovorna za zatvaranje i otvaranje uretre. Kontinencija mokraćne ovisi o postojanju intaktnog i jakog IUS-a te o stečenom ponašanju, učeći i vježbajući u ranom djetinjstvu kako održati visoki alfa simpatički tonus IUS-a, držeći ga zatvorenim dok je potrebno. Normalna vagina je cilindrična cijev kolageno-elastično-mišićnog tkiva. Njen jaki kolageni sloj je odgovoran za njen uspravni položaj. Porod uzrokuje suvišak i slabost vaginalne stijenke s posljedičnim prolapsom i laceracijom IUS-a, koji intimno prileži prednjoj vaginalnoj stijenci, što rezultira stresnom mokraćnom inkontinencijom (SUI). **Cilj istraživanja.** Prikazati trodimenzionalnim ultrazvukom (3D-UZ) i magnetskom rezonancijom (MR) te histopatološkim pregledom intrauretralni sfinkter i vaginu. **Metode.** Histopatološka tehnika te 3D-UZ i MR prikazi. **Rezultati.** Prikazi pokazuju IUS kao kompaktni tkivni cilindar koji se proteže od vrata mokraćnog mjehura do urogenitalne dijafragme u kontinentnih žena; IUS je oštećen u žena sa SUI. **Zaključak.** Prednja vaginalna stijenka i IUS bivaju oštećeni (prsnuti) u pacijentica sa SUI i s vaginalnim prolapsom. Oni su intaktni u kontinentnih žena.

**Introduction**

The internal urethral sphincter (IUS), as all sphincters in the body, is described as a muscular ring. It lies at the urinary bladder neck. Some deny its importance in keeping urinary continence with no general agree-

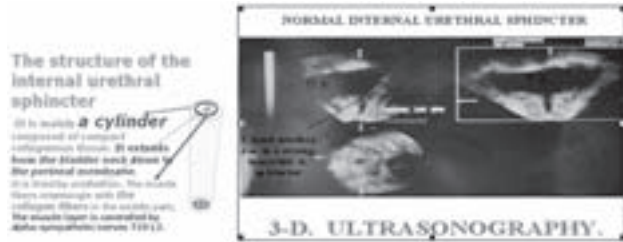

Figure 1. 3D-US pictures. A normal internal urethral sphincter on the left and a normal intact and strong internal urethral sphincter on the right. Slika 1. 3D-UZ slike. Normalni unutrašnji uretralni sfinkter lijevo i normalni intaktni čvrsti unutrašnji uretralni sfinkter desno.

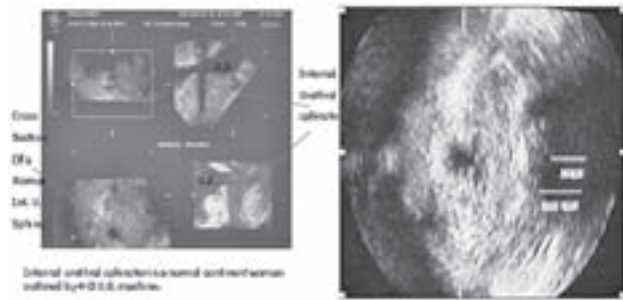


Figure 2. An intact and strong internal urethral sphincter, as seen by integrated 3-4 D US picture. The cross section showing 2 echoes overlapping in the midthickness of the cylinder, with a closed urethral lumen. Slika 2. Intaktni i čvrsti unutrašnji uretralni sfinkter, prikazan integriranim 3-4D ultrazvukom. Poprečni prerez prikazuje dva odjeka koji se preklapaju u središnjem zadebljanju cilindra sa zatvorenim uretralnim lumenom.

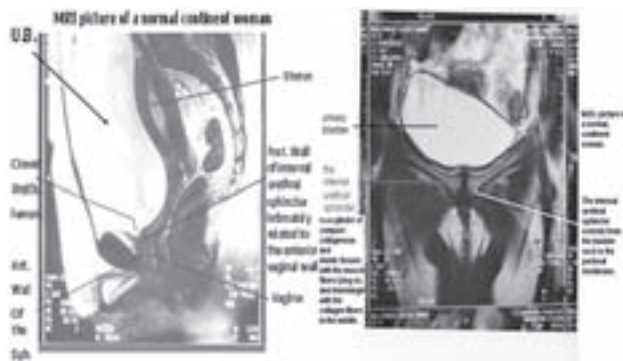


Figure 3. MRI pictures. Sagittal, and coronal sections showing intact and strong internal sphincters as cylinders extending from the urinary bladder neck to the urogenital diaphragm. MRI picture of a normal continent woman. Although the urinary bladder is extremely full, the internal urethral sphincter is closing the urethra. The internal urethra sphincter (IUS) is seen intimately related to the tough and strong anterior vaginal wall.

Slika 3. MR slike. Sagitalni i koronarni presjek prikazuju intaktni i čvrsti unutrašnji sfinkter u obliku cilindra koji se proteže od vrata mokraćnog mjehura do urogenitalne dijafra gme. MR prikaz normalne kontinentne žene. Unatoč izrazito punog mokraćnog mjehura unutrašnji uretralni sfinkter zatvara uretru. Unutrašnji uretralni sfinkter je u bliskom odnosu sa čvrstom i snažnom vaginalnom stjenkom.

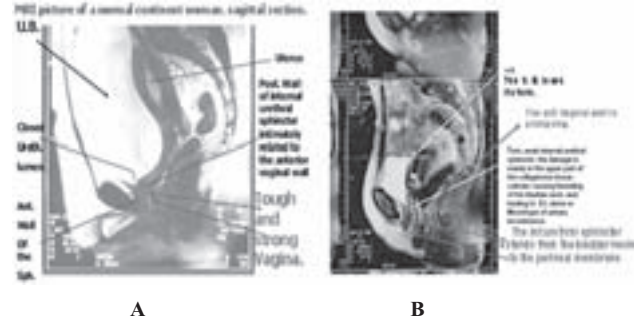


Figure 4. A comparison between normal intact internal sphincter (A) and torn, although keeping its cylindrical form, internal urethral sphincter (B). The rupture is mainly in the upper part leading to funneling of the urinary bladder neck.

Slika 4. Usporedba između normalna intaktnog unutrašnjeg sfinktera (A) i prsnutog sfinktera (B), premda je zadržao cilindrični oblik. Prsnuće je uglavnom u gornjem dijelu, oblikujući ljevjkasti vrat mokraćnog mjehura.

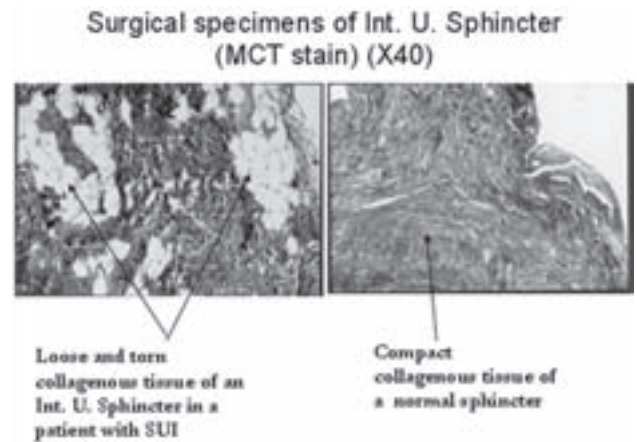


Figure 5. Histopathology of the IUS stained with Masson's trichrome stain, which stains collagen fibers blue or green. Right: a specimen from an intact IUS, with compact collagen fibers is seen; Left: a specimen from a patient with SUI showing torn IUS with loose collagen fibers.

Slika 5. Histopatologija IUS-a obojenog Massonovom trikromnom bojom, koja oboji kolagena vlakna zeleno ili plavo. Desno: primjerak s intaktnim IUS, s kompaktnim kolagenim vlaknima; Lijevo: primjerak pacijentice s mokraćnom stress inkontinencijom, prsnuti IUS je s rastresitim kolagenim vlaknima.

ment which urethral sphincter play the main role in keeping urinary continence.<sup>1,2</sup> Leakage of urine will occur voluntarily or involuntarily whenever the pressure in the bladder exceeds the pressure in the urethra. This apparently simple situation is in reality extremely complex and remains the subject of much debate.

McGuire et al.<sup>1</sup> concluded that the abdominal pressure (Pabd) required to induce the leakage of urine appears to be inversely proportional to urethral weakness. In other words, a normal urethra does not leak at any Pabd achievable, and a very bad urethra leaks at a very low pressure.

A new concept<sup>2-15</sup> is put forward to explain the act of micturition and the factors that control urinary continence. Urinary continence depends on 2 main factors: one inherent and one acquired. The *inherent factor* is the presence of an intact and strong IUS. The *second factor* is an acquired behavior, gained by learning and

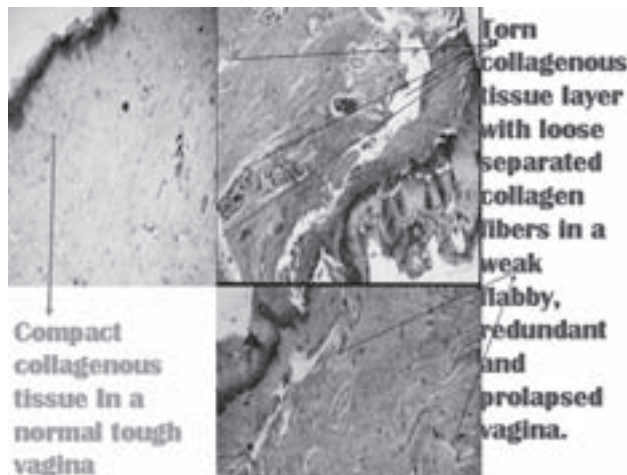


Figure 6. Histopathology of the vagina. Top left is normal tough vagina with compact collagen; the top right and the bottom pictures show loose torn collagen sheet.

Slika 6. Histopatologija vagine. Lijevo gore je čvrsta vaginalna stijenka sa zbijenim kolagenom; gore desno i dolje je stijenka sa slabim, razmaknutim i rastresitim kolagenim slojem.

training in early childhood, how to maintain a high alpha sympathetic tone (T10-L2) at the IUS keeping it closed all the time till there is a need or a desire to void.

The IUS is a compact tissue cylinder that extends from the bladder neck down to the urogenital diaphragm. The IUS is composed of a dense collagen cylinder, lined by urothelium with muscle fibers that lie on and intermingle with the collagen fibers in the middle of the cylinder's thickness. Three dimension ultrasound (3D-US), and magnetic resonance imaging (MRI) show the IUS as a compact tissue cylinder that extends in continent women from the bladder neck down to the urogenital diaphragm (Figures: 1-4). It is intimately overlying the anterior vaginal wall, so that lacerations of the vagina resulting from childbirth trauma will lacerate the IUS causing its weakness. The weak IUS can not withstand sudden rises of abdominal pressure ensuing in SUI. Normal vagina is a cylinder of collageno-elastic-

muscular tissues. Its strong collagen sheet is responsible for keeping the vagina in its normal upward position. Labors, specially prolonged, difficult, and multiple frequent labors cause overstretching of the vagina resulting in redundant, flabby and lacerated vaginal walls with subsequent prolapse. It also causes lacerations of the IUS which is intimately overlying the anterior vaginal wall resulting in a weak IUS with low urethral pressure which can not face sudden rises of abdominal pressure.

It is to say that leakage of urine will occur voluntarily or involuntarily whenever pressure in the urethra drops. This happens physiologically on micturition, voluntarily, through the high central nervous centers inhibiting the high alpha sympathetic tone thus relaxing the IUS and opening the urethra. Involuntarily, urine will leak on stress against a weak torn IUS with a low urethral closing pressure (UCP). Normally the resting urethral pressure is much higher than that of the bladder. It is usually more than 60 cm water in women, higher in men. When the UCP is low, due to weakness of the IUS, leakage of urine would occur on sudden rise of intra-abdominal, intra-vesical pressure. At once a quick reactive sympathetic response would then increase the urethral pressure preventing further leakage of urine.<sup>3,4</sup>

**Objectives:** (1) To demonstrate that there is a high alpha sympathetic tone at the IUS; (2) To show that the IUS is a cylinder that extends from the bladder neck to the urogenital diaphragm; (3) To describe the IUS' structure and its state in continent and incontinent women; (4) To examine the structure of the vagina in normal and prolapsed vaginas.

**Materials and methods**

The study was approved by the local Ethics Committee.

Twenty continent women as a control group and 152 patients suffering from stress urinary incontinence. SUI as proved clinically and by urodynamic studies were chosen for the study.




Figure 7. Postmortem specimens of the normal IUS and vagina: compact collagenous sheet with the muscle fibers lying on top and intermingling with a collagen fibers in the middle of the IUS cylinder's thickness.

Slika 7. Postmortlani primjerci normalnog IUS-a i vagine: zbijeni kolageni sloj s mišićnim vlaknima na vrhu, izmiješani s kolagenim vlaknima u sredini proširenja IUS cilindra.



### Comparison between Int. U. Sphincter in Normal and SUI Patients (H & E) (X40)

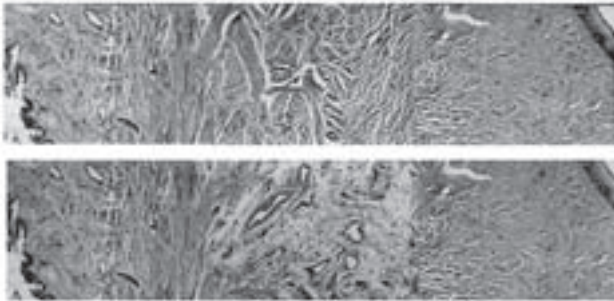


Figure 8. Comparison between an intact IUS (top) and a torn weak IUS (bottom). Post mortem specimens.

Slika 8. Usporedba između intaktnog IUS-a (gore) te prsnutog i slabog IUS-a (dolje). Postmortalni primjerci.

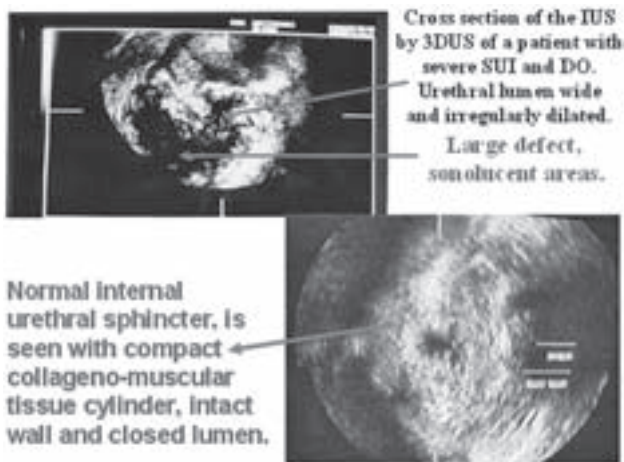


Figure 9. A comparison of a cross sections of a 3D-US picture of the normal intact internal urethral sphincter (right bottom) and of a 3D-US picture of a torn internal urethral sphincter (left above) in a patient who suffers severe stress urinary incontinence: the echo-lucent areas are seen.

Slika 9. Usporedba poprečnih presjeka 3D-UZ prikaza normalnog intaktnog unutrašnjeg uretralnog sfinktera (desno dolje) i 3D-UZ prikaza prsnutog unutrašnjeg uretralnog sfinktera (lijevo gore) u pacijentice s teškom mokraćnom stres inkontinencijom: vide se hipoehogena područja.

All the 152 patients had been evaluated at the urogynaecology clinic. Evaluation included special questionnaire that inquire about lower urinary tract function and its social impact. The questionnaire ended in identifying stress urinary incontinence.

Following recruitment, each patient was asked to keep a voiding diary to assess the severity of the leakage, and to monitor the results in the pre-operative and the post-operative follow up period. Then, physical examination, measurement of any residual urine, urinalysis and tests for bacteriological culture and sensitivity were done, and accordingly treated any infection. Urodynamic studies, namely cystometry, pressure profiles e.g. urethral pressure profile (UPP), stress cysto-urethral pressure profilometry and leak-point pressure were done before surgery and after surgery at the follow up periods.<sup>1</sup>

Three Dimension Ultrasound (3D-US) assessment of the IUS was done for the 20 continent women as control and for each patient of the 152 study cases, using trans-vaginal route and trans-perineal route, by a vaginal probe multi-frequent 5–7.5 MHz Kretz 530 machine and General Electric integrated 3D-4D Unit (GE Kretz) 730 pro machine.

Also MRI was done to compare the normal continent women with no anterior vaginal wall descent to those patients suffering SUI and anterior vaginal wall prolapse.

During surgical repair of SUI and vaginal prolapse by a new operation »Urethro-vaginoplasty«,<sup>15</sup> pieces of tissues 2–3 mm from the IUS and 1–2 cm from the vaginal wall were taken. The tissues were fixed in formalin, then embedded in paraffin and cut into 5 micron sections and stained with: (1) Haematoxylin and Eosin; (2) Masson trichrome stain which stains collagen fibers blue or green, and muscle fibers brown (Figures: 5, 6).

Also, from the general morgue, 15 postmortem specimens of the pelvic organs i.e. urinary bladder, urethra, uterus and upper part of the vagina, were previously obtained. Cases were selected so that 5 of them were with SUI as indicated in their medical records. Gross examination was done and sections were made of the urethra and vagina. Sections were prepared, stained and examined microscopically (Figures 7, 8).

Also a clinical trial was previously done to prove the presence of a high alpha sympathetic tone in the IUS, and to demonstrate the effects of alpha sympathetic blocker drugs e.g. phentolamine (Regitine Novartis, Basle Switzerland) and alpha sympathomimetic drugs e.g. norepinephrine (Levophed, Sanofi Aventis France) on the IUS. It included 15 normal continent volunteers and 15 patients with SUI. Clinical assessment was done for every case, and then urodynamic studies were done, cystometry and UPP. A written consent was taken from every patient and volunteer after explaining the procedure to them. With continuous monitoring of the pulse, BP, and ECG, 5 mg of phentolamine (Regitine) were injected i.v. and other UPP were recorded 5, and 10 minutes later. An i.v. infusion containing 1 mg (1/1000) norepinephrine, (Levophed) in 5% dextrose was started slowly, 5–30 drops/min. and another UPP was recorded immediately after the start of the infusion. The patient received 10–20 mL of the infusion, a dose of 20–40 micrograms of norepinephrine 1/1000.

## Results

Gross and microscopic examination showed that the IUS is a cylinder that is composed of a dense collagen sheet lined by urothelium with muscle fibers that intermingle with the collagen fibers in the middle of the cylinder's thickness. 3D-US and MRI pictures (Figures 1–4), showed the IUS in continent women as a compact tissue cylinder that extends from the bladder neck down to the urogenital diaphragm. The dense collagen tissue gives the IUS the high wall tension needed to create the

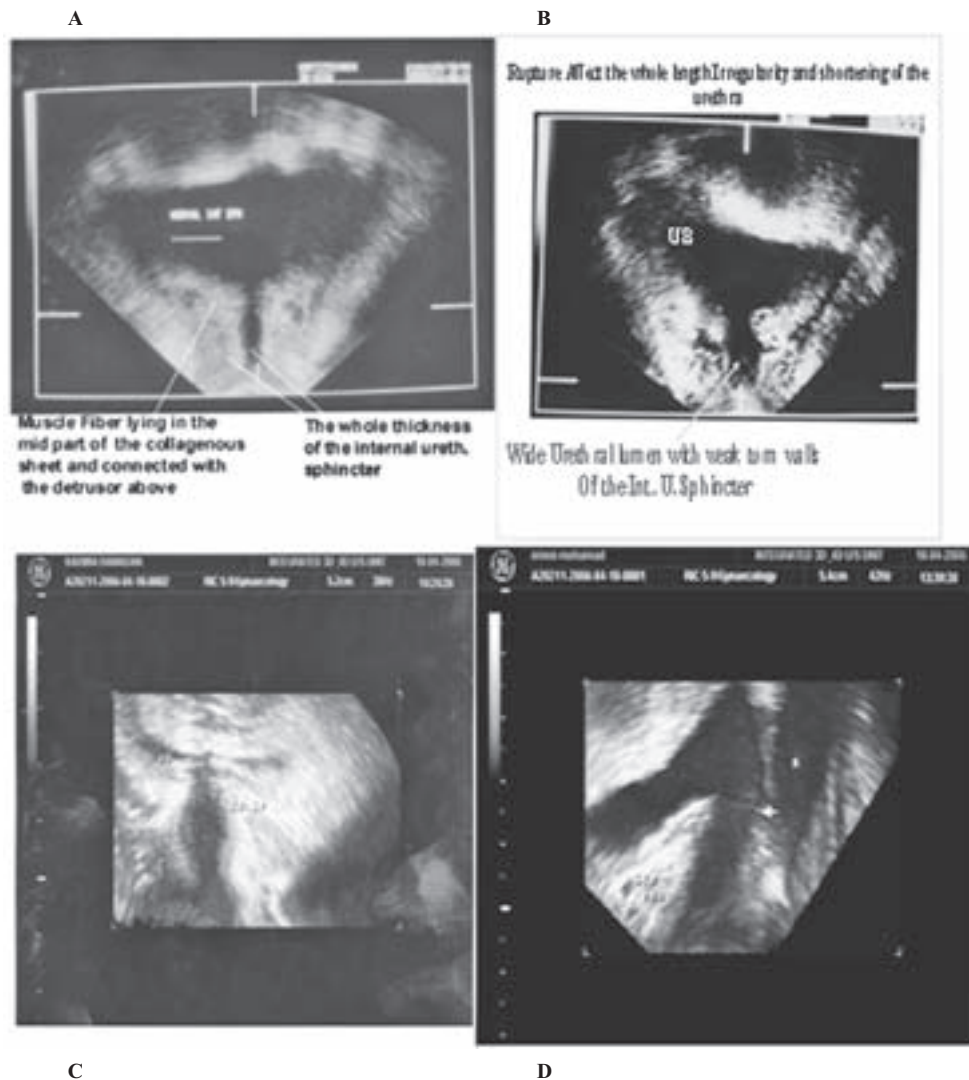


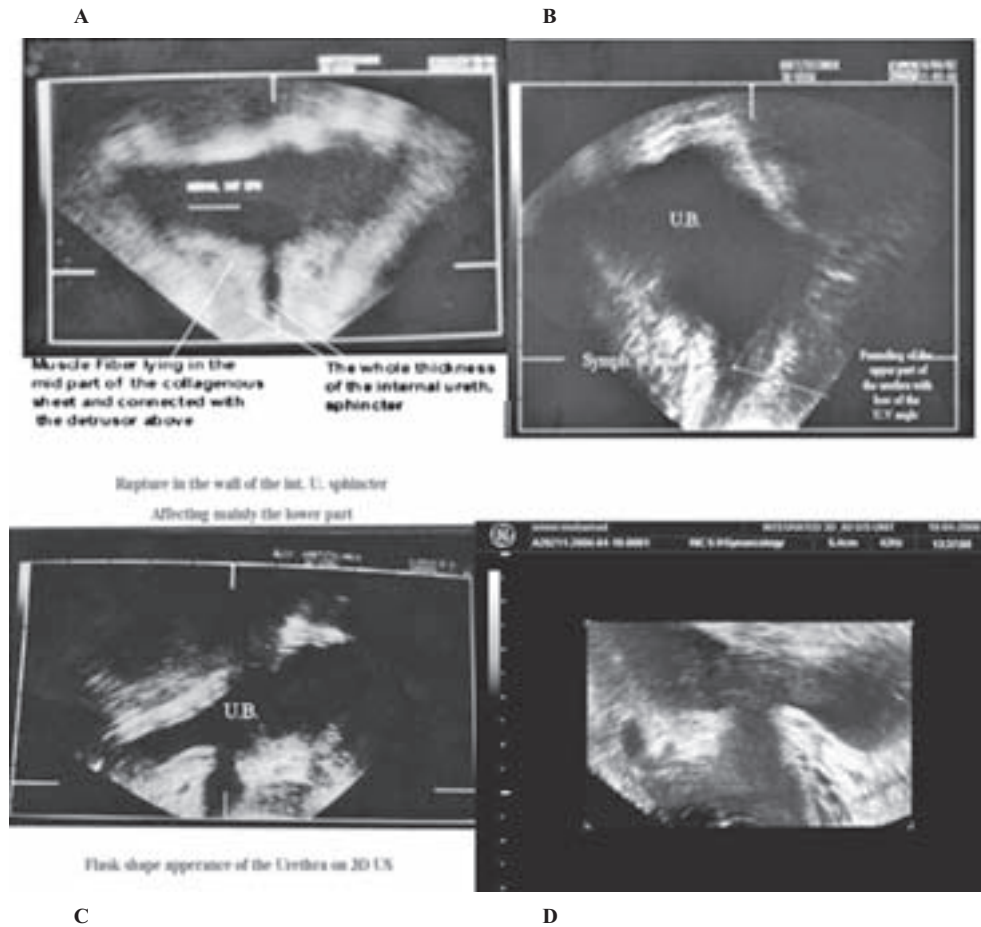
Figure 10. Comparison between an intact internal urethral sphincter (A) and torn sphincters (B, C & D) as seen by 3D-US. (B) Shows the rupture of the whole length, with irregularities of its walls and apparent shortening and collapse; (C) shows the rupture mainly in the lower part with a flask-shape appearance in spite of the rather empty bladder; (D) the rupture is mainly in the upper part with loss of the posterior urethro-vesical angle and funneling of the bladder neck.

Slika 10. Usporedba intaktnog unutrašnjeg uretralnog sfinktera (A) i prsnutih sfinktera (B, C i D) prikazanih 3D-UZ-om. (B) prikazuje rupturu u cijeloj duljini, s nepravilnostima stijenke, jasnim skraćenjem i kolapsom; (C) prikazuje razdor pretežno u donjem dijelu, izgleda tikvice unatoč praznom mjehuru; (D) razdor je pretežno u gornjem dijelu s nestankom stražnjeg uretro-vezikalnog kuta i s ljevkastim vratom mjehura.

high urethral closing pressure (UCP). While the muscle layer, supplied by the alpha sympathetic nerves T10-L2, is the key to closure and relaxation. In patients with SUI, gross and microscopic examination show marked dispersion and diminution of the collagen fibers of the IUS wall. The mucosa and muscle layer of the IUS are minimally affected. In the *clinical trial* the UPP was done and showed high urethral pressure, > 90 cm water in the controls, and lower pressure in those with SUI. After injecting alpha-sympathetic blocker phentolamine, the pressure dropped in both volunteers and patients with SUI. The results of the UPP proved the presence of a high alpha-sympathetic tone in the IUS. The acquired high UCP dropped markedly by 26–31% after injecting 5 mg of phentolamine. In the volunteers and patients with SUI, after norepinephrine infusion the lowered

UPP increased and reached previous levels and even higher levels. Cardiovascular parameters were monitored carefully all through. The BP dropped slightly with alpha sympathetic blocker, 10–30/5–10 mm Hg. This was due to a small dose given (5 mg). Larger doses produce a greater drop of the UPP and a greater drop in BP. The norepinephrine infusion was given slowly, 5–30 drops/min. But if the BP rose 30–50/10–20 mm Hg above the original level the infusion was immediately slowed down or stopped depending on other cardiovascular and vital data.

3D-US and MR imaging of the IUS in patients with SUI showed torn IUS. This is seen as echo lucent areas in the IUS, more apparent in cross section of the sphincter, in 3D-US pictures (Figure 9). The extent and the degree of damage that affect the collagen sheet cylinder of



**Figure 11.** Comparison between an intact internal urethral sphincter (**A**) and torn sphincters (**B, C & D**) as seen by 3D-US. (**B**) shows the rupture of the upper part, mainly, with funneling of the bladder neck and collapse; (**C**) shows rupture mainly in the lower part with a flask-shape appearance in spite of the rather empty bladder; (**D**) the rupture is affecting the whole length of the IUS causing collapse of the IUS with apparent shortening of the urethra.

**Slika 11.** Usporedba između intaktnog unutrašnjeg uretralnog sfinktera (**A**) i razderanih sfinktera (**B, C i D**), prikazanih 3D-UZ-om. (**B**) prikazuje razdor uglavnom gornjeg dijela s ljevkastim oblikom vrata mjehora i kolapsom; (**C**) prikazuje razdor uglavnog donjeg dijela s oblikom tikvice unatoč praznom mjehuru; (**D**) razdor zahvaća cijelu duljinu IUS-a uzrokujući njegov kolaps s jasnim skraćanjem uretre.

the IUS give different morphological shapes (*Figures 10–14*).

When the damage affects mainly the upper part of the cylinder, there is loss of the posterior urethro-vesical angle with funneling of the bladder neck. When the damage affects mainly the lower part of the sphincter, there is a flask-shape appearance of the IUS. But if the damage affects the whole length of the IUS, there is a collapse of the cylinder walls with irregularities and apparent shortening.

Also, microscopic examination of the vagina showed that it is composed of a dense collageno-elastic-muscular sheet in normal unprolapsed vagina. On the contrary the dense collagenous sheet is torn and macerated in prolapsed vagina (*Figure 6*).

## Discussion

Urinary continence depends on two main factors, one inherent and one acquired:<sup>2–15</sup>

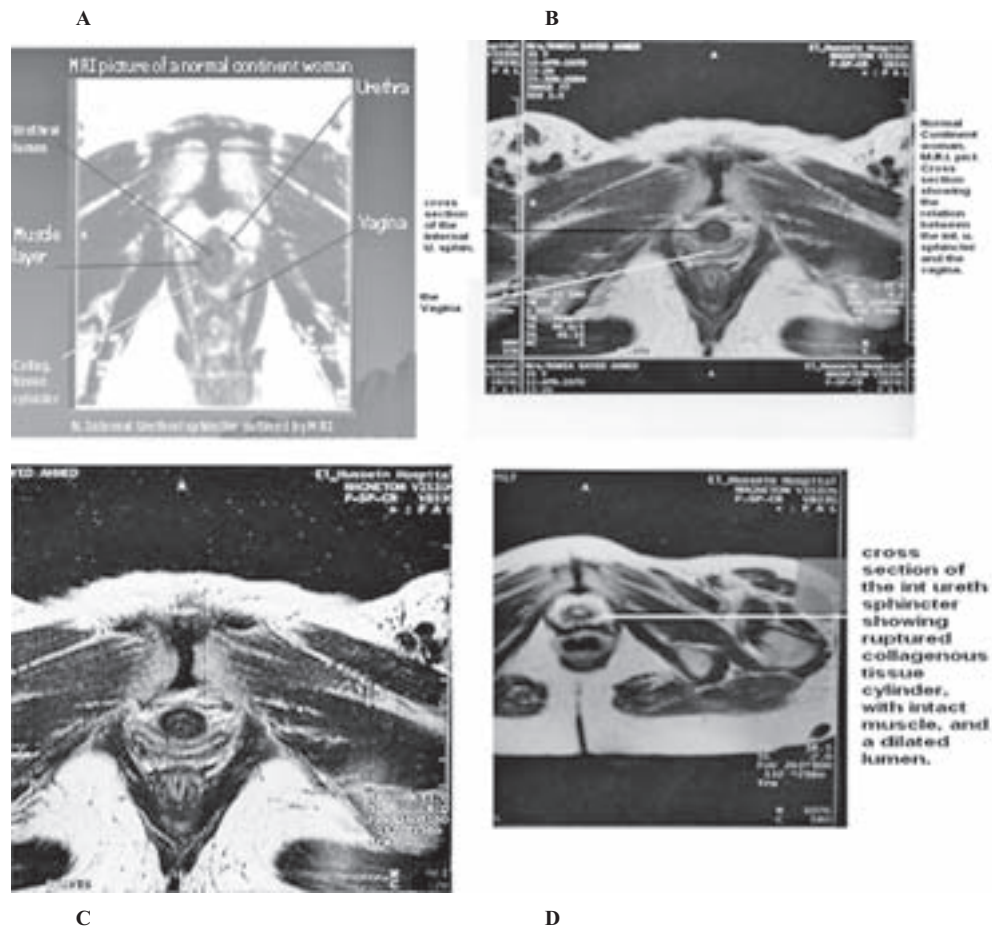
(1) *The inherent factor.* It is the presence of an intact and strong IUS. The IUS is intimately lying on the anterior vaginal wall.

(2) *The acquired factor* (second stage of micturition).<sup>2</sup> This is an acquired behavior gained by learning and training in early childhood how to maintain a high alpha sympathetic tone at the IUS keeping it closed all the time until voiding is needed, and or desired.

Imaging using US and MRI had been tried by some distinguished scientists, to see the state of the bladder neck, the urethra, and their position and their relation to the symphysis pubis and the pelvic floor.<sup>16–20</sup>

A tough and a strong anterior vaginal wall is an essential support for keeping the vagina in its upward position, and is a major support for the intimately overlying IUS and the lower part of the posterior wall of the urinary bladder on filling. A weak overstretched and flabby anterior vaginal wall will fall down (prolapse) with its overlying IUS and lower part of the posterior wall of the urinary bladder. The strength and the toughness of the vaginal wall depend on its rich compact collageno-elastic-mus-





**Figure 12.** MRI cross sections pictures in the pelvis showing the effects of injury on the transverse axis of the vagina and the internal urethral sphincter. The stages of stretching, attenuation and laxity of the vagina changing its cross section from H-shape in (A) into transverse slit in (B) and to more stretching and relaxation with injury to the collagen sheet (C), to more injury and damage to both the internal urethral sphincter and the vaginal walls with more stretching, attenuation and descent of the vaginal walls as seen in (D).

**Slika 12.** MR poprečni presjeci zdjelice prikazuju efekt ozljede poprečne osovine vagine i unutrašnjeg uretralnog sfinktera. Stupnjevi ispružanja, stanjenja i mlohavosti vagine koji se mijenjaju od H-oblika u (A), poprečnog otvora u (B), do jačeg izduženja i mlohavosti s ozljedom kolagene ovojnice (C), sve do još jačeg oštećenja unutrašnjeg uretralnog sfinktera i vaginalne stjenke, s jačim izduženjem, stanjenjem i spuštanjem vaginalne stjenke (D).

cular tissue cylinder. The compact tough collagen bundles, which give strength to the vaginal wall, are essential elements of keeping the vagina in its normal upward position without descending or falling down. As an example, a hard-cover book will stand upright on a shelf, while a paper-cover book will fall down.

Prolonged labor, difficult labor, multiple frequent labors, and operative vaginal deliveries cause stretching, attenuation, split and actual lacerations of the collagen bundles of the vagina causing weakness and laxity of the vaginal wall. After menopause, there is further slowly progressive collagen attenuation caused by ovarian hormone deficiency, which will aggravate the vaginal wall weakness, and the weakness of the IUS. Another factor which may add to the etiology of the vaginal wall weakness and the IUS weakness is repeated and chronic vaginal and urinary infections which will cause degeneration of the collagen.

The weakness and rupture of the vaginal collagen sheet will manifest itself mostly in the transverse axis of the vagina (Figure 15).

This is seen clinically and on imaging. At first, there will be loss of the nulliparous H-shape vagina which changes into a transverse slit in parous women (Figure 12). Then, further weakness will lead to loss of vaginal rugae; the vaginal wall will be smooth without folds as can be seen clinically. Further weakness and rupture of the vaginal collagen will induce vaginal wall redundancy and descent.

The stretching, attenuation, degeneration, split and lacerations which affect the anterior vaginal wall will, without doubt, affect the intimately overlying IUS causing rupture of its posterior wall (Figures 12–14). This will lead to a defective weak IUS with lowered UCP, and subsequent urinary incontinence on provocation.

In patients suffering SUI, the IUS is torn and disrupted with echo-lucent areas on imaging with 3D-US (Figure 9-A). Depending on the level and extent of the damage along the cylinder there are different morphological and functional changes. When the damage affects mainly the upper part there will be weakness of the upper part giving the morphological changes described as seen

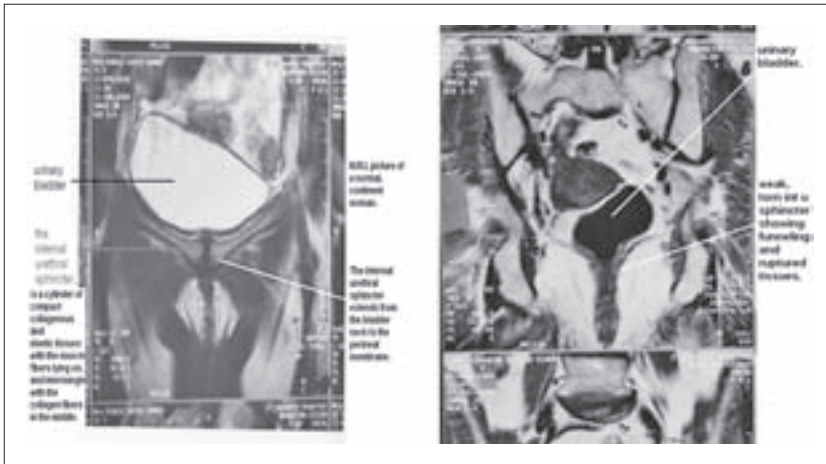
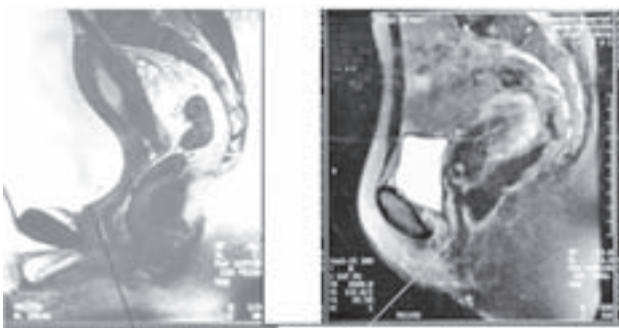


Figure 13. A comparison of MRI coronal sections, of a normal internal urethral sphincter on the left, compared to a torn internal sphincter with a wide urethra on the right, with funneling of the upper part and a flask-shape appearance of the lower part.

Slika 13. Usporedba MR koronarnih presjeka normalnog unutrašnjeg sfinktera (lijevo) s razderanim unutrašnjim sfinkterom (desno) s ljevkastim gornjim dijelom i tikvičastim oblikom donjeg dijela.



A tough and strong vagina is an essential support for the intimately overlying int. u. sph. and the lower part of the post. wall of the UB.  
A torn, weak anterior vag. wall will fall down, prolapse, with its overlying torn internal urethral sphincter as seen here.

Figure 14. MRI pictures of the normal and torn vagina and internal urethral sphincter, sagittal view. Left: the vagina and internal urethral sphincter are both intact. Right: the vaginal wall is torn, more in the central middle part than in the periphery; the intimately overlying internal urethral sphincter is torn as well.

Slika 14. MR prikazi sagitalnog presjeka normalne i razderane vagine i unutrašnjeg uretralnog sfinktera. Lijevo: vagina i unutrašnji uretralni sfinkter su netaknuti. Desno: stijenka rodnice je oštećena, jače u središnjem dijelu nego na periferiji, blisko prilježući uz unutrašnji uretralni sfinkter koji je isto tako oštećen.

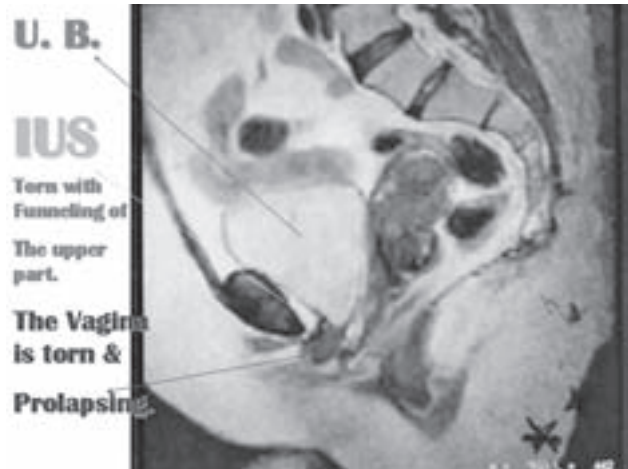


Figure 15. MRI picture, sagittal section. The IUS is a cylinder that extends from the bladder neck to the urogenital diaphragm; it is torn mainly in its upper part with funneling of the bladder neck. The vagina is also torn and prolapsing.

Slika 15. MR slike, sagitalni presjeci. IUS je cilindričnog oblika, proteže se od vrata mjehura sve do urogenitalne dijafagme; razderotina je pretežno u gornjem dijelu s ljevkastim vratom mjehura. Vagina je također oštećena i spuštena.

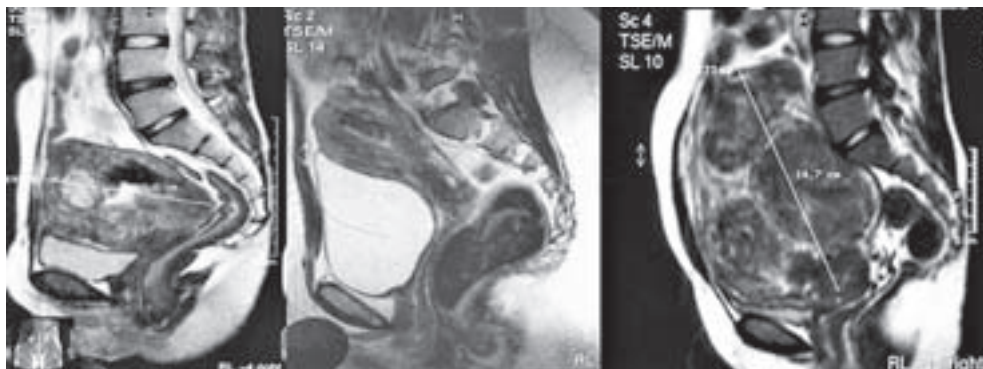


Figure 16. MRI pictures, sagittal view. The patient with fibroid uterus pressing and displacing the urinary bladder down, but the internal urethral sphincter is still intact, with no leakage of urine.

Slika 16. MR slike, sagitalni presjek. Pacijentica s miomatoznim uterusom, koji potiskuje mokraćni mjehur prema dolje, a uretralni sfinkter je još uvijek netaknut, bez bjezanja mokraće.



in figures 4-B, 10-B and -D, 11-B, 13-B and 14-B. Urine will enter the upper part of the urethra on sudden increase of intra-vesical pressure giving sensation of sudden desire to void, detrusor overactivity (DO). When the damage affects mainly the lower part there will be a flask-shape appearance (Figures 10-C, 11-C and 13-B), and genuine SUI ensues. When the damage affects the entire length there will be collapse of the urethra, with apparent shortening and mixed type of urinary incontinence (Figures 10-B, 11-D, 13-B and 14-B).

Reconstruction and repair of the torn wall will restore the normal shape and site of the bladder neck and urethra. This is done by »Urethro-vaginoplasty« operation.<sup>17</sup> In some patients suffering from SUI, the urodynamic studies show high UCP at rest. This is seen in cases where there is just splitting of the compact collagenous tissue cylinder, without any observable defective rupture in this compact layer, leaving the IUS with high wall tension at rest. However, on stress the split weak wall yields leading to leakage of urine. This defect can be better assessed by 3D-US studies.

Increased abdominal pressure and pressure on the bladder as for example due to fibroids, do not lead to SUI if the IUS is intact and strong (Figure 16).

## Conclusion

Weakness and/or rupture of the pelvic collagen will lead to pelvic organ prolapse (POP) and voiding troubles. If the injury affects the collagen of the IUS it will lead to SUI, DO or mixed type of urinary incontinence. If the vaginal collagen gets the insult it will lead to vaginal prolapse. If the insult affects the pelvic ligaments it will produce uterine and vault prolapse.

## References

- McGuire EJ, Cespedes D, O'Connell HE. Leak-point pressures. *Urologic Clinics North Am.* 1996;23(2):253–62.
- El Hemaly AKM, Mousa LA. Micturition and urinary incontinence. *Int J Gynecol Obstet* 1996;42:291–2.
- El Hemaly AKM, Mousa LAE. Stress urinary incontinence, a new concept. *Eur J Obstet Gynecol Reprod Biol* 1996;68:129–35.
- El Hemaly AKMA. Urinary incontinence in gynecology, a review article. [http://www.obgyn.net/urogyn/urogyn.asp?page=/urogyn/articles/abs.urinary\\_incontinence\\_gyn\\_chemaly](http://www.obgyn.net/urogyn/urogyn.asp?page=/urogyn/articles/abs.urinary_incontinence_gyn_chemaly).
- El Hemaly AKM. Nocturnal enuresis: Pathogenesis and treatment. *Int Urogynecol J Pelvic Floor Dysfunct* 1998;9:129–31.
- El Hemaly AKM. Nocturnal enuresis: A Novel concept on its pathogenesis and treatment. [http://www.obgyn.net/urogynecology/?page=articles/nocturnal\\_enuresis](http://www.obgyn.net/urogynecology/?page=articles/nocturnal_enuresis).

7. El Hemaly AKM. Nocturnal Enuresis: An update on the pathogenesis and treatment. [http://www.obgyn.net/urogynecology/?page=/ENHLIDH/PUBD/FEATURES/Presentations/nocturnal\\_enuresis](http://www.obgyn.net/urogynecology/?page=/ENHLIDH/PUBD/FEATURES/Presentations/nocturnal_enuresis).

8. Kandil IM, El Hemaly AKM, Radwan MM. Ultrasonic assessment of the internal urethral sphincter in stress urinary incontinence. *Int J Gynecol Obstet* 2003;2 ,No 1.

9. El Hemaly AKM, Kandil IM, El Mohamady BE. Menopause, and voiding troubles. <http://www.obgyn.net/displayppt.asp?page=/English/pubs/features/presentations/el-hemaly03-ss>

10. El Hemaly AKM, Kandil IM. Stress Urinary Incontinence (SUI) facts and fiction. Is SUI a puzzle?!<http://www.obgyn.net/displayppt.asp?page=/English/pubs/features/presentations/el-hemaly-ss>

11. El Hemaly AKM, Maksoud NA, Mousa LA, Kandil IM, Anwar A, El Hemaly MAK, El Mohamady BE. Evidence based facts on the pathogenesis and management of SUI. <http://www.obgyn.net/displayppt.asp?page=/English/pubs/features/presentations/el-hemaly02-ss>

12. El Hemaly AKM, Kandil IM, Radwan MM. Urethro-raphy. A new technique for surgical management of stress urinary incontinence. <http://www.obgyn.net/urogyn/urogyn.asp?page=/urogyn/articles/new-tech-urethro>.

13. El Hemaly AKM, Kandil IM, Rizk MA, Nabil A, Maksoud H, Radwan MM, El Shieka KZ, El Hemaly MAKM, El Saban AT. Urethro-raphy. The new operation for the treatment of stress urinary incontinence, SUI, detrusor instability, DI, and mixed-type of urinary incontinence; short and long term results. <http://www.obgyn.net/urogyn/urogyn.asp?page=urogyn/articles/urethrography-09280>

14. El Hemaly AKM, Kandil IM, Rizk MA, El Hemaly MA KM. Urethro-plasty, a novel operation based on a new concept, for the treatment of stress urinary incontinence, S.U.I., detrusor instability, D.I., and mixed-type of urinary incontinence. [http://www.obgyn.net/urogyn/urogyn.asp?page=/urogyn/articles/urethro-plasty\\_01](http://www.obgyn.net/urogyn/urogyn.asp?page=/urogyn/articles/urethro-plasty_01).

15. El Hemaly AKM, Kandil IM, Mousa LAS, El Hemaly MAKM. Urethro-vaginoplasty, an innovated operation for the treatment of: stress urinary incontinence (SUI), detrusor overactivity (DO), mixed urinary incontinence and anterior vaginal wall descent. [http://www.obgyn.net/urogyn/urogyn.asp?page=/urogyn/articles/urethro-vaginoplasty\\_01](http://www.obgyn.net/urogyn/urogyn.asp?page=/urogyn/articles/urethro-vaginoplasty_01)

16. Khullar V, Salvatore S, Cardozo L, Kelleher CJ, Bourne TH. A novel technique for measuring bladder wall thickness in women using vaginal ultrasound. *Obstet Gynecol* 1994;(4):220–3.

17. Macura KJ, Genadry RR, Bluemke DA. MR imaging of the female urethra and supporting ligaments in assessment of urinary incontinence: spectrum of abnormalities. *Radiographics* 2006;26(4):1135–49.

18. Khullar V, Cardozo L. Imaging in urogynaecology. *Br J Obstet Gynaecol.* 1996;103:1061–7.

19. Klutke C, Golomb J, Barbaric Z et al. The anatomy of stress incontinence: magnetic resonance imaging of the female bladder neck and urethra. *J Urol* 1993;143:563–6.

20. Mostwin JL, Yang A, Sanders R, Genadry R. Radiology, sonography and magnetic resonance imaging for stress incontinence. *Urol Clin North Am* 1995;22(3):539–49.

*Paper received:* April, 9, 2009; *accepted:* September, 15, 2009.

*Address for correspondence:* Abdel Karim M El Hemaly, MRCOG-FRCS, prof. in Obstetrics & Gynaecology, Al Azhar University, Faculty of Medicine, 3 Emad El Din Kamel St, Nasr city, Post No:11371, Cairo, Egypt. E-Mail : profakhemaly@hotmail.com