

## PALEORADIOLOGICAL STUDY ON TWO INFANTS DATED TO THE 17<sup>th</sup> AND 18<sup>th</sup> CENTURIES

### PALEORADIOLOŠKA STUDIJA O DVOJE DOJENČADI IZ 17./18. STOLJEĆA

Gabriele Sernesi\*, Enrico Petrella\*\*, Luca Ventura\*\*\*,  
Giorgio Gruppioni\*\*\*\*, Donata Luiselli\*\*\*\*, Elisabetta Cilli\*\*\*\*,  
Adele Canalini\*, Mirko Traversari\*\*\*\*\*

#### SUMMARY

*During an excavation campaign in the Church of the Conversion of Saint Paul in Roccapelago (North Italy), a hidden crypt was discovered, which yielded the remains of more than 400 individuals. The crypt was used as a cemetery by the inhabitants of the village of Roccapelago between the 16<sup>th</sup> and 18<sup>th</sup> centuries. Along the north side of the crypt, an area apparently separated from the rest of the burials was found, bordered by stones, where several burials of newborns and infants were concentrated. From here, five fabric rolls containing bones were recovered, and it was decided not to carry out destructive analyses, allocating the two best examples to a thorough radiological investigation to try to define the type of burial*

---

\* Department of Medical and Surgical Sciences, University of Modena and Reggio Emilia, Modena, Italy.

\*\* Department of Radiology, AUSL Romagna, Morgagni-Pierantoni City Hospital, Forlì, Italy.

\*\*\* Division of Pathology, San Salvatore Hospital, L'Aquila and Department of Biotechnological and Applied Clinical Sciences, University of L'Aquila, Italy

\*\*\*\* Department of Cultural Heritage, University of Bologna, Ravenna, Italy.

\*\*\*\*\* Department of Cultural Heritage, University of Bologna, Ravenna, Italy. ORCID: <https://orcid.org/0000-0002-6376-7626>.

*Correspondence Address:* Mirko Traversari, Department of Cultural Heritage, University of Bologna, Via degli Ariani 1, 48121, Ravenna, Italy. E-mail: [mirko.traversari@gmail.com](mailto:mirko.traversari@gmail.com).

and the complete biological profile of the infant. The two rolls, subjects of this study, can be dated archaeologically between the 17<sup>th</sup> and 18<sup>th</sup> centuries. CT analysis shows a varied group of bones with a fairly good state of conservation. The paleoradiological study carried out had the primary objective of avoiding the destruction of the two rolls, ensuring their conservation; but at the same time, providing essential data to understand their nature, defining the biological profile and the type of deposition.

**Keywords:** paleoradiology, infant mortality, paleopathology

## INTRODUCTION AND ARCHAEOLOGICAL CONTEXT

During an excavation campaign in the Church of the Conversion of Saint Paul in Roccapelago (North Italy), a hidden crypt was discovered. Archaeological excavations inside the crypt were conducted between 2009 and 2011, which yielded the remains of more than 400 individuals. The crypt was used as a cemetery by the inhabitants of the village of Roccapelago between the 16<sup>th</sup> and 18<sup>th</sup> centuries (Traversari et al., 2020; Lugli et al., 2018). A large number of human remains mostly consisted of commingled and completely skeletonized human remains, with some corpses, especially among the most recent stratigraphic units, which have undergone a different process of decomposition. A study of the textiles suggests that the bodies were dressed in tunics and socks and wrapped in shrouds. The age range of the skeletal assemblage was very wide, as hundreds of non-adult skeletal remains were also retrieved (Vellone et al., 2015). Along the north side of the crypt, an area apparently separated from the rest of the burials was found, bordered by stones. Here, several burials of newborns and infants were concentrated, whose bones were found to be wrapped in shreds of cloth in some cases. The analysis of the parish registers made it possible to recognize the so-called *Sepolcro degli Angeli* (Sepulchre of the Angels) or *Cimitero degli Infanti* (Cemetery of the Infants), in this area—a place clearly reserved for the deposition of children (Figus et al., 2017). Five rolls of cloth were recovered in total and, considering the peculiarity of the finds, we decided to micro-dig one (T9-Iv3), in agreement with the officials of the Archaeological, Beautiful Arts and Landscape Superintendence of Bologna, Modena, Reggio Emilia, and Ferrara, thereby unrolling the fabric to try to understand its nature. Thus, it emerged that, in reality, the roll represented the remains of a shirt, of which a gathered ribbon neckline was still recognizable with few residual osteological elements inside (Fig. 1).

We decided not to carry out further destructive analyses. However, we allocated the two best examples to a thorough radiological investigation to try to define the type of burial and the complete biological profile of the infant.



Figure 1. T9-Iv3, on the left, the state in which it was recovered, and on the right, when the micro-excavation is completed: these are the shreds of a shirt with a gathered neckline. The few recovered osteological elements are pertinent to a neonatal individual's side and arm.

### MATERIAL AND METHODS

The two rolls, subjects of this study, signed T9-Iv1 and T9-Iv2, were archaeologically dated between the 17<sup>th</sup> and 18<sup>th</sup> centuries (Figus et al., 2017). T9-Iv1 appeared to be more compromised by taphonomic processes. Its consistency was not compact. Thus, it was considered prudent not to remove it from the plastic bag that contained it. It was also difficult to recognize some elements of a textile nature, the fabric was very pleated; there seemed to be some seams and some insect exit holes, a symptom of a putrefactive process inside it (Vanin et al., 2020). T9-Iv2 was more solid and compact, again, traces of the passage of insects inside it were evident, as well as what could be a lace that perhaps decorated the end of the neckline or a sleeve (Fig. 2).



Figure 2. On the left T9-Iv1, on the right T9-Iv2.

In both cases, the vegetable fiber that constitutes the weave of the fabric appeared to be linen (Biselli et al., 2020). The radiological investigation on the two subjects was performed with a 64-slices Brilliance, Philips Medical System (Eindhoven - The Netherlands) CT imaging equipment. In the case of the first roll (T9-Iv1), the acquisition was carried out using a protocol called: “Dual Energy ^ DE-HeadAngio BoneRem (Adult)”, with acquisition parameters corresponding to 180 mA and 100 kV. The slice thickness and the interval of both acquisition and reconstruction are equal to 0,6 x 0,6 mm, and the scan consists of 557 slices. In the investigation of the second roll (T9-Iv2), the acquisition was carried out using a protocol called “Dual Energy ^ DE-Spine-Metal-Vol (adult)”, with acquisition parameters corresponding to 180 mA and 100kV. The slice thickness and the interval of both acquisition and reconstruction correspond to 0,6 x 0,6 mm (Petrella et al., 2016; Traversari et al., 2019a; Traversari et al., 2019b; Traversari et al., 2016) and a total of 561 slices were reconstructed. To estimate the age at death of the bone elements, the protocol drawn up by Scheuer, Musgrave, and Evans (1980) was used. Then it was approved according to the classification proposed by Fazekas and Kòsa (1978), and the results were validated by observing the postnatal ossification (Garn, Rohmann & Silverman, 1967). The appendicular skeleton was measured in a virtual environment. For the analysis of the diseases, classical manuals and atlases were used for comparison, including the “Photographic Regional Atlas of Bone Disease” (Mann & Hunt, 2013), “The Cambridge Encyclopedia of Human Paleopathology” (Aufderheide, & Rodriguez-Martìn, 1998) and “Identification of Pathological Conditions in Human Skeletal Remains” (Ortner, 2003).

## RESULTS

### *T9-Iv1*

CT analysis shows a varied group of bones with a fairly good state of conservation. There are no objects that can better locate or reveal the identity of the infant contained therein. The axial image package allows observation of 11 easily measurable and identifiable bones mixed with numerous small fragments too complex to identify and partially hidden by the shreds of tissue that completely envelop the contents. In no case is the presence of tendons detectable, while the few visible soft tissues appear as a shapeless mass devoid of any anatomical identity. It is possible that some hyper-intensities may be due to stones or small radiopaque objects. A virtual environment measurement of all recognizable bones in the sequence was performed, after which MPR-type reconstructions, in particular the observation, was concentrated on the coro-

nal plane and MIP type. From a practical point of view, therefore, this reconstruction algorithm highlights very dense structures against the background and is ideal for the correct visualization of the bones, which appear distinctly contrasted. In particular, two femurs can be identified, of which the *linea aspera* and the nutritive foramen are distinguishable from the axial package. The proximal epiphyses are slightly ovalized and angled, while the distal epiphyses are ovalized in correspondence with the proximal tibia, even if its tuberosity is not evident, it is normally well recognizable. They measure 5,97 cm (right) and 5,74 cm (left), respectively, which allows us to infer about 33,38 ( $\pm 2,08$ ) weeks of age at the death of the infant. On the lateral portion of the pouch, it was possible to identify a right radius and ulna. Analyzing the radius, it is noted that the proximal epiphyses appear to have a rather characteristic slight lateral tilt. The two bones indicated measure 4,06 cm (right radius) and 4,64 cm (right ulna), respectively, which leads to the conclusion that the radius has a corresponding age of 32,07 ( $\pm 2,29$ ) weeks. As for the ulna, on the other hand, it is identified in partial overlap with the radius (on the coronal plane) in what seems likely to be an anatomical position. The profile is slightly curved and frailer than the radius. It also appears slightly longer than the latter. The distal epiphysis appears slightly oval compared to the other bones, while it is possible to see the radial node on the posterolateral side (in the axial plane). The measure of the ulna allows us to deduce an age at death of 32,66 ( $\pm 2,20$ ) weeks (Fig. 3).

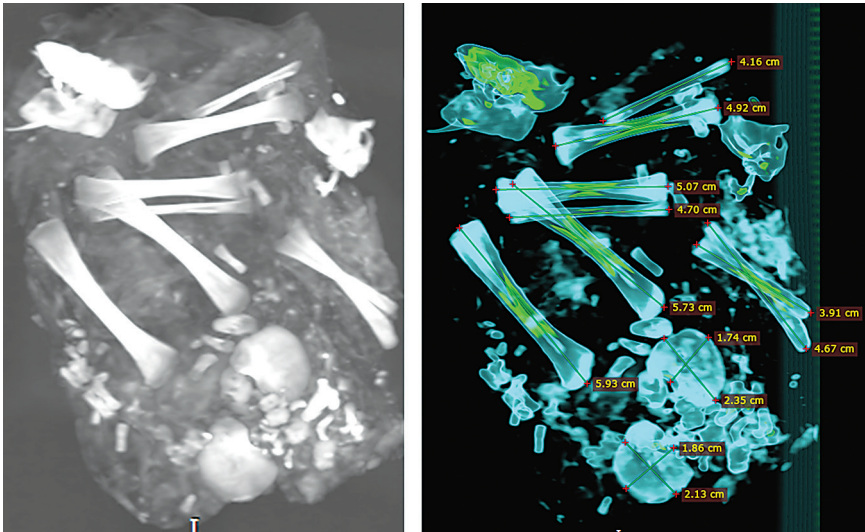


Figure 3. On the left, MIP reconstruction, complete view of T9-Iv1 on the coronal plane; on the right, coronal view with staggered colors and bone measurements useful for calculating age.

By observing the coronal plane, it was possible to glimpse the first of the two lower limbs of the infant, the right one, consisting of clearly distinguishable tibia and fibula and partially overlapping the femur; near the right limb, the left one is identifiable. The perinatal tibiae are more robust than the radius, ulna, and fibula and, consequently, are more radiopaque. They are naturally shorter than the femur, and the triangular course of the diaphyseal profile is highly characteristic. The proximal epiphysis of the tibia is slightly oval at the distal femur but is slightly smaller and has an anterior tuberosity. The distal epiphysis of the tibia, on the other hand, is flat, with a D-shaped profile and a smooth lateral edge. From the measurements, it was obtained that the two tibiae are 5,12 cm (right) and 5,06 cm (left) long, respectively, which leads to the inference that they both return 32,93 ( $\pm 2,12$ ) weeks as the age at the time of death. Considering the two fibulae, however, it was possible to see that they are shorter and less robust than the femurs and tibiae, and for this reason, they return a slightly less intense signal. They have a length comparable to the ulna, even if they do not show particular characteristics, and are linear, narrow, and with a very simple profile. The proximal fibula shows a rounded profile and a rounded metaphyseal surface. The distal fibula instead shows a vaguely triangular metaphysis. From the measurements, 4,77 cm (right) and 4,13 cm (left), respectively, were obtained, corresponding to an interval from 32 to 34 estimated weeks of age at the time of death. In correspondence with the femurs, on the coronal plane, and in a probably anatomical position, it was possible to identify and analyze the two ilia in a fairly good state of conservation. On the axial plane, the acetabulum and the postero-superior and postero-inferior iliac spines are distinguishable. For the metric, the maximum length (the distance between the anterior and posterior superior spine) and the maximum width (between the iliac crest's midpoint and the acetabular tip's convexity) were considered. Measurements in length and width of the two bones returned the following values: 2,36 cm and 2,31 cm (right), 1,78 cm and 1,67 cm (left). Length corresponds to 34 weeks of age, while the width corresponds to 28 weeks. Inside the roll, it is also possible to identify bone fragments probably attributable to vertebrae and carpal bones parallel to other elements making up the hand. However, it was decided not to proceed with the measurement of these elements, as they are not necessary for the resolution of the investigation and due to their incomplete arrangement (Table 1).

Table 1. Summary of the measurements made on T9-Iv1.

Bone	Measure (cm)	Estimated age of death (weeks from conception)	Result
Radius (right)	4,06	32,70 ( $\pm$ 2,29)	32-34 weeks
Ulna (right)	4,64	32,66 ( $\pm$ 2,20)	
Femur (right)	5,97	33,38 ( $\pm$ 2,08)	
Femur (left)	5,74	33,38 ( $\pm$ 2,08)	
Tibia (right)	5,12	32,93 ( $\pm$ 2,12)	
Tibia (left)	5,06	32,93 ( $\pm$ 2,12)	
Fibula (right)	4,77	32-34	
Fibula (left)	4,13	32-34	
Ilium (right)	2,36 (length), 2,31 (width)	34 (length), 28 (width)	
Ilium (left)	1,78 (length), 1,67 (width)	34 (length), 28 (width)	

*T9-Iv2*

CT analysis shows three long bones mixed with numerous fragments and splinters influenced by numerous taphonomic modifications. Also, in this case, a measurement in the virtual environment of all the bones recognizable by the sequence was performed. Subsequently, MPR-type reconstructions were carried out, and also of the MIP type. The three bones are identifiable as a partially incomplete right upper limb consisting of a humerus, a radius, and a fragmented ulna. Regarding the humerus, the olecranon fossa is partially identifiable, and its greater radiopacity and, consequently, robustness with respect to the bones of the forearm are evident. The medial border appears more strongly curved than the lateral border. The length of the humerus is 6,83 and corresponds to 39,83 ( $\pm$ 2,33) weeks of age at the time of death. As for the other two long bones, morphologically identifiable as a radius and an ulna, we note the greater gracility and shorter length of the first compared to the second. It is noted that the proximal metaphysis has the typical lateral tilt characteristic of the radius. This one has a length of 5,98 cm corresponding to 42,8 ( $\pm$ 2,29) weeks (Fig. 4).

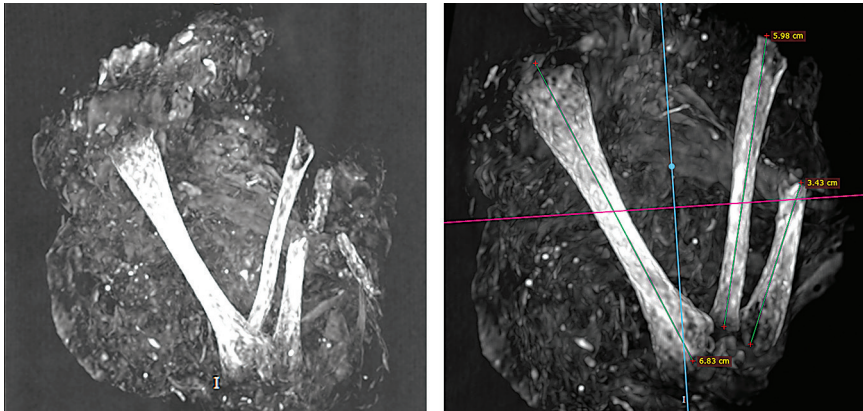


Figure 4. On the left, MIP reconstruction, complete view of T9-Iv2 on the coronal plane; on the right, grayscale vision and bone measurements useful for calculating age.

The ulna, on the other hand, can be identified in concomitance with the radius in an anatomical position. The profile is slightly curved and slenderer than the latter. However, the fragment is incomplete, and a distal portion is certainly missing, preventing further measurements or comparisons from being carried out. From the sets of axial images, the radiolucent layer of tissue interspersed with millimeter objects (stones or other small radiopaque materials), probably calcific fragments, and from the aforementioned bones, which have the highest signal intensity, is partially distinguishable. Also, in this case, the presence of tendons was not detectable, and the few hypothetical soft tissues present were not distinguishable, again appearing as a shapeless mass without anatomical identity (Table 2).

Table 2. Summary of the measurements made on T9-Iv2.

Bone	Measure (cm)	Estimated age of death (weeks from conception)	Result
Humerus	6,83	39,83 ( $\pm$ 2,33)	39-42 weeks
Radius	5,98	42,8 ( $\pm$ 2,29)	
Ulna	Incomplete	Not determinable	

## DISCUSSION AND CONCLUSIONS

Both individuals were recovered from an area of the crypt dedicated to the burial of infants. Parish registers of the deaths recognize this area alternately



as Sepolcro dei fanciulli (sepulchre of children), Arca dei fanciulli (children's ark), or Sepolcro degli angeli (sepulchre of angels) (Fig. 5).




Figure 5. Note dated 11 August 1765, from the II Book of the Dead (1738-1891) of Roccapelago, in which we read that Lucia Maddalena Liberata Vannoni, who died at the age of one, was buried in the Sepulcher of the Angels.

The taphonomic conditions are different, probably because, in the case of T9-Iv1, the fabric was arranged in a narrower and enveloping way, partially preventing the fauna from perpetuating the degenerative process. While for T9-Iv2, conditions of discovery showed that the infant was more compromised, preventing us from finding a defined anatomical identity, perhaps because the burial conditions were less meticulous in this particular case, or because post-depositional interventions had disrupted the deposition. CT analyses did not allow us to highlight particular pathological *stigmata*. There were no signs of pre- or post-mortem fractures, nor markers that would allow us to assume any previous pathology or that would allow us to identify the cause of death, certainly related to a medical cause, linked to the final stages of gestation, certainly not as confidently as for the present era. However, in the case of T9-Iv1, it was possible to hypothesize a cause of death due to maternal complications and spontaneous abortion. The calculations carried out using the maximum diaphyseal length for the bones in acceptable conditions returned a probable age between 32 and 34 weeks of gestation, therefore, a non-term birth. The anatomical position of discovery and deposition, with the exception of the petrous rocks and some small fragments, allowed us to deduce that the child was composed inside the crypt, dressed in what appeared to be a shirt and that his recovery, still in an anatomical position, is witness to a primary deposition. No further objects were accompanying the body, making it impossible to identify more precisely. However, its state of conservation remains more than acceptable for the purposes of the conducted studies. As for T9-Iv2, on the other hand, it was deduced from the possible measurements that he was born at term, died during the expulsive period, or

a few days after birth. The conditions of discovery were much more compromised than the first, so much so that it was possible to perform densitometric calculations on only two bones. It was possible to hypothesize an age between 39 and 42 weeks. The deposition modalities, even if completely similar to T9-Iv1, are more degraded and compromised, with a large loss of bone elements, a phenomenon perhaps due to more marked taphonomic effects. However, even in this case, it is a primary deposition with no objects inside that can lead to inferring the identity or social status of the subject. The optimal state of preservation was obtainable thanks to the low temperatures and altitude of the site, which preserved the initial characteristics. In the past, archaeological finds were only analyzed through anthropological or paleo-pathological methods to reveal any anatomical alterations, diseases, or causes of death. However, these methods often caused irreparable damage or destruction of the mummified bodies. The introduction of CT was a precursor for a fundamental breakthrough, which made it possible to obtain much more detailed imaging, including organs and soft tissues, while also preserving the integrity of the bodies. Thanks to the virtual dissection only, it was possible to distinguish the bandage from the rest of the materials, and the anatomy is perfectly distinguishable. Moreover, CT scans have enabled the detection of traces of pathology in adult subjects (Ventura et al., 2020a) as well as in infant mummies wrapped in fabrics (Ventura et al., 2007). Conventional X-ray examination may also be employed not only as a screening method, but as a diagnostic tool (Ventura et al., 2020b). The discovery of the Roccapelago crypt is unique in Italy, as it is a rare case in which an entire population inscribed between the 16<sup>th</sup> and 18<sup>th</sup> centuries was found in the same place, allowing numerous studies on health and lifestyle in the centuries concerned. In our case, the use of the paleoradiological analysis technique, by its definition minimally invasive, has allowed us to understand the nature of these two subjects without altering the structure with which they have come to the present day, at the same time providing important confirmations to historical sources. In conclusion, we found that the CT scan approach used special and unique parameters in order to obtain the correct spatial and contrast resolutions and highlighted numerous details and the consequent satisfactory anatomical identification of the infants. Further investigations are required, perhaps on larger samples-sizes, aimed at creating a personalized protocol, which could standardize this type of analysis and allow comparisons between different investigations.

## ACKNOWLEDGEMENTS

The authors wish to thank Donato Labate and Luca Mercuri (Archaeological, Beautiful Arts and Landscape Superintendence of Bologna, Modena, Reggio Emilia, and Ferrara) for giving us access to the specimens under their care. We also want to thank Maria Cecilia Hospital in Cotignola (RA), which provided the total body CT scans used in this study. Finally, we would like to thank Adam Jon Andrews for improving the use of English in the manuscript. This research was not supported by funding agencies in the public, commercial, or non-profit sectors. This manuscript represents original work, and it is not under consideration for publication elsewhere. All the authors participated in the preparation of the manuscript. The authors declare no conflict of interest. All authors meet the criteria for authorship, and should the manuscript be acceptable for publication, the authors will sign a statement attesting authorship, disclosing all potential conflicts of interest, and releasing the copyright.

## REFERENCES

1. Archivio Parrocchiale di Roccapelago, Libro dei Morti, 1599-1738.
2. Aufderheide, C. A. & Rodriguez-Martin, C. (1998). *The Cambridge Encyclopedia of Human Paleopathology*. Cambridge: Cambridge University Press.
3. Biselli, A. & Micheletti, I. (2020). Abiti e sudari delle mummie di Roccapelago ed altre esperienze di recupero di abiti da sepolture. In E. Cilli & M. Traversari (Ed.), *Le Mummie di Roccapelago. Un progetto pilota di ricerca interdisciplinare tra archeologia, antropologia, storia e scienze applicate* (pp. 47-60). Bologna: IBC-Istituto per i Beni Artistici, Culturali e Naturali della Regione Emilia-Romagna.
4. Fazekas, I. G. & Kosa, F. (1978), *Forensic Fetal Osteology*. Budapest: Akademiai Kiado.
5. Figus, C., Traversari, M., Scalise, L. M., Oxilia, G., Vazzana, A., Buti, L., Sorrentino, R., Gruppioni, G. & Benazzi, S. (2017). The study of commingled non-adult human remains: Insights from the 16<sup>th</sup>-18<sup>th</sup> centuries community of Roccapelago (Italy). *Journal of Archaeological Science: Reports*, 14, 382-391. <https://doi.org/10.1016/j.jasrep.2017.06.023>
6. Garn, S. M., Rohmann, C. G. & Silverman, F. N. (1967). Radiographic standards for postnatal ossification and tooth calcification. *Medical Radiography and Photography*, 43, 45-66.
7. Lugli, F., Cipriani, A., Tavaglione, V., Traversari, M. & Benazzi, S. (2018). Transhumance pastoralism of Roccapelago (Modena, Italy) early-modern individuals: Inferences from Sr isotopes of hair strands. *American Journal of Physical Anthropology*, 167(3), 470-483. <https://doi.org/10.1002/ajpa.23643>
8. Mann, R. W. & Hunt, D. R. (2013). *Photographic Regional Atlas of Bone Disease: A Guide to Pathologic and Normal Variation in the Human Skeleton*. Springfield: Charles C. Thomas editions.

9. Ortner, D. (2003). *Identification of Pathological Conditions in Human Skeletal Remains*. San Diego: Academic Press, Elsevier.
10. Petrella, E., Piciucchi, S., Feletti, F., Barone, D., Piraccini, A., Minghetti, C., Gruppioni, G., Poletti, V., Bertocco, M. & Traversari, M. (2016). CT Scan of Thirteen Natural Mummies Dating Back to the XV-XVIII Centuries: An Emerging Tool to Investigate Living Conditions and Diseases in History. *Plos One*, 11(6), e0154349. <https://doi.org/10.1371/journal.pone.0154349>
11. Scheuer, J. L., Musgrave, J. H. & Evans, S. P. (1980). The estimation of late fetal and perinatal age from limb bone length by linear and logarithmic regression. *Annals of Human Biology*, 7(3), 257-265. <https://doi.org/10.1080/0301446800004301>
12. Traversari, M., Minghetti, C., Milani, V., Frelat, M. A., Shaw, C. N. & Gruppioni, G. (2020). Le mummie di Roccapelago: ricostruzione delle attività occupazionali in una piccola comunità dall'alto Appennino modenese del XVIII secolo attraverso gli indicatori scheletrici di carico biomeccanico e con l'ausilio di tecnologie virtuali 3D. In E. Cilli & M. Traversari (Eds.), *Le Mummie di Roccapelago. Un progetto pilota di ricerca interdisciplinare tra archeologia, antropologia, storia e scienze applicate* (pp. 182-187). Bologna: IBC-Istituto per i Beni Artistici, Culturali e Naturali della Regione Emilia-Romagna.
13. Traversari, M., Figus, C., Petrella, E., Piciucchi, S., Vazzana, A., Cilli, E., Saragoni, L. & Benazzi, S. (2019a). Paleopathological analysis of a probable case of Jarcho-Levin Syndrome from the 18<sup>th</sup> century northern Italy, *Medicina Historica*, 3(1), 39-45. <https://mattioli1885journals.com/index.php/MedHistor/article/view/8119>
14. Traversari, M., Serrangeli, M. C., Catalano, G., Petrella, E., Piciucchi, S., Feletti, F., Oxilia, G., Cristiani, E., Vazzana, A., Sorrentino, R., De Fanti, S., Luiselli, D., Calcagnile, L., Saragoni, L., Feeney, R. N. M., Gruppioni, G., Cilli, E. & Benazzi, S. (2019b). Multi-analytic study of a probable case of fibrous dysplasia (FD) from certosa monumental cemetery (Bologna, Italy). *International Journal of Paleopathology*, 25, 1-8. <https://doi.org/10.1016/j.ijpp.2019.03.003>
15. Traversari, M., Feletti, F., Vazzana, A., Gruppioni, G. & Freat, M. A. (2016). Three cases of developmental dysplasia of the hip on partially mummified human remains (Roccapelago, Modena, 18<sup>th</sup> Century): a study of palaeopathological indicators through direct analysis and 3D virtual models. *Bulletins et Memoires de la Societe d'Anthropologie de Paris*, 28(3-4), 202-212. <https://doi.org/10.1007/s13219-015-0140-7>
16. Vanin, S., Bortolini, S., Giordani, G. & Tuccia, F. (2020). Indagine morfologica e molecolare sui reperti entomologici di Roccapelago. In E. Cilli & M. Traversari (Eds.), *Le Mummie di Roccapelago. Un progetto pilota di ricerca interdisciplinare tra archeologia, antropologia, storia e scienze applicate* (pp. 182-187). Bologna: IBC-Istituto per i Beni Artistici, Culturali e Naturali della Regione Emilia-Romagna.
17. Vellone, V. G., Repetto, G., Traversari, M., Vazzana, A., Boano, R., Gruppioni, G. & Fulcheri, E. (2015). Pulmonary anthracosis on natural mummies of XVI-XVIII century AD from Roccapelago (MO, Italy). *Pathologica*, 107(3-4), 213-214.
18. Ventura, L., Urbani, V., Ricci, A., Galzio, R., De Vito, M., Fantini, S. & Fornaciari, G. (2007). Subdural chronic hematoma in an infant mummy from Navelli (central Italy). Accidental or intentional injury? In *Proceedings of the VI World Congress on Mummy Studies* (pp. 579-582).

19. Ventura, L., Fornaciari, G., Calabrese, A., Arrizza, L. & Fornaciari A. (2020a). Paleopathology of a 19<sup>th</sup> century mummy of a nobleman from Popoli, central Italy. *Medicina Historica*, 4(1), 29-34. <https://mattioli1885journals.com/index.php/MedHistor/article/view/8741>
20. Ventura, L., Gaeta, R., Zampa, V., Aringhieri, G., Fornaciari, G., Di Lernia, S., Tafuri, M. A., Manzi, G. & Franchi, A. (2020b). Enostosis, hyperostosis corticalis generalisata and possible overlap syndrome in a 7000 years old mummy from Libya. *European Journal of Radiology*, 130, 109183. <https://doi.org/10.1016/j.ejrad.2020.109183>

## SAŽETAK

Tijekom iskapanja u crkvi Obraćanja sv. Pavla u selu Roccapelago (sjeverna Italija) pronađena je skrivena kriptna s ostatcima više od četiristo osoba. Stanovnicima sela Roccapelago kriptna je između 16. i 18. stoljeća služila kao groblje. Uza sjevernu stranu kriptne pronađen je prostor omeđen kamenjem, očito odvojen od ostalih ukopa, u kojem je bilo koncentrirano nekoliko ukopa novorođenčadi i dojenčadi. Ovdje je pronađeno pet smotuljaka tkanine, koji su sadržavali kosti. Donesena je odluka da se ne provode destruktivne analize, a dva najbolja primjerka podvrgnuta su temeljitom radiološkom istraživanju kako bi se pokušala definirati vrsta ukopa te potpun biološki profil djeteta. Dva smotuljka, koji su predmet ove studije, mogu se arheološki smjestiti između 17. i 18. stoljeća. CT analiza pokazuje raznoliku skupinu kostiju s prilično dobrim stanjem očuvanosti. Provedeno paleoradiološko istraživanje imalo je primarni cilj izbjeći uništenje dvaju smotuljaka, osiguravajući njihovu konzervaciju, ali u isto vrijeme pružiti važne podatke za razumijevanje njihove prirode, definirajući biološki profil i vrstu svjedočanstva.

**Ključne riječi:** paleoradiologija, smrtnost dojenčadi, paleopatologija

